

# Clinical distinction between nasal optic disc hypoplasia (NOH) and glaucoma with NOH-like temporal visual field defects

Hiroshi Ohguro  
Ikuyo Ohguro  
Midori Tsuruta  
Maki Katai  
Sachie Tanaka

Department of Ophthalmology,  
Sapporo Medical University School  
of Medicine, Japan

**Purpose:** To report on the clinically important differences between nasal optic hypoplasia (NOH) and glaucoma with NOH-like temporal visual field defect (VFD).

**Method:** Five NOH (four bilateral and one unilateral) patients, three unilateral NOH patients with glaucoma, and two glaucoma patients with NOH-like temporal VFD were clinically characterized. Superior segmental optic nerve hypoplasia was also associated with glaucoma in one eye of a bilateral NOH case and the NOH eye of a unilateral NOH patient. Ocular manifestations including refractive errors, size, and appearances of the optic discs, retinal nerve fiber thickness (NFLT) ascertained by optical coherence tomography (OCT), and VFD were examined.

**Results:** Ophthalmic examinations revealing NOH showed high myopia at more than  $-5.0D$ , a small disc with nasal double-ring appearance, significantly decreased NFLT by OCT, and retinal nerve fiber layer defect in the corresponding nasal sector. Stationary temporal VFD varied from a slight depression of the peripheral isopters to wide sector defects. In contrast, two glaucoma patients with NOH-like temporal VFD showed several different clinical features, including mild myopia less than  $-5D$ , a normal size with glaucomatous disc cupping; a slight decrease in nasal NFLT and progression of temporal and other glaucomatous VFD.

**Conclusion:** Careful evaluation of optic disc appearance and measurement of NFLT using OCT may help to distinguish between NOH and glaucoma with NOH-like temporal VFD.

**Keywords:** nasal optic disc hypoplasia, glaucoma, temporal visual field defects, optical coherence tomography, superior segmental optic nerve hypoplasia

## Introduction

Optic nerve hypoplasia (OH) is a relatively rare congenital defect of the retinal ganglion cells and optic nerve axons, and is clinically characterized by nonprogressive deterioration of vision and visual field defects (VFDs) in one or both eyes.<sup>1,2</sup> A temporal, wedge-shaped VFD breaking out horizontally from the blind spot is rarely recognized as NOH.<sup>3</sup> In 1981, Buchanan reported three cases of NOH<sup>4</sup> corresponding with specific findings in the optic disc, including small disc size, reduced amount of nasal disc tissue, an indented nasal disc margin, and the absence of nerve fiber striations in the nasal peripapillary retina. Since then, four cases of NOH have been reported.<sup>5,6</sup> In terms of the differential diagnosis of NOH, glaucomatous optic neuropathy is important because a sector VFD temporal to the blind spot similar to that of NOH is also detectable in some cases of glaucoma.<sup>3</sup>

In the present study, we examined five cases of NOH, three cases of NOH associated with glaucoma, and two cases of glaucoma associated with NOH-like temporal VFDs.

Correspondence: Hiroshi Ohguro  
Department of Ophthalmology,  
Sapporo Medical University School  
of Medicine South-1 West-16, Chuo-ku,  
Sapporo 060-8543, Japan  
Tel +81 011 611 2111  
Fax +81 011 613 6575  
Email ooguro@sapmed.ac.jp

We compared the clinically significant differences between NOH and glaucoma with NOH-like VFDs in order to gain additional insights into clinical aspects of NOH.

## Patients and methods

Five patients (two male, three female, mean age  $\pm$  standard deviation [SD]  $57.2 \pm 12.0$  years; range 44–74 years) with NOH, three NOH patients with glaucoma (one male, two female, aged  $64.7 \pm 1.52$  years; range 63–66 years), and two patients with glaucoma but not with NOH (a 68-year-old man and a 66-year-old woman) were recruited from 300 patients who have regular review in the glaucoma clinic at Sapporo Medical University Hospital. The study was approved by our Institutional Review Board and all the tenets of Declaration of Helsinki were followed. Informed consent was obtained by all participants.

Refractive errors were measured by an automated refractometer. Size and appearances of the optic discs were examined using fundus photos. The optic disc size was categorized into four groups according to the DM/DD ratio, ie, large disc ( $<2.2$ ;2), normal disc ( $2.2$ – $3.0$ ;3), relatively small disc ( $3.0$ – $3.2$ ;4), or small disc ( $>3.2$ ).<sup>7</sup> The peripapillary retinal nerve fiber thickness (NFLT) in four sectors (temporal  $316$ – $45^\circ$ , superior  $46$ – $135^\circ$ , nasal  $136$ – $225^\circ$ , inferior  $226$ – $315^\circ$ ) was measured using optical coherence tomography (OCT, Stratus, Zeiss-Humphrey, Dublin, CA) according to the method described by Blumenthal et al.<sup>8</sup> The degree and range of VFD were determined using Goldmann perimetry and a Humphrey field analyzer.

## Results

Clinical observations including patient age, sex, diagnosis, refractive errors, DM/DD ratios, disc appearance, presence of a nasal nerve fiber layer defect (NFLD), types of visual field defects and their progression, nasal quadrant NFLD, and duration of follow-up are summarized in Table 1. Among the five NOH patients (#1–5), four (#1–4) showed bilateral NOH and the other had unilateral NOH (#5). Three additional unilateral NOH cases (#6–8) were associated with normal tension glaucoma. Superior segmental optic nerve hypoplasia (SSOH) was also recognized in one eye of the bilateral NOH patient (#4) and in one eye of the unilateral NOH patient associated with glaucoma (#8). In terms of refractive errors, high myopia of more than  $-5.0$  D was found in 8/12 NOH eyes (66.7%).

An ophthalmoscopic examination revealing specific appearances of the optic disc of NOH (Table 1) showed small size (DM/DD ratios in the range 3.3–6.3 except for

one eye of one patient (#5), blurred nasal disc margins with a scleral halo (the so-called “double-ring appearance”) in all 12 NOH eyes (Figures 1–3), and NFLD were seen in the nasal sectors of the peripapillary retina in all NOH eyes (Figures 1–3). In an OCT examination of 10 NOH eyes from seven patients (except #2), NFLT in the nasal sector of the disc was decreased (mean 29.8 microns, 14–45 microns) and, especially in the four NOH eyes from unilateral cases (#4–8; mean 19.5 microns, 14–26 microns), were remarkably thinner compared with that in the other eye (mean 63.5 microns, 52–85 microns). NOH patients with associated SSOH (#4 and #8) also showed decreased NFLT in the superior peripapillary retina (Figure 2). In an analysis by visual field testing, the temporal VFD found in eyes with NOH were varied, ranging from a slight depression of peripheral isopters to wide sector defects (30–90 degree-width) converging on the blind spot (Figures 1–3). These temporal VFDs in the NOH eyes had been static for 2.0 to 13.5 years (mean follow-up period 5.9 years, Table 1). Progressive glaucomatous VFDs were found in both eyes in three unilateral NOH cases (#6–8).

Two glaucoma patients demonstrated NOH-like temporal VFDs in addition to the typical glaucomatous disc appearances and visual field changes (Figures 4 and 5). In contrast with the NOH cases described above, several differences in the clinical features of the glaucoma patients with NOH-like temporal VFDs were detected (see Table 1). These had normal optic disc sizes (DM/DD ratios 2.8–3.0), enlargement of disc cupping and diminution of infero/superotemporal neuroretinal rim (Figures 4 and 5), lack of a nasal double-ring appearance (Figures 4 and 5), OCT showing slightly decreased NFLT in the nasal sector (mean 49 microns, 45–54 microns, Figures 4 and 5), fewer refractive errors ( $-2.75$ D to  $-4.75$ D) than those found with NOH, and typical glaucomatous visual field changes, including depression of the internal isopters, nasal depression, nasal defect and/or isolated scotoma, and NOH-like temporal wedge defects that were progressive during the follow-up period (Figures 4 and 5).

## Discussion

Temporal VFDs are rarely detected as glaucomatous VFDs. In fact, in a previous study by Hart and Becker, temporal VFDs were seen in only 3% of 98 eyes in 72 glaucoma patients.<sup>9</sup> In the present study of 600 eyes in 300 patients who had regular follow-up in our glaucoma clinic, we found temporal VFDs in 15 eyes (2.5% of total eyes) of 10 patients (3.3% of total number of cases). Of these relatively rare 15 eyes in 10 cases,

**Table 1** Clinical features of nasal optic disc hypoplasia (NOH) and glaucoma associated with NOH-like visual field defect

Pt.#	Age sex	Diagnosis	Refractive errors (D)	DM/DD ratio	Disc appearance	Nasal NFLD	Visual field defects (VFD)	Progression of VFD		Nasal quadrant mean NFLT (µm)	Follow-up (years)
								Temporal	Glaucomatous		
1	44 F	OD: NOH	-7.25	6.3	Nas DR	+	Temp Dep	No		41	3
		OS: NOH	-7.50	5.8	Nas DR	+	Temp Wed Def	No		35	3
2	60 M	OD: NOH	-5.00	3.6	Nas DR	+	Temp Dep	No		N.D.	3
		OS: NOH	-6.00	3.6	Nas DR	+	Temp Wed Def	No		N.D.	3
3	61 M	OD: NOH	-6.25	5.8	Nas DR	+	Temp Wed Def	No		28	7
		OS: NOH	-6.00	4.0	Nas DR	+	Temp Dep	No		30	7
4	47 M	OD: NOH + SSOH	-3.50	3.3	Sup DR, Nas DR, Sup EV	+	Temp Dep, Inf Dep	No		45	4
		OS: NOH	-3.25	3.6	Nas DR	+	Temp Wed Def	No		37	4
5	74 F	OD: normal	-5.50	2.9	normal	-	Normal	No		85	13.5
		OS: NOH	-8.75	2.6	Nas DR	+	Temp Wed Def	No		26	13.5
6	63 F	OD: NTG + NOH	-4.50	4.7	Nas DR, Temp Not	+	Nas Def, Temp Wed Def, Iso Sct	No	Yes	19	2
		OS: NTG	-4.75	4.4	Cup Enlarg	-	Int Ispt Dep	No	Yes	53	2
7	66 M	OD: NTG + NOH	-17.0	4.4	Nas DR	+	Nas St, Temp Wed Def	No	Yes	19	11.5
		OS: NTG	-14.0	5.3	Cup Enlarg	-	Nas St, Seidel Sct	No	Yes	52	11.5
8	65 F	OD: NTG	-6.50	4.1	Cup Enlarg, Temp Not	-	Iso Sct	No	Yes	65	7.5
		OS: NTG + NOH + SSOH	-4.75	3.7	Cup Enlarg, Nas DR, Sup EV, Sup DR	+	Nas St, Temp Wed Def, Inf Dep	No	Yes	14	7.5
9	66 M	OD: POAG	-4.75	3.0	Cup Enlarg, Temp Not	-	Temp Wed Def, Nas Def, Iso Sct	Yes	Yes	54	10
		OS: POAG	-4.75	3.0	Cup Enlarg, Temp Not	-	Nas Def, Iso Sct	No	Yes	50	10
10	68 M	OD: NTG	-2.75	2.8	Cup Enlarg	-	Temp Wed Def, Int Ispt Dep	Yes	Yes	45	7.5
		OS: NTG	-2.75	2.9	Cup Enlarg	-	Temp Wed Def, Int Ispt Dep, Nas Dep	Yes	Yes	47	7.5

**Abbreviations:** Pt., patient; OD, right eye; OS, left eye; NOH, nasal optic disc hypoplasia; SSOH, superior segmental optic nerve hypoplasia; POAG, primary open angle glaucoma; NTG, normal tension glaucoma; D, diopters; Nas DR, nasal double-ring appearance; Sup DR, superior double-ring appearance; Temp Not, Temporal notching; Cup Enlarg, cupping enlargement; SupEV, superior entrance of vessels; Temp Dep, temporal depression; Temp Wed Def, temporal wedge defect; Inf Dep, inferior depression; Nas Def, nasal defect; Int Ispt Dep, internal isopter depression; Iso Sct, isolated scotoma; Seidel Sct, Seidel scotoma; Nas St, nasal step; N.D., not determined.

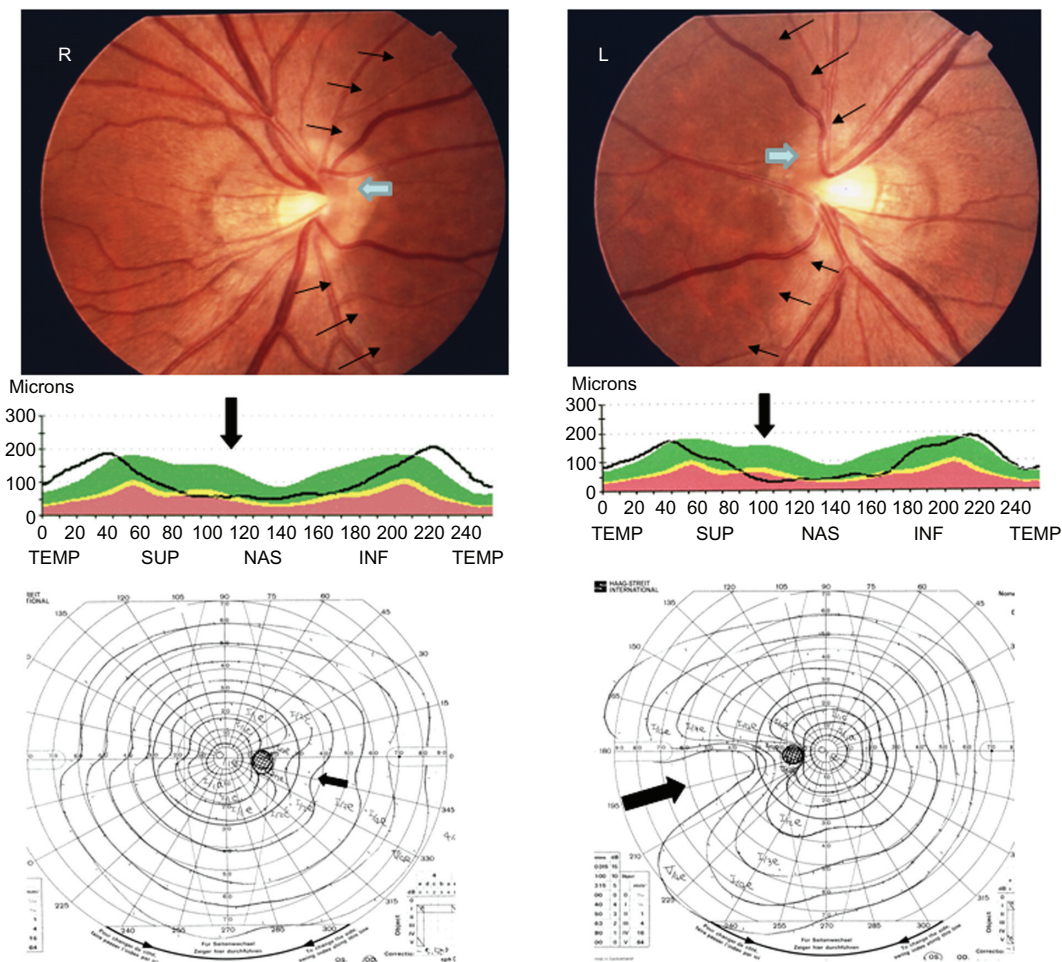
**Table 2** Difference in the ophthalmic features of NOH and glaucoma with NOH-like visual field defects

	Refractive errors	Disc size	Disc appearance		Nasal NFLT by OCT	Temporal visual field defects progression
			Nasal pallor	Double-ring appearance (scleral halo)		
NOH	High myopia (more than -5D)	Small	Apparent	Apparent	Significantly decreased	No
Glaucoma with NOH-like visual field defects	Mild myopia (less than -5D)	Normal	Not apparent	Not apparent	Slightly decreased	Yes

**Abbreviations:** NOH, nasal optic disc hypoplasia; NFLT, retinal nerve fiber layer thickness; OCT optical coherence tomography.

12 eyes from eight cases (Table 1, #1–8) were diagnosed as having NOH based on the diagnostic criteria of Buchanan and Hoyt,<sup>4</sup> ie, small optic disc size, reduced amount of tissue in the nasal sector of the optic disc (such as the indented or abnormally sharp nasal disc margin), absence of nerve fiber

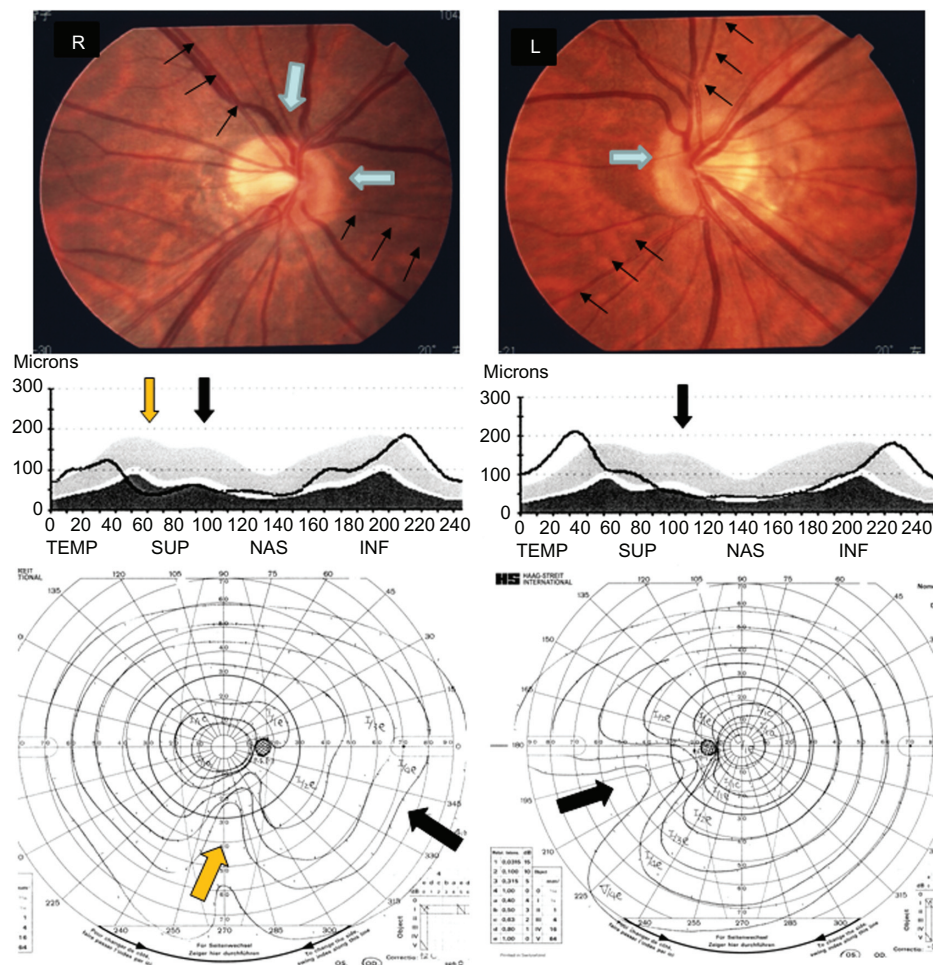
striations in the nasal peripapillary retina, and stationary wedge-shaped temporal VFDs breaking out from the blind spot. In addition to this, we found three distinctive clinical characteristics in our case series of NOH, ie, refractive errors at relatively higher degrees of myopia (>-5.0D), temporal



**Figure 1** Clinical manifestations of a bilateral NOH case (Patient 1).

**Top:** A double-ring appearance of nasal sectors of the optic discs (blurred margins with scleral halo, indicated by a blue arrow) and the presence of NFLD in the nasal sectors of the peripapillary retina (indicated by black arrows) were observed in the fundus photographs. **Middle:** A significant decrease of nasal NFLT (indicated by a black arrow) was evident in OCT analysis. **Bottom:** A temporal depression (OD) and a wedge-shaped temporal VFD (OS, indicated by a black arrow) were detected by Goldman perimetry.

**Abbreviations:** NOH, nasal optic hypoplasia; NFLD, nerve fiber layer defect; NFLT, retinal nerve fiber thickness; OCT, optical coherence tomography; OD, right eye; OS, left eye; VFD, visual field defect.



**Figure 2** Clinical manifestations of a bilateral NOH case with SSOH (Patient 4).

**Top:** A double-ring appearance of bilateral nasal sectors and a right superior sector of the optic discs (indicated by blue arrows) and the presence of NFLD in the bilateral nasal and superior sectors of the peripapillary retina (indicated by black arrows) were observed in the fundus photographs. **Middle:** A decrease of nasal NFLT (OD and OS, indicated by a black arrow) and superior NFLT (OD, indicated by a brown arrow) was evident in OCT analysis. **Bottom:** A temporal depression (OD) and a wedge-shaped temporal VFD (OS) (indicated by a black arrow) and an inferior visual field depression (OD, indicated by a brown arrow) were detected by Goldman perimetry.

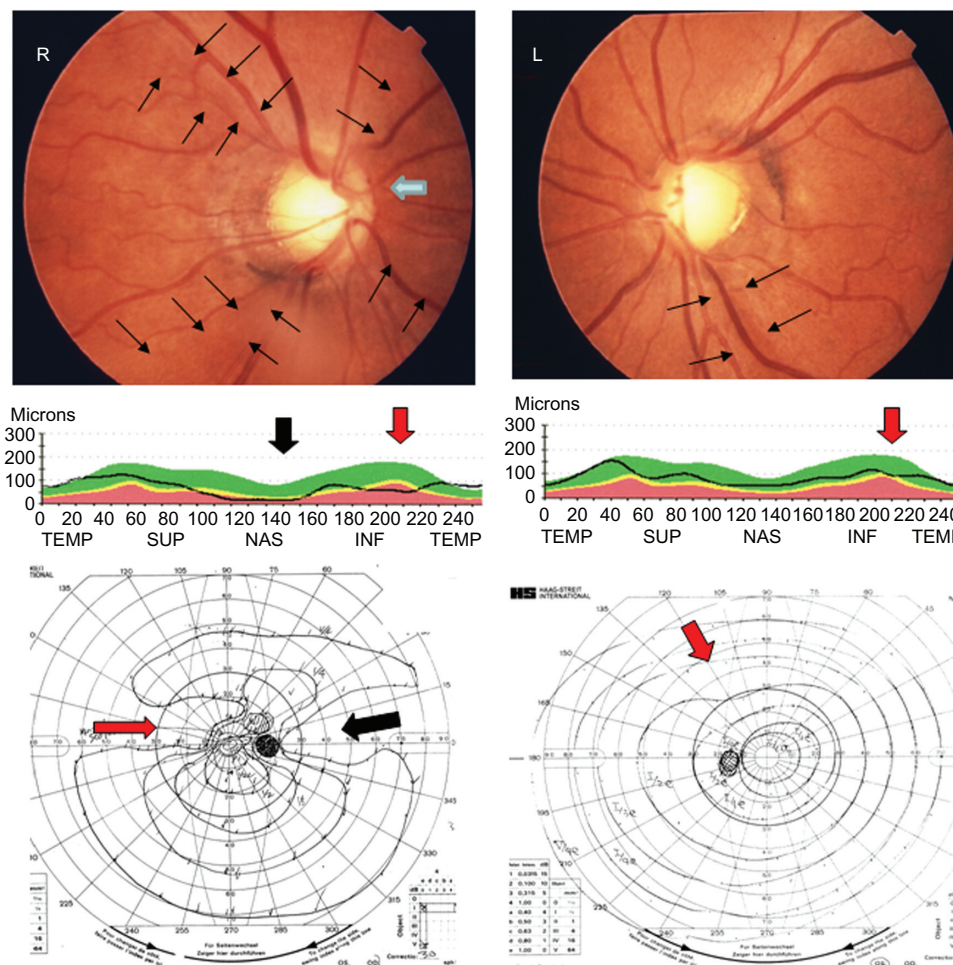
**Abbreviations:** NOH, nasal optic hypoplasia; NFLD, nerve fiber layer defect; NFLT, retinal nerve fiber thickness; OCT, optical coherence tomography; OD, right eye; OS, left eye; SSOH, superior segmental optic nerve hypoplasia; VFD, visual field defect.

VFDs of NOH ranging from a slight depression of peripheral isopters to wide sector defects, the latter corresponding with decreased NFLT in peripapillary nasal retina by OCT, and SSOH and glaucomatous optic neuropathy frequently accompanied by NOH.

OH is isolated but may often be associated with several endocrine and central nervous system deficits.<sup>10</sup> With regard to its clinical features, the small<sup>11</sup> blurred margin and double-ring-shaped optic disc have been identified to be the clinical hallmarks for OH.<sup>12</sup> It has been suggested that diminished numbers of nerve fibers within the confines of a wider scleral canal may cause such a blurred margin and double-ring shape. As described above, the characteristic appearance of the optic discs, ie, small with blurred nasal margins and scleral halo (double-ring appearance), was

commonly found in our NOH cases, but not in glaucoma patients with NOH-like temporal VFDs. Other ocular characteristics have been reported in association with OH, including aniridia,<sup>13</sup> high myopia,<sup>10</sup> chorioretinal and optic nerve coloboma,<sup>14</sup> and Duane retraction syndrome.<sup>15</sup> In our case series of NOH, high myopia (more than  $-5D$ ) was seen in 8/12 NOH eyes (66.7%).

SSOH, in which congenital hypoplastic change occurs within the superior segment of the disc, has been frequently reported in association with OH.<sup>16–18</sup> Yamamoto et al reported that SSOH was detected in 37 (54 eyes) of 14,431 cases (28,396 eyes; 0.3% of total cases and 0.2% of total eyes) during a Japanese survey in the city of Tajimi.<sup>19</sup> Compared with SSOH, NOH is much rarer and in fact only a few cases have been reported to date.<sup>4–6</sup> In our NOH cases, SSOH was



**Figure 3** Clinical manifestations of a unilateral NOH case with NTG (Patient 6).

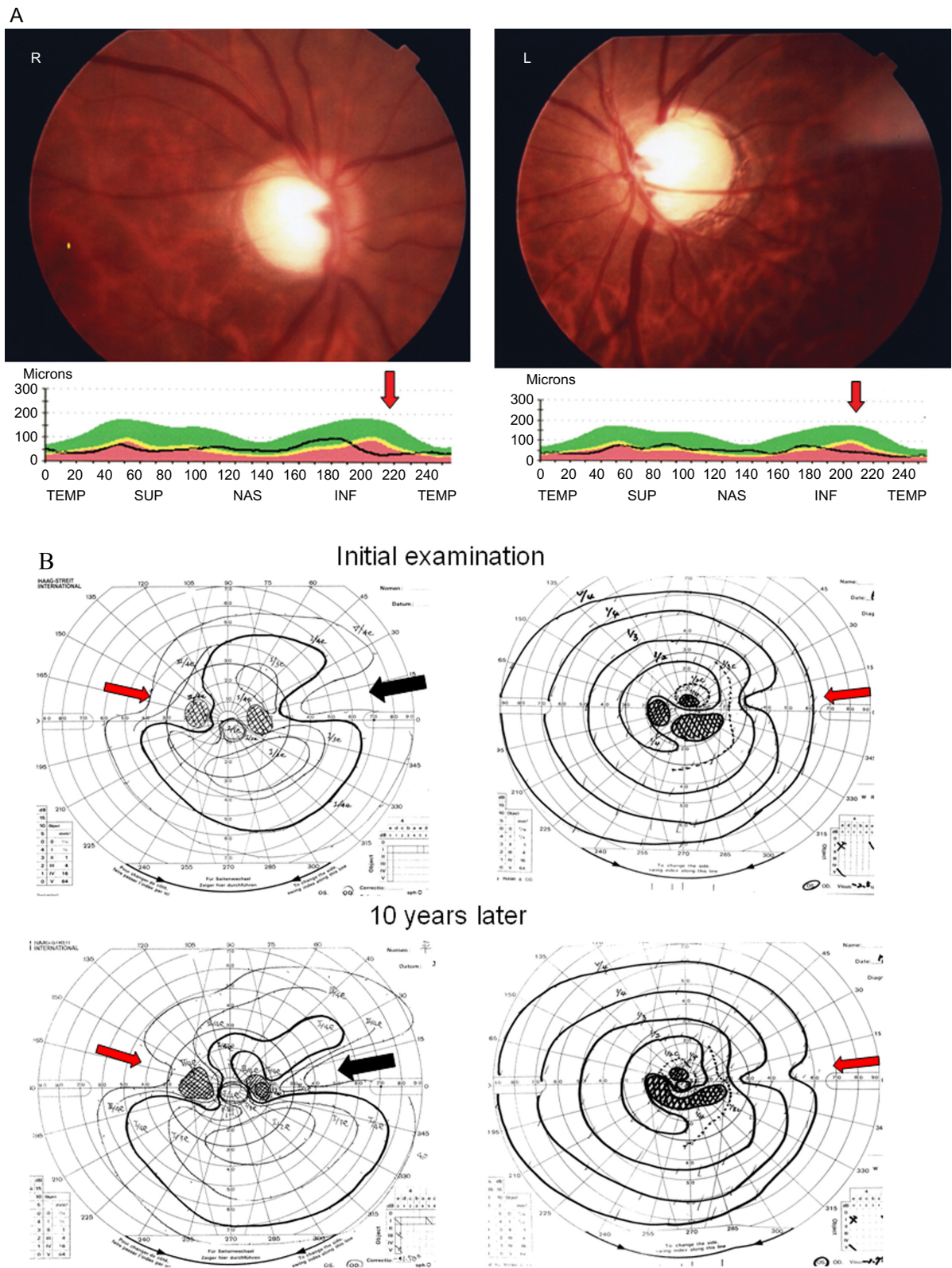
**Top:** Bilateral glaucomatous large disc cupping, double-ring appearance of nasal sector of the optic discs (OD, indicated by a blue arrow) and the presence of NFLD in the superotemporal, inferotemporal and nasal sectors of the peripapillary retina (indicated by black arrows) (OD) and the inferior sector (OS) were observed in the fundus photographs. **Middle:** A significant decrease of nasal NLFT (indicated by a black arrow) (OD) and inferotemporal NFLT (OS and OD, indicated by a red arrow) was evident in OCT analysis. **Bottom:** A wedge-shaped temporal VFD (OD, indicated by a black arrow) and glaucomatous VFDs (OD; nasal defect and isolated scotoma, OS; depression of the internal isopters, indicated by a red arrow) were detected by Goldman perimetry.

**Abbreviations:** NOH, nasal optic hypoplasia; NFLD, nerve fiber layer defect; NFLT, retinal nerve fiber thickness; NTG, normal tension glaucoma; OCT, optical coherence tomography; OD, right eye, OS, SSOH, superior segmental optic nerve hypoplasia; VFD, visual field defect.

associated with NOH, suggesting that there is a variety of anatomic defects in congenital optic disc hypoplasia, ranging from severe to minimal deficiency of optic nerve axons in several different sections of the optic disc area, as has been suggested by Frisen et al.<sup>20</sup>

Previous studies have shown that NLFT in glaucoma patients is significantly decreased compared with that in healthy subjects and in patients with ocular hypertension.<sup>21,22</sup> In addition, such glaucomatous changes in NFLT tend to affect the inferior and superior fibers first, because the corresponding NFLT is thicker than the nasal and temporal fibers (Inferior, Superior, Nasal, Temporal [ISNT] rule).<sup>23</sup> However, in contrast, NOH may be congenital or secondary to myopic stretching and, thus, affect mainly the nasal and

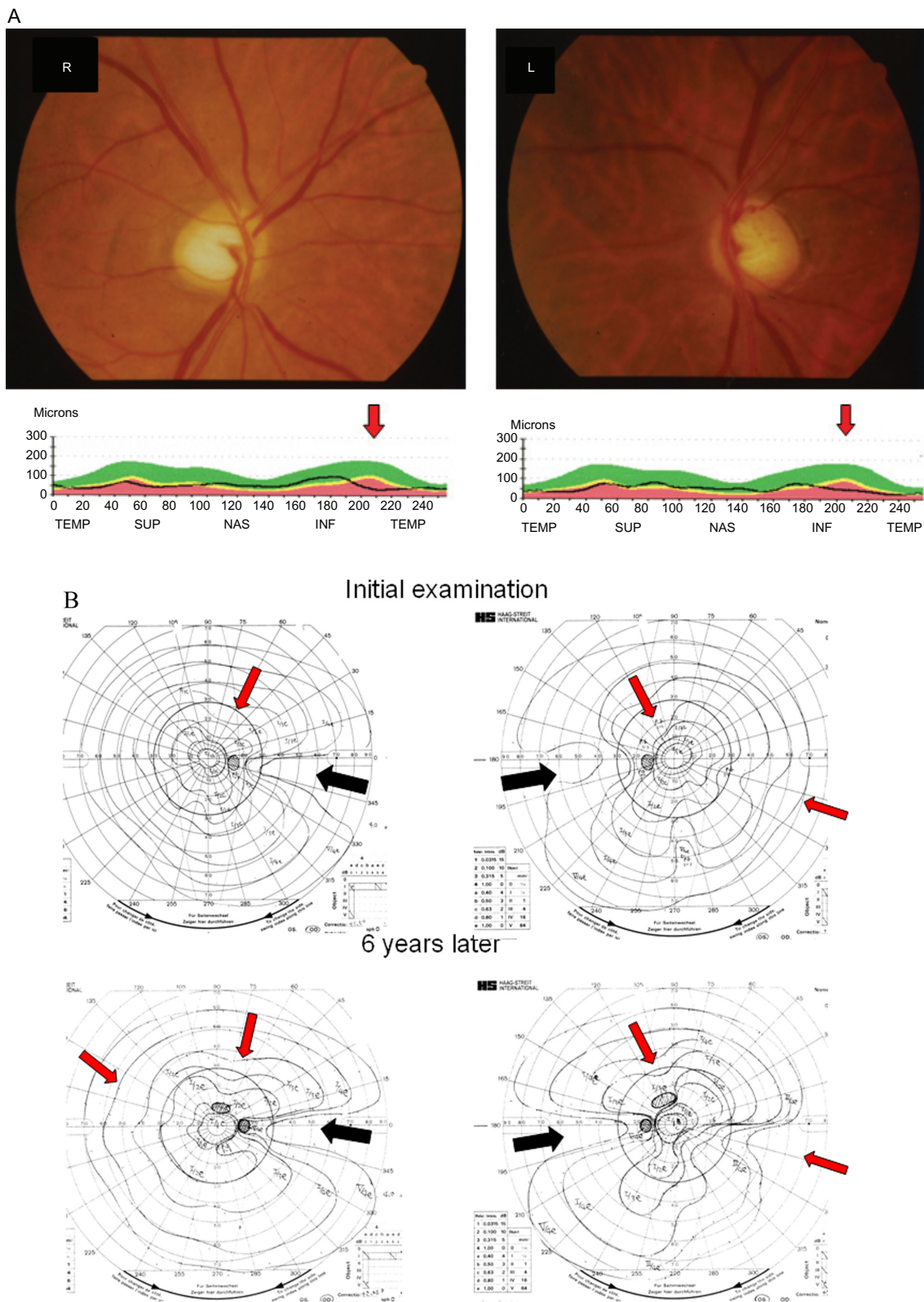
possibly temporal nerve fibers first. In our case series, using OCT, we also found that glaucoma patients with progressive, temporal, wedge-shaped visual field losses breaking out horizontally from the blind spot showed a decrease in NFLT in the nasal sector of the retina (mean 49 microns, 45–54 microns), which is comparable with the nasal quadrant NFLT in glaucoma patients reported by Zangwill et al (mean 39.2 microns, 30.6–47.7 microns).<sup>22</sup> However, in the present study, the severity of the NLFT thinning in the nasal sector of the glaucoma patients was much less than that in the NOH eyes (mean 29.8 microns, 14–45 microns). It was speculated that temporal VFDs may appear even with minimal damage to the nasal sector of the disc during progression of glaucoma because NFLT in the nasal sector is



**Figure 4** Clinical manifestations of a POAG case with unilateral NOH-like VFD (Patient 9).

**A)** Bilateral glaucomatous large cupping was observed in the fundus photographs (top). A significant decrease in inferotemporal NFLT (indicated by a red arrow) was detected through OCT analysis (bottom). **B)** A wedge-shaped temporal VFD (indicated by a black arrow, OD) and bilateral nasal defects with isolated scotomas (indicated by red arrows) were detected by Goldmann perimetry (top). During the 10-year follow-up, both the wedge-shaped temporal VFD (OD, indicated by a black arrow) and bilateral nasal visual field defects (indicated by red arrows) deteriorated (bottom).

**Abbreviations:** POAG, primary open angle glaucoma; NOH, nasal optic hypoplasia; NFLD, nerve fiber layer defect; NFLT, retinal nerve fiber thickness; OCT, optical coherence tomography; OD, right eye; OS, left eye; SSOH, superior segmental optic nerve hypoplasia; VFD, visual field defect.



**Figure 5** Clinical manifestations of a POAG case with bilateral NOH-like visual field defects (Patient 10).

**A)** Bilateral glaucomatous large cupping was observed in the fundus photographs (top). A significant decrease in inferotemporal NFLT (indicated by a red arrow) was detected through OCT analysis (bottom). **B)** Bilateral wedge-shaped temporal visual field defects (indicated by a black arrow) and depression of the internal isopters (indicated by red arrows), and nasal depression (OS, indicated by red arrows) were detected by Goldmann perimetry (top). During the six-year follow-up, both the bilateral wedge-shaped temporal VFDs (indicated by black arrows) and other visual field defects (indicated by red arrows) deteriorated (bottom).

**Abbreviations:** NOH, nasal optic hypoplasia; NFLD, nerve fiber layer defect; NFLT, retinal nerve fiber thickness; OCT, optical coherence tomography; OD, right eye; OS, left eye; SSOH, superior segmental optic nerve hypoplasia; VFD, visual field defect.



much thinner than that in the superior or inferior sector.<sup>8,21,22</sup> In contrast, congenital defects of the optic nerve fibers in the nasal sector of the optic disc may be more evident in the NOH eyes. If our speculation is correct, it is reasonable to conclude that distinct clinical manifestations between NOH and the glaucomatous change in the optic disc size and its appearance, severity of decrease in the nasal NFLT, and progression of the temporal VFD may help for their differential diagnosis. A large-scale prospective study is required to confirm this speculation.

In conclusion, specific changes in the optic disc appearance and correlation of these with the NFLT by OCT may help to distinguish NOH and glaucoma from NOH-like temporal VFD.

## Acknowledgments

We thank Dr Tadao Maeda, Department of Ophthalmology, Case Western Reserve University, for his critical comments on the manuscript.

## Disclosure

The authors indicate no financial support or financial conflict of interest.

## References

- Mosier MA, Lieberman MF, Green WR, Knox DL. Hypoplasia of the optic nerve. *Arch Ophthalmol*. 1978;96:1437–442.
- Zeki SM, Dutton GN. Optic nerve hypoplasia in children. *Br J Ophthalmol*. 1990;74:300–304.
- Mikelberg FS, Drance S. Glaucomatous visual field defects. In: Ritch R, Shields MB, Krupin T (editors). *The Glaucomas*. St Louis, MO: Mosby. 1996;523–537.
- Buchanan TAS, Hoyt WF. Temporal visual field defects associated with nasal hypoplasia of the optic disc. *Br J Ophthalmol*. 1981;65:636–640.
- Hashimoto M, Suzuki Y, Ohtsuka K. [A case of congenital chiasmal hypoplasia]. *Journal of the Eye*. 2002;19:249–251. Japanese.
- Matsumoto N, Hashimoto M, Konno S, Otsuka K. [Three cases of congenital nasal optic disc hypoplasia]. *Journal of the Eye*. 2005;22:1009–1012. Japanese.
- Awan KJ. Ganglionic neuroaplasia and hypoplasia of optic nerve. *Ann Ophthalmol*. 1976;8:1193–1202.
- Blumenthal EZ, Williams JM, Weinreb RN, Girkin CA, Berry CC, Zangwill LM. Reproducibility of nerve fiber layer thickness measurements by use of optical coherence tomography. *Ophthalmology*. 2000;107:2278–2282.
- Hart WM, Becker B. The onset and evolution of glaucomatous visual field defects. *Ophthalmology*. 1982;89:268–279.
- Skarf B, Hoyt CS. Association with anomalies of the endocrine and CNS. *Arch Ophthalmol*. 1984;102:62–67.
- Merien S, Harwood-Nash DC, Crawford JS. Axial tomography of optic canals in diagnosis of children's eye and optic nerve defects. *Am J Ophthalmol*. 1971;72:1122–1129.
- Zion V. Optic nerve hypoplasia. *Ophthalmic Sem*. 1976;1:171–196.
- Layman PR, Anderson DR, Flynn JT. Frequent occurrence of hypoplastic optic discs in patients with aniridia. *Am J Ophthalmol*. 1974;77:513–516.
- Brown GC. Optic nerve hypoplasia and colobomatous defects. *J Pediatr Ophthalmol Strabismus*. 1982;19:90–93.
- Denslow GT, Sims M. Duane's retraction syndrome associated with optic nerve hypoplasia. *J Pediatr Ophthalmol Strabismus*. 1980;17:26–28.
- Kim RY, Hoyt WF, Lessell S, Narahara MH. Superior segmental optic hypoplasia: A sign of maternal diabetes. *Arch Ophthalmol*. 1989;107:1312–1315.
- Landau K, Bajka JD, Kirschlarger BM. Topless optic discs in children of mothers with type 1 diabetes mellitus. *Am J Ophthalmol*. 1988;125:605–611.
- Unoki K, Ohba N, Hoyt WF. Optical coherent tomography of superior segmental optic hypoplasia. *Br J Ophthalmol*. 2002;86:910–914.
- Yamamoto T, Sato M, Iwase A. Superior segmental optic hypoplasia found in Tajimi eye health care project participants. *Jpn J Ophthalmol*. 2004;48:578–583.
- Frisen L, Holmegaard L. Spectrum of optic nerve hypoplasia. *Br J Ophthalmol*. 1978;62:7–15.
- Bowd C, Weinreb RN, Williams JM, Zangwill LM. The retinal nerve fiber layer thickness in ocular hypertensive, normal, glaucomatous eyes with optical coherence tomography. *Arch Ophthalmol*. 2000;118:22–26.
- Zangwill LM, Bowd C, Berry CC, et al. Discriminating between normal and glaucomatous eyes using the Heidelberg retinal tomography, GDx nerve fiber analyzer, and optical coherence tomography. *Arch Ophthalmol*. 2001;119:985–993.
- Jonas JB, Gusek GC, Naumann GOH. Optic disc, cup and neuroretinal rim size, configuration and correlations in normal eyes. *Invest Ophthalmol Vis Sci*. 1988;29:1151–1158.

### Clinical Ophthalmology

### Publish your work in this journal

Clinical Ophthalmology is an international, peer-reviewed journal covering all subspecialties within ophthalmology. Key topics include: Optometry; Visual science; Pharmacology and drug therapy in eye diseases; Basic Sciences; Primary and Secondary eye care; Patient Safety and Quality of Care Improvements. This journal is indexed on

Submit your manuscript here: <http://www.dovepress.com/clinical-ophthalmology-journal>

### Dovepress

PubMed Central and CAS, and is the official journal of The Society of Clinical Ophthalmology (SCO). The manuscript management system is completely online and includes a very quick and fair peer-review system, which is all easy to use. Visit <http://www.dovepress.com/testimonials.php> to read real quotes from published authors.