

# Kounis Syndrome Induced by Anisodamine: A Case Report

This article was published in the following Dove Press journal:  
*International Journal of General Medicine*

Haoyu Wu <sup>1</sup>  
Yiwei Cao<sup>2</sup>  
Fengjun Chang<sup>1</sup>  
Chunyan Zhang<sup>3</sup>  
Yanchao Hu<sup>3</sup>  
Lei Liang <sup>1</sup>

<sup>1</sup>Department of Cardiology, Shaanxi Provincial People's Hospital, Xi'an 710068, People's Republic of China;

<sup>2</sup>Department of Electrocardiology, Shaanxi Provincial People's Hospital, Xi'an 710068, People's Republic of China;

<sup>3</sup>Department of Cardiology, The Second Affiliated Hospital of Xi'an Jiaotong University, Xi'an 710004, People's Republic of China

**Abstract:** Kounis syndrome is a rare type of acute coronary syndrome caused by coronary spasm with or without atherosclerotic plaque erosion or rupture due to inflammatory factors released by allergic reactions. Due to a lack of awareness, Kounis syndrome is often underdiagnosed. Here, we for the first time report a case of Kounis syndrome induced by anisodamine. A 48-year-old woman presented with upper abdominal pain and vomiting after eating. She was diagnosed with gastrointestinal spasm and intramuscularly injected with 10 mg anisodamine. The patient subsequently developed chest pain and hypotension with erythematous rash. A systemic allergic reaction was diagnosed. Saline solution, promethazine and dexamethasone were administered immediately. A 12-lead electrocardiogram indicated ST-segment elevation in II, III and aVF leads. Emergent coronary angiography was recommended. According to a preoperative electrocardiogram, the ST-segment elevation in the II, III and aVF leads had disappeared. Coronary angiograph revealed no significant coronary stenosis. The patient was diagnosed with Kounis syndrome induced by anisodamine, showing acute ST-segment elevation myocardial infarction due to allergic coronary vasospasm. During the 9-month follow-up, the patient did not receive further anisodamine injections and remained free of chest pain. In conclusion, it is essential for clinicians to be aware of Kounis syndrome because of the wide range of triggers and its potentially fatal evolution if not identified in time.

**Keywords:** Kounis syndrome, allergic injury, coronary artery vasospasm, anisodamine

## Introduction

Kounis syndrome is defined as a hypersensitivity coronary disorder caused by the activation of mast cells.<sup>1</sup> It is a rare condition, and its reported incidence in emergency departments is 0.0194% of all admissions and 3.4% of allergy patient admissions.<sup>2,3</sup> The diagnosis of Kounis syndrome is mainly based on clinical manifestations. Due to a lack of awareness, Kounis syndrome is thought to be frequently missed or underdiagnosed. It is critical to identify Kounis syndrome because the treatment of Kounis syndrome is different from that of classic acute coronary syndrome.

Triggers of Kounis syndrome are increasingly being reported. Antibiotics (27.4%) and insect bites (23.4%) are the most common triggers.<sup>4</sup> Here, we report a case of Kounis syndrome induced by anisodamine showing ST-segment elevation myocardial infarction accompanied by erythematous pruritic rash.

## Case Report

A 48-year-old woman presented to the emergency department of our hospital with upper abdominal pain and vomiting after eating. She denied a history of diabetes,

Correspondence: Haoyu Wu  
Department of Cardiology, Shaanxi Provincial People's Hospital, No. 256 West Youyi Road, Xi'an 710068, People's Republic of China  
Tel +86-29-85251331-3201  
Fax +86-29-85236987  
Email wxs5132006@163.com

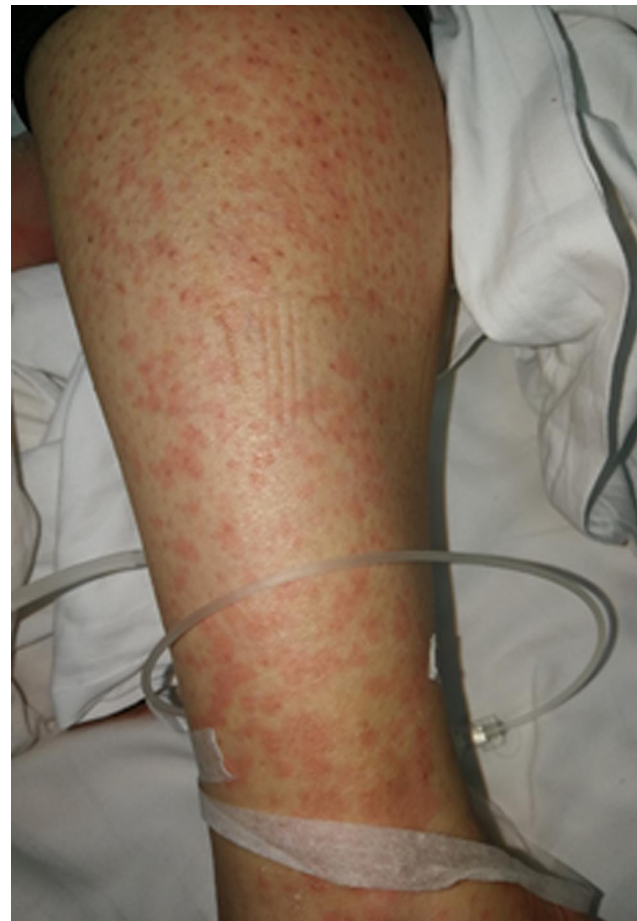hypertension and coronary heart disease. The patient's vital signs were as follows: blood pressure of 118/70 mm Hg, a regular pulse of 77 beats per minute, and a respiratory rate of 20 breaths per minute. Her facial expression indicated pain. The upper abdomen was tender, and there was no rebound pain. The patient was diagnosed with gastrointestinal spasm and intramuscularly injected with 10 mg anisodamine. The patient's abdominal pain was gradually relieved.

However, the patient developed chest pain with sweating 10 minutes after injection of anisodamine. The vital signs were as follows: blood pressure of 82/50 mm Hg, a regular pulse of 56 beats per minute, and a respiratory rate of 24 breaths per minute. The patient developed erythematous pruritic rash throughout the chest, abdomen and limbs (Figure 1). A systemic allergic reaction was diagnosed. Saline solution, promethazine (25 mg) and dexamethasone (10 mg) were administered immediately. A 12-lead electrocardiogram (ECG) was performed, and the results demonstrated ST-segment elevation in the II, III and aVF leads (0.5–0.7 mV) with ST-segment depression in I and aVL leads (0.2–0.4 mV) (Figure 2A). Suspected acute inferior wall myocardial infarction due to occlusion of the right coronary artery was also considered. The patient was treated with 300 mg aspirin and 180 mg ticagrelor for emergent coronary angiography. A preoperative ECG (49 minutes after the first ECG) demonstrated that the ST-segment elevation in the II, III and aVF leads had disappeared (Figure 2B). Coronary angiography showed no significant abnormalities (Figure 3). The immunoglobulin E level was 365 IU/mL (0–100). The peak troponin I level was 0.247 ng/mL (normal range <0.03, approximately 9 hours after chest pain). Echocardiography, chest X-ray and abdominal X-ray showed no obvious abnormality. The patient was diagnosed with Kounis syndrome induced by anisodamine, showing acute ST-segment elevation myocardial infarction due to allergic coronary vasospasm.

The patient was discharged without complications and advised to avoid the use of anisodamine. During the 9-month follow-up, the patient avoided anisodamine injection and remained free of chest pain.

## Discussion

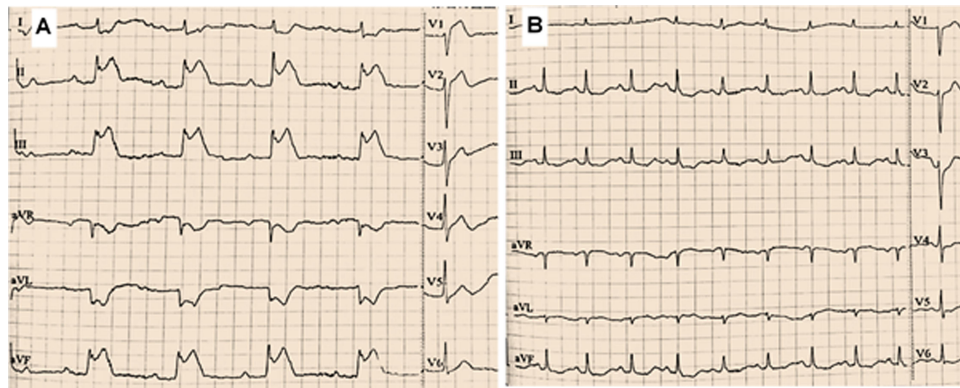
The patient in our case developed chest pain with erythematous rash after anisodamine injection. Based on 12-lead ECG, coronary angiography, immunoglobulin E and troponin I levels, the patient was diagnosed with Kounis syndrome induced by anisodamine. To the best of our



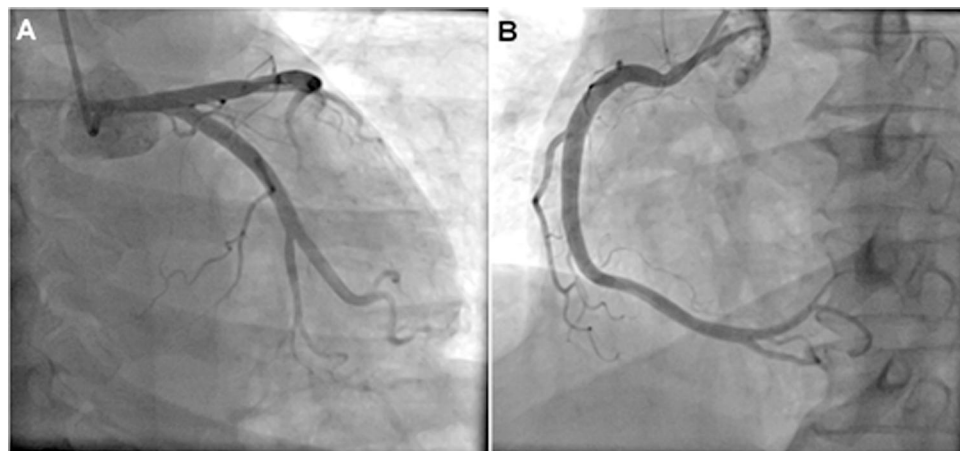
**Figure 1** Erythematous rash over the left lower limb.

knowledge, this is the first report of anisodamine as a trigger of Kounis syndrome.

Kounis syndrome is a rare type of acute coronary syndrome caused by coronary spasm with or without atherosclerotic plaque erosion or rupture due to inflammatory factors released by allergic reactions.<sup>1,5</sup> The exact mechanism is still unclear and may be related to the release of inflammatory factors after the direct activation of mast cells mediated by immunoglobulin E.<sup>6,7</sup> The current inflammatory factors believed to be involved include histamine, leukotrienes, prostaglandins, neutral protease, tryptase, arachidonic acid products, thrombin and platelet-activating factors.<sup>6</sup> Certain foods, drugs (non-steroidal anti-inflammatory drugs, dermatological drugs, and contrast media), latex, environmental exposure, and coronary stents may cause Kounis syndrome.<sup>8</sup> Anisodamine is a natural derivative of atropine; similar to atropine, anisodamine is a non-specific cholinergic antagonist and exhibits the usual spectrum of pharmacological effects of this drug class (including inhibition of respiratory secretion, gastrointestinal motility, gastrointestinal and



**Figure 2** Twelve-lead electrocardiogram results. **(A)** The first electrocardiogram indicating ST-segment elevation in the II, III and aVF leads (0.5–0.7 mV) with ST-segment depression in the I and aVL leads (0.2–0.4 mV). **(B)** The preoperative electrocardiogram (49 minutes after the first electrocardiogram) indicating ST-segment elevation in the II, III and aVF leads disappeared.



**Figure 3** Coronary angiogram revealing no significant stenosis. **(A)** Left coronary artery. **(B)** Right coronary artery.

sweat secretion, saliva secretion, and bladder contraction, among others). Anisodamine is often used for the treatment of gastrointestinal colic, gastric ulcer, septic shock, pulmonary insufficiency, organophosphorus poisoning and eclampsia.<sup>9</sup> In 2018, Castellano-Martinez et al<sup>10</sup> first reported that intravenous atropine might be a trigger of Kounis syndrome in a child, but the authors thought that diagnosis of Kounis syndrome caused by atropine was uncertain. Since then, there has been no report of atropine- or anisodamine-induced Kounis syndrome. Although Kounis syndrome can occur at any age, more than half of the affected patients are 40–70 years old.<sup>4</sup> The patient in our case was 48 years old, belonging to the most commonly affected age group.

The clinical characteristics of Kounis syndrome are acute myocardial ischemia (such as chest pain, palpitations, and dyspnea) and allergic reaction (such as erythematous rash, hives, and wheezing).<sup>11</sup> The diagnosis of Kounis

syndrome is mainly based on clinical manifestations. Laboratory tests (eosinophils, immunoglobulin E, and myocardial injury markers), ECG, echocardiography and coronary angiography support the diagnosis of this disease.<sup>4</sup> A careful review of the patient's clinical history, including drug and allergy history, is always essential for diagnosis. The utility of elevated immunoglobulin E levels in the diagnosis of Kounis syndrome is unclear, and normal immunoglobulin E levels cannot exclude the possibility of diagnosis.<sup>12</sup> The increase in myocardial injury markers seen in this disease indicates that allergic reactions cause the myocardial injury. ECG usually indicates ST-T changes. Echocardiography may indicate abnormal local wall motion in the distribution of the affected coronary artery. Coronary angiography may show coronary vasospasm or stenosis.

Kounis syndrome can be divided into three types according to coronary angiography results.<sup>1,13</sup> For type I (72.6% of patients), coronary angiography shows no

significant stenosis, and inflammatory factors lead to coronary artery spasm causing acute myocardial ischemia. For type II (22.3% of patients), patients have a history of coronary artery stenosis. Inflammatory factors cause coronary artery spasm together with atherosclerotic plaque erosion or rupture, leading to coronary artery occlusion. For type III (5.1% of patients), inflammatory factors cause stent thrombosis after coronary stenting, and aspiration of the thrombus is also recommended. The disease presented in this case was type I Kounis syndrome because the patient did not have coronary stenosis.

The treatment of Kounis syndrome is still challenging and lacks consensus. Most effective treatments are based on case reports.<sup>14</sup> The main goals are myocardial revascularization and the treatment of anaphylaxis. Corticosteroids and H1 and H2 antihistamines are commonly used to decrease the allergic reaction.<sup>15</sup> Patients with anaphylactic shock need appropriate fluid resuscitation. Vasodilators such as calcium channel blockers and nitrates can resolve the allergic vasospasms. In patients with types II and III Kounis syndrome, therapeutic management should also be based on the latest acute coronary syndrome guidelines.<sup>16</sup>

## Conclusion

In conclusion, anisodamine may be rarely associated with several cardiac adverse effects, including Kounis syndrome, as in our case. Kounis syndrome is a challenging and underdiagnosed disease that should be suspected in patients with angina-equivalent symptoms and systemic anaphylaxis. Keeping in mind and clinical suspicion of Kounis syndrome is beneficial for early diagnosis and appropriate treatment, which may affect the prognosis.

## Data Sharing Statement

The data that used to support this study are available on reasonable request from the corresponding author, Haoyu Wu.

## Consent for Publication and Ethics Approval

Written informed consent was obtained from the patient for her anonymized information to be published in this article. Our institution does not require ethical approval for reporting individual cases.

## Author Contributions

All authors made substantial contributions to conception and design, acquisition of data, or analysis and interpretation of

data; took part in drafting the article or revising it critically for important intellectual content; agreed to submit to the current journal; gave final approval of the version to be published; and agree to be accountable for all aspects of the work.

## Funding

This study was supported by the Natural Science Basic Research Program of Shaanxi Province (NO. 2020JQ-939), and the Science and Technology Development Incubation Fund Project of Shaanxi Provincial People's Hospital (NO. 2019YXQ-08). The funding bodies played a role in collection, and were not involved in data processing.

## Disclosure

The authors report no conflicts of interest in this work.

## References

1. Kounis NG. Kounis syndrome: an update on epidemiology, pathogenesis, diagnosis and therapeutic management. *Clin Chem Lab Med.* 2016;54(10):1545–1559. doi:10.1515/cclm-2016-0010
2. Li J, Zheng J, Zhou Y, Liu X, Peng W. Acute coronary syndrome secondary to allergic coronary vasospasm (Kounis Syndrome): a case series, follow-up and literature review. *BMC Cardiovasc Disord.* 2018;18(1):42. doi:10.1186/s12872-018-0781-9
3. Ralapanawa DM, Kularatne SA. Kounis syndrome secondary to amoxicillin/clavulanic acid administration: a case report and review of literature. *BMC Res Notes.* 2015;26:97. doi:10.1186/s13104-015-1072-5
4. Abdelghany M, Subedi R, Shah S, Kozman H. Kounis syndrome: a review article on epidemiology, diagnostic findings, management and complications of allergic acute coronary syndrome. *Int J Cardiol.* 2017;232:1–4. doi:10.1016/j.ijcard.2017.01.124
5. Kounis NG. Kounis syndrome (allergic angina and allergic myocardial infarction): a natural paradigm? *Int J Cardiol.* 2006;110(1):7–14. doi:10.1016/j.ijcard.2005.08.007
6. Soufras GD, Kounis GN, Kounis NG. Serum IgE antibody concentrations and the risk of Kounis syndrome. *Int J Cardiol.* 2013;168(2):1705–1706. doi:10.1016/j.ijcard.2013.03.052
7. Kounis NG, Koniari I, Tsigkas G, et al. Vasospastic coronary event following a single dose of amoxicillin in a patient with normal coronary arteries: Kounis syndrome and the myocardial infarction with normal coronary arteries conundrum. *Cardiovasc Diagn Ther.* 2019;9(1):110–111. doi:10.21037/cdt.2018.08.03
8. Akçay M, Yüksel S. Isotretinoin-associated possible Kounis syndrome: a case report and a review of other cardiovascular side effects reported in the literature. *Türk Kardiyol Dern Ars.* 2019;47(4):324–328. doi:10.5543/tkda.2018.67055
9. Poupko JM, Baskin SI, Moore E. The pharmacological properties of anisodamine. *J Appl Toxicol.* 2007;27(2):116–121. doi:10.1002/jat.1154
10. Castellano-Martinez A, Rodriguez-Gonzalez M. Coronary artery spasm due to intravenous atropine infusion in a child: possible Kounis syndrome. *Cardiol Young.* 2018;28(4):616–618. doi:10.1017/S1047951117002785

11. Kounis NG, Mazarakis A, Tsigkas G, Giannopoulos S, Goudevenos J. Kounis syndrome: a new twist on an old disease. *Future Cardiol*. 2011;7(6):805–824. doi:10.2217/fca.11.63
12. Biteker M, Duran NE, Biteker FS, et al. Allergic myocardial infarction in childhood: Kounis syndrome. *Eur J Pediatr*. 2010;169(1):27–29. doi:10.1007/s00431-009-0965-5
13. Biteker M. Current understanding of Kounis syndrome. *Expert Rev Clin Immunol*. 2010;6(5):777–788. doi:10.1586/eci.10.47
14. Mitsis A, Christodoulou E, Georgiou P. Coronary spasm secondary to cefuroxime injection, complicated with cardiogenic shock - a manifestation of Kounis syndrome: case report and literature review. *Eur Heart J Acute Cardiovasc Care*. 2018;7(7):624–630. doi:10.1177/2048872617701885
15. Sciatti E, Vizzardi E, Cani DS, et al. Kounis syndrome, a disease to know: case report and review of the literature. *Monaldi Arch Chest Dis*. 2018;88(1):898. doi:10.4081/monaldi.2018.898
16. Baroni M, Todd S, Pattarino F, Doni F. Carboplatin-induced Kounis syndrome. *J Cardiol Cases*. 2011;4(1):e58–e61. doi:10.1016/j.jccase.2011.04.004

International Journal of General Medicine

Dovepress

### Publish your work in this journal

The International Journal of General Medicine is an international, peer-reviewed open-access journal that focuses on general and internal medicine, pathogenesis, epidemiology, diagnosis, monitoring and treatment protocols. The journal is characterized by the rapid reporting of reviews, original research and clinical studies

across all disease areas. The manuscript management system is completely online and includes a very quick and fair peer-review system, which is all easy to use. Visit <http://www.dovepress.com/testimonials.php> to read real quotes from published authors.

Submit your manuscript here: <https://www.dovepress.com/international-journal-of-general-medicine-journal>