

Analysis of Factors Related to Distal Proximal Caries on the Distal Surface of the Mandibular Second Molar Induced by an Impacted Mandibular Third Molar

Xiang Jin
Xiang-Zi Zhang
Cheng-Ri Jin
Yun-Ze Xuan

Department of Dentistry, Affiliated
Hospital of Yanbian University, Yanji, Jilin,
133000, People's Republic of China

Objective: To analyze the factors related to distal proximal caries of the mandibular second molar (MSM) induced by an impacted mandibular third molar (MTM).

Methods: A total 500 panoramic radiographs of patients with impacted MTMs who were treated in the Department of Stomatology of the Affiliated Hospital of Yanbian University between October 2017 and October 2019 were selected. Descriptive and bivariate analyses were conducted, and the diagnosis of caries in the MSM and the position of the MTM were evaluated.

Results: The posterior margin space of the MSM was larger in males (13.5 mm) than females (11.1 mm, $P < 0.001$) and correlated with the MTM's impacted depth and eruption degree ($P < 0.001$). The prevalence of distal proximal caries of the MSM was 37.6%, and a χ^2 test showed that age, impacted depth, impacted direction, impacted angle, degree of occurrence, and CEJ distance were correlated with caries in the distal adjacent surface of the MSM ($P < 0.001$). Logistic multivariate analysis showed that the impacted depth was at position A or B, the impacted direction was mesioangular, and the impacted angle was $<80^\circ$. Distal adjacent caries of MSMs were prone to occur when entirely or partially emergent. CEJ distance was not an independent factor for caries. The severity of caries in an MSM's distal adjacent surface had statistical significance on the impacted depth and impacted angle ($P < 0.001$).

Conclusion: The posterior margin space of the MSM influences the impacted condition of the MTM. Preventive extraction can be considered if the impacted angle is $<80^\circ$, especially in the case of a fully or partially emergent MTM at position A or B and mesioangular impacted areas.

Keywords: mandibular third molar, dental caries, mandibular second molar, related factors

Introduction

The mandibular third molar (MTM), located at the back end of the dentition, is the most frequently impacted tooth.¹ Tooth impaction is mainly related to the following factors: inadequate space, enlarged crown size, limitation in skeletal growth, and late third molar maturation.² Even though impacted third molars could exist permanently without any symptoms, they could also lead to various pathologies and thereby symptoms, such as swelling, loss of bone, pain, pericoronitis, resorption of the roots of adjacent teeth, distal caries, and odontogenic tumors and cysts.²⁻⁴ Of these complications, distal caries is the most common.⁵ Due to the abnormal location of a protruded or non-protruded MTM, it can impact food intake and the retention of plaque between the

Correspondence: Yun-Ze Xuan
Department of Dentistry, Affiliated
Hospital of Yanbian University, No. 1327
of Juzi Street, Yanji, Jilin, 133000, People's
Republic of China
Tel +86 15526770621
Email xuanyunze_dr06@163.com



mandibular second molar (MSM), leading to caries in the MSM.³ Clinically, an impacted MTM makes it difficult to detect distal caries of the MSM by visual examination. In more severe cases, pulpitis and periodontal diseases have even appeared. Therefore, X-rays are also used for diagnosis. Previous studies have found that the rate of dental caries in the MSM caused by MTM inhibition ranged from 1% to 47%; this range was so wide due to differences in the studied regions, the ages of selected populations, oral hygiene habits, and research methods.⁶⁻⁸

To decide whether a MTM should be removed is likely among the most commonly encountered treatment dilemmas in the dental profession.^{1,2} The purpose of exploring the risk factors of MTM is to provide a reference for its clinical management. A symptomatic MTM should be removed in a timely manner, but determining preventive extraction of an asymptomatic MTM has always been controversial. At present, there are few studies in China of the correlation between an impacted MTM and MSM distal caries, or the clinical symptoms were evaluated only by comparing the status of eruption, and there is not enough evidence to support guidance for the preventive extraction of an impacted MTM.⁹ In addition, the research methods, regions, ethnicities, economies, and cultures studied by various research institutes are different, leading to highly differing results across studies. This highlights the necessity of comprehensive studying the factors that influence an impacted MTM and its relation to MSM caries.

Materials and Methods

Clinical Data

Between October 2017 and October 2019, 500 panoramic radiographs that met the inclusion and exclusion criteria of the study were selected from the patients admitted to the Department of Stomatology of the Affiliated Hospital of Yanbian University. All panoramic radiographs were required to fully show the relationship between MTM and adjacent MSM. This study was conducted in accordance with the declaration of Helsinki and approved by the Ethics Committee of Affiliated Hospital of Yanbian University. Informed consent was obtained from all participants.

Inclusion criteria:^{9,10} (1) age 17 and above; (2) good oral hygiene; (3) at least one molar dentition area was complete; (4) the panoramic radiographs were straightforward and fully showed the emergence state of the MTM

on the study side and the position relationship between the MTM and the adjacent MSM.

Exclusion criteria:⁹ (1) imaging findings of root absorption and apical lesions in the adjacent MSM; (2) transmission images of caries in the adjacent MSM distal occlusal surface; (3) prostheses and bands in the adjacent MSM; (4) the oblique MSM was caused by missing teeth in the posterior area; (5) inverted and buccal tongue tilt were observed according to the Winter classification.^{2,11}

When a patient's left and right MTMs met the inclusion criteria, one MTM was randomly selected for inclusion. After applying the inclusion and exclusion criteria, 188 images of patients with distal adjacent MSM caries caused by MTM obstruction were identified. Of these, 126 were male and 62 were female, with ages ranging from 17 to 63 and an average age of 33.18 ± 12.26 . The group included 72 Korean patients and 116 Han patients.

Panoramic Radiography Observation

The dental digital panoramic radiography (digital X-ray imaging system; Wai Tai Manufacturing Co.) was set at 220 volts, with a section thickness of 1.0 mm. All images were displayed on a 19-inch LCD screen with a resolution of 1440 by 900 pixels and viewed in a darkened room.

Diagnostic Criteria of Distal Caries in the Adjacent MSM

All images were evaluated by an observer with experience in oral and maxillofacial imaging. When the enamel or dentin surface of the adjacent MSM's distal surface showed radiography, a diagnosis of caries was made (see Figure 1). None of the radiographs indicated an absence of caries.

Determination of the Severity of Remote Caries in the Adjacent MSM

All images were passed through the International Caries Detection and Assessment System (ICDAS)¹² and the International Caries Classification and Management System (ICCMS™)¹³ by a physician with experience in oral and maxillofacial imaging diagnosis. The ICCMS™ was modified and adjusted for the evaluation of radiological classification studies in this study.

Based on the imaging findings, the caries were divided into three groups: (1) mild caries, in which the area of caries was less than half of the dentin thickness; (2) moderate caries, in which the area of caries was more than half of the dentin thickness and the pulp cavity was

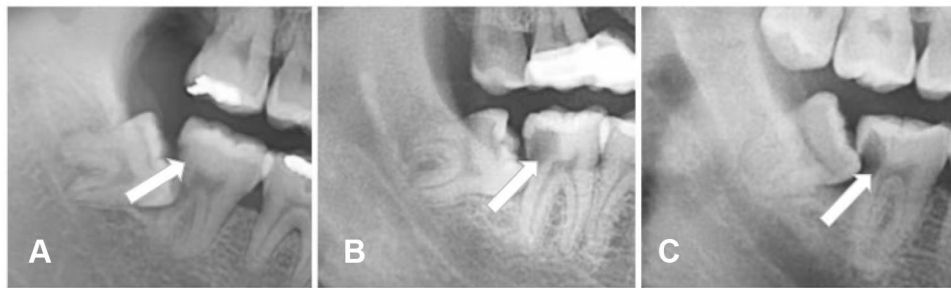


Figure 1 Distal adjacent caries of MSM (white arrow). (A) Mild caries. (B) Moderate caries. (C) Severe caries.

intact; (3) severe caries, which involved the pulp cavity and symptoms of pulpitis (see Figure 1A–C).

Determination of the Degree of MTM Eruption

Based on oral clinical examination, the degree of MTM eruption was divided into three groups: (1) complete eruption, in which the dental crown was fully exposed in the mouth; (2) partial eruption, in which the dental crown was partially exposed in the mouth; (3) no eruption, in which the dental crown was not exposed in the mouth.

Measurement Methods

Measurement of the MSM's Trailing Edge Clearance

The distance between the leading edge of the mandibular ramus and the trailing edge of the MSM crown was measured according to the Yilmaz method² by using the ranging function of EasyDent4 Viewer software most suitable for the panoramic radiographs. The average value of three measurements was accurate to 0.1 mm (see Figure 2).

Classification of the Impacted MTM

The classification of the impacted MTM was based on the Pell–Gregory¹⁴ and Winter classification systems.^{2,11} The Pell–Gregory system classifies the position of the

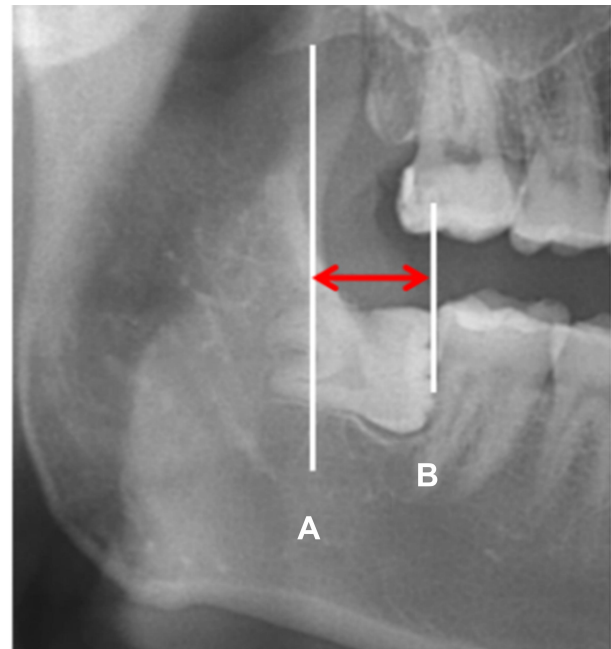


Figure 2 MSM trailing edge gap (red double arrow). (A): anterior edge line of mandibular ramus; (B): MSM trailing edge line.

impacted MTM according to the depth of the MTM in the jaw (see Figure 3).

The Winter system classifies the impacted MTM based on the angle formed by the long axis of the MTM and the long axis of the MSM (see Figure 4).

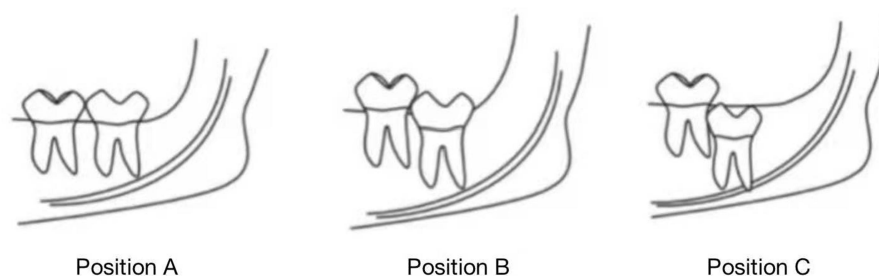


Figure 3 Pell-Gregory classification. Position (A) the apex of the crown is flat with, or above, the occlusal plane; position (B) the apex of the crown is below the occlusal plane but above the cervical margin of the second molar; position (C) the crown's apex is below the cervical margin of the second molar.

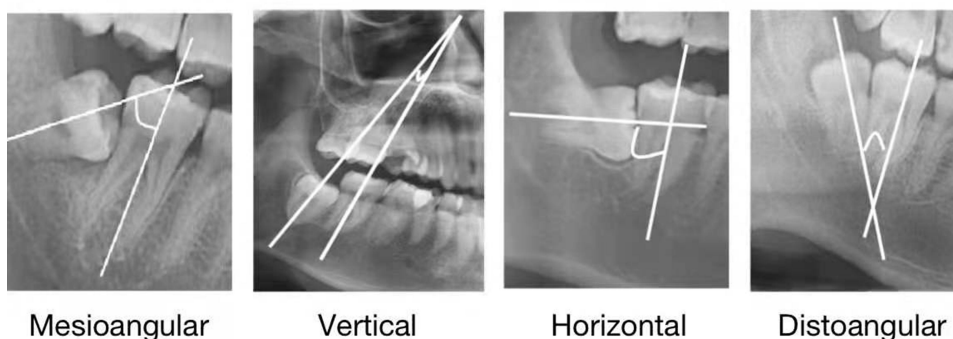


Figure 4 Winter classification. Mesioangular: 11° to 79°; Vertical: -10° to 10°; Horizontal: 80° to 100°; Distoangular: -11° to -79°.

The angle-measurement function of EasyDent4 Viewer software supporting the panoramic radiography was used to measure the angle formed by the MTM long axis and the MSM long axis on the coronal plane, and the average value of three measurements was accurate to 1°.

Measurement of the Angle of the Impacted MTM

The angle-measurement function of EasyDent4 Viewer was used to measure the angle of the impacted MTM on the coronal plane. The impacted angle was then used to measure the intersection angle of the MTM occlusion plane and the MSM occlusion plane based on the Shiller system.¹⁵ The average value of three measurements was accurate to 1°, and the impacted angles were classified into three groups (see Figure 5).

Measurement of the CEJ Distance Between the MTM and MSM

The CEJ distance between the MTM and MSM was measured on the coronal plane using the ranging function of Easy Dent4 Viewer. The distance between the MTM mesial surface CEJ and the MSM distal surface CEJ was measured according to the Leone method,¹⁶ and the average value of three measurements was accurate to 1 mm. The CEJ distances

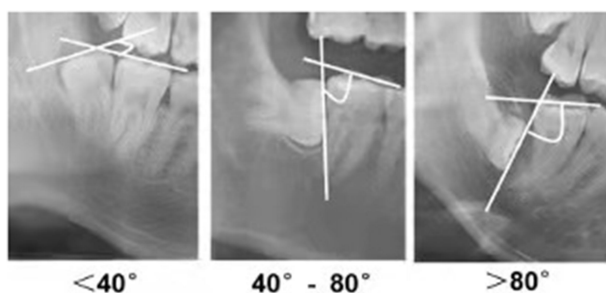


Figure 5 Measurements of the impacted angle. The impacted angles were classified into three groups: <40°, 40° to 80° and >80°.

were classified into five groups: (1) 1–3 mm; (2) 4–6 mm; (3) 7–9 mm; (4) 10–12 mm; (5) >12 mm (see Figure 6).

Statistical Analysis

SPSS 26.0 software was used for statistical analysis. Countable data were tested using a χ^2 test. MSM trailing edge gap data were expressed as mean \pm standard deviation. An independent sample *t*-test was used for comparison between the two groups, and one-way analysis of variance (ANOVA) was used to compare the differences between the groups. The LSD method was used for comparison between groups. The factors with statistical

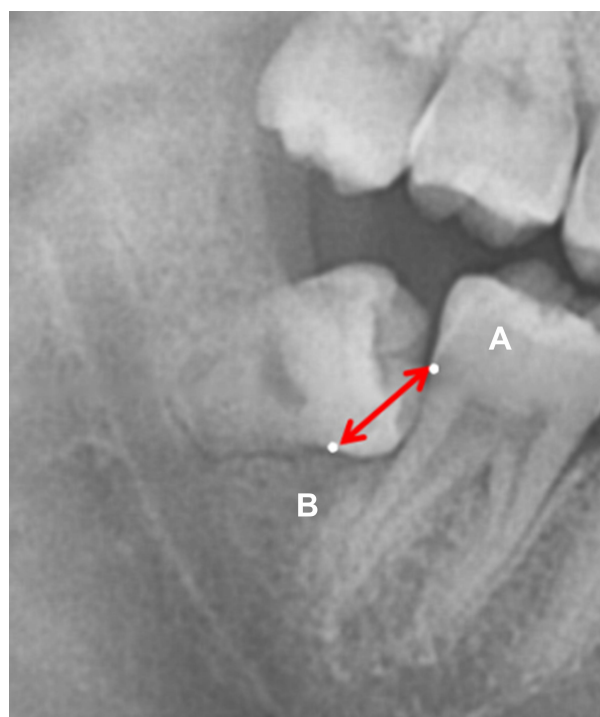


Figure 6 CEJ distance (red arrow). (A): MSM distal surface CEJ. (B): MTM mesial surface CEJ.

significance in the univariate analysis were included in the binary logistic regression model, with $P < 0.05$ being considered statistically significant. A rank-sum test was used to compare the degree of caries in each group.

Results

The MSM Trailing Edge Gap

The trailing edge gap of the MSM was found to be larger in male patients (13.5 mm) than in female patients (11.1mm), and the difference was statistically significant ($P < 0.001$; see Table 1). The MSM trailing edge gap affected the impacted depth and degree of the eruption of the MTM: as the MSM trailing edge gap increased, the impacted depth gradually decreased ($P < 0.001$; see Table 1) and the degree of eruption gradually increased ($P < 0.001$; see Table 1). Although there were statistical differences between all subgroups (all $P < 0.001$) in the impacted depth and degree of eruption, there were no significant differences in impact direction ($P = 0.071$ see Table 1).

The Relationship Between Rate of Caries and Variants in the Remote Adjacent Surface of the MSM

In the 500 cases studied, 188 were found to have MSM distal caries disease, and the rate of caries was 37.6%. A χ^2

test showed that age, depth, direction, angle, appear degree, and CEJ distance were far greater among MSM in the happening of the adjacent surface caries was statistically significant (all $P < 0.001$; see Table 2); differences in gender and ethnicity, however, showed no statistical significance ($P > 0.05$; see Table 2). The single-factor analysis showed that patients over the age of 30 with an impacted mesioangular MTM at position B, with an impacted angle of 40–80°, partial eruption, and CEJ distance of 4–6mm were at higher risk of caries.

Multivariate Logistic Regression Analysis of the Influencing Factors of Distal Caries Adjacent to the MSM

The factors with statistical significance in the univariate analysis were included in the binary logistic regression model. Age, depth, direction, angle, appearance degree, and CEJ distance were used as covariables in the binary logistic regression analysis to determine the independent factors affecting caries. The results showed that age, depth, direction, angle, and appearance degree were independent influencing factors for the occurrence of dental caries when other variables remained unchanged.

The risk of caries of those aged 31–63 was found to be 1.82 times that of those aged 17–30 ($P = 0.0011$; see Table 3). The risk of caries was 5.99 times higher when the depth was at position B than position C ($P < 0.001$) and 4.00 times higher when the depth was at position A than position C ($P = 0.003$) (see Table 3). The risk of caries was also found to be 3.58 times that of vertically impacted caries ($P = 0.004$; see Table 3). The risk of caries was 4.44 times and 9.19 times higher when the angle was less than 40° and 40–80°, respectively, compared with an angle of >80° ($P < 0.001$, $P < 0.001$; see Table 3). The risk of caries with partial eruption and complete eruption, respectively, was 1.91 times and 4.16 times that with no eruption ($P = 0.048$, $P < 0.001$; see Table 3). CEJ distance was not an independent influencing factor for caries.

The Degree of Caries in Each Group

The degree of caries in patients aged 17–30 was lower than that of those aged 31–63 ($P = 0.001$; see Table 4). Different caries damage degree of depth ($P = 0.01$; see Table 4), and the degree of caries at position C caries was found to be less than those at position B ($P = 0.003$); there were no significant differences, however, between degree of caries at position A, position B, and position C ($P = 0.135$, $P = 0.259$), and

Table 1 Comparison of Trailing Edge Gaps in Each Group

Variate	Trailing Edge Clearance (mm)	Statistical Magnitude	P
Gender		15.573	<0.001
Male	13.5±1.07		
Female	11.1±1.93		
Depth		313.392	<0.001
Position C	10.7±1.44		
Position B	12.0±1.70		
Position A	14.1±0.68		
direction		2.399	0.071
Mesioangular	12.6±1.83		
Vertical	13.2±1.62		
Horizontal	12.6±1.82		
Distoangular	12.6±2.24		
Appearance degree		60.035	<0.001
Unerupted	11.7±2.04		
Partial eruption	12.8±1.68		
Completely eruption	13.9±1.05		

Table 2 Relationship Between Caries Rate and Variables in the Remote and Adjacent Surfaces of MSM

Variate		Cases	Risk of Caries Cases	Risk of Caries Rate (%)	χ^2	P
Gender	Male	317	126	39.7	1.703	0.192
	Female	183	62	33.9		
Age	17–30	264	68	25.8	33.433	<0.001
	31–63	236	120	50.8		
Nationality	Han	282	116	41.1	3.444	0.063
	The Korean nationality	218	72	33		
Depth	Position A	206	24	11.8	157.561	<0.001
	Position B	220	150	68.2		
	Position C	77	14	18.2		
Direction	Mesioangular	298	146	49	45.196	<0.001
	Vertical	59	8	13.6		
	Horizontal	100	28	28		
	Distoangular	43	6	14		
Angle	<40°	181	57	31.5	49.224	<0.001
	40°–80°	195	99	50.8		
	>80°	124	32	25.8		
Appearance degree	Unerupted	143	34	23.8	17.158	<0.001
	Partial eruption	277	123	44.4		
	Completely eruption	80	31	38.8		
CEJ distance	1–3mm	127	20	15.7	69.976	<0.001
	4–6mm	234	132	56.4		
	7–9mm	114	28	24.6		
	10–12mm	17	6	35.3		
	>12mm	8	2	25		

differences in direction were also found to have no statistical significance ($P=0.292$; see Table 4). Differences in impacted angle were found to be statistically significant ($P<0.001$; see Table 1): patients with an impacted angle of 40–80° had a greater degree of caries than those with an angle of < 40° and > 80° ($P<0.001$, $P<0.001$ L; see Table 4). There was no statistically significant difference, however, in the degree of caries between patients with an angle of < 40° and those with an angle of >80° ($P=0.665$).

Discussion

The formation of distal caries in the MSM is a long-term process and represents a major complication related to an impacted MTM;^{17–19} further, the impacted condition of the MTM is often affected by the posterior margin space of the MSM.² The present study found that the MSM trailing edge gap was correlated with the impacted depth and degree of eruption: when the MSM following edge gap was less than 13.5 mm in male patients and 11.1 mm in female patients,

MTM eruption was affected; these findings were similar to those of Yilmaz et al.² The incidence of caries on the distal surface of the MSM has also been found to increase due to the complex and varied anatomical structure of the MTM and the lack of trailing edge space, as well as the unique environmental factors between the MTM and the adjacent distal surface of the MSM. The present study found that the incidence of caries on the remote adjacent surface of the MSM caused by MTM inhibition was 37.6%. Previous studies have found that the incidence of caries in the MSM's distal surface adjacent to the MTM is between 7% and 32%,^{6,18,20,21} which is similar to the findings of the present study. Kang et al,⁹ however, used cone-beam computed tomography (CBCT) to diagnose caries, finding that the rate of caries on the MSM's distal adjacent surface caused by an impacted MTM was as high as 52%. This suggests that CBCT has greater sensitivity and accuracy than X-rays in the diagnosis of distal adjacent caries in the MSM. In the present study, the incidence of caries may have been lower than the true number, possibly caused by the fact that some

Table 3 Multivariate Logistic Regression Analysis of the Influencing Factors of Caries in the Remote Adjacent Surface of MSM

Variate		OR	95% C.I.		P
			Lower	Upper	
Age	17–30	1.82	1.15	3.08	0.011
	31–63				
Depth	Position C	5.99	2.66	13.51	<0.001
	Position B	4.00	1.62	10.00	0.003
	Position A				
Direction	Vertical	3.58	1.23	10.41	0.019
	Mesioangular	0.75	0.19	2.98	0.682
	Distoangular	2.14	0.68	6.73	0.194
Angle	>80°	4.44	2.25	8.74	<0.001
	<40°				
	40°–80°	7.19	3.76	13.77	<0.001
Appearance degree	Unerupted	1.91	1.01	3.62	0.048
	Partial eruption				
	Completely eruption	4.16	1.74	9.96	0.001
CEJ		1.07	0.97	1.17	0.177

Table 4 Comparison of Caries Between Groups

Variate	Risk of Caries Cases	Mean Rank	Z	P
Age	17–30	68	-3.294	0.001
	31–63	120		
Depth	Position C	14	9.214	0.01
	Position B	150		
	Position A	24		
Direction	Mesioangular	146	3.724	0.292
	Vertical	8		
	Horizontal	28		
	Distoangular	6		
Angle	<40°	57	-6.172	<0.001
	40°–80°	99		
	>80°	32		

surface caries are not easily identified in panoramic radiography.

The longer the MTM is exposed in the oral environment, the higher the development and severity of the MSM's distal adjacent caries.²² Therefore, age may be

a factor to be considered in the preventive extraction of the MTM. The present study found that patients over the age of 30 had a higher rate of caries in the distal adjacent surface of the MSM (up to 50.8%), which is similar to the results of Chang et al.²⁰ To prevent remote adjacent dental caries in the MSM and promote long-term oral health, early removal of an obstructed or emergent MTM found before the age of 30 should be considered.

The present study also analyzed the correlation between gender and the occurrence of distal caries of the adjacent MSM caused by an impacted MTM, with no statistical difference found. Falci et al,¹⁸ however, found that distal adjacent caries of the MSM were more common in male patients, which may be related to the fact that women pay more attention to oral health care. However, the present study did not evaluate gender differences in oral health care, and there are no relevant previous studies.

Previous studies have shown that the impaction rate of the MTM differs across regions and ethnicities,²³ leading to differences in the incidence of caries on the remote and adjacent surfaces of the MSM. The subjects in the present study were from two ethnic groups: Korean and Han. Considering the differences in their diet and lifestyle, the two different ethnicities were compared in relation to the occurrence of caries in the distal adjacent surface of the MSM caused by an impacted MTM. No statistically significant difference was found.

The occurrence of an impacted MTM is directly related to the occurrence of caries in the remote adjacent surface of the MSM. In the present study, the influence of impacted depth on caries in the adjacent MSM's distal surface was analyzed. The results showed that the rate of caries in the distal adjacent surface of the MSM was highest under the median impacted condition, which differs from the findings of Chang et al,²⁰ who found that the rate of caries was higher when the impacted MTM was at a high level. This may be because the population of the present study had a wide age range: as a patient's age increases, the impacted MTM at position A, which are more easily removed, either fall out or are removed, which may cause a decrease in the number of impacted MTMs at position A.

Falci et al¹⁸ and Nunn et al²⁴ suggested that the occurrence of caries is significantly correlated with the presence of a proximally impacted MTM, while the effect of vertically, distoangularly, or other types of impacted teeth was not significant. The present study found that a mesioangular impacted MTM led to a rate of distal adjacent caries of 59.6%. Multivariate logistic regression analysis in this group showed that an impacted angle of 0–

80° was a risk factor for caries on the MSM's distal surface. When the impacted angle was 40–80°, caries were also more likely to occur in the distal surface of the MSM, which is similar to the findings of McArdle et al²² and Chang et al.²⁰ The present study also found that the incidence of caries in the MSM was correlated with MTM eruption: MTM partial eruption occurred when the rate of caries in the MSM was highest (44.4%). This may be because the MTM forms a gap with the MSM, resulting in higher food impaction, which is not conducive to cleaning, and the occurrence of caries in the far adjacent MSM surface.

Chang et al²⁰ believed that the possibility of caries on the MSM's distal surface was higher when the CEJ distance between the MTM and MSM was 7–9 mm. Falci et al¹⁸ reported similar results (CEJ distance 3–10 mm). In the present study, CEJ distance was statistically significant in the univariate analysis, indicating that it is a factor affecting the occurrence of caries on the MSM's distal surface, similar to the findings of the previous research. Kang et al⁹ also found a linear correlation between MTM impacted angle and CEJ distance. As such, the present study carried over age, impacted depth, impacted direction, impacted angle, appearance degree, and CEJ distance into logistic multivariate analysis and found that CEJ distance was not an independent influencing factor for caries. This suggests that depth, direction, angle, and degree of eruption should be considered more than CEJ distance when determining clinical protocol. In clinical practice, caries mainly affect the crown, including the enamel and dentin layers, while the impacted MTMs in the present study caused distal caries of the MSM and were prone to root caries.

In the present study, the imaging examination criteria of ICDAS¹² and ICCMS^{TM13} were modified, and the severity of caries was classified into mild, moderate, and severe based on the imaging results. The severity of caries in patients aged 30–63 was higher than in patients aged 17–30 and differed across different impacted depths. The severity of caries in mildly impacted caries was found to be lower than in the moderately impacted caries. The severity of caries in the far and middle surface of the MSM was also found to increase when the impacted angle of the MTM was 40–80°. Since the treatment and prognosis of MSM distal caries depends on the severity of the lesion, the results of the present study provide a reference for the factors related to the severity of distal caries in the MSM and the treatment plan for the MTM.

The diagnosis of caries in the present study was based on a projection on the distal surface of the MSM on curved

sectional film. If early caries diagnosis cannot be confirmed by panoramic radiography, an auxiliary periapical film should be taken for diagnosis. In clinical work, panoramic radiography is the most commonly used imaging method for the observation of impacted teeth. Compared with periapical film, panoramic radiography is easily operated and offers a more comprehensive imaging range and stable imaging quality. Compared to CBCT, panoramic radiography also costs less, has less radiation, and is more acceptable to patients. Therefore, the diagnosis of MSM distal caries by panoramic radiography has been widely used in previous studies.^{2,14} However, the resolution of a panoramic radiograph is not as high as that of periapical film or CBCT, which may result in a missed diagnosis of early distal caries in the MSM.

Conclusion

MTM eruption is relatively complex, and the age, depth, direction, angle, and appearance degree are influencing factors for distal caries of the MSM caused by the MTM. To reduce the complications and pain caused by an impacted MTM and maintain long-term oral health, early removal of the MTM can be considered. However, when a patient is older, the impacted MTM position is low, and the root tip is near the inferior alveolar neural tube, the advantages and disadvantages should be comprehensively considered. Whether this consideration results in the retention or preventive extraction of the MTM, the ultimate purpose of choosing the most appropriate treatment plan is to improve the patient's overall quality of life.

Disclosure

The authors declare that there are no conflicts of interest.

References

1. Claudia A, Barbu HM, Adi L, et al. Relationship between third mandibular molar angulation and distal cervical caries in the second molar. *J Craniofac Surg*. 2018;29(8):2267–2271. doi:10.1097/SCS.00000000000004505
2. Yilmaz S, Adisen MZ, Misirlioglu M, et al. Assessment of third molar impaction pattern and associated clinical symptoms in a central anatolian turkish population. *Med Princ Pract*. 2016;25(2):169–175. doi:10.1159/000442416
3. Gloria J, Martins CC, Armond A, et al. Third molar and their relationship with caries on the distal surface of second molar: a meta-analysis. *J Maxillofac Oral Surg*. 2018;17(2):129–141. doi:10.1007/s12663-017-1032-9
4. Marques J, Montserrat-Bosch M, Figueiredo R, et al. Impacted lower third molars and distal caries in the mandibular second molar. Is prophylactic removal of lower third molars justified? *J Clin Exp Dent*. 2017;9(6):e794–8. doi:10.4317/jced.53919

5. McArdle LW, Patel N, Jones J, et al. The mesially impacted mandibular third molar: the incidence and consequences of distal cervical caries in the mandibular second molar. *Surgeon*. 2018;16(2):67–73. doi:10.1016/j.surge.2016.05.001
6. Ozec I, Herguner SS, Tasdemir U, et al. Prevalence and factors affecting the formation of second molar distal caries in a Turkish population. *Int J Oral Maxillofac Surg*. 2009;38(12):1279–1282. doi:10.1016/j.ijom.2009.07.007
7. McArdle LW, McDonald F, Jones J. Distal cervical caries in the mandibular second molar: an indication for the prophylactic removal of third molar teeth? Update. *Br J Oral Maxillofac Surg*. 2014;52(2):185–189. doi:10.1016/j.bjoms.2013.11.007
8. Pourdanesh F, Dehghani N, Azarsina M, et al. Pattern of odontogenic infections at a tertiary hospital in tehran, iran: a 10-year retrospective study of 310 patients. *J Dent (Tehran)*. 2013;10(4):319–328.
9. Kang F, Huang C, Sah MK, et al. Effect of eruption status of the mandibular third molar on distal caries in the adjacent second molar. *J Oral Maxillofac Surg*. 2016;74(4):684–692. doi:10.1016/j.joms.2015.11.024
10. Tassoker M, Kok H, Sener S. Is There a possible association between skeletal face types and third molar impaction? A retrospective radiographic study. *Med Princ Pract*. 2019;28(1):70–74. doi:10.1159/000495005
11. EshghPour M, Nezadi A, Moradi A, et al. Pattern of mandibular third molar impaction: a cross-sectional study in northeast of Iran. *Niger J Clin Pract*. 2014;17(6):673–677. doi:10.4103/1119-3077.144376
12. Ismail AI, Sohn W, Tellez M, et al. The international caries detection and assessment system (ICDAS): an integrated system for measuring dental caries. *Community Dent Oral Epidemiol*. 2007;35(3):170–178. doi:10.1111/j.1600-0528.2007.00347.x
13. Pitts NB, Ekstrand KR. International caries detection and assessment system (ICDAS) and its international caries classification and management system (ICCMS) - methods for staging of the caries process and enabling dentists to manage caries. *Community Dent Oral Epidemiol*. 2013;41(1):41–52. doi:10.1111/cdoe.12025
14. Akarslan ZZ, Kocabay C. Assessment of the associated symptoms, pathologies, positions and angulations of bilateral occurring mandibular third molars: is there any similarity? *Oral Surg Oral Med Oral Pathol Oral Radiol Endod*. 2009;108(3):e26–e32. doi:10.1016/j.tripleo.2009.05.036
15. Shiller WR. Positional changes in mesio-angular impacted mandibular third molars during a year. *J Am Dent Assoc*. 1979;99(3):460–464. doi:10.14219/jada.archive.1979.0295
16. Leone SA, Edenfield MJ, Cohen ME. Correlation of acute pericoronitis and the position of the mandibular third molar. *Oral Surg Oral Med Oral Pathol*. 1986;62(3):245–250. doi:10.1016/0030-4220(86)90001-0
17. Altan A, Akbulut N. Does the angulation of an impacted mandibular thirdmolar affect the prevalence of preoperative pathoses? *J Dent (Shiraz)*. 2019;20(1):48–52.
18. Falci SG, de Castro CR, Santos RC, et al. Association between the presence of a partially erupted mandibular third molar and the existence of caries in the distal of the second molars. *Int J Oral Maxillofac Surg*. 2012;41(10):1270–1274. doi:10.1016/j.ijom.2012.03.003
19. Marciani RD. Is there pathology associated with asymptomatic third molars? *J Oral Maxillofac Surg*. 2012;70(9 Suppl 1):S15–S19. doi:10.1016/j.joms.2012.04.025
20. Chang SW, Shin SY, Kum KY, et al. Correlation study between distal caries in the mandibular second molar and the eruption status of the mandibular third molar in the Korean population. *Oral Surg Oral Med Oral Pathol Oral Radiol Endod*. 2009;108(6):838–843. doi:10.1016/j.tripleo.2009.07.025
21. Al-Khateeb TH, Bataineh AB. Pathology associated with impacted mandibular third molars in a group of Jordanians. *J Oral Maxillofac Surg*. 2006;64(11):1598–1602. doi:10.1016/j.joms.2005.11.102
22. McArdle LW, Renton TF. Distal cervical caries in the mandibular second molar: an indication for the prophylactic removal of the third molar? *Br J Oral Maxillofac Surg*. 2006;44(1):42–45. doi:10.1016/j.bjoms.2005.07.025
23. Carter K, Worthington S. Predictors of third molar impaction: a systematic review and meta-analysis. *J Dent Res*. 2016;95(3):267–276. doi:10.1177/0022034515615857
24. Nunn ME, Fish MD, Garcia RI, et al. Retained asymptomatic third molars and risk for second molar pathology. *J Dent Res*. 2013;92(12):1095–1099. doi:10.1177/0022034513509281

International Journal of General Medicine

Publish your work in this journal

The International Journal of General Medicine is an international, peer-reviewed open-access journal that focuses on general and internal medicine, pathogenesis, epidemiology, diagnosis, monitoring and treatment protocols. The journal is characterized by the rapid reporting of reviews, original research and clinical studies

Submit your manuscript here: <https://www.dovepress.com/international-journal-of-general-medicine-journal>

across all disease areas. The manuscript management system is completely online and includes a very quick and fair peer-review system, which is all easy to use. Visit <http://www.dovepress.com/testimonials.php> to read real quotes from published authors.