

First Report of Severe Autoimmune Hemolytic Anemia During Eltrombopag Therapy in Waldenström Macroglobulinemia-Associated Thrombocytopenia

Yingying Shen^{1,*}
 Fanhua Yu^{2,*}
 Hangping Ge¹
 Keding Shao²
 Yuhong Zhou¹
 Baodong Ye¹
 Yiping Shen¹
 Dijiong Wu¹

¹Department of Hematology, The First Affiliated Hospital of Zhejiang Chinese Medical University, Hangzhou, Zhejiang, People's Republic of China; ²Zhejiang Chinese Medical University, Hangzhou, Zhejiang, People's Republic of China

*These authors contributed equally to this work

Abstract: Autoimmune thrombocytopenia (ITP) and autoimmune hemolytic anemia (AIHA) can be observed in Waldenström macroglobulinemia (WM). The autoimmune disorders are primarily mediated by autoimmune monoclonal gammopathy, but drug-induced hemolysis should also be considered. Herein, we presented the case of a 63-year-old female WM patient complicated with ITP, who was admitted to our department with a complaint of abdominal pain. After first half of bortezomib/dexamethasone/rituximab (BRD) chemotherapy, her platelet level recovered, but subsequently decreased to extremely low level (around $1-2 \times 10^9/L$), and the patient suffered from platelet transfusion refractoriness. During the management of refractory thrombocytopenia, the patient developed severe hemolytic anemia, and further tests confirmed warm AIHA. FcγRIIIa polymorphism test showed that the patient had FcγRIIIa-131RH, which implied that the AIHA may not be WM-related. Given the effects of ibrutinib in controlling WM, secondary AITP and AIHA, ibrutinib single treatment was started, which quickly corrected the thrombocytopenia within five days, but not hemolysis. With a relatively safe platelet level, eltrombopag was stopped, and the hemolysis relieved three days after eltrombopag withdrawal. This is the first report on eltrombopag-induced AIHA in the management of WM-associated ITP.

Keywords: Waldenström macroglobulinemia, immune thrombocytopenia, ibrutinib, hemolytic anemia, eltrombopag, rituximab

Introduction

Waldenström macroglobulinemia (WM) is a chronic lymphoproliferative disorder, with an indolent clinical course. Autoimmune thrombocytopenia (ITP) has been observed in 3.8% of patients with WM¹ and 10–20% of patients may complicated with autoimmune hemolytic anemia (AIHA).² The occurrences of autoimmune disorders are thought to be related to a dysfunctional immune response associated with WM process.

The preferred management of ITP is corticosteroids if thrombocytopenia is the sole manifestation in WM (normal hemoglobin and without symptoms), and anti-lymphoma therapies such as chemotherapy should be initiated if the thrombocytopenia does not improve with previous treatment.³ Herein, we report a WM patient who rapidly developed pancytopenia (especially with severe ITP) refractory to dexamethasone (DXM) containing chemotherapy (BRD: Bortezomib, DXM and

Correspondence: Dijiong Wu;
 Yiping Shen
 Department of Hematology, The First Affiliated Hospital of Zhejiang Chinese Medical University, #54 Youdian Road, Hangzhou, Zhejiang, 310006, People's Republic of China
 Fax +8657187073569
 Email wudijiong@zcmu.edu.cn;
 shenyp_@126.com

Rituximab), which progressed to very severe thrombocytopenia. During the management of thrombocytopenia with eltrombopag, severe AIHA occurred. Disease remission was finally achieved with the application of ibrutinib, which is an effective Bruton's tyrosine kinase inhibitor, and the AIHA ceased after withdrawal of eltrombopag. To the best of our knowledge, this is the first report of eltrombopag-induced AIHA, and ibrutinib is an ideal option for the autoimmune disorder in WM, and its effect in controlling WM-related ITP is inspiring.

Case Report

A 63-year-old female was admitted to our department with a complaint of abdominal pain on January 8, 2020, and blood routine test showed pancytopenia (WBC $1.8 \times 10^9/L$, Hb 82g/L and PLT $14 \times 10^9/L$). The patient recalled that, three months ago, she suffered from gingival bleeding for four days, but did not take it seriously after healing. Besides moderate anemia and subcutaneous bleeding, she also had multiple enlarged lymph nodes in retroperitoneum, hepatic portal area and pelvic cavity, as well as splenomegaly, as observed by abdominal computerized tomography (CT). Further examinations showed an extremely high ratio of CD19 positive cells (17.63%) in the peripheral blood. Hence, we screened for B cell originated disorders. Histopathology result showed 4% small lymphocytes and occasional lymphoplasmacytic cells in bone marrow aspiration, and there was an active proliferation of megakaryocytes (approximately 126/slide) with dysmaturity (only 9% were platelet-producing). The immunophenotype of this abnormal population was positive for CD19, CD20, CD22, CD79b, CD200, sIgM and κ light chain, weak expression of CD25 and negative for CD103, CD10, CD5, CD11c, CD23, CD27, CD56, CD43, FMC-7, CD38, λ light chain, and CD138, which indicated an abnormal clonal mature B cell population. The next-generation sequencing (NGS) indicated positive for MYD88 L265p mutation (c.794T>C). There was also a clonal IgM in serum (total IgM 7.65 g/L, immunoelectrophoresis showed positive for IgM and κ light chain). These clinical data supported the diagnosis of WM. In addition, Coombs test (both direct antiglobulin test and indirect antiglobulin test), CD55/CD59, lactate dehydrogenase (LDH) showed negative.

Given the ITP-like manifestation in bone marrow morphology, a dexamethasone-containing chemotherapy (BRD: Bortezomib 2 mg weekly $\times 4$, DXM 20 mg weekly $\times 4$ and Rituximab 375 mg/m² monthly) was

initiated. The platelet counts increased to normal after the first two rounds of DXM, but decreased to $12 \times 10^9/L$ after the third dose of DXM, and became refractory to platelet transfusion (Figure 1). The platelet count was maintained at $1-2 \times 10^9/L$, and the patient did not respond to second round continued dose of DXM (20 mg qd for 4 days). The patient refused further chemotherapy and accepted ITP-based treatment including methylprednisolone (12 mg qd), intravenous immunoglobulin (IVIG, 20 g qd $\times 4$), recombinant human thrombopoietin (TPO, 15,000U qd), and TPO receptor agonist (Eltrombopag 75 mg qd) subsequently, but remained unresponsive to all these treatments. Rituximab was continued during the course (500 mg qw $\times 3$) considering the primary WM disease (Figure 2).

During the management of refractory thrombocytopenia, the patient suffered from severe hemolytic anemia (hemoglobin decreased from 104 g/L to 41 g/L), with increased serum indirect bilirubin (IBIL maximum was 119.7 $\mu\text{mol/L}$), LDH (maximum was 559U/L) and reticulocyte (maximum was 25.25%) (Figure 3). The cold agglutinating titer is under 1:4, while the direct antiglobulin test (DAT) was positive for IgG and C3. And the Anti-nuclear antibody (ANA), Ham's, Rous test, as well as ADAMST13 activity and Flare test (PNH), showed normal. To further distinguish whether the hemolysis originated from the primary disease (WM) or was drug-induced, we tested the polymorphism of Fc γ R. The results showed that the patient was Fc γ RIII α 131H/R and Fc γ RIII α 158F/V (Figure 4), which indicated that the hemolysis may not have developed from the progression of WM.⁴ Eltrombopag was highly suspected as the cause of hemolysis, since it was initiated 10 days before the onset of hemolysis, but no published evidence was available for its withdrawal regardless of its potential benefit in platelet recovery. Given the patient's refusal of chemotherapy, we finally started ibrutinib with her informed consent after explaining the high risk of hemorrhage, accompanied by continuous eltrombopag daily and IVIG twice a week. Five days later, the platelet count increased significantly to $15 \times 10^9/L$, but hemolysis did not improve within 15 days, and even got worse. The dosage of ibrutinib was increased from 140 mg to 420 mg per day, and the platelet count continuously increased to around $25 \times 10^9/L$. With decreased risk of hemorrhage, eltrombopag was withdrawn, and the hemolysis stopped immediately (indicators improved every day). IBIL, LDH and absolute value of reticulocyte decreased to almost

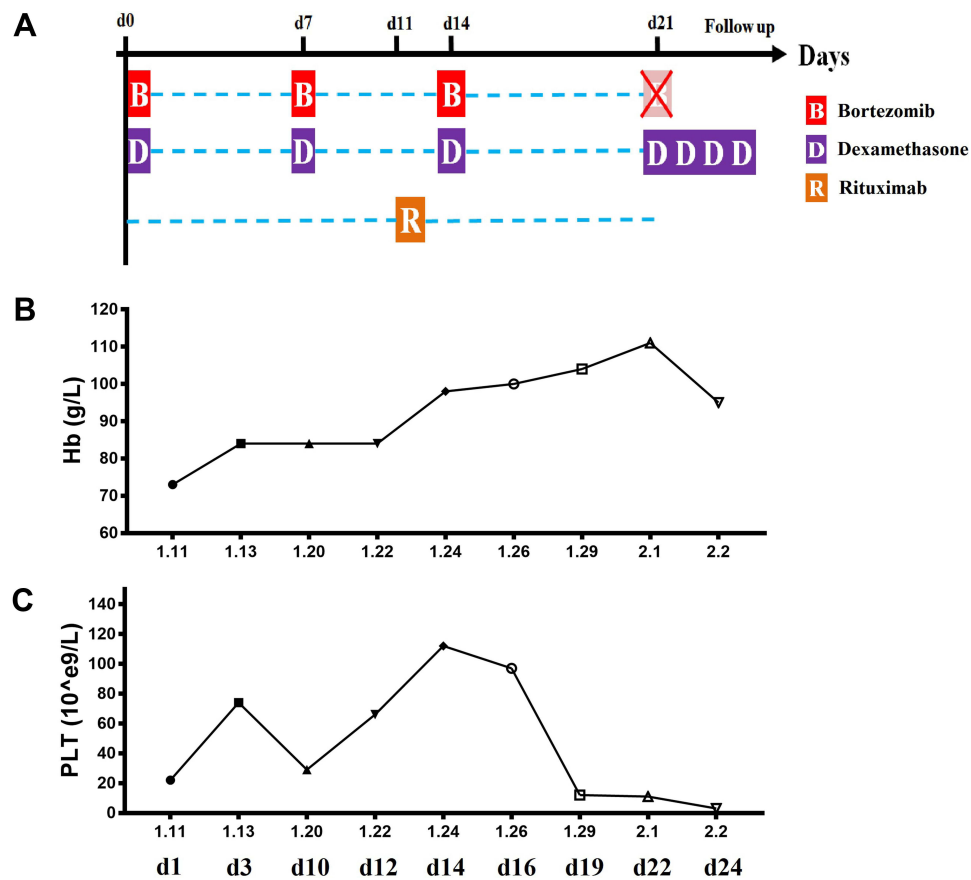


Figure 1 Changes of hemogram during BRD (Bortezomib 2mg weekly×4, DXM 20mg weekly×4 and Rituximab 375mg/m² monthly) chemotherapy. The proposal of BRD chemotherapy was present in (A). The platelet counts increased to normal after first two rounds of BD, but decreased to 12×10⁹/L after the third round, and became refractory to platelet transfusion (B). Additionally, the hemoglobin also decreased 8 days after third round of BD (C).

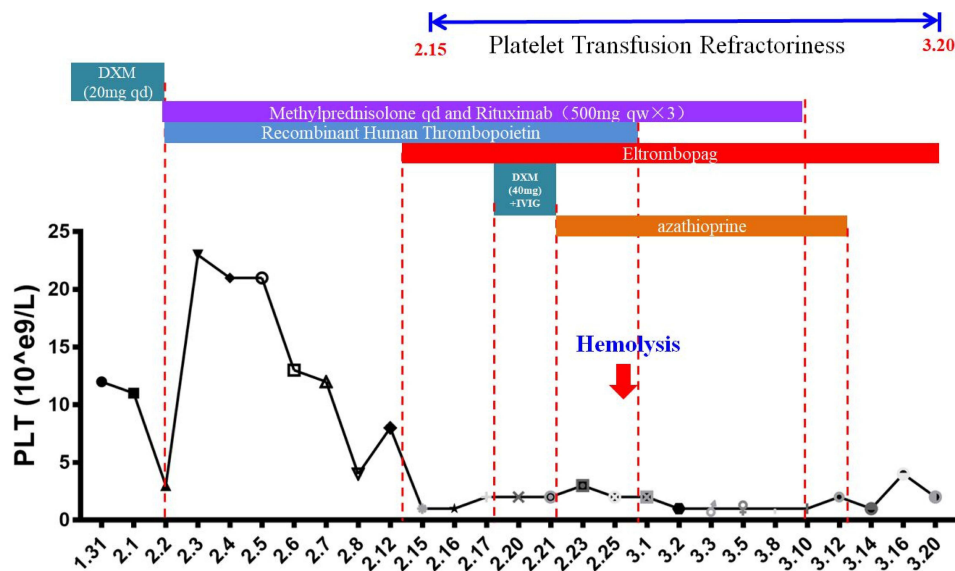


Figure 2 Changes of platelet count after multiple managements on thrombocytopenia. The response of platelet was not sufficient after second round DXM (20mg qd for 3 days). With the consequence treatment including methylprednisolone, intravenous immunoglobulin (IVIG), recombinant human thrombopoietin (TPO) and TPO receptor agonist, no response was observed as well, and patient suffered from with platelet transfusion refractoriness.

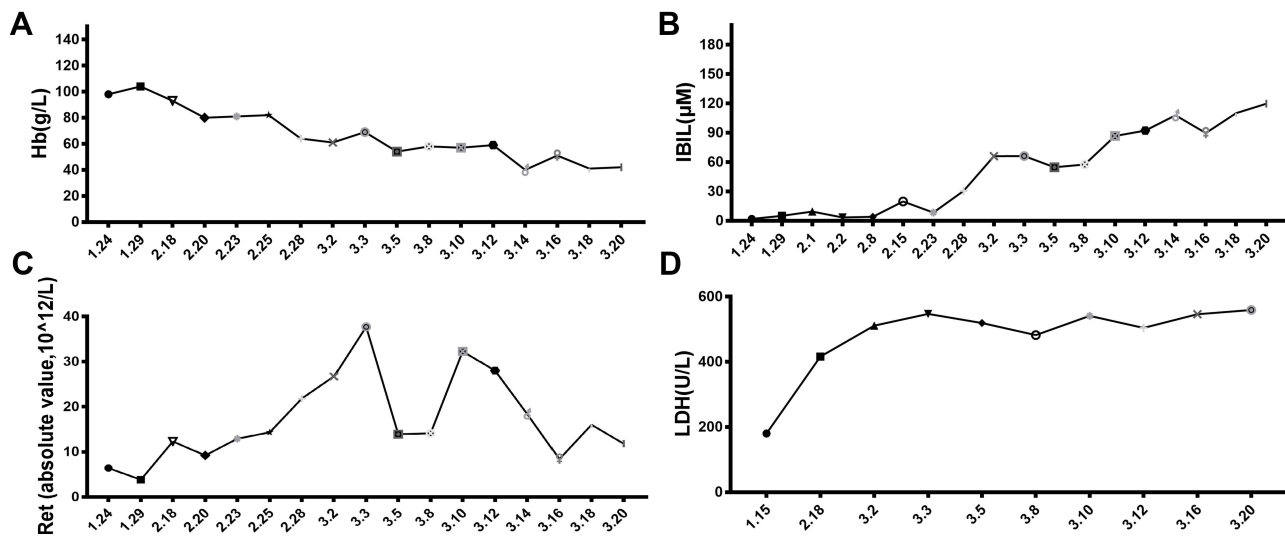


Figure 3 Severe hemolytic anemia occurred during the management of thrombocytopenia. During the management of refractory thrombocytopenia, the patient suffered from severe hemolytic anemia (hemoglobin decreased from 104 g/L to 41g/L, **(A)**), with high level serum indirect bilirubin (IBIL maximum to 119.7 μ mol/L, **(B)**), increased reticulocyte **(C)**, and lactic dehydrogenase (LDH maximum to 559U/L, **(D)**).

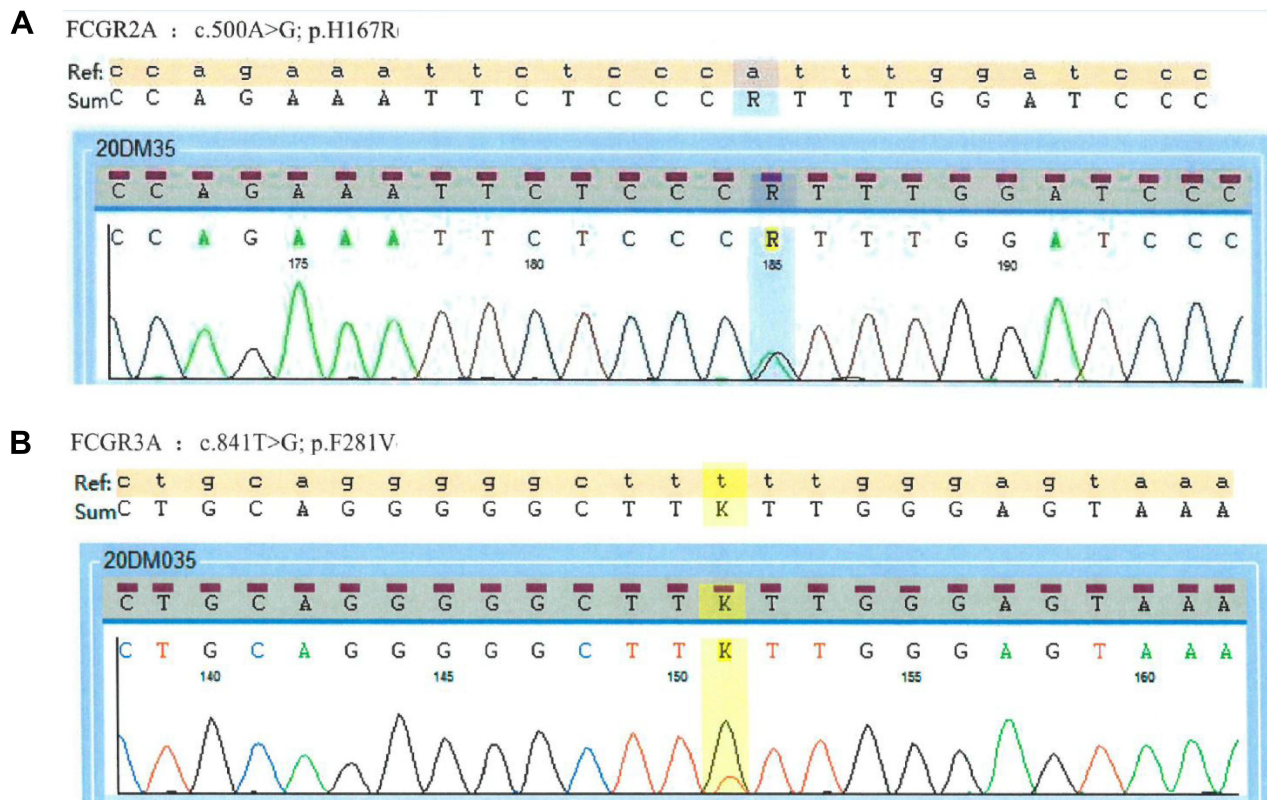


Figure 4 PCR and Sanger test for polymorphism of Fc γ R. Results showed that this patient is Fc γ RII α 131H/R **(A)** and Fc γ RIII α 158F/V **(B)**.

normal within 10 days, and the hemoglobin recovered in 50 days (Figure 5). The patient continued the ibrutinib maintenance therapy for three months and achieved very good partial remission (VGPR), with normal IgM, hemogram and stable disease.

Discussion

Autoimmune phenomenon is well recognized in B cell-associated disorders, which is mostly mediated by autoimmune monoclonal gammopathy, including IgM or IgG.^{1,3,5,6} The secondary immune thrombocytopenia in

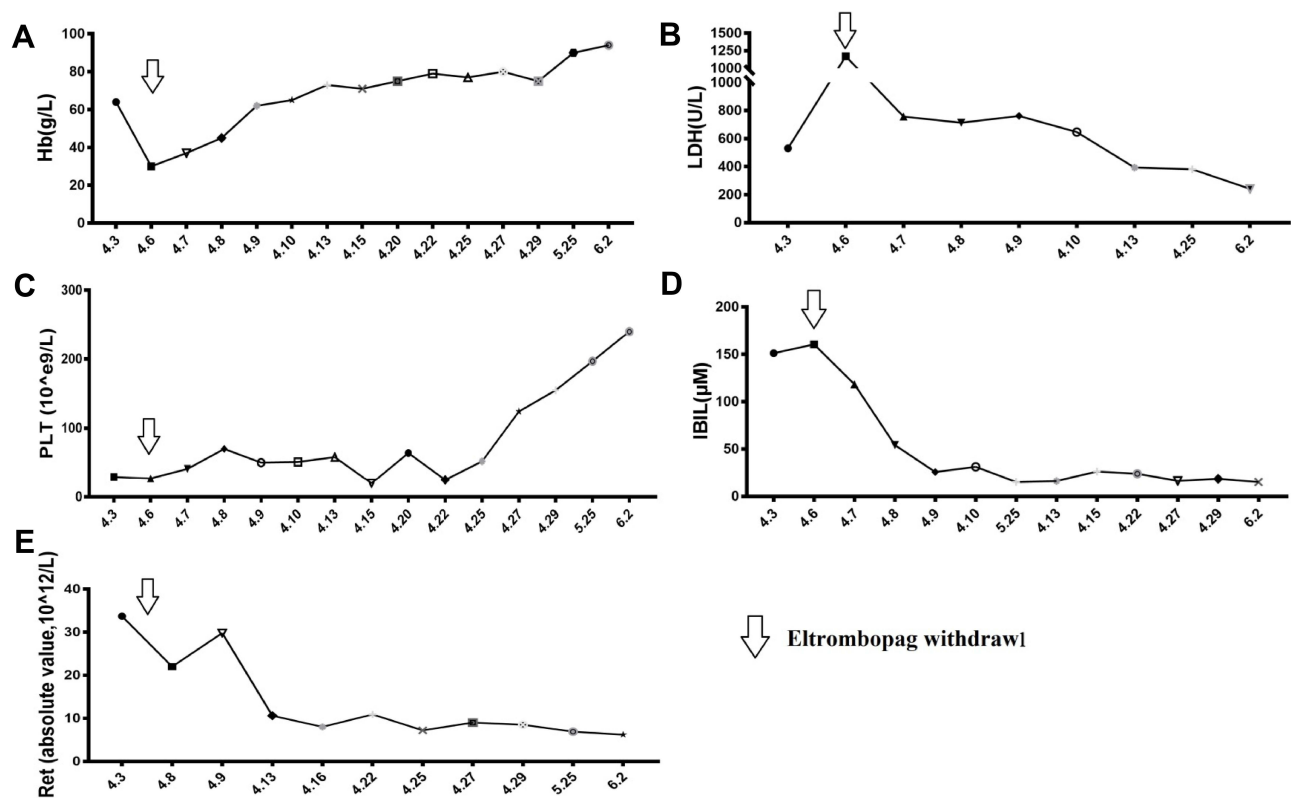


Figure 5 Changes of hemoglobin, platelet, and hemolysis indexes after Eltrombopag withdraw. Results shows that LDH (B), IBIL (D) and Ret (E) improved immediately within 3 days after eltrombopag withdrawal, and decreased to almost normal within 10 days. The hemoglobin recovered in 50 days (A) and platelet count recovered to normal in 20 days later (C).

WM may be complement-mediated, and the severity of thrombocytopenia varies from mild to fatal.¹ The primary therapy for ITP in WM is corticosteroids or corticosteroids containing chemotherapy. For the refractory and relapse cases, splenectomy, vinca alkaloids, azathioprine, and high-dose intravenous gamma-globulin therapy may not work. According to the National Comprehensive Cancer Network (NCCN) guideline, the preferred regimens for WM include bendamustine/rituximab (BR), bortezomib/dexamethasone/rituximab (BRD), ibrutinib±rituximab (I±R), and rituximab/cyclophosphamide/dexamethasone (BCD), which can achieve >80% efficacy.⁷

In this case, the patient achieved quick platelet response in the first half of BRD therapy, but subsequently suffered from refractory platelet transfusion and severe thrombocytopenia. The refractory thrombocytopenia did not respond to high dose IVIG, recombinant human thrombopoietin (rhTPO), methylprednisolone and azathioprine, respectively. Given the high response rate of eltrombopag for secondary immune thrombocytopenia in chronic lymphoproliferative disorders,⁸ TPO receptor agonist (TPO-

RA) was tried, but the platelet count showed no improvement.

To the best of our knowledge, there is only one report about concomitant AIHA and ITP in WM, which was resolved by the combination treatment with rituximab and romiplostim.⁹ AIHA includes both warm AIHA and cold agglutinin disease (CAD), and the most common cause of hemolysis in B cell disorders is primary disease related,¹⁰ in which the malignant cells serve as antigen-presenting cells to T lymphocytes, and the generated autoreactive lymphocytes are involved. In WM, the majority of cases with AIHA are CAD, and DAT results always show positive for anti-C3 but negative for anti-IgG.¹⁰ Inconsistent with the literature, our case was positive for both anti-IgG and anti-C3, and warm AIHA was confirmed. IgG fragment C (Fcγ)-mediated erythrophagocytosis has been recognized as the major pathogenic mechanism responsible for AIHA.^{11–13} To distinguish whether the warm AIHA in WM was disease-related or drug-induced, the polymorphism of FcγRIIa was detected by Sanger sequencing. As reported, all the IgG-mediated warm AIHA in WM mostly

showed FcγRIIα-131 homozygous (131 HH or 131RR),⁴ and the heterozygous 131RH in our case indicated that AIHA may not be WM clone-related, and drug-induced AIHA was suspected. However, no clear drug was found after searching published literatures and from our experience. According to the patient's preference, ibrutinib single treatment was initiated, which may be beneficial for the primary disease as well as secondary ITP and AIHA.^{14–16} As expected, the thrombocytopenia was quickly resolved, and became transfusion independent, but the AIHA did not resolved and even worsen, which further indicated that the AIHA was not WM-related. With a relatively safe platelet level, we discontinued eltrombopag, which was a potential suspicious drug that was started 10 days before hemolysis. Notably, the hemolysis stopped within three days (indicator improved every day) after eltrombopag withdrawal. Based on the clinical manifestations and consequent changes, we deduced that the AIHA may close related to eltrombopag.

In summary, this is the first report of severe autoimmune hemolytic anemia during eltrombopag therapy in Waldenström macroglobulinemia-associated thrombocytopenia. The mechanism of hemolysis in our case is unclear and may be associated with the specific disease background. Further investigations are needed. Physicians should consider the possibility of drug-induced AIHA if hemolysis develops, and drug withdrawal should be immediately initiated.

Ethics Approval and Consent to Participate

This study was approved by the ethics committee of the Zhejiang Provincial Hospital of TCM.

Consent for Publication

Written informed consent was obtained from the individual for the publication of any potentially identifiable images or data included in this article.

Funding

The present study was supported by the Natural Science Foundation of Zhejiang Province (NO. LY21H290003, LY17H290005), Zhejiang Outstanding Young Talent Fund of Traditional Chinese Medicine (NO. 2015ZQ012) and Specialized Project for Scientific Research of Bases for TCM Clinical Research of State Administration of TCM (NO. JDZX2015109).

Disclosure

The authors declare that there is no conflict of interest.

References

- Owen RG, Lubenko A, Savage J, Parapia LA, Jack AS, Morgan GJ. Autoimmune thrombocytopenia in Waldenström's macroglobulinemia. *Am J Hematol*. 2001;66:116–119. doi:10.1002/1096-8652(200102)66:2<116::AID-AJH1026>3.0.CO;2-V
- Jonsson V, Kierkegaard A, Salling S, et al. Autoimmunity in Waldenström's macroglobulinaemia. *Leuk Lymphoma*. 1999;34:373–379. doi:10.3109/10428199909050962
- Nakazaki K, Hangaishi A, Nakamura F, et al. IgG-associated immune thrombocytopenia in Waldenström macroglobulinemia. *Int J Hematol*. 2010;92:360–363. doi:10.1007/s12185-010-0639-0
- Poullain S, Dervite I, Leleu X, et al. Autoimmune hemolytic anemias and IgG antierythrocyte autoantibodies in Waldenström's macroglobulinemia: association with FcγRIIa polymorphism. *Leukemia*. 2006;20:1179–1181. doi:10.1038/sj.leu.2404199
- Gertz MA. Waldenström macroglobulinemia: 2017 update on diagnosis, risk stratification, and management. *Am J Hematol*. 2017;92:209–217. doi:10.1002/ajh.24557
- Fattizzo B, Barcellini W. Autoimmune cytopenias in chronic lymphocytic leukemia: focus on molecular aspects. *Front Oncol*. 2019;9:1435. doi:10.3389/fonc.2019.01435
- Castillo JJ, Advani RH, Branagan AR, et al. Consensus treatment recommendations from the tenth international workshop for Waldenström Macroglobulinaemia. *Lancet Haematol*. 2020;7:e827–e837. doi:10.1016/S2352-3026(20)30224-6
- Visco C, Rodeghiero F, Romano A, et al. Eltrombopag for immune thrombocytopenia secondary to chronic lymphoproliferative disorders: a Phase 2 multicenter study. *Blood*. 2019;134(20):1708–1711. doi:10.1182/blood.2019001617
- Nozaki Y, Koshiishi M, Sueki Y, et al. [Successful treatment with rituximab and romiplostim for thrombocytopenia associated with Waldenström's macroglobulinemia initially presenting as Evans syndrome]. *Rinsho Ketsueki*. 2015;56:317–322. Japanese.
- Durani U, Go RS, Kay NE. Immune-mediated hemolytic anemia and thrombocytopenia in clonal B-cell disorders: a review. *Clin Adv Hematol Oncol*. 2018;16:670–676.
- Rosse WF, Hillmen P, Schreiber AD. Immune-mediated hemolytic anemia. *Hematology Am Soc Hematol Educ Program*. 2004;2004(1):48–62. doi:10.1182/asheducation-2004.1.48
- van Royen-kerkhof A, Sanders EA, Walraven V, et al. A novel human CD32 mAb blocks experimental immune haemolytic anaemia in FcγRIIa transgenic mice. *Br J Haematol*. 2005;130:130–137. doi:10.1111/j.1365-2141.2005.05571.x
- Hill QA, Stamps R, Massey E, et al. Guidelines on the management of drug-induced immune and secondary autoimmune, haemolytic anaemia. *Br J Haematol*. 2017;177(2):208–220. doi:10.1111/bjh.14654
- Tripathi A, Steingart R. Resolution of Waldenström Macroglobulinemia-associated autoimmune hemolysis with ibrutinib. *J Oncol Pract*. 2016;12:490–491. doi:10.1200/JOP.2016.011932
- Treon SP, Meid K, Gustine J, et al. Long-term follow-up of ibrutinib monotherapy in symptomatic, previously treated patients with Waldenström Macroglobulinemia. *J Clin Oncol*. 2020;39:JCO2000555.
- Sato R, Jacob J, Gaballa S. Rapid flare of immune thrombocytopenia after stopping ibrutinib in a patient with chronic lymphocytic leukemia. *Leuk Lymphoma*. 2018;59(7):1738–1741. doi:10.1080/10428194.2017.1387907

OncoTargets and Therapy

Dovepress

Publish your work in this journal

OncoTargets and Therapy is an international, peer-reviewed, open access journal focusing on the pathological basis of all cancers, potential targets for therapy and treatment protocols employed to improve the management of cancer patients. The journal also focuses on the impact of management programs and new therapeutic

agents and protocols on patient perspectives such as quality of life, adherence and satisfaction. The manuscript management system is completely online and includes a very quick and fair peer-review system, which is all easy to use. Visit <http://www.dovepress.com/testimonials.php> to read real quotes from published authors.

Submit your manuscript here: <https://www.dovepress.com/oncotargets-and-therapy-journal>