

Evaluation of a partial retinal surface tear by optical coherence tomography

Kenji Kawazoe¹
Hisato Ohno¹
Kenji Inoue¹
Yasuo Yanagi²

¹Inouye Eye Hospital, 4-3 Kanda-Surugadai, Chiyoda-ku, Tokyo, Japan;

²Department of Ophthalmology, University of Tokyo School of Medicine, 7-3-1 Hongo Bunkyo-ku, Tokyo, Japan

Abstract: Differential diagnosis of retinal hemorrhage and partial tear of the retinal surface may be difficult in some cases. A 62-year-old woman was mistakenly followed-up for small retinal hemorrhages for more than 1 year. Blocked fluorescence specific to retinal hemorrhage was not observed by fluorescein angiography (FAG). Optical coherence tomography (OCT) clearly showed defects of the retinal surface indicating partial tears of the surface at the vitreoretinal juncture and not hemorrhage. OCT is a useful and noninvasive device for the differential diagnosis of retinal hemorrhage and partial tear of the retinal surface.

Keywords: OCT, differential diagnosis, retinal surface defect, vitreoretinal juncture over retinal vessels

Introduction

Fluorescein angiography (FAG) is usually performed to evaluate retinal hemorrhage of unknown cause. In contrast, optical coherence tomography (OCT) enables precise evaluation of the retinal structure in a noninvasive manner. For retinal hemorrhage, OCT is also useful for observing a cross-section of the retina affected by hemorrhage.

We herein report a case of partial tears of the retinal surface that was mistakenly followed-up as small retinal hemorrhages until OCT clearly showed the defects of the retinal surface.

Case report

A 62-year-old woman was referred to our hospital on suspicion of retinal hemorrhage involving the retinal vessels in her left eye (Figure 1). At her first visit, visual acuity was 20/20 and as she did not have other symptoms she was to be followed-up. As the finding of her fundus had not changed 1 year later, FAG and OCT were performed to examine the cause of retinal hemorrhage. Blocked fluorescence specific to retinal hemorrhage was not observed by FAG (Figure 2). Partial defects of the retinal inner layer were however shown by OCT (Figure 3). From these results, we diagnosed this case as partial tears of the retinal surface at the vitreoretinal juncture and not hemorrhage.

Discussion

Differential diagnosis of retinal hemorrhage and partial tear of the retinal surface may be difficult in some cases, because both lesions have similar retinal colors and configurations. A case like the one we present here is probably overlooked without

Correspondence: Hisato Ohno
Inouye Eye Hospital, 4-3 Kanda-Surugadai,
Chiyoda-ku, Tokyo, 101-0062, Japan
Tel +81 3 3295 0911
Fax +81 3 3293 0917
Email oono-h@inouye-eye.or.jp

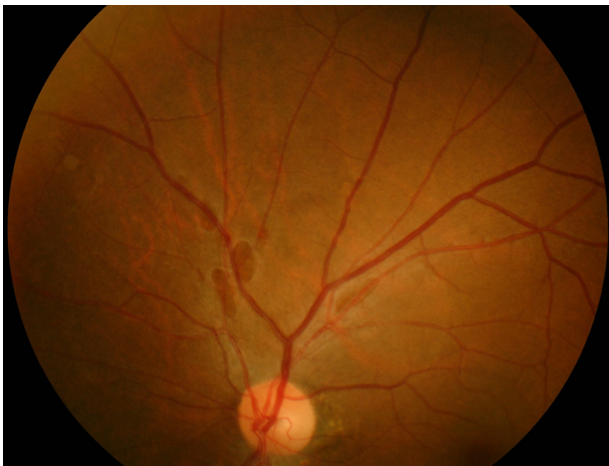


Figure 1 Several spots similar to retinal hemorrhage were seen along with the vessels superior to the disc.

further examinations in routine work. OCT is a useful and noninvasive device for the differential diagnosis of retinal hemorrhage and partial tear of the retinal surface. OCT shows an image of partial tear of the retinal surface as a defect of the inner layer of the retina. The image is quite different from that of retinal hemorrhage.

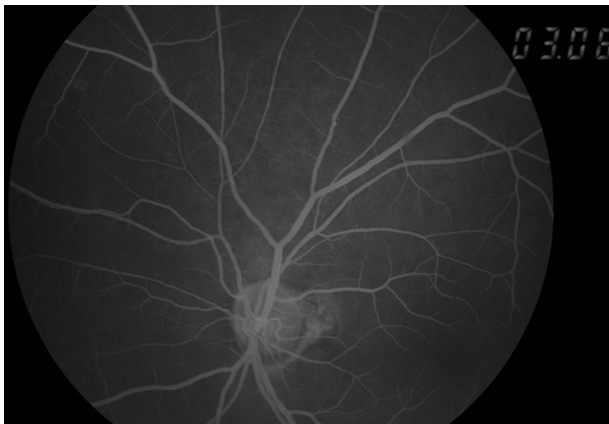


Figure 2 Fluorescein leakage specific to retinal hemorrhage was not shown in fluorescein angiography.

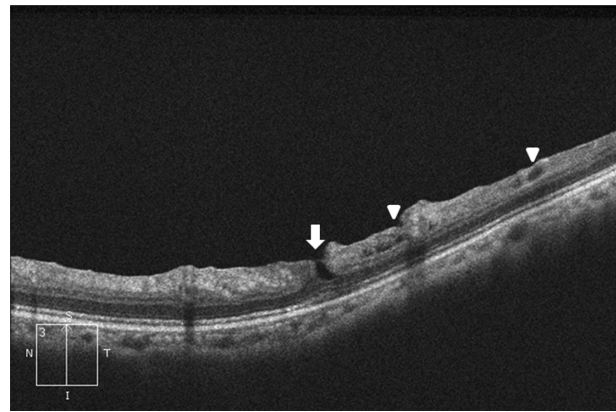


Figure 3 Optical coherence tomography reveals the defects of the inner layer of the retina equivalent to the partial tear (arrow) and small surface break (arrowhead).

Foos RY emphasized the causative role of vitreous traction with partial tears of the retinal surface being caused by posterior vitreous detachment, and proposed three events that predispose to or cause small surface breaks: developmental thinning of the inner limiting lamina; subsurface retinal degeneration; and transmigrating macrophages. When small surface breaks become complicated by vitreous incarceration or by simple epiretinal membrane formation, direct posterior vitreous detachment may peel portions of the superficial retina, and the resulting large surface breaks may in turn provoke complex proliferative lesions of the vitreoretinal juncture.¹

In our case, OCT clearly showed the defect of the inner layer of the retina and small surface break. Regular follow-up of the retina is needed to detect further complications.

Disclosure

No conflicts of interest were declared in relation to this paper.

Reference

1. Foos RY. Vitreoretinal juncture over the retinal vessels. *GraefesArchiv Ophthalmologie*. 1977;204:223–234.

Clinical Ophthalmology

Publish your work in this journal

Clinical Ophthalmology is an international, peer-reviewed journal covering all subspecialties within ophthalmology. Key topics include: Optometry; Visual science; Pharmacology and drug therapy in eye diseases; Basic Sciences; Primary and Secondary eye care; Patient Safety and Quality of Care Improvements. This journal is indexed on

Submit your manuscript here: <http://www.dovepress.com/clinical-ophthalmology-journal>

Dovepress

PubMed Central and CAS, and is the official journal of The Society of Clinical Ophthalmology (SCO). The manuscript management system is completely online and includes a very quick and fair peer-review system, which is all easy to use. Visit <http://www.dovepress.com/testimonials.php> to read real quotes from published authors.