

New ECG Algorithm for the Prediction of Culprit Vessel in Acute Myocardial Infarction Involving Lateral Part of the Ventricle: Ilkay Classification

Ersin Sarıçam¹, Mehmet Akif Erdol², Engin Bozkurt³, Erdogan Ilkay³, Ömer Faruk Cantekin⁴

¹Department of Cardiology, Medicana International Ankara Hospital, Atılım University, Ankara, Turkey; ²Ankara Şehir Hastanesi, Cardiology Clinic, Ankara, Turkey; ³Department of Cardiology, Medicana International Ankara Hospital, Ankara, Turkey; ⁴Faculty of Health Sciences, Department of Social Work, Gazi University, Ankara, Turkey

Correspondence: Ersin Sarıçam, Medicana International Ankara Hospital, Atılım University, Sogutozu District 2165 St. No: 6 Sogutozu, Ankara, Turkey, Email saricamersin@yahoo.com

Background: Isolated lateral myocardial infarction sometimes does not meet ST-segment elevation myocardial infarction (STEMI) criteria according to contiguous leads. This condition could cause late diagnosis and the need for revascularization therapy.

Aim: To accurately predict the occlusion of lateral surface of the left ventricle, we defined a new electrocardiogram (ECG) algorithm by using angiographic and electrocardiographic correlations.

Methods: This was a retrospective, multicenter observational study. The study population consisted of 200 patients with STEMI affecting lateral surface of myocardium, between 2021 and 2022. According to the coronary angiography results, we identified 74 eligible patients for study protocol. The study patients were divided into two groups: isolated DB (14 patients) or circumflex obtuse marginal group (60 patients).

Results: ST depression in lead V2 had high positive predictive values for the prediction of obtuse marginal occlusion (positive predictive values (PPV), 100%; negative predictive value (NPV), 90%). ST elevation in V2 in ECG, in conjunction with ST depression in lead III had high positive predictive values for prediction of diagonal branch of LAD. Moreover, the presence of hyperacute T wave (≥ 10 mm) in lead V2 and ≥ 2 mm ST depression in lead III had large diagonal branch of LAD (PPV, 98%; NPV, 100%). However, < 10 mm T wave in lead V2 and < 2 mm ST depression in lead III had small diagonal branch of LAD.

Conclusion: We comprehensively classified the lateral STEMI definition through new electrocardiographic scheme as Ilkay classification, whereby we could accurately predict infarct-related artery and its occlusion level in lateral myocardial infarction.

Keywords: diagonal branch, electrocardiogram, lateral myocardial infarction

Introduction

The electrocardiogram (ECG) is the most commonly used and readily available diagnostic tool for the diagnosis of ST-segment elevated myocardial infarction (STEMI).¹ Early recognition of STEMI improves outcomes. Moreover, identifying the infarct-related coronary artery on the ECG is of great importance for reperfusion treatment.² The ECG should be acquired and interpreted promptly after emergency evaluation. Acute myocardial ischemia may cause dynamic changes in ECG waveform. Serial ECG assessment supplies clinicians with critical information for the patients with non-diagnostic ECG at initial presentation.³

To date, ECG pattern for the classification STEMI has shown infarct location and infarct-related artery.^{4,5} Isolated lateral myocardial infarction is caused by the occlusion of the obtuse marginal branch of the left circumflex (Cx) arteries or the diagonal branch of left anterior descending (LAD).^{6,7} The occlusion of diagonal branch (DB), arising from the LAD, commonly occurs together with acute LAD obstruction.⁸ However, isolated DB occlusion has been infrequently seen as STEMI. Moreover, diagonal branch (DB) occlusion can be subtle in electrocardiogram change.⁹ ECG changes of

isolated DB occlusion have been explained in previous studies.^{10–12} Especially, ECG abnormalities have been defined predominantly in leads I and aVL. However, information about the changes in the precordial leads is less common.^{13,14}

According to the latest ESC Guidelines for the management of acute STEMI, ST elevation in leads I and aVL meet classic STEMI criteria.³ However, isolated diagonal occlusion often will not meet STEMI criteria due to presence of the ST elevation noncontiguous leads aVL and V2. This confusing condition could cause late diagnosis and the need for revascularization therapy. Secondly, early ECG findings could be subtle because of borderline or minimal ST-segment/T wave differentiation. Initially, only hyperacute T-wave changes could be detected in the early phase of STEMI without ST-segment elevation. Recognizing infarct-related artery may be important especially in small branch occlusion. Another difficulty in diagnosis, in some acute coronary syndrome cases, is that the obtuse marginal or diagonal branch occlusion could be missed as culprit vessel due to insignificance, being a small vessel for revascularization. Finally, ECG classification in acute myocardial infarction involving isolated lateral ventricle (according to diagonal branch occlusion region (D1 or D2) and the obtuse marginal) has not been clearly identified. Therefore, there is a need for a new ECG interpretation for the early detection of acute coronary occlusion involving the lateral region.

To accurately predict the occlusion of lateral surface of left ventricle, we classified the ECG pattern of lateral involving myocardial infarction by using angiographic and electrocardiographic correlations. We think a new ECG algorithm may help identify more subtle cases of diagonal and obtuse marginal occlusion based on coronary anatomy.

Methods

This was a retrospective, multicenter observational study. The study population consisted of 200 patients with STEMI affecting lateral surface of myocardium, between 2021 and 2022. All of the patients were retrospectively investigated. Coronary angiography was performed on all patients within the first 12 h after onset of symptoms. All patients underwent primary percutaneous coronary intervention (PCI).

Diagnosis of STEMI was made based on the history of typical chest pain (lasting more than 20 min), documented ST-segment elevation ≥ 1 mm in ≥ 2 contiguous leads, and an associated rise and/or fall of hs-Troponin I at emergency department (ED) of Medicana Ankara Hospital and Ankara Sehir Hospital.

The patients with right coronary artery as the infarct-related artery, complete left bundle branch block, pacemaker, digitalis therapy, left ventricular hypertrophy, ECG signs of an old MI or previous cardiac surgery were excluded.

Study Population

According to the coronary angiography results, we determined 74 eligible patients for study protocol. The patients were divided into two groups based on culprit vessel involvement (diagonal artery or Cx proximal/obtuse marginal/ramus intermedius involvement).

Fourteen patients were diagnosed with isolated diagonal artery occlusion with ST-elevations in I, aVL and V2, sparing V3-V5 on ECG (diagonal group). Sixty patients had circumflex proximal/first obtuse marginal or intermediate artery as culprit vessel with ST-elevations in II, III, aVF, V6 on ECG (control group).

In both groups, culprit vessel had TIMI flow (Thrombolysis in Myocardial Infarction Trial) grade 0–1 and diameter ≥ 2 mm, as evaluated by coronary angiography; and final TIMI flow of culprit vessel was grade 2–3 after primary PCI.

Study Group (Isolated Diagonal Branch Disease)

Isolated diagonal artery myocardial infarction inclusion criteria were: sinus rhythm; ST-elevation of at least 2 mm (above 40 years) or 2.5 mm (below 40 years) in V2 precordial lead, at least 1 mm elevation in other leads (I, aVL). Coronary angiography documented diagonal vessel disease (D1 or D2) as the culprit lesion and no LAD stenosis greater than 50%. PCI was performed in 14 patients with isolated diagonal artery occlusion because of chest pain.

ECG criteria used to locate the occlusion of the first diagonal artery (D1) and the second diagonal artery (D2) are based on deviations of the ST-segment elevation in v2 lead, I and aVL lead and ST-segment depression in III lead, and T wave height in V2 lead on ECG. All these deviations were evaluated in all patients.

Control Group

Sixty patients had circumflex proximal/first obtuse marginal or ramus intermedius artery as culprit artery. ECG criteria used to locate the occlusion are based on the ST-segment depression in V2 and ST-segment elevations (at least 1 mm) in II, III, aVF, and V6 leads on ECG.

Electrocardiographic Analysis

Standard 12-lead ECG was recorded at a paper speed of 25 mm/s and a voltage of 10 mm/mV at the time of admission. ECG tracings were reviewed by 2 independent investigators blinded to clinical and angiographic data before and after PCI.

The J-point (junction between QRS termination and ST-segment onset) was used to determine the magnitude of the ST-segment. The ST-segment elevation was measured at PQ junction (QRS onset).³

Coronary Angiography

All patients underwent coronary angiography via femoral artery access. Each coronary angiogram was evaluated by two independent observers blinded to ECG findings. All cases were identified by characteristics of lesions (ulcerated plaque, severe stenosis), flow of blood through stenosis. Flow over the culprit lesion was graded using Thrombolysis in Myocardial Infarction Trial (TIMI) criteria.¹⁵

Statistical Analyses

The data were analyzed using SPSS 7.0 for Windows (SPSS Inc., Chicago, Illinois). Categorical variables were presented as number and percentage (%) and continuous variables were presented as mean \pm SD. Odds ratio with 95% confidence intervals and positive predictive values (PPV), negative predictive value (NPV) were calculated for selected variables and their significance. Qualitative variables were compared using the Chi-square test/Fisher's exact test as appropriate. A *p* value of <0.05 was considered statistically significant.

Results

The study sample consisted of 74 patients with mean age of 45.64 ± 4.94 years. The male patient proportion was higher than that of females (53 (71.6%), 21 (28.4%), respectively).

The most frequent infarct-related artery was proximal left circumflex/first obtuse marginal (Cx-OM1) artery in 54 (72%). First diagonal (D1), second diagonal (D2), and ramus intermedius (RI) accounted for 7 (10%), 7 (10%), and 6 (8%), respectively. All patients underwent primary PCI. The demographic, electrocardiographic, and angiographic features of the study population were shown in [Table 1](#).

Table 1 Demographic, Electrocardiographic, and Angiographic Features of the Study Population

| | | Count | Column N % |
|-----------------------------------|------------------|------------|------------|
| Gender | Female | 21 | 28.4% |
| | Male | 53 | 71.6% |
| Study population | D1 | 7 | 9.5% |
| | D2 | 7 | 9.5% |
| | Cx- OM1/ RI | 60 | 81.1% |
| Presence of Diagonal or Cx/OM1/RI | DIAGONAL (D1-D2) | (7+7) 14 | 18.9% |
| | (Cx/OM1 and RI) | (54+ 6) 60 | 81.1% |

(Continued)

Table 1 (Continued).

| | | Count | Column N % |
|--|-----|-------|------------|
| Successful PCI | Yes | 74 | 100.0% |
| | No | 0 | 0.0% |
| dm | No | 62 | 83.8% |
| | Yes | 12 | 16.2% |
| ht | No | 64 | 86.5% |
| | Yes | 10 | 13.5% |
| ST elevation in lead V2 | Yes | 14 | 18.9% |
| | No | 60 | 81.1% |
| ST depression in lead V2 | Yes | 60 | 81.1% |
| | No | 14 | 18.9% |
| High T wave (≥ 10 mm) in lead V2 | Yes | 7 | 9.5% |
| | No | 67 | 90.5% |
| ST depression in lead III | Yes | 14 | 18.9% |
| | No | 60 | 81.1% |

Abbreviations: Cx, left circumflex artery; OMI, first obtuse marginal artery; D1, first diagonal artery; D2, second diagonal artery; RI, ramus intermedius artery; PCI, primary percutaneous coronary intervention; DM, diabetes mellitus; HT, hypertension.

ECG Parameters to Predict Occlusion Location

The algorithm presented in [Table 2](#) shows the best correlation of electrocardiographic with angiographic findings. ST depression in lead V2 had high positive predictive values for prediction of Cx proximal-OM1/RI occlusion (positive predictive values (PPV), 100%; negative predictive value (NPV), 90%). ST elevation in V2 in ECG, in conjunction with ST depression in lead III had high positive predictive values for prediction of diagonal branch of LAD. Moreover, the presence of hyperacute T wave (≥ 10 mm) in lead V2 and ≥ 2 mm ST depression in lead III had large diagonal branch of

Table 2 The Relationship Between Electrocardiographic and Angiographic Regions of the Study Population

| | | Diagonal Group | | Cx-OMI/RI Group | | P |
|--------------------------|-----------|----------------|--------|-----------------|--------|--------|
| | | f | % | f | % | |
| dm | No | 12 | 85.7% | 50 | 83.3% | 0.595 |
| | Available | 2 | 14.3% | 10 | 16.7% | |
| ht | No | 11 | 78.6% | 53 | 88.3% | 0.388 |
| | Available | 3 | 21.4% | 7 | 11.7% | |
| ST elevation in lead V2 | Available | 14 | 100.0% | 0 | 0.0% | <0.001 |
| | No | 0 | 0.0% | 60 | 100.0% | |
| ST depression in lead V2 | Available | 0 | 0.0% | 60 | 100.0% | <0.001 |
| | No | 14 | 100.0% | 0 | 0.0% | |

(Continued)

Table 2 (Continued).

| | | Diagonal Group | | Cx-OMI/RI Group | | P |
|--|-----------------------|----------------|--------|-----------------|--------|--------|
| | | f | % | f | % | |
| High T wave (≥ 10 mm) in lead V2 | Available (D1 branch) | 7 | 50.0% | 0 | 0.0% | <0.001 |
| | No (D2 branch) | 7 | 50.0% | 60 | 100.0% | |
| ST depression in lead III | Available | 14 | 100.0% | 0 | 0.0% | <0.001 |
| | No | 0 | 0.0% | 60 | 100.0% | |

Abbreviations: CX, left circumflex; OMI, first obtuse marginal; D1, first diagonal artery; D2, second diagonal artery; RI, ramus intermedius; DM, diabetes mellitus; HT, hypertension.

LAD (PPV, 98%; NPV, 100%) (Figure 1). However, <10 mm T wave in lead V2 and <2 mm ST depression in lead III had small diagonal branch of LAD (Figure 2).

There was a significant statistical difference between the two groups regarding the presence of ST elevation in lead V2, ST depression in lead V2, and ST depression in lead III ($p < 0.001$). D1 group T wave had 11.14 ± 1.06 mm, D2 group T wave 4.85 ± 0.69 mm; $p < 0.001$) (Table 2).

Finally, we explained lateral myocardial infarction through the new electrocardiographic algorithm and accepted it as Ilkay classification (Table 3; Figure 3).

Intra and interobserver variability coefficients of ECG patterns were 0.998; 0.950; respectively.

Discussion

The left ventricular lateral wall is supplied by the diagonal branch of the LAD, the obtuse marginal branch of the Cx, or the ramus intermedius.⁶ Diagonal branches of LAD are categorized as D1, D2, D3, etc. Commonly, the first diagonal (D1) branch of LAD tends to be the most prominent with a diameter larger than 2 mm.¹⁶

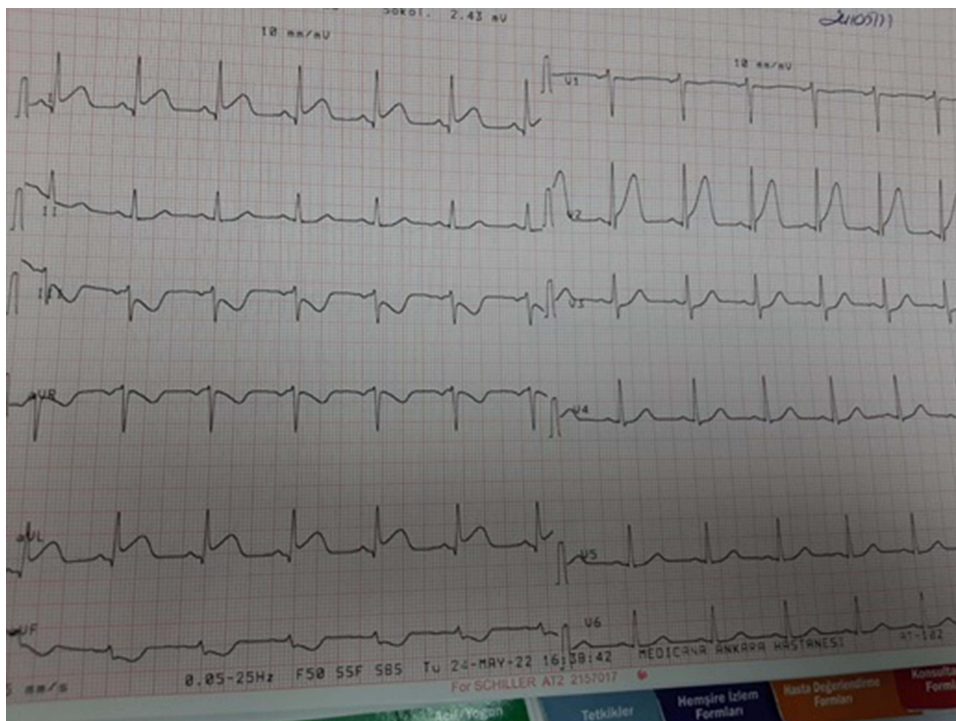


Figure 1 ECG pattern of patient with large diagonal branch (D1) occlusion. ≥ 10 mm T wave and ST elevation in lead V2; ST elevation lead I and aVL; and ≥ 2 mm ST depression lead III.

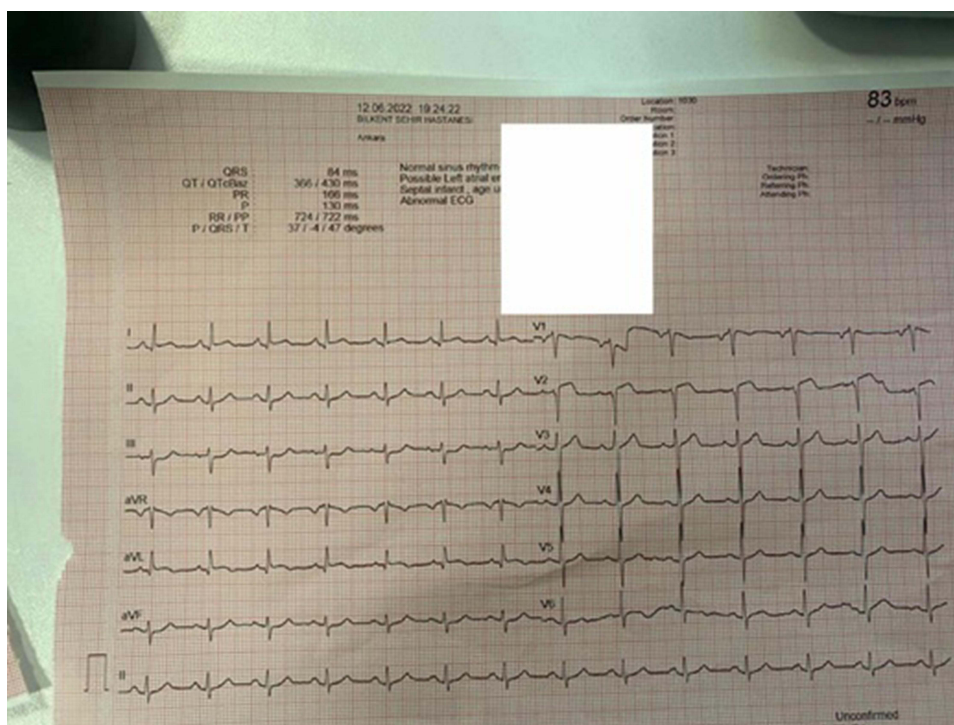


Figure 2 ECG pattern of patient with small diagonal branch (D2) occlusion. Normal T wave and ST elevation in lead V2; minimal ST elevation in lead I and aVL, and <2 mm ST depression lead III.

Lateral STEMI caused by diagonal branch occlusion leads to the ST-segment vector movement toward I, aVL, and V2.¹⁷ Therefore, changes on electrocardiographic leads are associated with the involvement of these branches. ST-segment vector movement seems to be away from V2 (ST depression) in first obtuse marginal occlusion.

ECG changes of lateral surface vessel occlusion of the heart have been explained before.^{11–13} The leads I and aVL have been predominantly evaluated, but information about the changes in the precordial leads is less common. Birnbaum et al reported that ST elevation in aVL and V2 were associated with the occlusion of the first diagonal branch (PPV, 89%; NPV, 100%) and ST elevation in aVL coexisting with ST depression in V2 was related to obstruction of the first obtuse marginal branch (PPV, 100%; NPV, 98%).^{11,18} More recently, isolated ST elevation in V2 coexisting with ST depression in lead III has been shown to predict the occlusion of a large diagonal branch of LAD and has been defined in ECG appearance as the “South African Flag” sign.¹⁹

T waves on ECG represent ventricular repolarization. It has a height proportional to their QRS complex (with T amplitude usually <5mm in limb leads and <10mm in precordial leads). There are many causes of tall T-waves, including early repolarization, LBBB, left ventricular hypertrophy, hyperkalemia, and myocardial infarction.²⁰ Hyperacute T waves may occur early after the onset of coronary occlusion and tend to be a short-lived pattern that

Table 3 Electrocardiographic Algorithm of Lateral Myocardial Infarction as Ikkay Classification

| Lateral Region | ST Elevation in Lead V2 | Tall T Wave (≥10 mm) | ST Depression in Lead V2 | ST Depression in Lead III |
|-------------------------------------|-------------------------|----------------------|--------------------------|---------------------------|
| Large diagonal/ first diagonal (D1) | Yes | Yes | No | Yes |
| Small diagonal/second diagonal (D2) | Yes | No | No | Yes |
| Cx/OMI/ramus intermedius | No | No | Yes | No |

Abbreviations: CX, left circumflex; OMI, first obtuse marginal; D1, first diagonal artery; D2, second diagonal artery; RI, ramus intermedius.

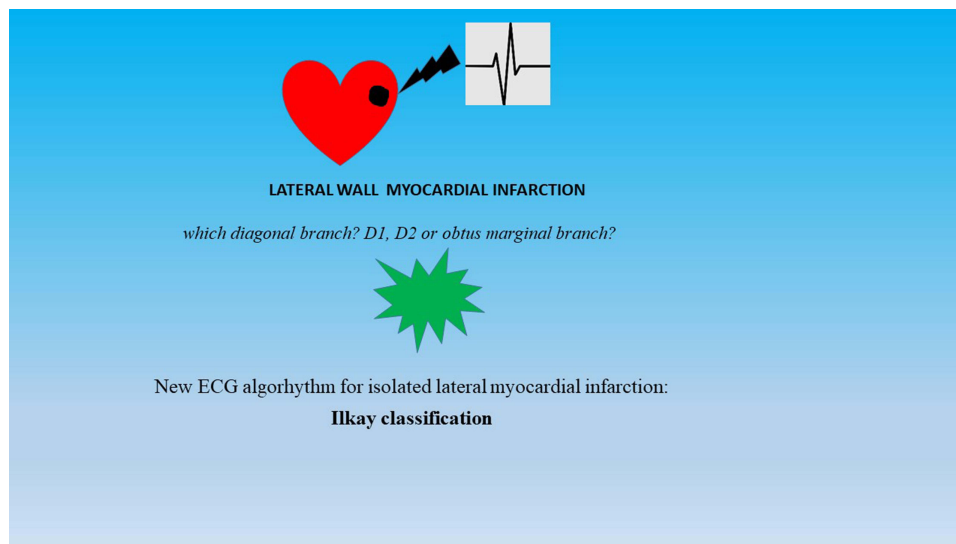


Figure 3 Isolated lateral wall myocardial infarction according to diagonal branches (D1 or D2) and the obtuse marginal has not been clearly identified as electrocardiographic classification. Therefore, there is a need for a new electrocardiogram (ECG) interpretation to accurately predict acute occlusion involving lateral part of ventricle.

progresses rapidly into ST-segment elevation.²¹ In occlusive myocardial infarction, hyperacute T waves are regionally localized to an anatomic area and broad base, rounded peak, and large relative to R-wave.²¹

To date, lateral STEMI has not been defined as detailed schedule. We presented lateral STEMI with the best correlation between electrocardiographic and angiographic findings. ST depression in lead V2 and ST elevation in aVL had high positive predictive values for prediction of Cx proximal-OM1/RI occlusion (PPV, 100%; NPV, 90%). Bedside, ST elevation in V2 coexisting with \geq ST depression in lead III and ≥ 10 mm higher T wave in V2 had high positive predictive values for prediction of large diagonal branch of LAD (PPV, 98%; NPV, 100%). However, ST elevation in V2 coexisting with < 2 mm ST depression in lead III and normal height T wave had small diagonal branch of LAD. Finally, we reported lateral myocardial infarction through new electrocardiographic chart, and defined as İlkay classification.

Vessel size is the most commonly used parameter to define the clinical significance of a side branch.¹³ Koo et al developed a new scoring system (SNUH score) that incorporated the number and distribution of branches as well as the size, to better reflect the myocardial mass at risk ($[(\text{Size (S)}, \text{vessel diameter} \geq 2.5 \text{ mm}; \text{Number (Nu)} \text{ number of diagonal branches} \leq 2; \text{Highest (H)}, \text{no branch below the target branch})]$). They stated that SNUH score was higher in branches with ST-segment elevation.⁹ Fanne et al reported that more severe lateral lead ST-elevations were related to higher SNUH score and pre-intervention TIMI flow.¹³

Contrary to popular belief, STEMI in lateral surface affecting leads may be associated with dangerous results. Acute Cx occlusion with left dominant circulation had worse outcome (7). Furthermore, loss of the diagonal branch in anterior STEMI patients had independently higher in-hospital complications.¹⁷ Additionally, in acute coronary syndromes involving bifurcation lesions (side branch assessment limited to MEDINA 0,0,1 lesions), revascularization should be planned using the detection of plaque disruption and/or thrombus at the site of the bifurcation with hemodynamic status.^{22,23}

There are several ECG algorithms proposed for patients without known coronary artery disease. One of them is the electrocardiographic diastolic index (EDI), which predicts diastolic dysfunction in adult patients.²⁴

ECG interpretation difficulty in the diagnosis of STEMI has recently led to the development of a new paradigm. Occlusion myocardial infarction (OMI) definition was proposed for acute myocardial infarction patients in the ED and was compared to the diagnostic accuracy of OMI ECG findings with STEMI criteria. It was found that OMI findings were better than STEMI criteria for the ECG diagnosis.^{25,26} Our study data support the new OMI paradigm. Many patients with circumflex or D1 occlusions do not meet STEMI criteria as 2 consecutive leads. These patients could be recognized by subtle ST-segment elevation/hyperacute T-wave in V2, or ST depression in inferior leads or V2. Early recognition of ST-T difference leads to timely revascularization and limits left ventricular muscle damage. Thanks to İlkay classification, we could explain, simply, the electrocardiographic definition of lateral myocardial infarction.

Limitations

The group of patients with diagonal occlusions (14 patients) was small due to restrictive inclusion criteria. A second limitation is represented by the lack of a validation cohort which improves reproducibility. Another limitation of this paper is its retrospective nature.

Conclusion

We comprehensively classified the lateral STEMI definition through new electrocardiographic scheme. ST elevation in V2 coexisting with \geq ST depression in lead III and ≥ 10 mm higher T wave in V2 had high positive predictive values for prediction of large diagonal branch of LAD. ST elevation in V2 coexisting with < 2 mm ST depression in lead III and normal height T wave had small diagonal branch of LAD. ST-segment depression in lead V2 and ST-segment elevation in aVL had high positive predictive values for prediction of Cx proximal-OM1 occlusion. We defined this new electrocardiographic chart as Ilkay classification.

Abbreviations

Cx, left circumflex; ECG, electrocardiogram; LAD, left anterior descending; STEMI, ST-segment elevated myocardial infarction.

Impact on Daily Practice

The diagnosis of isolated lateral myocardial infarction (isolated diagonal branch or obtuse marginal) does not completely meet current myocardial infarction guidelines. This condition could cause late diagnosis and the need for revascularization therapy. Isolated lateral ventricle infarction according to diagonal branches (D1 or D2) and the obtuse marginal has not been clearly identified as electrocardiographic classification. Therefore, there is a need for a new electrocardiogram (ECG) interpretation to accurately predict acute occlusion involving the lateral region. We have improved new ECG algorithm by using angiographic and electrocardiographic correlations.

Classifications

Ilkay classification: New ECG algorithm for isolated lateral myocardial infarction.

Institutional Review Board Statement

The study protocol was accepted by Medicana International Ankara Hospital Human Research Ethics Committee (2022/19). Written informed consent was obtained from each patient. The study was conducted in accordance with the Declaration of Helsinki (as revised in 2013).

Funding

This research received no external funding.

Disclosure

As the authors of this article, all of us declare no conflict of interest.

References

1. Chan AW, Komder J, Elliott H, et al. Improved survival associated with prehospital triage strategy in a large regional ST-segment elevation myocardial infarction program. *JACC Cardiovasc Interv.* 2012;5(12):1239–1246. doi:10.1016/j.jcin.2012.07.013
2. Gulati M, Levy PD, Mukherjee D, et al. 2021 AHA/ACC/ASE/CHEST/SAEM/SCCT/SCMR guideline for the evaluation and diagnosis of chest pain: a Report of the American College of Cardiology/American Heart Association Joint Committee on Clinical Practice Guidelines. *Circulation.* 2021;144(22):e368–e454.
3. Thygesen K, Alpert JS, Jaffe AS, et al. Executive Group on behalf of the Joint European Society of Cardiology (ESC)/American College of Cardiology (ACC)/American Heart Association (AHA)/World Heart Federation (WHF) Task Force for the Universal Definition of Myocardial Infarction. Fourth universal definition of myocardial infarction (2018). *J Am Coll Cardiol.* 2018;72(18):2231–2264. doi:10.1016/j.jacc.2018.08.1038

4. Ibanez B, James S, Agewall S, et al. 2017 ESC Guidelines for the management of acute myocardial infarction in patients presenting with ST-segment elevation: the Task Force for the management of acute myocardial infarction in patients presenting with ST-segment elevation of the European Society of Cardiology (ESC). *Eur Heart J*. 2017;39(2):119–177.
5. Fiol M, Carrillo A, Cygankiewicz I, et al. A new electrocardiographic algorithm to locate the occlusion in left anterior descending coronary artery. *Clin Cardiol*. 2009;32(11):E1–6. doi:10.1002/clc.20347
6. Wang JC, Normand SL, Mauri L, Kuntz RE. Coronary artery spatial distribution of acute myocardial infarction occlusions. *Circulation*. 2004;110(2004):278–284. doi:10.1161/01.CIR.0000135468.67850.F4
7. Kobo O, Marcusohn E, Roguin A, et al. Prognosis of patients with left circumflex artery acute myocardial infarction in relation to ST-segment on admission electrocardiogram. *J Invasive Cardiol*. 2021;33(1):E20–E24.
8. Newman JD, Shimbo D, Baggett C, et al.; ARIC Study Investigators. Trends in myocardial infarction rates and case fatality by anatomical location in four United States communities, 1987 to 2008 (from the Atherosclerosis Risk in Communities Study). *Am J Cardiol*. 2013;112(11):1714–1719. doi:10.1016/j.amjcard.2013.07.037
9. Koo BK, Lee SP, Lee JH, et al. Assessment of clinical, electrocardiographic, and physiological relevance of diagonal branch in left anterior descending coronary artery bifurcation lesions. *JACC Cardiovasc Interv*. 2012;5(11):1126–1132. doi:10.1016/j.jcin.2012.05.018
10. Birnbaum Y, Hasdai D, Sclarovsky S, Herz I, Strasberg B, Rechavia E. Acute myocardial infarction entailing ST-segment elevation in lead aVL: electrocardiographic differentiation among occlusion of the left anterior descending, first diagonal, and first obtuse marginal coronary arteries. *Am Heart J*. 1996;131(1):38–42. doi:10.1016/S0002-8703(96)90048-4
11. Iwasaki K, Kusachi S, Kita T, Taniguchi G. Prediction of isolated first diagonal branch occlusion by 12-lead electrocardiography: ST segment shift in leads I and aVL. *J Am Coll Cardiol*. 1994;23(7):1557–1561. doi:10.1016/0735-1097(94)90656-4
12. Sclarovsky S, Birnbaum Y, Solodky A, Zafir N, Wurzel M, Rechavia E. Isolated mid-anterior myocardial infarction: a special electrocardiographic sub-type of acute myocardial infarction consisting of ST-elevation in nonconsecutive leads and two different morphologic types of ST depression. *Int J Cardiol*. 1994;46(1):37–47. doi:10.1016/0167-5273(94)90115-5
13. Abu Fanne R, Kleiner Shochat M, Shotan A, et al. Acute diagonal-induced ST-elevation myocardial infarction and electrocardiogram-guidance in the era of primary coronary intervention: new insights into an old tool. *Eur Heart J Acute Cardiovasc Care*. 2020;9(8):827–835. doi:10.1177/2048872619828291
14. Singh A, Dwivedi S, Pradhan A, et al. Isolated ST-elevation myocardial infarction involving leads I and aVL: angiographic and electrocardiographic correlations from a tertiary care center. *Cardiol Res Pract*. 2021;2021:7638020. doi:10.1155/2021/7638020
15. Mueller HS, Dyer A, Greenberg MA. The thrombolysis in myocardial infarction (TIMI) trial: Phase I findings. *N Engl J Med*. 1985;312:932–936.
16. Zhang S, Deng X, Yang W, et al. The diagonal branches and outcomes in patients with anterior ST-elevation myocardial infarction. *BMC Cardiovasc Disord*. 2020;20(1):108. doi:10.1186/s12872-020-01386-4
17. Monaghan M, Sreenivasan S. A Red Flag ECG. *Circulation*. 2020;142(19):1871–1874. doi:10.1161/CIRCULATIONAHA.120.050249
18. Durant E, Singh A. Acute first diagonal artery occlusion: a characteristic pattern of ST elevation in noncontiguous leads. *Am J Emerg Med*. 2015;33(9):1326.e3–5. doi:10.1016/j.ajem.2015.02.008
19. Littmann L. “South African flag sign: a teaching tool for easier ECG recognition of high lateral infarct. *Am J Emerg Med*. 2016;34(1):107–109. doi:10.1016/j.ajem.2015.10.022
20. Somers MP, Brady WJ, Perron AD, Mattu A. The prominent T wave: electrocardiographic differential diagnosis. *Am J Emerg Med*. 2002;20(3):243–251. doi:10.1053/ajem.2002.32630
21. Levis JT. ECG Diagnosis: hyperacute T Waves. *Perm J*. 2015;19(3):79. doi:10.7812/TPP/14-243
22. Lawton JS, Tamis-Holland JE, Bangalore S, et al. 2021 ACC/AHA/SCAI guideline for coronary artery revascularization: a report of the American College of Cardiology/American Heart Association Joint Committee on Clinical Practice Guidelines. *J Am Coll Cardiol*. 2022;79(2):e21–e129. doi:10.1016/j.jacc.2021.09.006
23. Lunardi M, Louvard Y, Lefèvre T, et al. Definitions and standardized endpoints for treatment of coronary bifurcations. *EuroIntervention*. 2022;80(1):63–88.
24. Hayiroğlu MI, Çınar T, Çiçek V, et al. A simple formula to predict echocardiographic diastolic dysfunction-electrocardiographic diastolic index. *Herz*. 2021;46(Suppl 2):159–165. doi:10.1007/s00059-020-04972-6
25. Pendell Meyers H, Bracey A, Lee D, et al. Accuracy of OMI ECG findings versus STEMI criteria for diagnosis of acute coronary occlusion myocardial infarction. *Int J Cardiol Heart Vasc*. 2021;33:100767. doi:10.1016/j.ijcha.2021.100767
26. McLaren JTT, Pendell Meyers H, Smith SW, Chartier LB. From STEMI to occlusion MI: paradigm shift and ED quality improvement. *Can J Emerg Med*. 2022;24(3):250–255. doi:10.1007/s43678-021-00255-z

Publish your work in this journal

The International Journal of General Medicine is an international, peer-reviewed open-access journal that focuses on general and internal medicine, pathogenesis, epidemiology, diagnosis, monitoring and treatment protocols. The journal is characterized by the rapid reporting of reviews, original research and clinical studies across all disease areas. The manuscript management system is completely online and includes a very quick and fair peer-review system, which is all easy to use. Visit <http://www.dovepress.com/testimonials.php> to read real quotes from published authors.

Submit your manuscript here: <https://www.dovepress.com/international-journal-of-general-medicine-journal>