

# Kinetics of central macular thickness reduction in patients with macular edema after intravitreal drug therapy

Lingmin He  
Annie Chan  
Theodore Leng  
Mark S Blumenkranz

Department of Ophthalmology,  
Stanford University School of  
Medicine, Stanford, California, USA

**Background:** The purpose of this study was to characterize central macular thickness and retinal volume following intravitreal injections using time domain and spectral domain optical coherence tomography (TD-OCT and SD-OCT, respectively).

**Methods:** Nine patients with macular edema secondary to diabetes or retinal vein occlusion treated with intravitreal triamcinolone 4.0 mg and/or bevacizumab 1.25 mg were enrolled. Central macular thickness and volume was measured by SD-OCT and TD-OCT scan at baseline, and 1, 3, 6, 24, 48 hours, and 1 week postinjection.

**Results:** Equations were derived to describe central macular thickness and volume reduction in the hours following intravitreal injection. Measurements of central macular thickness by SD-OCT were significantly reduced by 3 hours ( $P = 0.03$ ) and retinal volume by 6 hours ( $P = 0.03$ ). Central macular thickness measured 40.9 (28.6–53.2)  $\mu\text{m}$  thicker on the SD-OCT instrument while volume measured 3.47 (3.27–3.66)  $\text{mm}^3$  higher.

**Conclusion:** Significant central macular thickness and volume reductions occur in the first hours after injection with triamcinolone and/or bevacizumab.

**Keywords:** retinal vein occlusion, intravitreal injection, diabetic retinopathy

## Introduction

Diabetic retinopathy and retinal vein occlusion are the leading causes of vision loss in working aged adults due to retinal vascular abnormalities.<sup>1–3</sup> Macular edema is a major common pathway for vision loss in both these diseases.<sup>4</sup> Laser photocoagulation has been the mainstay of treatment for both diabetic macular edema and macular edema secondary to branch but not central retinal vein occlusion.<sup>3,5–7</sup> However, recent studies have shown that intravitreal delivery of corticosteroids and anti-vascular endothelial growth factor (VEGF) agents can provide significant visual benefits for branch and central retinal vein occlusion.<sup>8–12</sup>

The corticosteroid most often used for intravitreal injections is triamcinolone because of its long therapeutic response of up to 3 months.<sup>13</sup> Ranibizumab (rhuFab V2, Lucentis<sup>®</sup>, Genentech, South San Francisco, CA) is the affinity-matured anti-VEGF antibody recently approved for retinal vein occlusion.<sup>11,12</sup> The full-length antibody, bevacizumab (Avastin<sup>®</sup>, Genentech, South San Francisco, CA), is commonly used off-label.<sup>14</sup> These agents are effective in improving visual acuity and reducing macular edema associated with diabetic retinopathy and retinal vein occlusion in prospective randomized trials.<sup>15–23</sup> However, a durable effect is often not achieved, with macular edema recurring after several months, and retreatment is required.<sup>18,24</sup> When both triamcinolone and bevacizumab were used in a combined injection, visual

Correspondence: Mark S Blumenkranz  
300 Pasteur Drive A-157, Stanford,  
CA 94305, USA  
Tel +1 650 323 0231  
Fax +1 650 323 6385  
Email mark.blumenkranz@stanford.edu

improvement was faster but the added benefit disappeared in longer follow-up.<sup>25</sup> Compared with laser photocoagulation, intravitreal injections may be more effective in the months after intervention, but laser may offer better visual outcomes in the following years.<sup>26,27</sup> A recent trial suggests that a combined therapeutic approach using intravitreal ranibizumab or triamcinolone injections for their short-term effects and laser for long-term control may be optimal.<sup>28</sup> However, the most cost-effective and convenient approach from both the patient and physician perspective remains unclear.

A better understanding of the immediate effects of these drugs would provide insight into their mechanisms of action and could lead to the development of more targeted and effective treatments. Additionally, it may help clarify the role of each type of therapeutic intervention, elucidating the optimal dosing regimens for patients. This pilot study used spectral domain optical coherence tomography (SD-OCT) to characterize short-term changes in macular thickness in the first hours and days following a single intravitreal injection of one or both of these agents, and investigated potential measurement differences between two widely used OCT methods, ie, SD-OCT and time domain OCT (TD-OCT).

## Materials and methods

The research protocol for this observational study was approved by the Stanford University School of Medicine Institutional Review Board. A total of 45 patients with macular edema secondary to either diabetic retinopathy or retinal vein occlusion were identified by computerized review of patient records and were asked to participate in the study between November and December 2008. Patients who were pregnant were excluded from the study, as were children. An initial power calculation using a power of 80%

and significance level of 0.05 indicated that approximately 10 patients were needed to determine a central macular thickness difference of 90  $\mu\text{m}$  with a standard deviation of 100  $\mu\text{m}$ , as had been shown in previous studies.<sup>25,29</sup> A total of nine patients were able to be enrolled during the study period, of which six were treated with intravitreal triamcinolone 4.0 mg alone (including five with diabetic macular edema). Of the four patients with retinal vein occlusion, one had branch vein occlusion and three had central vein occlusion. The patient with branch retinal vein occlusion received bevacizumab 1.25 mg. For the three patients with central retinal vein occlusion, one received triamcinolone 4.0 mg, one received bevacizumab 1.25 mg, and one received both agents simultaneously. The clinical judgment of the treating physician determined the type of injection given to the patients; all had previously received some sort of intravitreal injection. A summary of each patient's disease process and injection received can be found in Table 1.

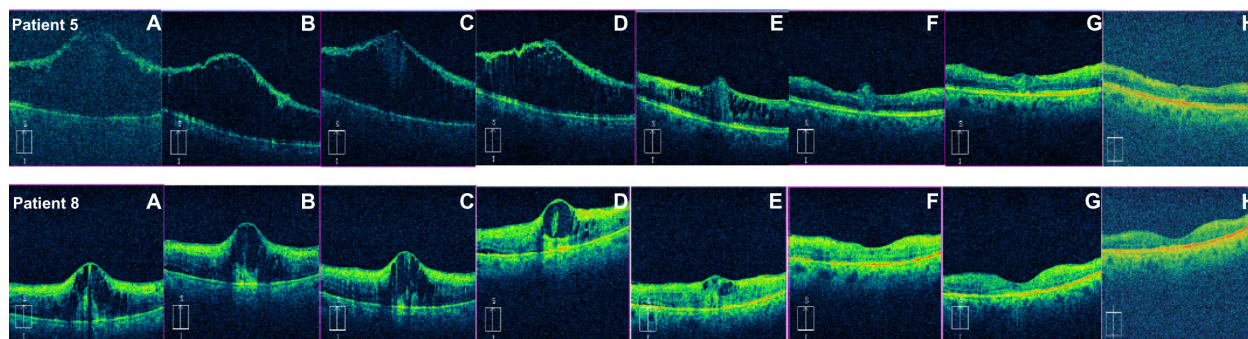
Imaging was performed using TD-OCT (Stratus OCT Software Version 5.0 Carl Zeiss Meditec, Dublin, CA) and SD-OCT (Cirrus HD-OCT Software Version 3.0; Carl Zeiss Meditec) prior to injection and then at 1 hour, 3 hours, 6–9 hours, 1 day, 2 days, and 1 week after injection. A six-line fast macular scanning protocol was used for the TD-OCT device and a 512  $\times$  128 macular cube protocol was used for the SD-OCT device. Snellen visual acuity with pinhole was recorded before each scan. Additional SD-OCT scans were obtained from seven patients at their final visit 4–6 weeks later. Figure 1 shows an example of the SD-OCT images collected for patients 5 and 8. After the first patient, the following four patients with diabetic retinopathy had imaging performed on both eyes so that the fellow (noninjected) eye could serve as a control for any fluctuations in levels of macular edema.

**Table 1** Summary of disease process, injection, visual acuity, and calculated coefficient for exponential decline in macular edema in enrolled patients 48 hours after treatment

Patient	Disease	Drug	Baseline VA	VA after 1 week	Baseline CMT ( $\mu\text{m}$ )	CMT after 48 hours	CMT after 1 week	Coefficient (per hour)	R <sup>2</sup>	95% CI (per hour)
1	D*	T	20/400 +1	20/400 +1	706	528	459	-0.007	0.97	-0.009 to -0.005
2	D*	T	20/100	20/70 -2	271	271	253	0.002	0.03	-0.005 to 0.009
3	CV	T, B	20/150	20/100 +1	697	318	250	-0.013	0.74	-0.025 to -0.001
4	BV*	B	20/40 +2	20/20	377	292	285	-0.010	0.67	-0.021 to 0.001
5	CV	T	CF at 2 feet	CF at 6 feet	1141	266	251	-0.036	1.00	-0.040 to -0.032
6	D	T	20/100 +1	20/40 +1	737	479	347	-0.005	0.94	-0.007 to -0.003
7	D*	T	20/40 +1	20/25 -2	408	358	360	-0.005	0.94	-0.006 to 0.03
8	CV	B	CF at 4 feet	CF at 6 feet	716	258	164	-0.025	0.99	-0.029 to 0.020
9	D*	T	20/80	20/70 -2	529	468	420	-0.002	0.43	-0.005 to 0.001

**Notes:** Baseline CMT measurements are given from SD-OCT. \*Indicates that patient also had an epiretinal membrane.

**Abbreviations:** D, diabetes mellitus; CF, count fingers; CV, central retinal vein occlusion; BV, branch retinal vein occlusion; T, triamcinolone 4 mg; B, bevacizumab 1.25 mg; CI, confidence interval; VA, visual acuity; CMT, central macular thickness; SD-OCT, spectral domain optical coherence tomography.



**Figure 1** Representative spectral domain optical coherence tomography scans from two patients showing the macula at (A) prior to intravitreal injection, (B) 1 hour, (C) 3 hours, (D) 6–9 hours, (E) 24 hours, (F) 48 hours, (G) 1 week, and (H) 1 month following injection. Patient 5 (top) received an injection of triamcinolone 4.0 mg while patient 8 (bottom) received bevacizumab 1.25 mg.

Software-generated measurements for central subfield mean thickness were recorded as central macular thickness. Central macular thickness and macular volume measurements at each time point were plotted and fitted to both an exponential and linear regression model to determine the rate of reduction in the first 24 and 48 hours after injection. Results for each individual patient were then averaged to generate a mean and confidence interval for the measurement. Individual scans on the SD-OCT instrument were reviewed and any abnormalities in the segmentation software that would have resulted in incorrect calculations of central macular thickness and macular volume were manually corrected using the analysis software for two of the 91 scans collected in this study. Lines from the TD-OCT scans with gross errors in automated segmentation were discarded, because the review software did not have an editing feature. Paired *t*-tests were used to determine the time at which the reduction in central macular thickness and macular volume became significant. Data were analyzed for each injection type and disease process separately, and also for all nine patients together using the Analyse-It software program (Analyse-It Software, Leeds, UK). Both percent and absolute changes are reported because it has been shown that absolute changes in thickness are the preferred measure in mild thickening, and relative change is preferred in more severe thickening.<sup>30</sup> The mean difference in central macular thickness and volume measurements from both instruments were compared to determine if a systematic difference in measurement existed for patients with macular edema.

## Results

The mean age of the patients in this study was 70.6 (55–82) years; six were female and three were male. Table 1 summarizes the disease, injection type, and visual acuity for each patient, as well as the extent to which they

could be fit to a regression model. Baseline visual acuity was correlated with central macular thickness, with a linear coefficient of 0.68. When central macular thickness was tracked over time, correlation coefficients were uniformly higher for exponential than for linear regressions, and only the exponential coefficients are displayed. All patients except patient 1 displayed some improvement in visual acuity in the first week after their intravitreal injection. All patients except for patient 2 showed a negative correlation coefficient, indicating an exponential reduction in central macular thickness during the first 48 hours following an injection. Patient 2 (regression coefficient 0.002 per hour) also had the lowest correlation coefficient ( $R^2 = 0.03$ ). Five patients had correlation coefficients greater than 0.9 (patient 1 and patients 5–8), and of these, two were perfectly described by an exponential function (patients 5 and 8). One of the remaining patients had a correlation coefficient less than 0.5 (patient 9), while the coefficient for the other two was approximately 0.7 (patients 3 and 4). The aggregate data for all patients by injection and by disease process medication is shown in Table 2. When separated into subgroups, the confidence intervals for the coefficient of reduction in central macular thickness include 0. However, when the patients are analyzed together, the exponential coefficient of reduction was  $-0.010$  ( $-0.018$  to  $-0.002$ ) per hour ( $R^2 = 0.83$ ). Figure 2 is a graphical representation of the central macular thickness for each patient in the first 48 hours after their injection.

Volume measurements were more poorly described by both exponential and linear regression models, although again the exponential regression produced higher correlation coefficients. Four patients had correlation coefficients less than 0.5. Three patients had correlation coefficients between 0.7 and 0.9 (patients 3, 6, and 8) and two patients had correlation coefficients greater than 0.9 (patients 1 and 5). Again, the confidence interval included 0 when patients were separated by

**Table 2** Exponential regression coefficients for the first 48 hours after injection shown for all patients combined and also divided by treatment and by disease process

	Coefficient of reduction (per hour)	Average R <sup>2</sup>	95% CI (per hour)
All injections combined (n = 9)	-0.010	0.83	-0.018 to -0.002
Triamcinolone 4 mg (n = 6)	-0.008	0.78	-0.020 to 0.004
Bevacizumab 1.25 mg (n = 2)	-0.014	0.74	-0.111 to 0.083
Diabetic retinopathy (n = 5)	-0.004	0.69	-0.001 to 0.003
Retinal vein occlusion (n = 4)	-0.018	0.90	-0.085 to 0.049

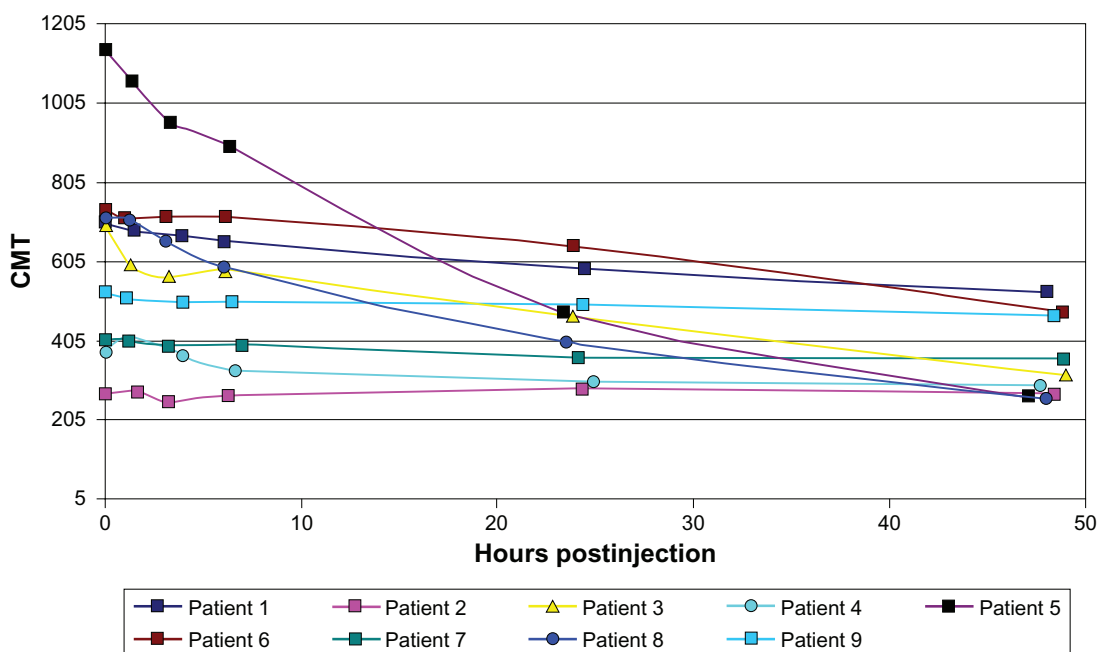
**Abbreviation:** CI, confidence interval.

injection type and disease process, but when all the data were combined, the average exponential coefficient of reduction was -0.005 (-0.009 to -0.0002) per hour (R<sup>2</sup> = 0.34).

Table 3 displays the mean reduction in central macular thickness in the hours to days after intravitreal injections measured by both the TD-OCT and SD-OCT devices. A statistically significant reduction was found by the SD-OCT instrument starting at 3 hours after injection (P = 0.027) and persisted throughout the following period. By 48 hours, the mean reduction in central macular thickness was 260.44 (46.41–474.47) μm (33.51%). This accounted

for 80% of the eventual reduction achieved in a week, ie, 310.33 (88.56–532.11) μm (41.17%). However, on the TD-OCT instrument, a significant reduction was not seen until 24 hours (P = 0.035) or longer after injection. At 48 hours after injection, the mean reduction was 259.78 (72.75–446.81) μm (37.92%) or 90% of the reduction achieved at 1 week. When the data were separated by injection types, the statistical significance disappeared for scans taken from both machines as the group sizes were not powered to detect a difference. Additionally, when the data were separated by disease process as shown in Table 4, there was a significant difference in central macular thickness starting at 3 hours for patients with diabetic retinopathy and 6 hours for those with retinal vein occlusion (P = 0.003, P = 0.048, respectively). However, this difference between the groups was no longer significant after 24 hours, although the mean difference continued to grow larger. No significant trends were observed in the four diabetic patients whose fellow eyes with macular edema were also scanned as a control for variations in macular edema as the natural progression or fluctuation of the disease.

Reductions in macular volume were also evaluated and showed similar trends. The reduction in volume seen on SD-OCT scans reached statistical significance at 6 hours (P = 0.031), while the mean difference was 0.89 (0.11–1.67) mm<sup>3</sup> (5.42%). At 48 hours, volume reduction was 3.20 (0.27–6.13) mm<sup>3</sup> (17.90%). This was over 80% of the



**Figure 2** Reduction in central macular thickness in the first 48 hours after injection. **Abbreviation:** CMT, central macular thickness.

**Table 3** Pooled data for mean reduction (n = 9) in central macular thickness compared with baseline measurements made before injection on both SD-OCT and TD-OCT instruments

Time postinjection	Mean reduction in SD-OCT ( $\mu\text{m}$ )	95% CI	P value	Mean reduction in TD-OCT ( $\mu\text{m}$ )	95% CI	P value
0 hours <sup>a</sup>	620.22	–	–	574.56	–	–
1 hour	22.44	–9.82 to 174.45	0.147	42.33	–8.49 to 209.92	0.091
3 hours	55.22	8.22 to 102.23	0.027*	50.44	–36.75 to 137.64	0.219
6 hours	71.56	11.85 to 131.26	0.025*	75.00	–7.93 to 157.93	0.071
24 hours	173.67	12.42 to 334.92	0.038*	171.56	15.73 to 327.38	0.035*
48 hours	260.44	46.41 to 474.47	0.023*	259.78	72.75 to 446.81	0.013*
1 week	310.33	88.56 to 532.11	0.012*	285.56	91.48 to 479.63	0.010*

**Notes:** <sup>a</sup>Value reported at 0 hours is the mean central macular thickness of all patients at baseline; \* $P < 0.05$ .

**Abbreviations:** CI, confidence interval; SD-OCT, spectral domain optical coherence tomography; TD-OCT, time domain optical coherence tomography.

reduction in volume reached in 1 week, 3.88 (0.85–6.91)  $\text{mm}^3$  (22.21%). The TD-OCT instrument did not show a significant change until 24 hours after the injection ( $P = 0.041$ ). Similar to the SD-OCT scans, at 48 hours after injection, volume was reduced by 3.39 (0.74–6.04)  $\text{mm}^3$  (25.08%). This was over 80% of the reduction in volume achieved in a week, ie, 3.10 (0.10–6.09)  $\text{mm}^3$  (21.80%). When analyzed separately by type of injection and by disease, none of the reductions in macular volume were statistically significant.

Compared with the CMT measurements made by the TD-OCT instrument, SD-OCT measurements were on average 40.9 (28.6–53.2)  $\mu\text{m}$  thicker (n = 84, all scans). The SD-OCT instrument also calculated a greater volume, on average 3.47 (3.27–3.66)  $\text{mm}^3$  higher than TD-OCT data.

## Discussion

The results reported here indicate that the reduction in central macular thickness occurs rapidly in the first few hours after intravitreal drug injection and generally follows an exponential rather than linear decay. This suggests that the drugs may immediately change the permeability of the retinal pigment epithelium to fluid movement or can recruit pumps to expel accumulated proteins and fluid actively. The rate of

reduction in central macular thickness is best described by the following exponential function:

$$[\text{Central macular thickness} = \text{baseline central macular thickness} * \exp(-0.01/\text{hour} * \text{postinjection})]$$

Volume measurement data were less consistent, but can be described by the equation:

$$[\text{Volume} = \text{baseline volume} * \exp(-0.006/\text{hour} * \text{postinjection})]$$

Prior studies by Marmor have determined 0.1  $\mu\text{L}/\text{hour}/\text{mm}^2$  to be the rate at which the retinal pigment epithelium is capable of pumping out fluid, or an expected reduction of 0.1  $\text{mm}^3/\text{hour}$  in the 1  $\text{mm}^2$  space of measurement for central macular thickness.<sup>31</sup> Even higher flow rates are achievable when the retina is damaged, like in retinal detachments, and passive transport is the predominant force driving fluid movement.<sup>31</sup> Our study found a linear rate of reduction of  $-0.066 \text{ mm}^3/\text{hour}$  or an exponential coefficient  $-0.0005$  per hour, a very similar rate to the one reported previously. This suggests that intravitreal triamcinolone and bevacizumab injections may be enhancing some mechanism of active transport to cause efflux of macular edema fluid. Blood retinal

**Table 4** Data for mean reduction in central macular thickness compared with baseline measurements before injection in patients with diabetic retinopathy or retinal vein occlusion

Time postinjection	Mean reduction in DR, n = 5 ( $\mu\text{m}$ )	95% CI	P value	Mean reduction in RVO, n = 4 ( $\mu\text{m}$ )	95% CI	P value
0 hours <sup>a</sup>	530.2	–	–	732.75	–	–
1 hour	11.0	–3.4 to 25.4	0.101	36.8	–64.3 to 137.8	0.331
3 hours	23.0	13.1 to 32.9	0.003*	95.5	–27.7 to 218.7	0.090
6 hours	22.6	2.2 to 43	0.037*	132.8	2.1 to 263.4	0.048*
24 hours	56.0	–8.1 to 120.1	0.072	320.8	–75.1 to 716.6	0.082
48 hours	109.4	–21.8 to 240.6	0.082	449.3	–69.6 to 968.1	0.070
1 week	162.4	–29.7 to 354.5	0.079	495.3	–27.7 to 1018.2	0.057

**Notes:** <sup>a</sup>Value reported at 0 hours is the mean CMT of all patients at baseline; \* $P < 0.05$ .

**Abbreviations:** CI, confidence interval; DR, diabetic retinopathy; RVO, retinal vein occlusion.

junctions in this case are likely intact and passive forces do not come into play.

The focus of previous pharmacokinetic studies has been the period of time in which an agent remains in the vitreous. Studies of high-dose triamcinolone injections (20–25 mg) showed that the steroid is still detectable in eyes without prior vitrectomy even a year and a half after the injection, and for 3 or more months afterwards in eyes that had undergone vitrectomy.<sup>24,32,33</sup> Bevacizumab 1.5 mg has been shown to have an aqueous half-life of 9.8 days.<sup>34</sup> Given the different rates of clearance of these agents, it seems worthwhile to compare the rates at which they act in the initial period. It has been hypothesized that corticosteroids may act by inhibiting the VEGF gene or by modulating the effector proteins related to the VEGF signaling pathway.<sup>13</sup> A similar drug effect time would be evidence in support of the two agents affecting a common pathway. The results in this study suggest that this is possibly the case; the rates of reduction in macular edema are likely to be comparable between patients receiving intravitreal triamcinolone and bevacizumab.

This study also reveals that significant reductions in both central macular thickness and macular volume occur as early as the first 6 hours after an intravitreal injection. While study enrollment was insufficiently powered to detect differences in patients receiving triamcinolone 4.0 mg alone or bevacizumab 1.25 mg alone, the pooled data strongly suggest that a robust change occurred rapidly in the injected eyes. When the data were separated by disease process, an initially significant change at 3 and 6 hours occurred, but because of the lack of power and increase in variance, the calculations after 24 hours were no longer significant, even though the mean difference grew larger. After 1 week, patients on average saw a reduction of 41% in their central macular thickness, with over half of this change occurring in the first day and 80% of the change by 48 hours. Further, patients generally had an improvement in Snellen visual acuity measured at these visits. Only patient 1 experienced no change in visual acuity, despite having a dramatic reduction in her central macular thickness from 706  $\mu\text{m}$  to 459  $\mu\text{m}$ . However, she had long-standing, poorly controlled disease previously treated with vitrectomy and extensive peripheral ischemia on fluorescein angiography, severely limiting her visual potential. Previous studies have shown that patients with ischemic central retinal vein occlusion do not respond to triamcinolone injections, while those with nonischemic central retinal vein occlusion do respond.<sup>18</sup> It may be that the degree of ischemic damage already incurred in the retina is

the limiting factor for response. Only patient 2 experienced no reduction in central macular thickness, although he did have an improvement in visual acuity. He did not have extensive areas of ischemia by fluorescein angiography. He did start with a relatively more normal central macular thickness measurement (271  $\mu\text{m}$ ) which left relatively little headroom for a statistically significant decrease in central macular thickness compared with the other eight patients, all of whom had considerably larger starting values for central macular thickness. Studies have also shown that the link between visual acuity and macular thickness may be tenuous, with only a modest correlation between best corrected visual acuity and macular thickness.<sup>35,36</sup>

It is also interesting to note that patient 2 had a correlation coefficient of 0.03 when fit to an exponential curve and patient 9 had a correlation of 0.43. This suggests that there may be infrequent nonresponders to triamcinolone 4.0 mg injections. Because there were only two patients who received bevacizumab 1.25 mg injections, it is difficult to determine whether this phenomenon is also true for that drug, although there is anecdotal evidence for this phenomenon in some diabetic patients, at least for single injections. This effect will be important to understand in order to optimize treatment schedules for patients and eliminate injections that do not benefit patients. The results of this study indicate that responders to treatment would likely show a change within hours of the injection. Future studies can evaluate if a strategy of remeasuring central macular thickness within 24–48 hours and choosing an alternative agent in nonresponders would lead to better resolution of macular edema and improved visual outcomes. A study with longer follow-up would also be helpful to evaluate whether the initial response is predictive of long-term sustainability of the reduction in macular edema.

Previous studies and meta-analyses have determined that patients often see an improvement in the months following an injection, and many need repeated injections for a sustained effect.<sup>20,37</sup> A 2007 DRCRnet study showed that patients receiving bevacizumab 1.25 mg and 2.25 mg injections had greater reductions in central macular thickness than those who received laser treatment. These patients also had better improvements in visual acuity at 12 weeks with no short-term benefits of combining laser and bevacizumab injections.<sup>38</sup> Laser photocoagulation was also shown to be less effective than triamcinolone 4.0 mg injections in the short term, but the effect was no longer present at 1 year and even reversed later, with patients receiving laser having better visual outcomes after 2 years.<sup>26,27</sup> Based on those results and the preliminary

results generated from this study, similar mechanisms may be activated by both injection types.

It is possible that the effects of triamcinolone are more short-term than those of bevacizumab, but this is yet to be shown in a prospective comparison. Overall, it appears that intravitreal injections of anti-VEGF agents and corticosteroids could be used for their short-term effects (days and weeks) to reduce macular edema to a level at which laser photocoagulation can be considered to achieve long-term control (years and more). A recent DRCRnet study was performed to evaluate the efficacy of such a combination approach, using intravitreal triamcinolone or ranibizumab injections for their short-term effects and laser for long-term control. Participants were randomized to sham injection and prompt laser, ranibizumab 0.5 mg and prompt laser, ranibizumab 0.5 mg and delayed laser, or triamcinolone 4.0 mg and prompt laser. Patients who received drug injections and laser treatments had more reduction in central macular thickness than those who received sham injections and laser after one and 2 years.<sup>28</sup>

Since the initiation of this study, more work has been done to understand the measurement differences between the Stratus and the Cirrus OCT systems. Kiernan et al found that in conditions of increased macular thickness, the thickness measured by the Cirrus is 43  $\mu\text{m}$  greater than the Stratus, likely due to measurement differences built into the detection algorithms of the machines.<sup>39</sup> Our study showed a similar increase in thickness of 40.9  $\mu\text{m}$  and a volume of 3.47 (3.27–3.66)  $\mu\text{m}^3$  higher.

The conclusions able to be drawn from this study are limited by the small sample size. While 45 patients were approached to participate, only nine were enrolled because of the time commitment on the day of injection and for follow-up visits. However difficult the recruitment, it would be valuable to pursue future investigations involving more patients receiving each type of injection and underlying disease processes. An effective treatment strategy could be determined more rapidly because it appears that patients who are destined to respond to treatment are likely to declare themselves within the first 24 hours after receiving an intravitreal injection of triamcinolone or bevacizumab. Additionally, further studies could lead to new insights into the mechanism of action of different therapies for macular edema, paving the way for the development of more targeted therapeutics.

## Acknowledgment

This research was partially supported by an equipment loan from Carl Zeiss Meditech Inc, Dublin, CA.

## Disclosure

This study was presented in part at the meeting of the Association for Research in Vision and Ophthalmology, Fort Lauderdale, FL, May 2–6, 2010. None of the authors have any proprietary interest in any of the products used in this study.

## References

1. Rogers S, McIntosh RL, Cheung N, et al. The prevalence of retinal vein occlusion: pooled data from population studies from the United States, Europe, Asia, and Australia. *Ophthalmology*. 2010;117(2):313–319.
2. Argon laser photocoagulation for macular edema in branch vein occlusion. The Branch Vein Occlusion Study Group. *Am J Ophthalmol*. 1984;98(3):271–282.
3. McIntosh RL, Mohamed Q, Saw SM, Wong TY. Interventions for branch retinal vein occlusion: an evidence-based systematic review. *Ophthalmology*. 2007;114(5):835–854.
4. Wilkinson-Berka JL, Miller AG. Update on the treatment of diabetic retinopathy. *Scientific World Journal*. 2008;8:98–120.
5. Schachat AP. A new approach to the management of diabetic macular edema. *Ophthalmology*. 2010;117(6):1059–1060.
6. Mohamed Q, McIntosh RL, Saw SM, Wong TY. Interventions for central retinal vein occlusion: an evidence-based systematic review. *Ophthalmology*. 2007;114(3):507–519.
7. Karia N. Retinal vein occlusion: pathophysiology and treatment options. *Clin Ophthalmol*. 2010;4:809–816.
8. Haller JA, Bandello F, Belfort R Jr, et al. Randomized, sham-controlled trial of dexamethasone intravitreal implant in patients with macular edema due to retinal vein occlusion. *Ophthalmology*. 2010;117(6):1134–1146.
9. Ip MS, Scott IU, Van Veldhuisen PC, et al. A randomized trial comparing the efficacy and safety of intravitreal triamcinolone with observation to treat vision loss associated with macular edema secondary to central retinal vein occlusion: the Standard Care vs Corticosteroid for Retinal Vein Occlusion (SCORE) study report 5. *Arch Ophthalmol*. 2009;127(9):1101–1114.
10. Scott IU, Ip MS, Van Veldhuisen PC, et al. A randomized trial comparing the efficacy and safety of intravitreal triamcinolone with standard care to treat vision loss associated with macular edema secondary to branch retinal vein occlusion: the Standard Care vs Corticosteroid for Retinal Vein Occlusion (SCORE) study report 6. *Arch Ophthalmol*. 2009;127(9):1115–1128.
11. Brown DM, Campochiaro PA, Singh RP, et al. Ranibizumab for macular edema following central retinal vein occlusion: six-month primary end point results of a phase III study. *Ophthalmology*. 2010;117(6):1124–1133.
12. Campochiaro PA, Heier JS, Feiner L, et al. Ranibizumab for macular edema following branch retinal vein occlusion: six-month primary end point results of a phase III study. *Ophthalmology*. 2010;117(6):1102–1112.
13. Sivaprasad S, McCluskey P, Lightman S. Intravitreal steroids in the management of macular oedema. *Acta Ophthalmol Scand*. 2006;84(6):722–733.
14. Pieramici DJ, Rabena MD. Anti-VEGF therapy: comparison of current and future agents. *Eye (Lond)*. 2008;22(10):1330–1336.
15. Ip M, Kahana A, Altaweel M. Treatment of central retinal vein occlusion with triamcinolone acetonide: an optical coherence tomography study. *Semin Ophthalmol*. 2003;18(2):67–73.
16. Park CH, Jaffe GJ, Fekrat S. Intravitreal triamcinolone acetonide in eyes with cystoid macular edema associated with central retinal vein occlusion. *Am J Ophthalmol*. 2003;136(3):419–425.

17. Bashshur ZF, Maluf RN, Allam S, Jurdi FA, Haddad RS, Noureddin BN. Intravitreal triamcinolone for the management of macular edema due to nonischemic central retinal vein occlusion. *Arch Ophthalmol*. 2004;122(8):1137–1140.
18. Ip MS, Gottlieb JL, Kahana A, et al. Intravitreal triamcinolone for the treatment of macular edema associated with central retinal vein occlusion. *Arch Ophthalmol*. 2004;122(8):1131–1136.
19. Astam N, Batioglu F, Ozmert E. Short-term efficacy of intravitreal bevacizumab for the treatment of macular edema due to diabetic retinopathy and retinal vein occlusion. *Int Ophthalmol*. 2009;29(5):343–348.
20. Grover D, Li TJ, Chong CC. Intravitreal steroids for macular edema in diabetes. *Cochrane Database Syst Rev*. 2008;1:CD005656.
21. Gunduz K, Bakri SJ. Intravitreal bevacizumab for macular oedema secondary to branch retinal vein occlusion. *Eye (Lond)*. 2008;22(9):1168–1171.
22. Hauser D, Bukelman A, Pokroy R, et al. Intravitreal triamcinolone for diabetic macular edema: comparison of 1, 2, and 4 mg. *Retina*. 2008;28(6):825–830.
23. Yilmaz T, Weaver CD, Gallagher MJ, et al. Intravitreal triamcinolone acetate injection for treatment of refractory diabetic macular edema: a systematic review. *Ophthalmology*. 2009;116(5):902–911.
24. Jermak CM, Dellacroce JT, Heffez J, Peyman GA. Triamcinolone acetate in ocular therapeutics. *Surv Ophthalmol*. 2007;52(5):503–522.
25. Ahmadieh H, Ramezani A, Shoeibi N, et al. Intravitreal bevacizumab with or without triamcinolone for refractory diabetic macular edema; a placebo-controlled, randomized clinical trial. *Graefes Arch Clin Exp Ophthalmol*. 2008;246(4):483–489.
26. Diabetic Retinopathy Clinical Research Network. A randomized trial comparing intravitreal triamcinolone acetate and focal/grid photocoagulation for diabetic macular edema. *Ophthalmology*. 2008;115(9):1447–1449.
27. Beck RW, Edwards AR, Aiello LP, et al. Three-year follow-up of a randomized trial comparing focal/grid photocoagulation and intravitreal triamcinolone for diabetic macular edema. *Arch Ophthalmol*. 2009;127(3):245–251.
28. Elman MJ, Aiello LP, Beck RW, et al. Randomized trial evaluating ranibizumab plus prompt or deferred laser or triamcinolone plus prompt laser for diabetic macular edema. *Ophthalmology*. 2010;117(6):1064–1077.
29. Soheilian M, Ramezani A, Bijanzadeh B, et al. Intravitreal bevacizumab (Avastin) injection alone or combined with triamcinolone versus macular photocoagulation as primary treatment of diabetic macular edema. *Retina*. 2007;27(9):1187–1195.
30. Browning DJ, Glassman AR, Aiello LP, et al. Optical coherence tomography measurements and analysis methods in optical coherence tomography studies of diabetic macular edema. *Ophthalmology*. 2008;115(8):1366–1371.
31. Marmor MF. Control of subretinal fluid and mechanisms of serous detachment. In: Marmor MF, Wolfensberger TJ, editors. *The Retinal Pigment Epithelium: Function and Disease*. New York, NY: Oxford University Press; 1998.
32. Kosobucki BR, Freeman WR, Cheng L. Photographic estimation of the duration of high dose intravitreal triamcinolone in the vitrectomized eye. *Br J Ophthalmol*. 2006;90(6):705–708.
33. Jonas JB. Intraocular availability of triamcinolone acetate after intravitreal injection. *Am J Ophthalmol*. 2004;137(3):560–562.
34. Krohne TU, Eter N, Holz FG, Meyer CH. Intraocular pharmacokinetics of bevacizumab after a single intravitreal injection in humans. *Am J Ophthalmol*. 2008;146(4):508–512.
35. Browning DJ, Glassman AR, Aiello LP, et al. Relationship between optical coherence tomography-measured central retinal thickness and visual acuity in diabetic macular edema. *Ophthalmology*. 2007;114(3):525–536.
36. Blumenkranz MS, Haller JA, Kuppermann BD, et al. Correlation of visual acuity and macular thickness measured by optical coherence tomography in patients with persistent macular edema. *Retina*. 2010;30(7):1090–1094.
37. Khurana RN, Do DV, Nguyen QD. Anti-VEGF therapeutic approaches for diabetic macular edema. *Int Ophthalmol Clin*. 2009;49(2):109–119.
38. Scott IU, Edwards AR, Beck RW, et al. A phase II randomized clinical trial of intravitreal bevacizumab for diabetic macular edema. *Ophthalmology*. 2007;114(10):1860–1867.
39. Kiernan DF, Hariprasad SM, Chin EK, Kiernan CL, Rago J, Mieler WF. Prospective comparison of cirrus and stratus optical coherence tomography for quantifying retinal thickness. *Am J Ophthalmol*. 2009;147(2):267–275.

## Clinical Ophthalmology

### Publish your work in this journal

Clinical Ophthalmology is an international, peer-reviewed journal covering all subspecialties within ophthalmology. Key topics include: Optometry; Visual science; Pharmacology and drug therapy in eye diseases; Basic Sciences; Primary and Secondary eye care; Patient Safety and Quality of Care Improvements. This journal is indexed on

Submit your manuscript here: <http://www.dovepress.com/clinical-ophthalmology-journal>

Dovepress

PubMed Central and CAS, and is the official journal of The Society of Clinical Ophthalmology (SCO). The manuscript management system is completely online and includes a very quick and fair peer-review system, which is all easy to use. Visit <http://www.dovepress.com/testimonials.php> to read real quotes from published authors.