

Does Veritas[®] play a role in breast reconstruction? a case report

Alessandro Borgognone
Tommaso Anniboletti
Francesco De Vita

Department of Plastic and
Reconstructive Surgery,
CTO Hospital, Rome, Italy

Abstract: To reduce operative times and surgical complications in implant-based breast reconstruction, many authors advocate the use of exogenous material (modified xenograft) to support tissue regeneration. In this article, a case is presented in which a bovine collagen patch (Veritas[®] Collagen Matrix; Synovis Surgical Innovations, St Paul, MN) was used in the immediate breast reconstruction with an implant. The good results obtained in this case confirm Veritas[®] as a viable alternative to AlloDerm[®] Regenerative Tissue Matrix (LifeCell Corporation, Branchburg, NJ) and further support its ability to sustain and stimulate recovery of the surrounding tissues.

Keywords: Veritas[®], implant-based, breast reconstruction, bovine collagen, patch

Introduction

To reduce operative times and surgical complications in implant-based breast reconstruction, many authors advocate the use of exogenous material to support tissue regeneration. Until recently, cadaveric dermal allograft (AlloDerm[®] Regenerative Tissue Matrix; LifeCell Corporation, Branchburg, NJ) has been widely used.¹ More readily available and reliable, Veritas[®] Collagen Matrix (Synovis Surgical Innovations, St Paul, MN) is derived from the noncross-linked propylene oxide-treated acellular collagen matrix from bovine pericardium. The cost of each 8 × 14-cm patch is approximately €1800 (€3600 for two reconstructions), which is similar to the cost of AlloDerm[®].² The use of Veritas[®] as a biological substitute has been widely reported, and several studies have confirmed its efficacy.^{3,4} In this article, a case is presented in which a bovine collagen patch was used in the immediate breast reconstruction with an implant.

Materials and methods

A method was needed that would protect the implant on the inferior pole as well as reduce the risk of infection and wound dehiscence from the tight contact with the devascularized subcutaneous tissue of the thin inferior breast flap. Furthermore, immediate and definitive fill of the void tissue space at the inferior pole of the breast was required.

A 37-year-old woman was referred to us for immediate reconstruction after nipple-sparing mastectomy, which was carried out through the inframammary fold. She was small breasted and the mastectomy was particularly devascularizing, with interruption of the inferior pole vasculature.

The immediate reconstruction was carried out through the inframammary fold and involved a bilateral submuscular pocket, a bilateral teardrop textured implant

Correspondence: Alessandro Borgognone
Department of Plastic and Reconstructive
Surgery, CTO Hospital, Via San Nemesio
21, Rome 00145, Italy
Tel +39 0651003858
Fax +39 066782428
Email borgognone@gmail.com

(Natrelle™ 510 FX-350; Allergan Inc, Irvine, CA), and two 8 × 14-cm patches of bovine pericardium collagen matrix to complete the inferior pole of the pocket. Both patches were sewn with polydioxanone 4/0 continuous running sutures (PDS II, Ethicon Inc, Somerville, NJ) and a few cardinal stitches. The suture was located between the free-floating inferomedial edge of the pectoralis major and the serratus anterior laterally and medially at the level of the inframammary fold attachment to the muscular rectus fascia. The resultant pocket was left open at the level of the serratus anterior and pectoralis major muscles on the extreme lateral side. This allowed free communication between the compartments above and below the muscles. The pocket, made of the pectoralis major muscle and the bovine patch, was fully covered with the cutaneous–subcutaneous mastectomy flap (Figures 1–3).

Results

One year after reconstruction, the woman experienced a good esthetic outcome without capsular contracture and she was very happy with her breast.

Discussion and conclusion

The good result obtained in this case may propose Veritas® as a viable alternative to Alloderm®, and may support its ability to sustain and stimulate recovery of the surrounding tissues even if it must be confirmed by more cases. The

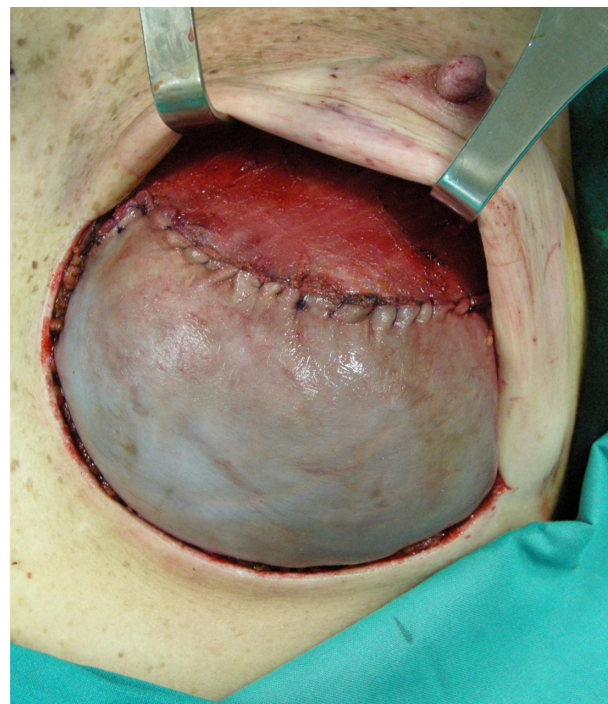

Figure 2 Intraoperative view of the left breast.

aforementioned patient selected for the bovine pericardium collagen matrix patch exhibited the ideal characteristics for reconstruction with Alloderm®; in fact according to the study of Namnoun,⁵ the best candidates for using Veritas® are: those with juvenile tight breasts, those needing immediate bilateral reconstruction, those requiring nipple- or skin-sparing mastectomy, and those not requiring complementary radiotherapy. The Veritas® bovine pericardium patch was licensed by the British Standard Institution in October 2009 and it has been introduced throughout the European Union, while for now a main obstacle to Alloderm® distribution in Europe is that it requires a country-by-country approval.

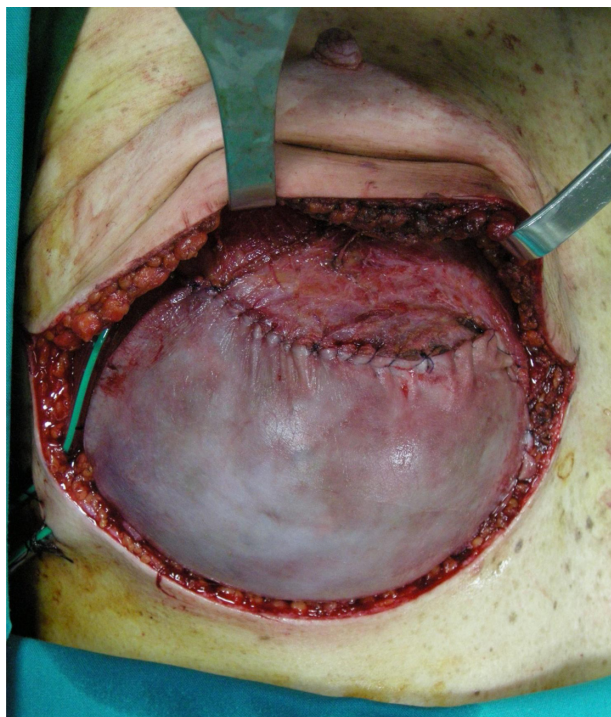


Figure 1 Intraoperative view of the right breast.

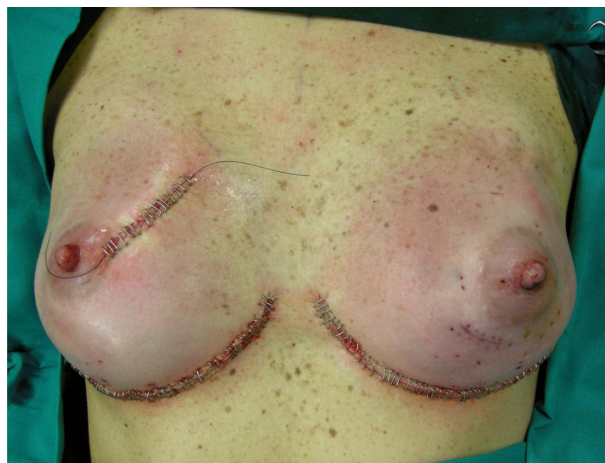

Figure 3 Immediate bilateral postoperative view.

Disclosures

The authors report no conflicts of interest in this work. There was no funding source involved in the study. No ethical approval was required for the study.

References

1. Ellsworth WA, Rizvi M, Lypka M, Bass BL, Friedman JD. Breast implant salvage with the use of acellular dermal matrix following partial mastectomy. *Plast Reconstr Surg.* 2010;126(4):189e–190e.
2. LifeCell Corporation. Alloderm: Regenerative Tissue Matrix. LifeCell product information. Branchburg, NJ: LifeCell Corporation; 2004.
3. Shashidharan S, Karras R, Henry G. Use of Veritas acellular collagen matrix in chest wall reconstruction: an emerging choice. *Am Surg.* 2010; 76(2):218–220.
4. Limpert JN, Desai AR, Kumpf AL, Fallucco MA, Aridge DL. Repair of abdominal wall defects with bovine pericardium. *Am J Surg.* 2009; 198(5):e60–e65.
5. Nannoun JD. Expander/implant reconstruction with AlloDerm: recent experience. *Plast Reconstr Surg.* 2009;124(2):387–394.

Breast Cancer: Targets and Therapy

Dovepress

Publish your work in this journal

Breast Cancer: Targets and Therapy is an international, peer-reviewed open access journal focusing on breast cancer research, identification of therapeutic targets and the optimal use of preventative and integrated treatment interventions to achieve improved outcomes, enhanced survival and quality of life for the cancer patient.

Submit your manuscript here: <http://www.dovepress.com/breast-cancer---targets-and-therapy-journal>

View the full aims and scopes of this journal here. The manuscript management system is completely online and includes a very quick and fair peer-review system, which is all easy to use. Visit <http://www.dovepress.com/testimonials.php> to read real quotes from published authors.