

Endoilluminator-assisted Descemet membrane endothelial keratoplasty and endoilluminator-assisted pre-Descemet endothelial keratoplasty

Soosan Jacob^{1,2}
Amar Agarwal¹
Dhivya Ashok Kumar¹

¹Dr Agarwal's Eye Hospital and Eye Research Centre, ²Dr Agarwal's Refractive and Cornea Foundation (DARCF), Chennai, India

Dear editor

We read with great interest the article by Kobayashi et al on the use of endoillumination probe-assisted Descemet membrane endothelial keratoplasty (DMEK) for bullous keratopathy secondary to argon-laser iridotomy.¹ We would like to bring to the author's notice that one of us (SJ) described the use of external endoillumination for DMEK, and the same was published under our names in 2014 as endoilluminator-assisted transcorneal illumination for DMEK,² with study patients included from January 2013. There are also numerous other references to this online.³⁻⁶ We have termed this technique endoilluminator-assisted DMEK or E-DMEK and endoilluminator-assisted pre-Descemet endothelial keratoplasty (E-PDEK) when applied to PDEK.⁷ E-DMEK makes the surgery simpler by allowing good visualization and better surgeon comprehension of graft morphology and dynamics and enhanced visualization and three-dimensional depth perception through edematous and hazy corneas (Figure 1). The technique also aids the surgeon with better comprehension of graft orientation and positioning (Video S1). We would like to gently bring to the authors' attention that our work was the initial report on E-DMEK, and that this has been missed in their citation.

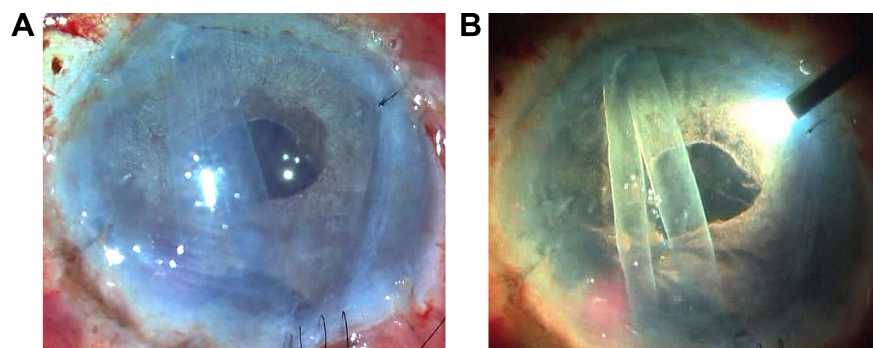


Figure 1 E-DMEK/E-PDEK.

Notes: (A) View of DMEK graft through microscope light shows insufficient visualization; (B) with microscope light turned off and with oblique external illumination by an endoilluminator (vitreo-retinal light pipe), three-dimensional visualization improves with better comprehension of entire graft morphology, orientation, and position.

Abbreviations: E-DMEK, endoilluminator-assisted Descemet membrane endothelial keratoplasty; E-PDEK, endoilluminator-assisted pre-Descemet endothelial keratoplasty.

Correspondence: Amar Agarwal
Dr Agarwal's Eye Hospital and Eye Research Centre, 19 Cathedral Road, Chennai 600086, India
Tel +91 44 2811 6233
Fax +91 44 2811 5871
Email dragarwal@vsnl.com

Disclosure

The authors report no conflicts of interest in this communication.

References

1. Kobayashi A, Yokogawa H, Yamazaki N, Masaki T, Sugiyama K. The use of endoillumination probe-assisted Descemet membrane endothelial keratoplasty for bullous keratopathy secondary to argon laser iridotomy. *Clin Ophthalmol*. 2015;8(9):91–93.
2. Jacob S, Agarwal A, Agarwal A, Narasimhan S, Kumar DA, Sivagnanam S. Endoilluminator-assisted transcorneal illumination for Descemet membrane endothelial keratoplasty: enhanced intraoperative visualization of the graft in corneal decompensation secondary to pseudophakic bullous keratopathy. *J Cataract Refract Surg*. 2014;40(8):1332–1336.
3. Jacob S. *New Technique: The E-DMEK procedure can make a world of difference to the DMEK surgeon*. Eurotimes. December 2013. Available from <http://www.eurotimes.org/node/1076>. Accessed 25 August 2015.
4. Jacob S. *E-DMEK Fuch's Dystrophy with Cataract*. Available from <http://www.eyetube.net/video/dmek-fuch-s-dystrophy-with-cataract>. Accessed 25 August 2015.
5. Jacob S. *Endoilluminator assisted DMEK (E-DMEK)/endoilluminator assisted PDEK (E-PDEK)*. Available from http://ascrs14.expoplanner.com/handouts_ascrs/002917_13050069_ENDOILLUMINATOR_ASSISTED_DMEK_OR_E-DMEK.pdf. Accessed 25 August 2015.
6. Jacob S. *PDEK bubble challenges*. Eurotimes December 2014. Available from <http://www.eurotimes.org/node/1661>. Accessed 25 August 2015.
7. Agarwal A, Dua HS, Narang P, et al. Pre-Descemet's endothelial keratoplasty (PDEK). *Br J Ophthalmol*. 2014;98(9):1181–1185.

Supplementary material

Video S1 Enhanced visualization and three-dimensional depth perception with the use of oblique external light from the endoilluminator in E-DMEK and E-PDEK.

Author's reply

Akira Kobayashi

Department of Ophthalmology, Kanazawa University Graduate School of Medical Science, Kanazawa, Japan

Correspondence: Akira Kobayashi
Department of Ophthalmology, Kanazawa University Graduate School of Medical Science, 13-1 Takara-machi, Kanazawa, Ishikawa 920-8641, Japan
Email kobaya@kenroku.kanazawa-u.ac.jp

Dear editor

First of all, I would like to apologize for overlooking a wonderful and important article concerning the use of an endoilluminator for Descemet membrane endothelial keratoplasty (DMEK) by Jacob et al published in 2014.¹ We have been using endoillumination to improve visualization during cataract surgery since 2003,² as cited in Jacob et al's article.¹ Therefore, it is quite natural for us to use this technique for DMEK as well as complicated partial thickness corneal transplant endothelial keratoplasty (DSAEK). Actually, we have been using an endoilluminator for DMEK since 2013 and found it quite useful especially for Asian eyes with dark brown irises. Our case report³ published in 2015 (5 months after Jacob et al's publication) was originally submitted to

another journal before the publication of Jacob et al's article, and during the resubmission process to *Clinical Ophthalmology*, Jacob et al published their paper.¹ This is why the oversight occurred in our article. Anyway, I congratulate them on their first publication on the use of E-DMEK. I strongly believe the use of an endoilluminator is quite a useful technique for DMEK.

Disclosure

The author reports no conflicts of interest in this communication.

References

1. Jacob S, Agarwal A, Agarwal A, Narasimhan S, Kumar DA, Sivagnanam S. Endoilluminator-assisted transcorneal illumination for Descemet membrane endothelial keratoplasty: enhanced intraoperative visualization of the graft in corneal decompensation secondary to pseudophakic bullous keratopathy. *J Cataract Refract Surg*. 2014;40(8):1332–1336.
2. Nishimura A, Kobayashi A, Segawa Y, Sugiyama K. Endoillumination-assisted cataract surgery in a patient with corneal opacity. *J Cataract Refract Surg*. 2003;29(12):2277–2280.
3. Kobayashi A, Yokogawa H, Yamazaki N, Masaki T, Sugiyama K. The use of endoillumination probe-assisted Descemet membrane endothelial keratoplasty for bullous keratopathy secondary to argon laser iridotomy. *Clin Ophthalmol*. 2015;9:91–93.

Dove Medical Press encourages responsible, free and frank academic debate. The content of the Clinical Ophthalmology 'letters to the editor' section does not necessarily represent the views of Dove Medical Press, its officers, agents, employees, related entities or the Clinical Ophthalmology editors. While all reasonable steps have been taken to confirm the content of each letter, Dove Medical Press accepts no liability in respect of the content of any letter, nor is it responsible for the content and accuracy of any letter to the editor.

Clinical Ophthalmology

Publish your work in this journal

Clinical Ophthalmology is an international, peer-reviewed journal covering all subspecialties within ophthalmology. Key topics include: Optometry; Visual science; Pharmacology and drug therapy in eye diseases; Basic Sciences; Primary and Secondary eye care; Patient Safety and Quality of Care Improvements. This journal is indexed on

Submit your manuscript here: <http://www.dovepress.com/clinical-ophthalmology-journal>

Dovepress

PubMed Central and CAS, and is the official journal of The Society of Clinical Ophthalmology (SCO). The manuscript management system is completely online and includes a very quick and fair peer-review system, which is all easy to use. Visit <http://www.dovepress.com/testimonials.php> to read real quotes from published authors.