

Diabetic papillopathy treated with intravitreal ranibizumab

Mine Yildirim
Deniz Kilic
Mehmet Emin Dursun
Birgul Dursun

Department of Ophthalmology,
Gazi Yasargil Training and Research
Hospital, Diyarbakir, Turkey

Abstract: In this report, we present a case of diabetic papillopathy that resolved after a single dose of intravitreal ranibizumab injection. A 50-year-old male presented with painless visual loss in his right eye. His visual acuity was 1/10 in the right eye and 10/10 in the left eye. Anterior segment examination of both eyes was unremarkable. Posterior segment of the right eye showed nonproliferative diabetic retinopathy with a swollen optic disc. Fluorescein angiography and optical coherence tomography were performed. There was dye leakage from the right optic disc. Optical coherence tomography revealed a significant increase in retinal nerve fiber layer thickness. Magnetic resonance imaging of the brain and orbit were normal. The patient received a single intravitreal ranibizumab (0.5 mg) injection. Two weeks after the injection, there was a marked regression of the disc swelling. Three months after the injection the optic disc was pallor and visual acuity was 6/10.

Keywords: diabetic papillopathy, optic disc swelling, ranibizumab, optical coherence tomography

Introduction

The term diabetic papillopathy (DP) is used for unilateral or bilateral optic disc swelling in which the patient has either type 1 or type 2 diabetes mellitus.¹ This entity is diagnosed by excluding the other causes of disc swelling.² The exact pathogenesis is not clearly understood but some authors consider DP as a form of anterior ischemic optic neuropathy (AION).³ Unlike AION; DP has a benign course without significant sequela.¹ Although there is no accepted treatment paradigm; in some recent case reports, treatment with intravitreal injection of different agents was effective in reducing disc swelling.⁴⁻⁶ In this study we report a case of DP treated with intravitreal ranibizumab injection and demonstrate resolution of optic disc swelling.

Case report

Written informed consent has been provided by the patient to have the case details and accompanying images published.

A 53-year-old male presented with acute painless decreased vision in his right eye. The patient was on a regimen of oral hypoglycemic agents and had no other known medical disease. Best-corrected visual acuity (BCVA) was 1/10 in the right eye and 10/10 in the left eye. The intraocular pressure (IOP) was 14 mm Hg in each eye. The anterior segment examination of both eyes was unremarkable. There was no afferent pupillary defect. Dilated fundus examination showed significant bilateral non-proliferative diabetic retinopathy and a swollen optic disc with telangiectatic vessels

Correspondence: Deniz Kilic
Department of Ophthalmology,
Gazi Yasargil Training and Research
Hospital, PO Box 21010, Uckuyular,
Diyarbakir, Turkey
Tel +90 505 920 3928
Email dnz_kilic@hotmail.com

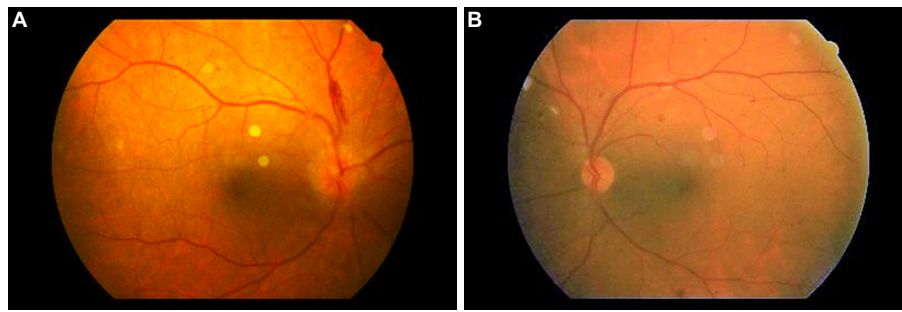


Figure 1 Fundus photographs of the patient.
Notes: (A) Nonproliferative diabetic retinopathy and a swollen optic disc. (B) Nonproliferative diabetic retinopathy.

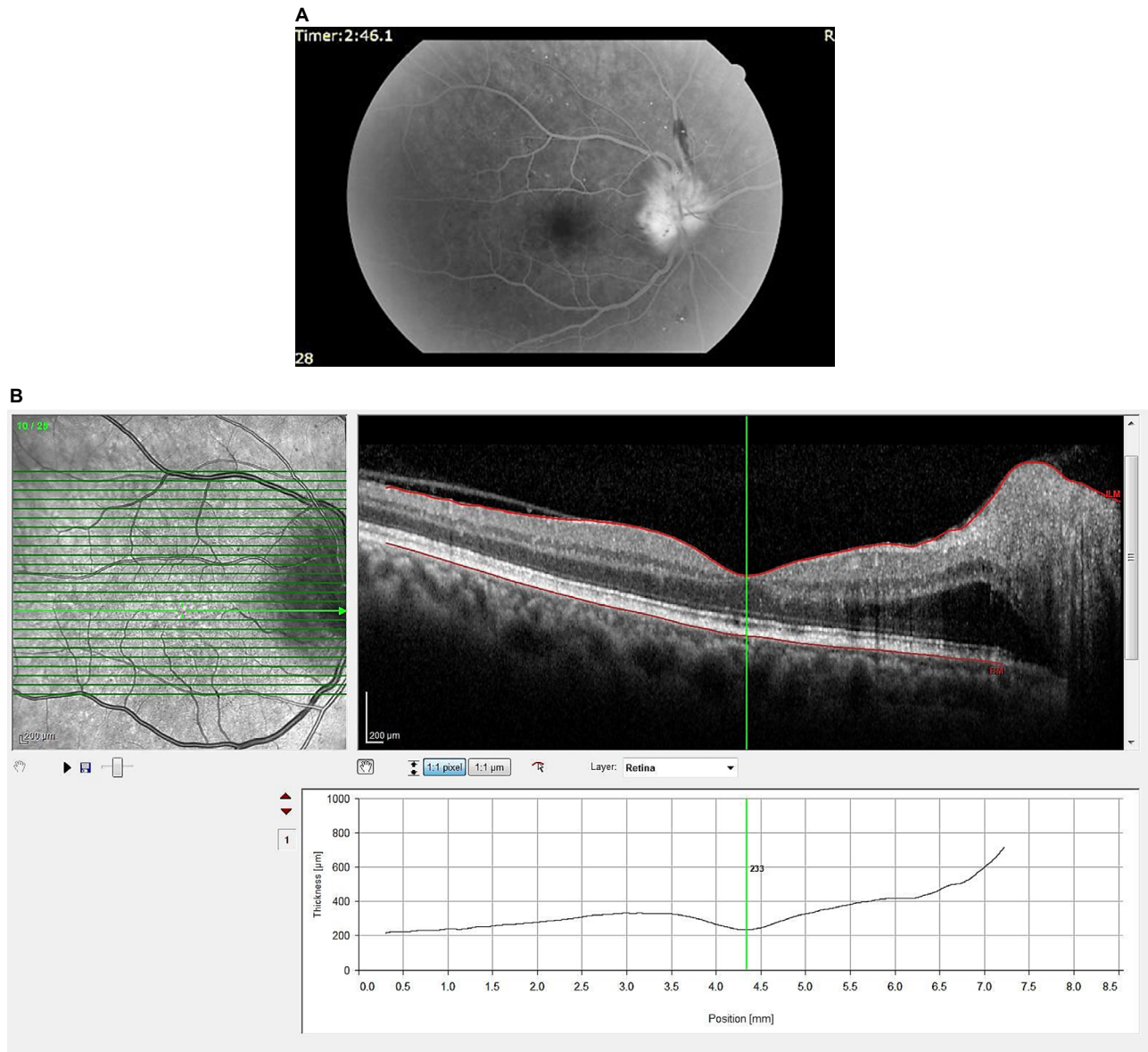


Figure 2 Fundus fluorescein angiography and optical coherence tomography image of the right eye.
Notes: (A) At presentation fundus fluorescein angiography of the right eye shows dye leakage from the optic disc. (B) At presentation optical coherence tomography of the right eye shows an increase in the retinal nerve fiber layer thickness without macular edema.

in the right eye (Figure 1A and B). Fundus fluorescein angiography (FFA) and optical coherence tomography were performed. In the right eye there was dye leakage from the

optic disc and a significant increase in the retinal nerve fiber-layer thickness without macular edema (Figure 2A and B). Visual field examination of the right eye showed diffuse

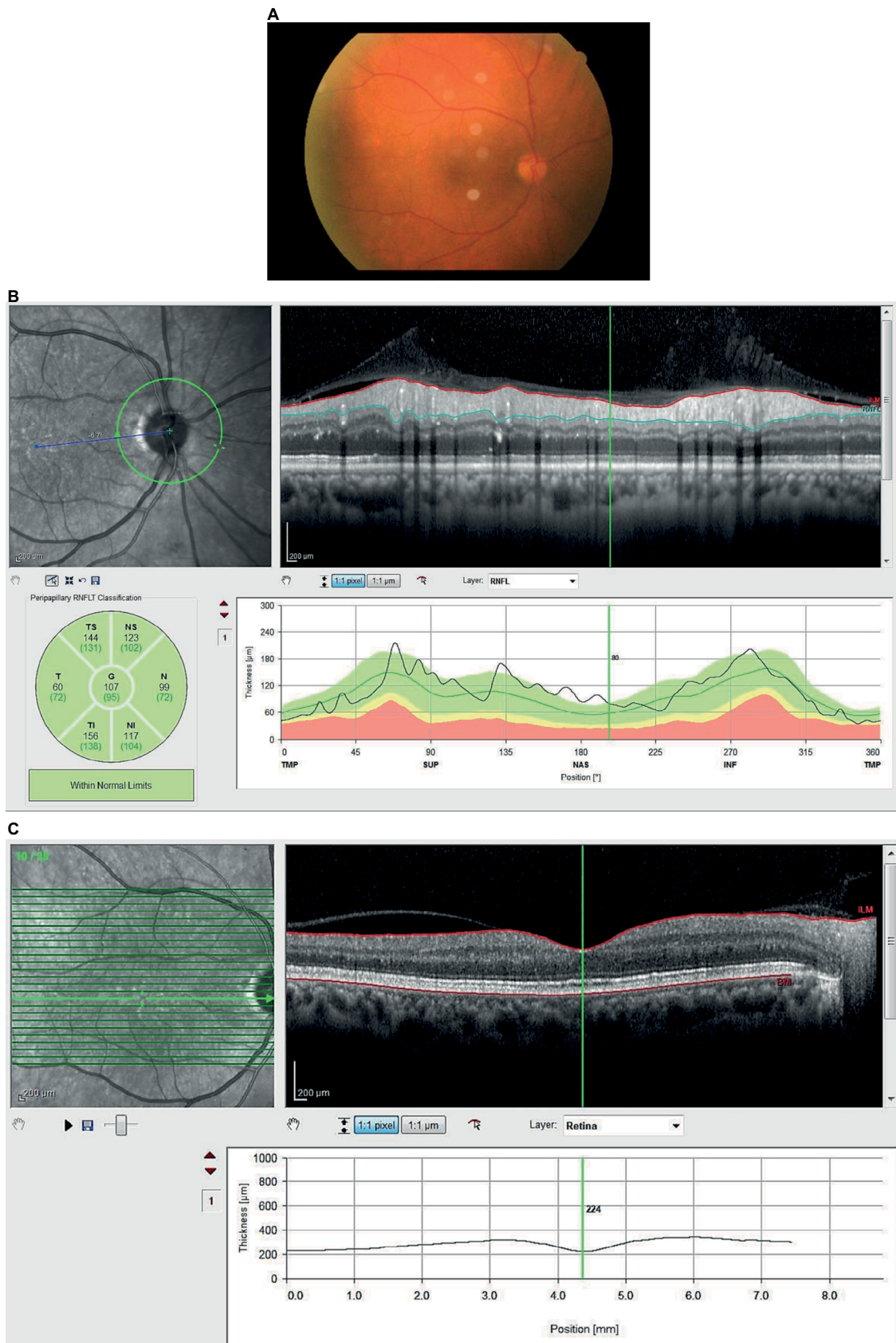


Figure 3 Retinal images 2 weeks after the injection.

Notes: (A) Within 2 weeks, there was marked regression of disc swelling. (B) After 2 weeks optical coherence tomography of the right eye shows a decrease in the retinal nerve fiber layer thickness. (C) Optical coherence tomography of the right eye shows no macular edema.

Abbreviations: RNFL, retinal nerve fiber layer; RNFLT, retinal nerve fiber layer thickness; T, temporal; TS, superior temporal; NS, superior nasal; N, nasal; NI, inferior nasal; TI, inferior temporal; G, global; TMP, temporal; SUP, superior; NAS, nasal; INF, inferior.

depression whereas the left eye was normal. Visual evoked potential was in the normal range for both eyes. Clinical neurologic examination and magnetic resonance imaging of the brain were normal. Blood pressure measurements, complete blood count, sedimentation rate and electrolytes were within normal limits. Glycosylated hemoglobin was 9.5%. After complete examination of the patient, he was diagnosed with DP and informed about expected effects and possible complications of intravitreal ranibizumab injection. After the patient was informed about the expected effects,

the right eye was prepared and draped in a sterile manner and topical anesthetic was instilled in the eye. Subsequently, 0.5 mg/0.05 ml ranibizumab was injected into the vitreous cavity.

Within 2 weeks, BCVA in the right eye improved to 3/10 and IOP was normal. There was marked regression of disc swelling (Figure 3A–C). Three months following the injection, BCVA was 6/10, IOP was normal, and the optic disc was mildly pale with complete resolution of swelling in the right eye (Figure 4A–C). The patient is being followed up for his diabetic retinopathy.

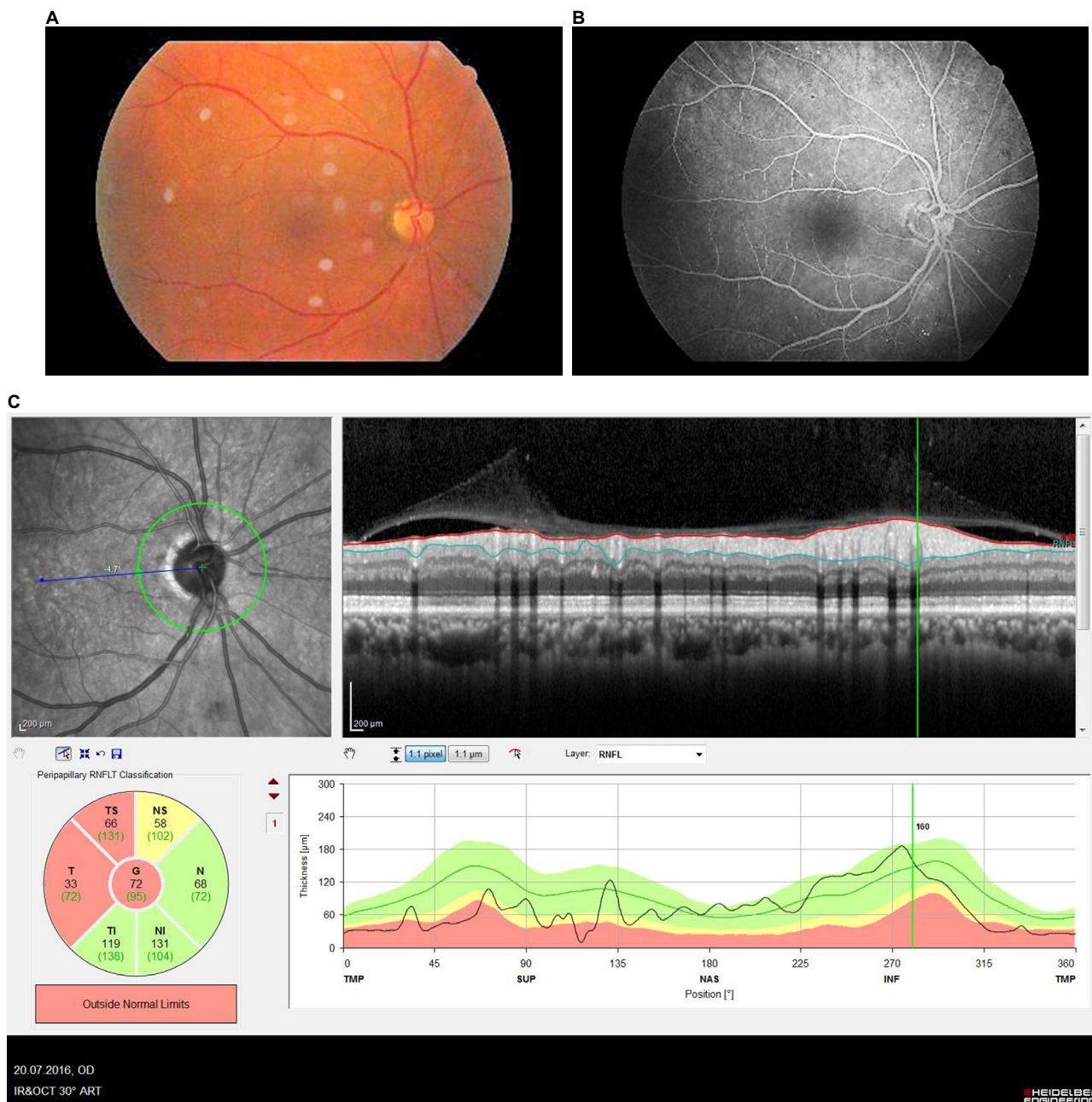


Figure 4 Retinal images 3 months after the injection.

Notes: (A) Three months following the injection, the optic disc was mildly pale. (B) Three months following the injection, fundus fluorescein angiography showed no dye leakage. (C) There was a decrease in the retinal fiber layer thickness (RFLT) 3 months after the injection.

Discussion

Acute, painless visual loss is a clinical sign of optic disc swelling that is caused by a variety of reasons. DP is one of these reasons and it has been published by many investigators since 1971.^{7,8} Although it is thought to be a mild form of non-arteritic AION by some researchers,³ DP can be distinguished from AION by certain clinical findings. In contrast to patients with DP, AION patients suffer from profound loss of visual acuity. After the resolution of optic neuropathy visual field defect and visual acuity loss persists in patients with AION. On the other hand; in DP patients visual field defects are transient and visual acuity improves to 4/10 or more.^{1,2} These two conditions can also be distinguished by FFA. Early disc hypofluorescence due to hypoperfusion with late leakage around the affected segment occurs in AION. But in patients with DP, FFA shows a very early hyperfluorescence, most likely due to telangiectasia of the optic disc that increases throughout the study.⁹

The patient was diagnosed as having DP because of the following: painless visual loss, no other clinical disorder except uncontrolled diabetes mellitus, early disc hyperfluorescence on FFA and good visual outcome post-treatment.

Anti-VEGF agents have recently been used for some reported DP cases with visual improvement and reduced optic disc swelling.^{4,5} Periocular and intravitreal corticosteroid injection was also found to be effective in patients with DP.⁶ These effective treatment options indicate that inflammatory elements could be involved in the pathogenesis of this disorder. It is known that VEGF induces a rapid and reversible increase in vascular permeability. So, if an optic nerve head is ischemic there will be an increased amount of VEGF leading to vasogenic disc edema.¹⁰ But still the exact pathogenesis of DP and the mechanism of action of anti-VEGF in patients with DP is not well understood. The treatment we administered in our case was intravitreal

ranibizumab injection. After 2 weeks, disc swelling had largely resolved and visual acuity had improved from 1/10 to 6/10. There were no complications at all and DP had not reappeared at the 3-month follow-up.

Conclusion

Two weeks after intravitreal ranibizumab injection, there was an increase in visual acuity in our patient. VEGF may play a role in the pathogenesis of DP and so the administered intravitreal ranibizumab could have helped the patient to recover. However, the efficacy and safety of this management of DP needs to be proven through further larger clinical studies.

Disclosure

The authors report no conflicts of interest in this work.

References

1. Bayraktar Z, Alacali N, Bayraktar S. Diabetic papillopathy in type II diabetic patients. *Retina*. 2002;22(6):752–758.
2. Regillo CD, Brown GC, Savino PJ, Byrnes GA, Benson WE, Tasman WS, Sergott RC. Diabetic papillopathy. Patient characteristics and fundus findings. *Arch Ophthalmol*. 1995;113(7):889–895.
3. Hayreh SS, Zimmerman B. Nonarteritic anterior ischemic optic neuropathy: clinical characteristics in diabetic patients versus nondiabetic patients. *Ophthalmology*. 2008;115(10):1818–1825.
4. Kim M, Lee JH, Lee SJ. Diabetic papillopathy with macular edema treated with intravitreal ranibizumab. *Clin Ophthalmol*. 2013;7:2257–2260.
5. Al-Hinai AS, Al-Abri MS, Al-Hajri RH. Diabetic papillopathy with macular edema treated with intravitreal bevacizumab. *Oman J Ophthalmol*. 2011;4(3):135–138.
6. Al-Haddad CE, Jurdi FA, Bashshur ZF. Intravitreal triamcinolone acetonide for the management of diabetic papillopathy. *Am J Ophthalmol*. 2004;137(6):1151–1153.
7. Lubow M, Makley TA Jr. Pseudopapilledema of juvenile diabetes mellitus. *Arch Ophthalmol*. 1971;85(4):417–422.
8. Appen RE, Chandra SR, Klein R, Myers FL. Diabetic papillopathy. *Am J Ophthalmol*. 1980;90(2):203–209.
9. Oto S, Yilmaz G, Cakmakci A, Aydin P. Indocyanine green and fluorescein angiography in nonarteritic anterior ischemic optic neuropathy. *Retina*. 2002;22(2):187–191.
10. Weis SM, Cheresch DA. Pathophysiological consequences of VEGF-induced vascular permeability. *Nature*. 2005;437(7058):497–504.

International Medical Case Reports Journal

Publish your work in this journal

The International Medical Case Reports Journal is an international, peer-reviewed open-access journal publishing original case reports from all medical specialties. Previously unpublished medical posters are also accepted relating to any area of clinical or preclinical science. Submissions should not normally exceed 2,000 words or

Submit your manuscript here: <https://www.dovepress.com/international-medical-case-reports-journal-journal>

4 published pages including figures, diagrams and references. The manuscript management system is completely online and includes a very quick and fair peer-review system, which is all easy to use. Visit <http://www.dovepress.com/testimonials.php> to read real quotes from published authors.

Dovepress