

# Multimodal Imaging Features of Focal Scleral Nodule

Víctor Manuel Asensio-Sánchez  
Gabriela Estefanía Pacheco-  
Carllirgos  
Francisco Javier Valentín-Bravo

Ophthalmology Department, Clinical  
University Hospital of Valladolid,  
Valladolid, Spain

**Abstract:** This article describes a 63-year-old woman with a yellow-white mass in the inferior juxtapapillary region discovered on routine ocular examination. She was diagnosed as solitary idiopathic choroiditis (SIC) after an extensive ocular examination. SIC is a rare condition of unknown aetiology that can sometimes be mistaken as inflammatory processes or intraocular tumors. Solitary idiopathic choroiditis is suspected clinically and the diagnosis is established with multimodal imaging, so CIS has been renamed focal scleral nodule because of the scleral location.

**Keywords:** solitary idiopathic choroiditis, unifocal helioid choroiditis, multimodal imaging, intraocular tumor, intraocular inflammation, focal scleral nodule

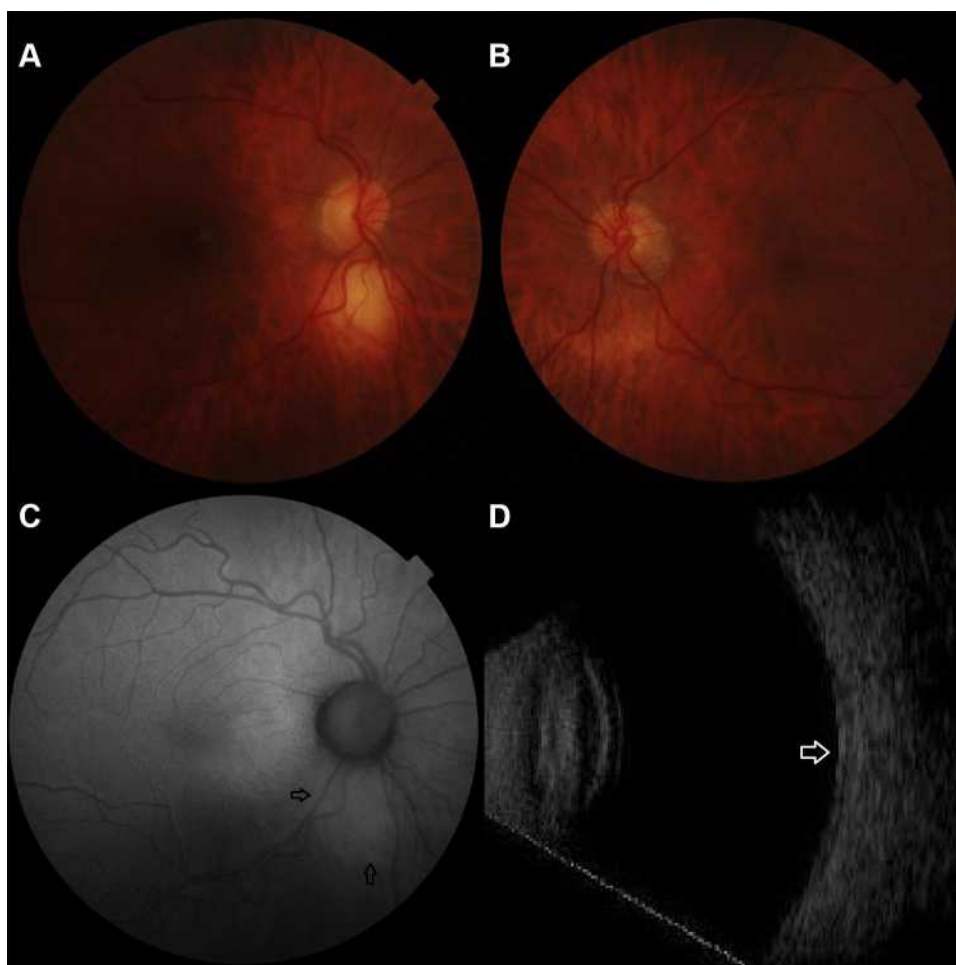
## Introduction

Solitary idiopathic choroiditis (SIC), also known as unifocal helioid choroiditis, is a distinct clinical entity manifests as a yellow-white nodular lesion that resembles other choroidal tumors and inflammatory chorioretinal diseases.<sup>1,2</sup> Multimodal imaging with fundusoscopic appearance is the best way to distinguish it from choroidal lesions. Multimodal imaging is necessary to rule out the differentials of this condition. Optical coherence tomography shows SIC to be a well-defined mild hyperreflective intrascleral lesion.<sup>3</sup> Moreover, in SIC has not been identified any evidence of an inflammation component.<sup>3</sup> A nomenclature change to focal scleral nodule (FSN) is appropriate of a lesion originated primarily in the sclera and to prevent extensive ocular and medical workup to determine the exact etiology to avoid unnecessary treatment.<sup>3</sup> We describe the clinical and multimodal imaging of FSN in an asymptomatic female patient.

## Clinical Case

A 63-year-old white woman with no significant past medical history was diagnosed as having a choroidal lesion on routine ophthalmic examination and was referred for further evaluation to our hospital. On examination, her visual acuity in both eyes was 20/20 (Snellen's). No significant finding was observed on anterior segment examination. Intraocular pressure was 14 mmHg bilaterally. She had no afferent pupillary defect and had normal color vision and brightness perception in both eyes. No cells or flare in the anterior or posterior segment were observed. On dilated exam, the left fundus was normal (Figure 1A). Examination of the right fundus revealed a round deep yellow-white mass without visible subretinal fluid, 1.25 mm in diameter, located in the peripapillary area, inferonasal to the optic disc (Figure 1B). Fundus autofluorescence showed mild intrinsic hyperautofluorescence

Correspondence: Víctor Manuel Asensio-Sánchez  
Tel +34 983 37 79 82  
Email vmasensio@yahoo.es

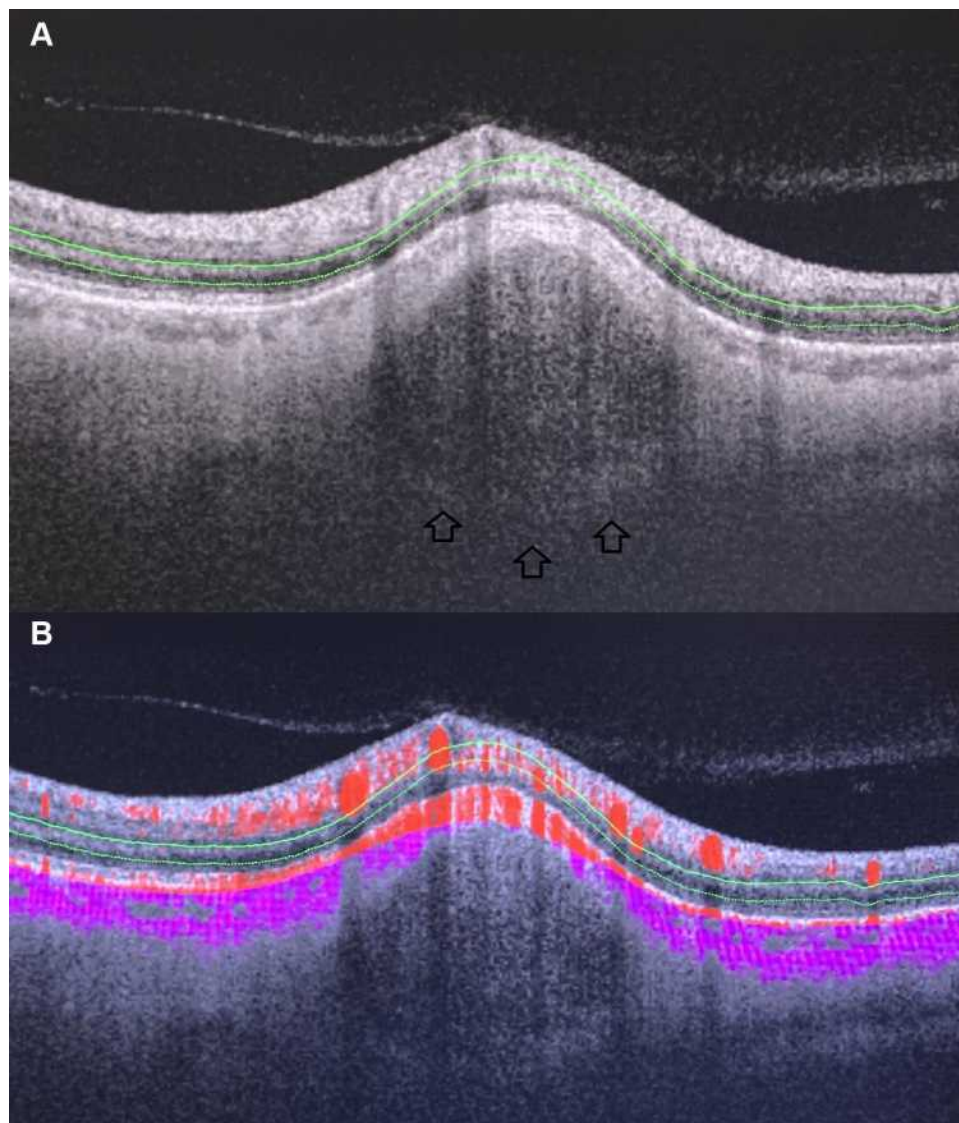


**Figure 1** Funduscopy appearance of the lesion. Note the yellow-white and discrete lesion with a surrounding orange halo a configuration that is consistent with solitary idiopathic choroiditis (A). Normal funduscopy left eye (B). (C) Fundus autofluorescence imaging demonstrates hyperautofluorescence (arrows). (D) B-scan ultrasonography showing a high echogenicity (arrow).

(Figure 1C). Ultrasonography B showed acoustic solidity but failed to show an elevated lesion. There was no evidence of calcification within the mass (Figure 1D). Swept source (SS) imaging optical coherence tomography (OCT) (Triton Plus DRI-OCT; Topcon Medical Systems, Inc.) disclosed an intrascleral shape mass with round configuration and visible posterior margin that was associated with compression of overlying choroidal layer. The choroid was almost absent at the apex of the mass (Figure 2). No retinal thickening, or exudates were noted. In OCT angiography (OCTA), choriocapillaris flow impairment was seen overlying the SIC lesion. OCTA images show an avascular lesion (Figure 3). ESR, serum calcium and ACE levels were within normal limits. Mantoux tests were normal. These features were consistent with inactive SIC. The patient refused fluorescein angiography.

## Discussion

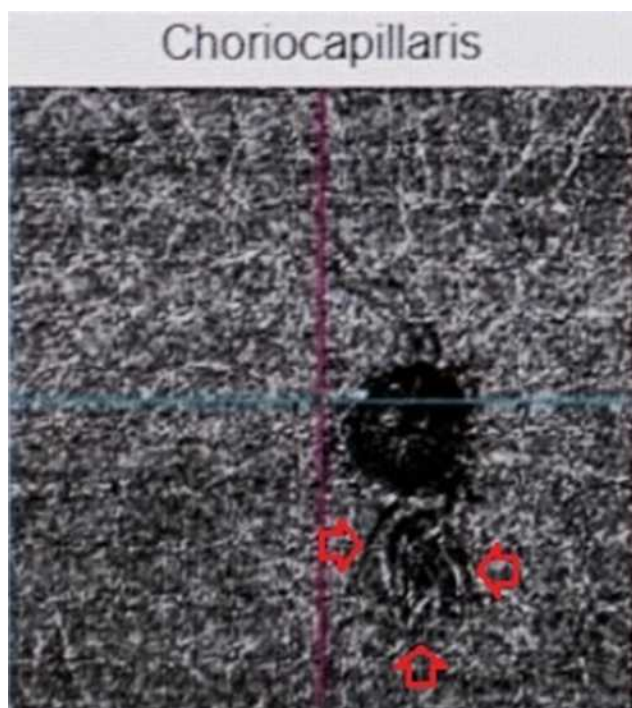
The clinical signs and imaging features in this case are consistent with the published description of SIC.<sup>1-3</sup> The lesion was initially thought to be a tubercular or sarcoid granuloma. Routine blood and systemic investigations were normal. SIC is a benign and uncommon mass deep to the retina, often discovered only at routine examination in an asymptomatic patient. Hong et al<sup>2</sup> described for the first time a choroidal lesion that was called unifocal helioid choroiditis because the lesions have a sunlike appearance. Five years later this lesion was renamed SIC by Shields et al.<sup>1</sup> SIC is most commonly found in Caucasians females.<sup>1,3</sup> It is unilateral, yellow-white asymptomatic mass about 1 disc diameter in size and posterior to the equator near the optic nerve.<sup>1,3</sup> Solitary SIC is an amelanotic tumor often confused with intraocular masses and



**Figure 2 (A)** SS-OCT imaging confirms the diagnosis as the lesion can clearly be seen coming up from the sclera and compressing the overlying choroid and choriocapillaris. The lesion is inactive as there is no sign of yellow intraretinal exudation, localized subretinal fluid or focal retinal hemorrhages and the posterior border (arrows) of the lesion is well defined. **(B)** Cross-sectional composite OCT angiogram. The lesion is avascular. Overlying choroidal vasculature is thinned. Flow signals are color coded: purple, choroid; red, neuroretina.

inflammatory diseases.<sup>4-8</sup> Both conditions have an appearance similar to the lesions seen in SIC patients. Diagnosis of choroidal tumors can be difficult. Additional imaging, including B-scan ultrasonography, fluorescein angiography, indocyanine green angiography and OCT, was helpful in securing the diagnosis.<sup>4-6</sup> A solitary choroidal granuloma is most frequently associated with sarcoidosis, tuberculosis and syphilis but also can be idiopathic. But intraocular inflammation, medical history, and laboratory tests can be helpful in differential diagnosis.<sup>6-8</sup> Before OCT, the lesion was considered an inflammatory granulomatous reaction in the choroid with no known systemic association (idiopathic). More recently, Fung et al<sup>9</sup> described the imaging

characteristics of SIC with EDI-OCT provided evidence that these lesions could arise from the sclera, outer choroid, or both and the overlying choroidal vasculature was thinned. In 2020, Fung et al<sup>3</sup> described multimodal imaging characteristics of SIC in the largest series to date. They described the lesions as being solid on ultrasound, hyper-autofluorescent and located in the sclera without any choroidal involvement. Swept-source OCT provided the capability to evaluate the posterior margin of these lesions, which displayed a nodular shape and compresses the overlying choroidal vasculature and was instrumental in differentiating SIC from other simulating conditions.<sup>3,10</sup> Multimodal imaging performed by us suggests a nodular



**Figure 3** OCT angiography: resulted in fewer choriocapillaris flow voids (between arrows).

mass of scleral origin with compression and thinning of the overlying choroid. Our patient never had any history to suggest inflammation and the mass was an incidental finding in our case. Although definitive localization of SIC cannot be made without histopathology, these features are suggestive of a scleral lesion rather than choroiditis.<sup>3,10</sup> Based on these observations, this lesion shows features of a focal scleral nodule. Fung et al<sup>3</sup> validated to rename unifocal helioid choroiditis and solitary idiopathic choroiditis as focal scleral nodule (FSN) because of the scleral location of the lesion. The diagnosis of FSN is clinically suspected and diagnostically established with multimodal imaging. FSN is generally acoustically dense on B-ultrasonography, hypofluorescent on early phase fluorescein angiography with late scleral staining, and slightly hyperautofluorescent attributed to unmasking of underlying scleral autofluorescence. The most important test in establishing the diagnosis is swept-source imaging optical coherence tomography in which the mass appears with a nodular configuration of the lesion in the sclera, with a visible posterior margin and diffuse hyperreflectivity and compressing overlying choroid. A detailed explanation of our imaging findings and their interpretation has been mentioned

above. The mass was an incidental finding in our case and our patient never had any previous eye problems. The treatment for the condition is controversial: in the patient described, no treatment was needed other than regular monitoring. In subsequent follow-ups, visual acuity, tumor size and morphology remained stable. It is important for ophthalmologists to be aware of this condition to avoid an extensive ocular examination and laboratory workup and unnecessary treatment.

## Ethics

Institutional approval was not required to publish the details of the case.

## Consent

The authors confirm that written informed consent has been provided by the patient to have the case details and any accompanying images published.

## Disclosure

The authors report no conflicts of interest in this work.

## References

- Shields JA, Shields CL, Demirci H, Hanover S. Solitary idiopathic choroiditis: the Richard B. Weaver lecture. *Arch Ophthalmol.* 2002;120(3):311–319. doi:10.1001/archophth.120.3.311
- Hong PH, Jampol LM, Dodwell DG, Hrisomalos NF, Lyon AT. Unifocal helioid choroiditis. *Arch Ophthalmol.* 1997;115(8):1007–1013. doi:10.1001/archophth.1997.01100160177006
- Fung AT, Waldstein SM, Gal-Or O, et al. Focal scleral nodule: a new name for solitary idiopathic choroiditis and unifocal helioid choroiditis. *Ophthalmology.* 2020;S0161-6420(20)30396-1.
- Shields JA, Shields CL. Clinical features of posterior uveal melanoma: choroidal granuloma. In: *Atlas of Intraocular Tumors*. Philadelphia: Lippincott Williams & Wilkins; 1999:74–93.
- Shields JA, Shields CL. Differential diagnosis of posterior uveal melanoma: chorioretinal granuloma. In: *Intraocular Tumors: A Text and Atlas*. Philadelphia: WB Saunders Company; 1992:145–146.
- Shields JA, Shields CL. Lesions simulating posterior uveal melanoma: choroidal granuloma. In: *Atlas of Intraocular Tumors*. Philadelphia: Lippincott Williams & Wilkins; 1999:146–147.
- Marcus DF, Bovino JA, Burton TC. Sarcoid granuloma of the choroid. *Ophthalmology.* 1982;89(12):1326–1330. doi:10.1016/S0161-6420(82)34627-8
- Olk RJ, Lipman MJ, Cundiff HC, Daniels J. Solitary choroidal mass as the presenting symptom in systemic sarcoidosis. *Br J Ophthalmol.* 1983;67(12):826–829. doi:10.1136/bjo.67.12.826
- Fung AT, Kaliki S, Shields CL, Mashayekhi A, Shields JA. Solitary idiopathic choroiditis: findings on enhanced depth imaging optical coherence tomography in 10 cases. *Ophthalmology.* 2013;120(4):852–858. doi:10.1016/j.ophtha.2012.09.017
- Welch RJ, Surakiatchanukul T, Shields CL. Multimodal imaging characteristics of solitary idiopathic choroiditis in 26 cases. *Invest Ophthalmol Vis Sci.* 2017;58:1855.

### International Medical Case Reports Journal

Dovepress

#### Publish your work in this journal

The International Medical Case Reports Journal is an international, peer-reviewed open-access journal publishing original case reports from all medical specialties. Previously unpublished medical posters are also accepted relating to any area of clinical or preclinical science. Submissions should not normally exceed 2,000 words or 4

published pages including figures, diagrams and references. The manuscript management system is completely online and includes a very quick and fair peer-review system, which is all easy to use. Visit <http://www.dovepress.com/testimonials.php> to read real quotes from published authors.

Submit your manuscript here: <https://www.dovepress.com/international-medical-case-reports-journal-journal>