

Case Report: Targeted Therapy with Anlotinib for a Rare Case of Spinal Cord Glioblastoma with *FGFR3* Mutation

Ruiqiong Liu, Wei Wei, Huaying Hou, Ping Cong, Yong Zhou, Xiaoming Yu

Cancer Center, The Second Hospital, Cheeloo College of Medicine, Shandong University, Jinan, 250033, People's Republic of China

Correspondence: Xiaoming Yu, Cancer Center, The Second Hospital, Cheeloo College of Medicine, Shandong University, Jinan, 250033, People's Republic of China, Tel +86-0531-85875541, Email yxm_sd@hotmail.com

Abstract: Primary spinal cord glioblastoma (PSC GBM) is a rare disease with limited treatment options. Here, we describe a case of PSC GBM treated with anlotinib in this report. Molecular characterization confirmed the presence of the *MGMT* promoter unmethylated, *IDH* wild type, *FGFR3* p.S249C and p53 p.V73fs mutations in the patient. Anlotinib is a multitarget tyrosine kinase inhibitor that target VEGFR2/3, FGFR1-4, PDGFR α/β , and c-kit. After a partial resection of the tumor at the extramedullary invasion site, the patient was administered anlotinib 12 mg p.o. once every day (days 1–14, 21-day cycle) in combination with irinotecan chemotherapy (days 1 and 8, 21-day cycle). The patient exhibited significant symptom remission and partial response and was maintained for more than 10 months of follow-up. This case study showed that *FGFR3* S249C may be a new marker for the treatment of PSC GBM with anlotinib. This case is also another strong support for molecular diagnosis and precision medicine.

Keywords: spinal cord glioblastoma, *FGFR3* mutation, anlotinib, targeted therapy, precision medicine

Introduction

Primary spinal cord glioblastoma (PSC GBM) is an extremely rare disease with a very dismal prognosis, just accounting for approximately 1.4% of intraspinal tumors.¹ Despite advances in surgery techniques and postoperative adjuvant treatments such as chemotherapy and radiotherapy, patients with PSC GBM still suffer from this disease. The overall survival (OS) time of spinal cord GBM is about 10–14 months, shorter than that of intracranial GBM.^{2,3} Moreover, the disease is often associated with severe neurological impairment, which seriously affects the quality of life. Except for surgery and chemoradiotherapy, targeted therapies that can be used to treat PSC GBM are rarely reported.

The fibroblast growth factor receptor (FGFR) family consists of four members, FGFR1-4.⁴ These tyrosine kinase receptors are expressed on cell membranes with 22 known ligands.⁵ The interaction between FGFRs and their ligands activates downstream signaling pathways such as AKT, ERK and MAPK pathway, which are involved in cell survival, proliferation, development, angiogenesis and differentiation.⁶ Aberrations in FGFRs including single nucleotide variants (SNVs), gene rearrangements or fusions, and copy number amplifications (CNAs) are recognized as a molecular driver in different kinds of cancer.⁷ *FGFR3* S249C is one of the hotspot SNVs in bladder urothelial carcinoma, head and neck squamous cell carcinoma, lung squamous cell carcinoma, and kidney papillary cell carcinoma.⁸ *FGFR3* S249C is known to be oncogenic and promotes chemoresistance by activating the Akt signaling pathway.⁹ Patients with tumors carrying S249C mutation could be treated with pan-FGFR targeted inhibitor.⁸

Anlotinib is a multitarget tyrosine kinase inhibitor that target VEGFR2/3, FGFR1-4, PDGFR α/β , and c-kit. In addition to inhibiting tumor angiogenesis, anlotinib also inhibits tumor cell growth based on its molecular mechanism. Currently, anlotinib is often used to treat advanced non-small cell lung cancer (NSCLC), small cell lung cancer (SCLC) and soft tissue sarcoma. In addition, it has also been reported to be used in the treatment of recurrent intracranial glioblastoma.¹⁰

In this case report, we describe a patient with a rare PSC GBM with FGFR3 mutation. The patient achieved satisfactory results after receiving radiotherapy and chemotherapy combined with anlotinib targeted therapy.

Case Description

A 55-year-old man was admitted to the hospital as a new patient on July 22, 2020. Prior to admission, he presented with progressive numbness and weakness of the right lower extremity, which later developed into an inability to walk alone and an incontinence of urine and feces. Magnetic resonance imaging (MRI) showed a space-occupying lesion in the medullary cone (Figure 1A). After receiving relevant systemic examinations to confirm that there were no tumors or metastases in other organs, the patient underwent a partial resection of the tumor at the extramedullary invasion site under general anesthesia on

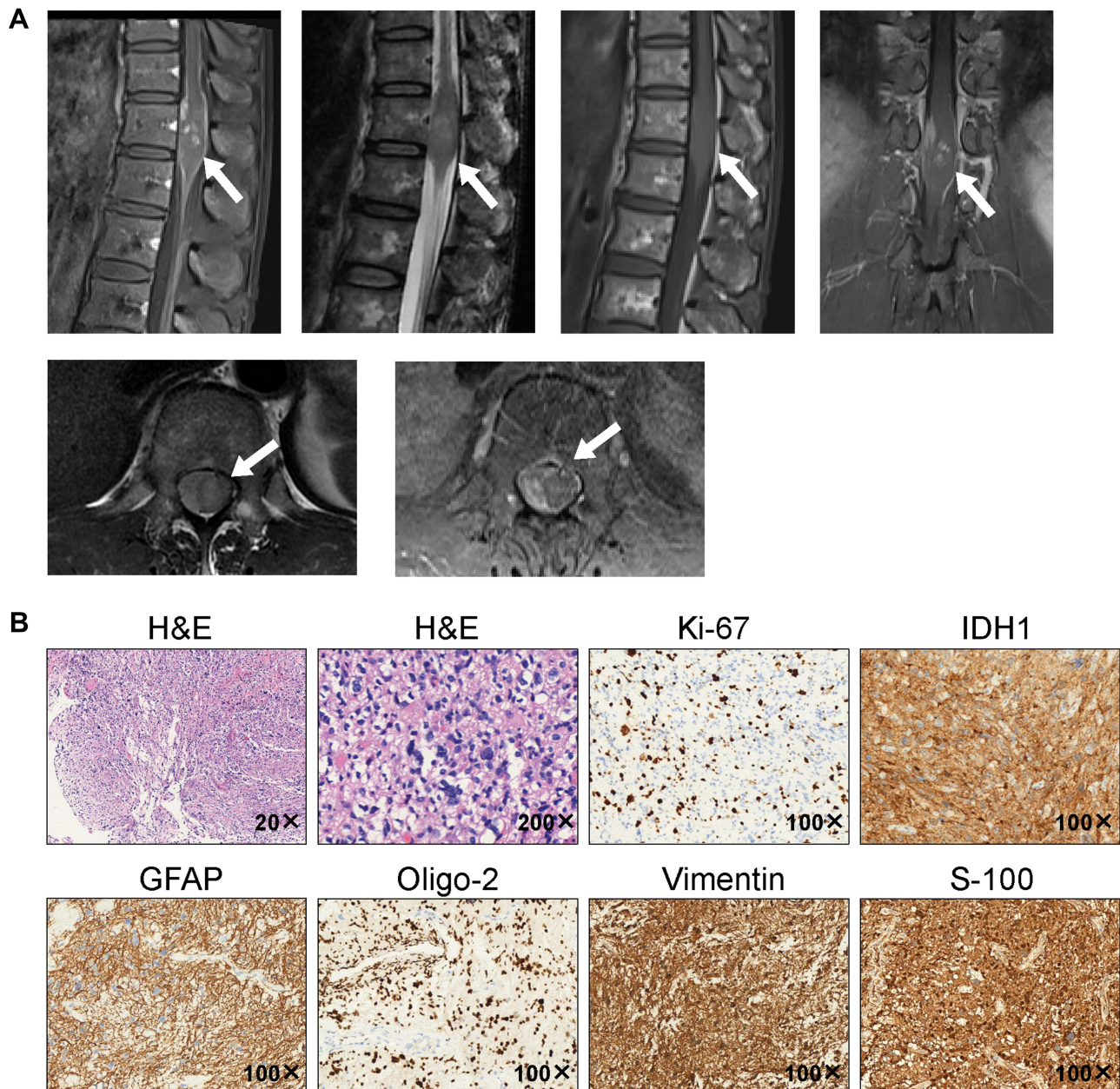


Figure 1 Images of initial MRI examination and pathological diagnosis. (A) Magnetic resonance imaging revealed space-occupying lesion in medullary cone. (B) Hematoxylin and eosin stain of the resected tissue supported the diagnosis of glioblastoma (hypercellularity, nuclear pleomorphism, brisk mitotic activity and multinuclear giant cell). The immunohistochemical results showed that IDH1, GFAP, Oligo-2, p53, and S-100 were expressed and the Ki67 proliferation index was ~50%.

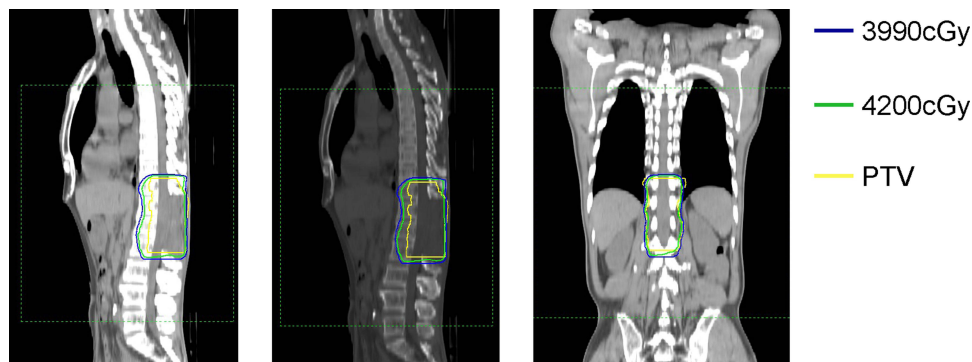


Figure 2 Dose distribution of three-dimensional conformal radiotherapy plan. Radiotherapy dose distribution is depicted as isodose levels. Planning target volume (PTV) is outlined in yellow.

August 3, 2020. Histopathology confirmed glioblastoma, World Health Organization (WHO) grade IV. Immunohistochemical results showed that the Ki-67 proliferation index was 50%. In addition, the tumor tissue stained positive for IDH1, GFAP, Oligo-2, Vimentin and S-100 (Figure 1B). Furthermore, immunohistochemical assays were used to detect the expression level of anlotinib targets. We found that most of these receptors stained positive in tumor cells. In addition, the high ratio of p-AKT/AKT indicates that the AKT pathway is activated in the tumor cells (Supplemental Figure 1).

Three weeks after the surgery, the patient was treated with three-dimensional conformal radiotherapy (3D-CRT) for a total dose of 42 Gy in 21 fractions on August 26, 2020 (Figure 2). Next-generation sequencing (NGS) analysis of DNA was performed with the surgical tissue. The results showed the *MGMT* promoter unmethylated, *IDH* wild type, *FGFR3* p.S249C and p53 p.V73fs mutations. The patient was originally scheduled to receive temozolomide (TMZ) chemotherapy concurrent during radiotherapy, but TMZ was discontinued two days later due to a severe skin allergic reaction. Anlotinib is a novel multitarget tyrosine kinase inhibitor that is designed to primarily inhibit VEGFR2/3, FGFR1–4, PDGFR α/β , and c-Kit. Considering the patient's intolerance to TMZ and the unmethylation status of *MGMT*, he was administered 10 cycles of anlotinib 12 mg P.O. every day (days 1–14, 21-day cycle) in combination with irinotecan chemotherapy (days 1 and 8, 21-day cycle) in the next 9 months. During this period, the muscle strength of the patient's right lower limb improved significantly to enable him to walk independently, and he did not experience incontinence again. MRI showed that the tumor slightly shrank, the parenchymal density decreased, and the enhancement weakened. The patient exhibited significant symptom remission and was maintained for approximately 10 months of follow-up. After that, the patient did not come to our hospital again for further treatment due to personal reasons. The patient has now been lost to follow-up. The timeline of treatment and radiographic responses is shown in Figure 3.

Discussion

Spinal cord tumors are less common than intracranial tumors and account for less than 10% of central nervous system tumors. However, PSC GBM is extremely rare, accounting for only 1.5% of all spinal cord tumors.¹¹ PSC GBM has the characteristics of easy local spread and poor prognosis. It can occur in any segment of the spinal cord but is more common in the neck and chest. PSC GBM can occur at any age from children to older adults but has a predilection for younger patients.¹² Additionally, the prognosis of primary spinal cord GBM is worse than that of brain GBM. The reported main causes of death were intracranial metastasis and respiratory failure, which may indicate that the spread of cerebrospinal fluid and the rapid growth of the cervical spinal cord along the nerve fiber bundles are the two main exacerbations of the disease.¹

There is no current consensus on the best treatment for infiltrating PSC GBM due to the rarity of the disease. Current treatments for PSC GBM are similar to those for brain gliomas. The standard treatment is often multimodal, consisting of surgery, concurrent TMZ and radiotherapy, adjuvant chemotherapy and antiangiogenic treatments. The role of radiotherapy in spinal cord gliomas is similarly controversial. In the cases of subtotal resection, several studies revealed an increased PFS with the postoperative radiotherapy. However, due to the limited dose of the organs at risk in the spinal

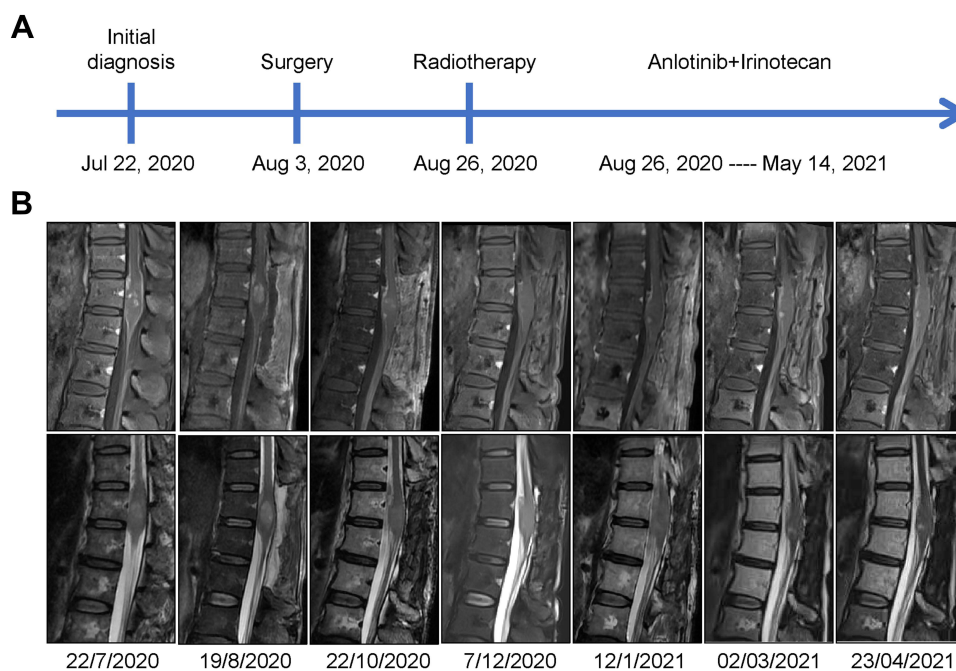


Figure 3 Timeline of treatment and MRI responses. (A) Timeline of the patient's treatment. (B) MRI images of the patient at different times.

cord region, the prescription dose of the PSC GBM could not meet the ideal requirements. This is one of the reasons why the radiotherapy effect of spinal glioma is worse than that of brain glioma. Therefore, it is of great significance to explore more drugs to increase the therapeutic effect of PSC GBM.

In this case report, we describe a 55-year-old patient with a primary spinal glioma with *FGFR* mutation, which is very rare. The role of FGFRs in healthy cells is to mediate cell developmental processes, especially embryogenesis, angiogenesis, and tissue regeneration.¹³ Dysfunction of these receptors leads to abnormal cell signaling. Because FGFRs are present in more than one tissue type, *FGFR* alterations can be observed in different types of cancers, such as urothelial carcinoma, cholangial carcinoma, endometrial cancer, ovarian cancer, breast cancer, non-small cell lung cancer (NSCLC), head and neck cancers, and glioblastomas.¹⁴ S249C mutation is one of the most frequent point mutations in *FGFR3* occurring in the extracellular domain (Figure 4).¹⁵ The resulting cysteine residues from these mutations lead to dimerization of the receptor and ligand-independent signaling.¹⁶ So far, the S249C mutation of *FGFR3* has not been reported in primary spinal glioma. Due to the extensive genomic alterations of *FGFR* across multiple cancer types, numerous FGFR-targeted therapies are currently being evaluated in preclinical and clinical trials. *FGFR* inhibitors

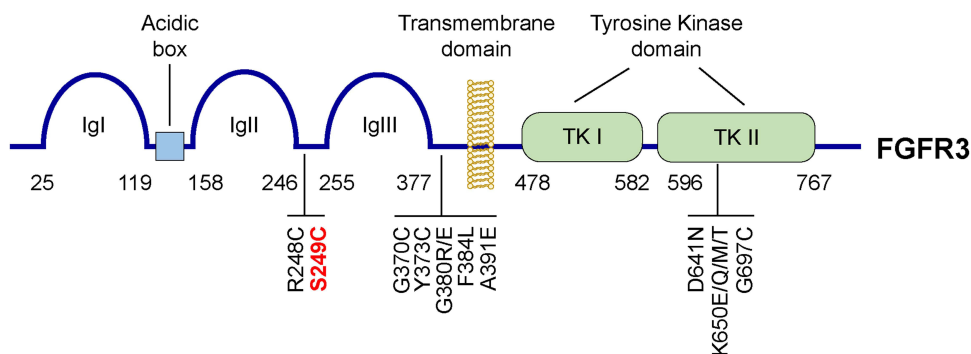


Figure 4 Structure of FGFR3 and the receptors' known mutations with their relative locations. FGFR3 consists of three extracellular immunoglobulin like domains (IgI, IgII and IgIII), followed by a transmembrane domain and two tyrosine kinase domains, TK I and TK II. The somatic mutations reported in cancer patients and their relative location on the protein were labeled at the bottom of the picture.

mainly include small-molecule receptor TKIs (nonselective, selective and covalent), monoclonal antibodies, FGF ligand traps and DNA/RNA aptamers.⁷

p53 is a very important tumor suppressor gene. A rare p53 mutation is also reported in our case. The p53 p.V73fs mutant is caused by the frame shift due to the duplication of cytosine 216 of the gene sequence. This resulted in an error in the sequence from 73 amino acid of the p53 protein and premature termination. This mutation will affect the tumor suppressor effect of p53 protein. Similar mutations have also been reported in the human colon cancer cell-line SM12.¹⁷

Anlotinib is a novel oral multitarget tyrosine kinase inhibitor, which inhibits was originally designed to inhibit VEGFR2/3, FGFR1–4, PDGFR α/β , and c-Kit, resulting in its dual effects on antitumor angiogenesis and tumor growth.¹⁸ It was approved by China Food and Drug Administration for the third-line treatment in advanced NSCLC on May 9, 2018. Hypertension, elevated thyroid-stimulating hormone, hand and foot syndrome, elevated thyroglobulin, elevated total cholesterol, and diarrhea are common adverse events during anlotinib treatment.¹⁹

In this case report, we describe a patient with a rare PSC GBM with *FGFR3* mutation. For this target, the patient received radiotherapy and chemotherapy in combination with anlotinib targeted therapy and achieved satisfactory results. MRI showed that the enhancement weakened, which may also be related to the antivascular effect of anlotinib. After treatment, the patient was able to walk independently and was free of incontinence, which improved the quality of his life significantly.

Abbreviations

PSC GBM, primary spinal cord glioblastoma; OS, overall survival; FGFR, fibroblast growth factor receptor; SNVs, single nucleotide variants; CNAs, copy number amplifications; NSCLC, non-small cell lung cancer; SCLC, small cell lung cancer; MRI, magnetic resonance imaging; WHO, World Health Organization; 3D-CRT, three-dimensional conformal radiotherapy; NGS, next generation sequencing; TMZ, temozolomide.

Ethics Approval and Consent for Publication

This study was approved by the Ethics Committee of the Second Hospital of Shandong University. Written informed consent was obtained from the patient in accordance with the Declaration of Helsinki for the purpose of publication of the present case report and any relevant images.

Funding

This work was supported by a grant (81802816) from the National Natural Science Foundation of China, and a grant from (ZR2019BH029) Shandong Provincial Natural Science Foundation, China.

Disclosure

The authors declare that they have no conflict of interest.

References

1. Cheng L, Yao Q, Ma L, et al. Predictors of mortality in patients with primary spinal cord glioblastoma. *Eur Spine J*. 2020;29(12):3203–3213. doi:10.1007/s00586-020-06515-3
2. Chanchotisationsien A, Xiong J, Yu J, Chu S. Exophytic primary intramedullary spinal cord glioblastoma: case report and critical review of literature. *World Neurosurg*. 2019;122:573–576. doi:10.1016/j.wneu.2018.11.113
3. Adams H, Avendano J, Raza SM, Gokaslan ZL, Jallo GI, Quinones-Hinojosa A. Prognostic factors and survival in primary malignant astrocytomas of the spinal cord: a population-based analysis from 1973 to 2007. *Spine*. 2012;37(12):E727–E735. doi:10.1097/BRS.0b013e31824584c0
4. Ardizzone A, Scuderi SA, Giuffrida D, et al. Role of Fibroblast Growth Factors Receptors (FGFRs) in brain tumors, focus on astrocytoma and glioblastoma. *Cancers*. 2020;12(12):3825. doi:10.3390/cancers12123825
5. Dai S, Zhou Z, Chen Z, Xu G, Chen Y. Fibroblast Growth Factor Receptors (FGFRs): structures and small molecule inhibitors. *Cells*. 2019;8(6):614. doi:10.3390/cells8060614
6. Tiong KH, Mah LY, Leong CO. Functional roles of fibroblast growth factor receptors (FGFRs) signaling in human cancers. *Apoptosis*. 2013;18(12):1447–1468. doi:10.1007/s10495-013-0886-7
7. Krook MA, Reeser JW, Ernst G, et al. Fibroblast growth factor receptors in cancer: genetic alterations, diagnostics, therapeutic targets and mechanisms of resistance. *Br J Cancer*. 2020;124(5):880–892. doi:10.1038/s41416-020-01157-0
8. Li J, Hu K, Huang J, Zhou L, Yan Y, Xu Z. Insights of fibroblast growth factor receptor 3 aberrations in pan-cancer and their roles in potential clinical treatment. *Aging*. 2021;13(12):16541–16566. doi:10.18632/aging.203175

9. Xie X, Lin J, Zhong Y, Fu M, Tang A. FGFR(3S249C) mutation promotes chemoresistance by activating Akt signaling in bladder cancer cells. *Exp Ther Med.* 2019;18(2):1226–1234. doi:10.3892/etm.2019.7672
10. Wang Y, Liang D, Chen J, et al. Targeted therapy with anlotinib for a patient with an oncogenic FGFR3-TACC3 fusion and recurrent glioblastoma. *Oncologist.* 2020;26(3):173–177.
11. Wong AP, Dahdaleh NS, Fessler RG, et al. Risk factors and long-term survival in adult patients with primary malignant spinal cord astrocytomas. *J Neurooncol.* 2013;115(3):493–503. doi:10.1007/s11060-013-1251-y
12. Moinuddin FM, Alvi MA, Kerezoudis P, et al. Variation in management of spinal glioblastoma multiforme: results from a national cancer registry. *J Neurooncol.* 2019;141(2):441–447. doi:10.1007/s11060-018-03054-2
13. Weaver A, Bossaer JB. Fibroblast growth factor receptor (FGFR) inhibitors: a review of a novel therapeutic class. *J Oncol Pharm Pract.* 2020;27:1078155220983425.
14. Helsten T, Elkin S, Arthur E, Tomson BN, Carter J, Kurzrock R. The FGFR landscape in cancer: analysis of 4853 tumors by next-generation sequencing. *Clin Cancer Res.* 2016;22(1):259–267. doi:10.1158/1078-0432.CCR-14-3212
15. Babina IS, Turner NC. Advances and challenges in targeting FGFR signalling in cancer. *Nat Rev Cancer.* 2017;17(5):318–332. doi:10.1038/nrc.2017.8
16. Bernard-Pierrot I, Brams A, Dunois-Larde C, et al. Oncogenic properties of the mutated forms of fibroblast growth factor receptor 3b. *Carcinogenesis.* 2006;27(4):740–747. doi:10.1093/carcin/bgi290
17. Leroy B, Girard L, Hollestelle A, Minna JD, Gazdar AF, Soussi T. Analysis of TP53 mutation status in human cancer cell lines: a reassessment. *Hum Mutat.* 2014;35(6):756–765. doi:10.1002/humu.22556
18. Sun Y, Niu W, Du F, et al. Safety, pharmacokinetics, and antitumor properties of anlotinib, an oral multi-target tyrosine kinase inhibitor, in patients with advanced refractory solid tumors. *J Hematol Oncol.* 2016;9(1):105. doi:10.1186/s13045-016-0332-8
19. Han B, Li K, Wang Q, et al. Effect of anlotinib as a third-line or further treatment on overall survival of patients with advanced non-small cell lung cancer: the ALTER 0303 Phase 3 randomized clinical trial. *JAMA Oncol.* 2018;4(11):1569–1575. doi:10.1001/jamaoncol.2018.3039

OncoTargets and Therapy

Dovepress

Publish your work in this journal

OncoTargets and Therapy is an international, peer-reviewed, open access journal focusing on the pathological basis of all cancers, potential targets for therapy and treatment protocols employed to improve the management of cancer patients. The journal also focuses on the impact of management programs and new therapeutic agents and protocols on patient perspectives such as quality of life, adherence and satisfaction. The manuscript management system is completely online and includes a very quick and fair peer-review system, which is all easy to use. Visit <http://www.dovepress.com/testimonials.php> to read real quotes from published authors.

Submit your manuscript here: <https://www.dovepress.com/oncotargets-and-therapy-journal>