

# Thrombotic Thrombocytopenic Purpura After Radiofrequency Ablation of Hepatocellular Carcinoma: A Case Report

Renbiao Chen, Yonglei Zhao, Pierre Umba Mabombo, Hongjie Hu, Xiaoxuan Zhou

Department of Radiology, Sir Run-Run Shaw Hospital, Zhejiang University, Hangzhou, People's Republic of China

Correspondence: Hongjie Hu, Tel +86 57186006752, Fax +86 57186044817, Email hongjiehu@zju.edu.cn

**Abstract:** Radiofrequency ablation (RFA) has become one of the commonly used treatment methods for hepatocellular carcinoma (HCC). It is widely available in the clinic and presents the advantages of short recovery time and a less invasive approach. Only a few complications, such as hemorrhage, ascites, and duct injury, have been reported after RFA for HCC. Herein, we report for the first time the case of a patient diagnosed with recurrent HCC in whom thrombotic thrombocytopenic purpura (TTP) was diagnosed as a complication of the RFA procedure. A 64-year-old male patient with a 2-year history of resected-stage V HCC, in whom later recurrence occurred, underwent RFA for HCC. This patient had a rapid drop in platelets and some petechiae on the wrists after RFA. Combining the clinical and laboratory tests, the diagnosis of TTP was reached. We immediately used plasmapheresis combined with drug therapy, which successfully treated the clinical condition of TTP, with no evidence of recurrence or other complications 1 year after initial treatment. TTP is a rare complication of RFA procedures. Prompt diagnosis and aggressive treatment measures are critical. Through this case report, we hope to raise awareness of the complications of RFA.

**Keywords:** hepatocellular carcinoma, radiofrequency ablation, thrombotic thrombocytopenic purpura, complication, plasma exchange

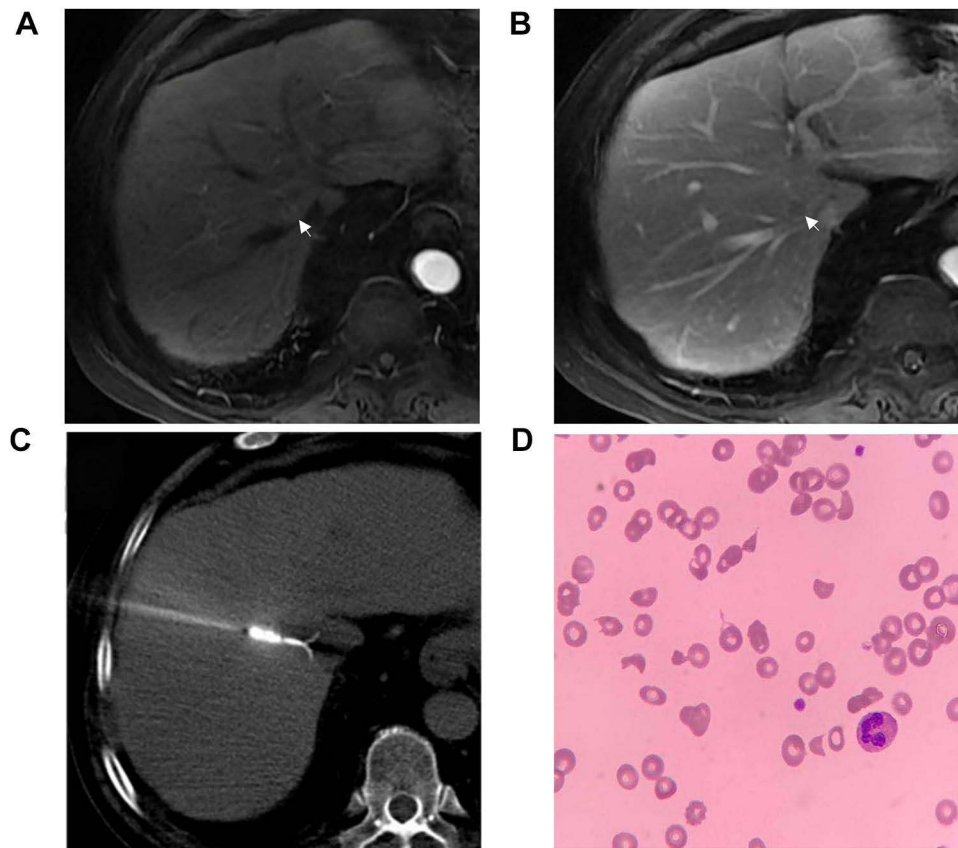
## Introduction

Thrombotic thrombocytopenic purpura (TTP) is a microvascular thrombotic hemorrhage syndrome, which is divided into hereditary and acquired types. The latter can be idiopathic or secondary, according to whether a primary disease is involved. The secondary form of disease and its pathogenesis are not well clarified, but it is mainly caused by infection, drugs, tumor, autoimmune disease, and other factors.<sup>1,2</sup>

Radiofrequency ablation (RFA) has become one of the commonly used treatment methods for hepatocellular carcinoma (HCC). It is widely available in clinics and presents the advantages of short recovery time and a less invasive approach.<sup>3</sup> Although a variety of complications with RFA has been described, the development of TTP has not been reported when treating HCC with RFA. We present for the first time a patient diagnosed with recurrent HCC who developed TTP after RFA.

## Case Report

A 64-year-old male patient underwent segment V laparoscopic hepatectomy for HCC 2 years ago and was regularly followed up at the hepatobiliary surgery clinic. Enhanced magnetic resonance imaging (MRI) of the liver showed, on T2-weighted imaging (T2WI) and diffusion-weighted imaging (DWI), a hyper-signal nodule localized in segment VIII, in the vicinity of the porta hepatica, which was significantly enhanced in the arterial phase (Figure 1A), while the wash-out and pseudo-capsule features could be seen in the delayed phase (Figure 1B). This was consistent with the typical imaging findings of HCC lesions on non-invasive diagnosis. A percutaneous nodule biopsy provided pathological evidence of HCC. Combining the clinical, imaging, and pathological elements, the diagnosis of HCC recurrence was retained. Considering the condition of our patient, with the focus in the patient's liver being close to the main blood vessels,



**Figure 1** (A) Contrast-enhanced liver MRI, early arterial phase, showing a typical image of HCC lesions located in segment VIII, with significant contrast intake. (B) Delayed phase of enhanced liver MRI, showing the wash-out and pseudo-capsule appearance of HCC. (C) Computed tomography-guided radiofrequency ablation was performed to treat the HCC. (D) A peripheral blood smear showed numerous schistocytes.

percutaneous alcohol injection would be likely to damage the blood vessels and cause vascular necrosis. It might even cause alcohol to enter the blood vessels and damage important organs. Cryoablation might also cause energy loss due to the proximity of large blood vessels, resulting in poor treatment results. After discussion with several senior specialists, it was considered that the patient was more suitable for RFA. Thus, the patient was admitted for RFA. The treatment procedure was as follows. With the patient in the supine position, a computed tomography (CT) scan was used to determine the level of the puncture and the entry point of the needle on the body surface. Following local disinfection with iodophor and using sterile cavity towels, 5 mL of lidocaine was injected at the puncture point for local anesthesia. The intrahepatic lesion was punctured with one RFA treatment needle, the CT scan determined that the tip of the needle was located in the lesion, and RFA treatment was performed (parameters: 40 W, 4.5 min). The patient had no discomfort during the operation, and it was again shown that there was no bleeding beside the needle tract. After the operation, the patient had no discomfort and was sent back to the ward. We used the following equipment: RFA machine (MaiDe, China, model S-1500); RF needle (MaiDe, China, model 21-863271, specification: working length 2 cm, needle length 15 cm; 21-863471, specification: working length 3 cm, needle length 15 cm). On the preoperative laboratory evaluation, the patient's platelet count was  $180 \times 10^9/\mu\text{L}$ , which was within normal limits.

On the third day after admission, the patient underwent CT-guided RFA for HCC (Figure 1C). On the fifth day, he had some petechiae on the wrists, his platelet count dropped to  $8 \times 10^9/\mu\text{L}$ , and peripheral blood smears showed a large number of schistocytes (Figure 1D). The activity of ADAMTS-13 was  $<10\%$  and ADAMTS-13 inhibitor was positive. All these elements were consistent with the diagnosis of TTP.

The patient was started on therapy with plasmapheresis immediately after the diagnosis of TTP, and which lasted for 10 days. In addition, the patient was treated with cyclophosphamide injection (400 mg, intravenous drip) on days 10, 14, and 17, and with rituximab injection (700 mg, intravenous drip) on days 25, 32, 39, and 46. The platelet counts gradually

elevated to  $90 \times 10^9/\mu\text{L}$  and the ADAMTS-13 activity was 100% at discharge. There was no recurrence of TTP 1 year after RFA therapy for HCC.

## Discussion

TTP is a thrombotic microvascular disease caused by a lack of von Willebrand factor (vWF) lyase (ADAMTS13) activity, which leads to extensive microvascular thrombosis, resulting in microvascular hemolysis, consumptive thrombocytopenia, and heart, brain, kidney, and other organ dysfunction.<sup>2</sup>

RFA has the advantages of reduced trauma and rapid recovery, and has become a hotspot of interventional therapy for HCC in recent years. RFA for HCC is widely used in the clinic, with only a few reported complications, including abdominal hemorrhage, ascites, and duct injury.<sup>4,5</sup> Herein, we reported a patient with recurrent HCC who developed TTP after RFA.

In this case, the patient denied any history of TTP or known risk factors, and we excluded other factors that might contribute to the development of TTP. Coronavirus disease 2019 (COVID-19) was the first to be excluded. The patient was tested for COVID-19 IgM antibodies, IgG antibodies, and COVID-19 nucleic acid on admission, and the results were negative. The results of the retest before surgery were negative. We thought that the clinical events displayed by the patient were likely to have been caused mainly by RFA. Hepatic stellate cells are not only the key cells in the process of liver fibrosis, but also one of the cell types that produce vWF lyase (ADAMTS13). ADAMTS13 can lyse endothelial cells and release vWF polymers with hemostatic function, thus promoting the antithrombotic effect.<sup>6</sup> We speculate that this process may be caused by the poor basis of liver function in patients with HCC and damage during RFA. The aging of hepatic stellate cells in patients with HCC leads to reduced function, which in turn produces less ADAMTS13 and affects antiplatelet function. In addition, RFA causes vascular and hepatic stellate cell damage to a certain extent, ultimately resulting in the development of TTP. This hypothesis needs to be proven on a cellular molecular level in patients and animal experiments.

The occurrence of TTP is a life-threatening event and is correlated with a high fatality rate, requiring immediate and active management. Plasmapheresis is the first treatment choice, followed by fresh plasma infusion and drug therapy. In this case, our institution recommended the use of plasmapheresis combined with drug therapy, which resulted in the successful treatment of the clinical condition of TTP without any evidence of post-treatment recurrence or other complications 1 year after initial treatment. Through this case report, we hope to raise clinicians' awareness of this rare radiofrequency-related complication.

## Ethics Statement

Details of the case reported in the article were approved by the central institution, Run-Run Shaw Hospital, Zhejiang University School of Medicine.

## Consent for Publication

The patient provided informed consent to publish their case details and any accompanying images.

## Disclosure

The authors report no conflicts of interest in this work.

---

## References

1. Shenkman B, Einav Y. Thrombotic thrombocytopenic purpura and other thrombotic microangiopathic hemolytic anemias: diagnosis and classification. *Autoimmun Rev*. 2014;13(4–5):584–586. doi:10.1016/j.autrev.2014.01.004
2. Joly BS, Coppo P, Veyradier A. Thrombotic thrombocytopenic purpura. *Blood*. 2017;129(21):2836–2846. doi:10.1182/blood-2016-10-709857
3. Decadt B, Siriwardena AK. Radiofrequency ablation of liver tumours: systematic review. *Lancet Oncol*. 2004;5(9):550–560. doi:10.1016/S1473-0245(04)01567-0
4. Maeda M, Saeki I, Sakaida I, et al. Complications after radiofrequency ablation for hepatocellular carcinoma: a multicenter study involving 9411 Japanese patients. *Liver Cancer*. 2020;9(1):50–62. doi:10.1159/000502744
5. Sato M, Tateishi R, Yasunaga H, et al. Mortality and morbidity of hepatectomy, radiofrequency ablation, and embolization for hepatocellular carcinoma: a national survey of 54,145 patients. *J Gastroenterol*. 2012;47(10):1125–1133. doi:10.1007/s00535-012-0569-0
6. Feng Y, Li X, Xiao J, et al. ADAMTS13: more than a regulator of thrombosis. *Int J Hematol*. 2016;104(5):534–539. doi:10.1007/s12185-016-2091-2

Journal of Hepatocellular Carcinoma

Dovepress

### Publish your work in this journal

The Journal of Hepatocellular Carcinoma is an international, peer-reviewed, open access journal that offers a platform for the dissemination and study of clinical, translational and basic research findings in this rapidly developing field. Development in areas including, but not limited to, epidemiology, vaccination, hepatitis therapy, pathology and molecular tumor classification and prognostication are all considered for publication. The manuscript management system is completely online and includes a very quick and fair peer-review system, which is all easy to use. Visit <http://www.dovepress.com/testimonials.php> to read real quotes from published authors.

Submit your manuscript here: <https://www.dovepress.com/journal-of-hepatocellular-carcinoma-journal>