

Analgesic Efficacy of an Ultrasound-Guided Transversus Thoracis Plane Block Combined with an Intermediate Cervical Plexus Block on Postoperative Pain Relief After Trans-Areolar Endoscopic Thyroidectomy: A Single Center Prospective Randomized Controlled Study

Ruipeng Zhong^{1,2,*}, Yun Zou^{3,*}, Shuzhen Bao², Yijian Chen², Guiming Huang², Lifeng Wang³, Li Chen³, Maolin Zhong³, Weidong Liang³

¹Gannan Medical University, Ganzhou, People's Republic of China; ²Department of Anesthesiology, Ganzhou People's Hospital, Ganzhou, People's Republic of China; ³Anesthesia Surgery Center, the First Affiliated Hospital of Gannan Medical University, Ganzhou, People's Republic of China

*These authors contributed equally to this work

Correspondence: Weidong Liang, Anesthesia Surgery Center, the First Affiliated Hospital of Gannan Medical University, No. 128, Jinling West Road, Economic and Technological Development Zone, Ganzhou, Jiangxi Province, 341000, People's Republic of China, Tel +86 15970122157, Email lwd0929@gmu.edu.cn

Purpose: This study aimed to investigate the analgesic effect of ultrasound-guided transversus thoracis plane block (TTPB) combined with intermediate cervical plexus block (ICPB) in the early postoperative period after trans-areolar endoscopic thyroidectomy.

Patients and Methods: A total of 62 female patients undergoing trans-areolar endoscopic thyroidectomy were randomly classified to the TTPB combined with ICPB group with ropivacaine (block group) or superficial cervical plexus block group (control group). The primary outcome measures were resting visual analogue scale (VAS) in the chest area at 6 h after surgery. The secondary outcome measures included chest resting and movement VAS score, neck resting and movement VAS score within 24 h after surgery, intraoperative remifentanyl consumption, postoperative analgesia rate and analgesic requirements and patient satisfaction score for pain management at discharge.

Results: Compared with the control group, the block group at rest showed consistently lower VAS scores in the chest area at 6 and 12 h after operation; the block group at rest showed lower VAS scores in the neck at 6, 12 and 24 h after operation. Regarding movement, the VAS scores of the chest and neck area at 2, 6, 12 and 24 h after the operation were lower in the block group than in the control group. The consumption of remifentanyl, rate of postoperative analgesic requirements, and consumption of postoperative rescue analgesia in the block group were lower than those in the control group. Satisfaction with pain treatment at discharge was higher in the block group than in the control group.

Conclusion: Ultrasound-guided TTPB combined with ICPB provides good analgesic effect in the early postoperative period after trans-areolar endoscopic thyroidectomy.

Keywords: regional anesthesia, nerve block, analgesia, trans-areolar endoscopic thyroidectomy

Introduction

Endoscopic thyroidectomy via the areola approach is one of the important modalities of minimally invasive thyroidectomy; it has the advantages of concealed incision and simultaneous management of bilateral thyroid lesions.^{1,2} Breast endoscopic thyroidectomy requires the establishment of artificial channels above the two nipples and under the chest wall

to separate the chest wall from the pectoralis major muscle to establish operating tunnels in the neck; thus, it is considered a minimally invasive surgery with great invasiveness.³ A total of 35–65% of patients complain about moderate to severe pain after transaxillary endoscopic thyroidectomy.⁴ Endoscopic thyroidectomy involves considerable subcutaneous mobilisation in the chest and parasternal areas and requires carbon dioxide inflation of the operative space,⁵ therefore, patients expectedly experience pain after trans-areolar endoscopic thyroidectomy.

Opioid use remains the mainstay of postoperative analgesia, but studies have shown that perioperative opioid use is associated with social abuse,⁶ which indicates the importance of reducing perioperative opioid use. At present, multimodal analgesia based on nerve block is being widely investigated and has produced encouraging clinical results.⁷ The invasive sites of breast endoscopic thyroidectomy are mainly the anterior chest wall and neck, which are innervated by the intercostal and cervical plexus nerves, respectively. For the analgesia used in this type of surgery, limited studies have been conducted on analgesia in the neck region, whereas no relevant reports have been regarding analgesia in the chest region.

Therefore, we hypothesised that ultrasound-guided transversus thoracis plane block (TTPB) combined with intermediate cervical plexus block (ICPB) can provide good analgesic effects for trans-areolar endoscopic thyroidectomy and reduce the use of opioids during the perioperative period. We present the following article in accordance with the CONSORT reporting checklist.

Materials and Methods

Study Design

This research was a single-center, prospective, randomized, blind, controlled study. It was performed at Ganzhou People's Hospital, Jiangxi, China, approved by our institutional ethics committee and registered in the China Clinical Trial Registry. The study enrolment occurred from 31 March 2022 to 22 September 2022, and written consent was obtained from all participating patients. This report was written following the CONSORT guidelines.

Study Population

Patients scheduled for trans-areola endoscopic thyroidectomy with the following characteristics were included in this study: female, aged 24–60 years and ASA grade 1–2. Patients were excluded in accordance with the following exclusion criteria: coagulopathy, allergy to local anaesthetics, patients who had undergone previous neck, breast or shoulder surgery; patients who have recently used opioids or any other analgesic medication. Withdrawal criteria included patients whose surgical procedures were changed, those who underwent a second operation and those who dropped out of the study.

Randomization and Blinding

Using a computer-generated random number table, all enrolled patients were randomized to the block or control group. The anaesthesiologist performed ultrasound-guided TTPB and ICPB or superficial cervical plexus block. Postoperative data collection was documented by another investigator. Patients and the independent researcher responsible for postoperative follow-up were blinded to allocation. Blinding the anaesthesiologists and surgeons to this study was not possible because receiving a nerve block can lead to significant signs. However, anaesthesiologists and surgeons did not reveal the group assignment to the participants.

Anesthesia and Surgery

Patients in both groups were routinely fasted and instructed to be abstinent preoperatively. Anaesthesia was induced with midazolam 0.05 mg/kg, sufentanil 0.3 µg/kg, propofol 1.5 to 2.5 mg/kg, and rocuronium 1 mg/kg, and the intermittent positive pressure ventilation (IPPV) mode was performed mechanically after endotracheal intubation. Anaesthesia was maintained with propofol and remifentanyl during surgery for a depth of anaesthesia bispectral index (BIS) between 45 and 55 until the end of surgery and flurbiprofen axetil 50mg was intravenously injected at the end of surgery. The patients were monitored in the post-anaesthesia care unit (PACU) after the surgery. Postoperatively, 1 mg butorphanol was injected for analgesia when the VAS score at rest was greater than or equal to 4 or when analgesia was requested.

Surgical procedure: An arcuate incision was made along the medial aspect of the right areola and 50–100 mL saline was injected into the deep subcutaneous fascia below the suprasternal notch. The skin was separated from the fascia through incision. Following subcutaneous tunnel formation, carbon dioxide was inflated and maintained at a constant pressure of 6 mm Hg using laparoscopic instruments. Incision was made at 11 o'clock at the left and right areola position, trocar was used as the main and auxiliary opening, and ultrasonic scalpel and a pair of toothless forceps were placed at the main and auxiliary opening, respectively.

Intervention Measures

The nerve block procedure was performed after induction of general anesthesia.

The block group underwent ultrasound-guided bilateral TTPB combined with ICPB. Routine skin disinfection was performed using a linear 10–13 MHz ultrasound probe. The probe was placed parallel to the sternum, and the T4–T5 intercostal space was identified to show the costal cartilage, pectoralis major muscle, internal intercostal muscle, transversus thoracis muscle, internal mammary artery and pleura. The 22G puncture needle was inserted through the pectoralis major muscle and intercostal internal muscle to the pectoral transverse muscle plane; no blood or air was pumped back, and 0.25% ropivacaine 20 mL was injected. The drug showed fusiform spread in the plane of the transversus thoracis muscle. Ultrasound-guided ICPB involved the following: 1) routine disinfection with ultrasound placed transversely at the midpoint of the posterior border of the sternocleidomastoid muscle to expose the sternocleidomastoid muscle, anterior scalene muscle and middle scalene muscle; 2) insertion of a 22G puncture needle in the plane and injection of 8 mL 0.25% ropivacaine into the space between the sternocleidomastoid muscle and prevertebral fascia.

In the control group, only ultrasound-guided superficial cervical plexus block was performed, and 8 mL 0.25% ropivacaine was injected into the dorsal border of the sternocleidomastoid muscle. Block was repeated on the other side.

Outcomes

The primary outcome was the pain score in the chest area at 6 h after surgery at rest. Secondary outcomes were intraoperative remifentanyl consumption, VAS score in the chest and neck area at 2, 6, 12 and 24 h after surgery at rest and during movement, postoperative analgesic demand rate and requirements, patient satisfaction score with pain treatment at discharge, complications, nausea and vomiting and other adverse reactions. Postoperative pain was assessed by a 10 cm VAS (0 cm, no pain; 10 cm, worst pain). Resting was defined as calm breathing, and movement was defined as deep breathing, coughing or swallowing. Patient satisfaction was determined with the Likert scale at the time of discharge. Specifically, a simple satisfaction survey was conducted to ask patients about their satisfaction with anaesthesia and analgesia, with scores ranging from 1 to 5 (1: very satisfied, 2: satisfied, 3: uncertain, 4: dissatisfied, 5: very dissatisfied).

Sample Size Calculation and Statistical Analysis

The calculation of the patient sample size was based on a pilot study (N=10), in which the VAS score in the chest area at 6 h after surgery at rest was recorded. Results showed a score of 4 ± 1.1 in the control group, with the assumption that the effective difference was a VAS score of 3 in the block group (two-sided $\alpha = 0.05$, power of 90%). A sample size of 26 patients per group was required according to the formula, and we added 20% more patients in the final sample size, considering the possible exclusion for surgical reasons and the possibility of patient withdrawal during the study ($n = 32$ in each group).

Data were analyzed using IBM SPSS Statistics 26.0. Normal distribution was assessed using the Kolmogorov–Smirnov test. Continuous measures that satisfied a normal distribution were described using the mean \pm standard deviation, and differences between groups in terms of outcome parameters, such as age, height, weight, body mass index (BMI) and operative time, were analyzed by independent sample test. Continuous data that did not satisfy a normal distribution were described using median and interquartile range, and differences in VAS pain scores between groups at 2, 6, 12 and 24 h after surgery, opioid consumption and patient satisfaction score were analyzed using the Mann–Whitney *U*-test. Categorical variables, such as ASA classification, type of surgery, postoperative analgesia and adverse reactions, were analyzed using the Pearson Chi-square test. Two-sided *P* values less than 0.05 were considered statistically significant.

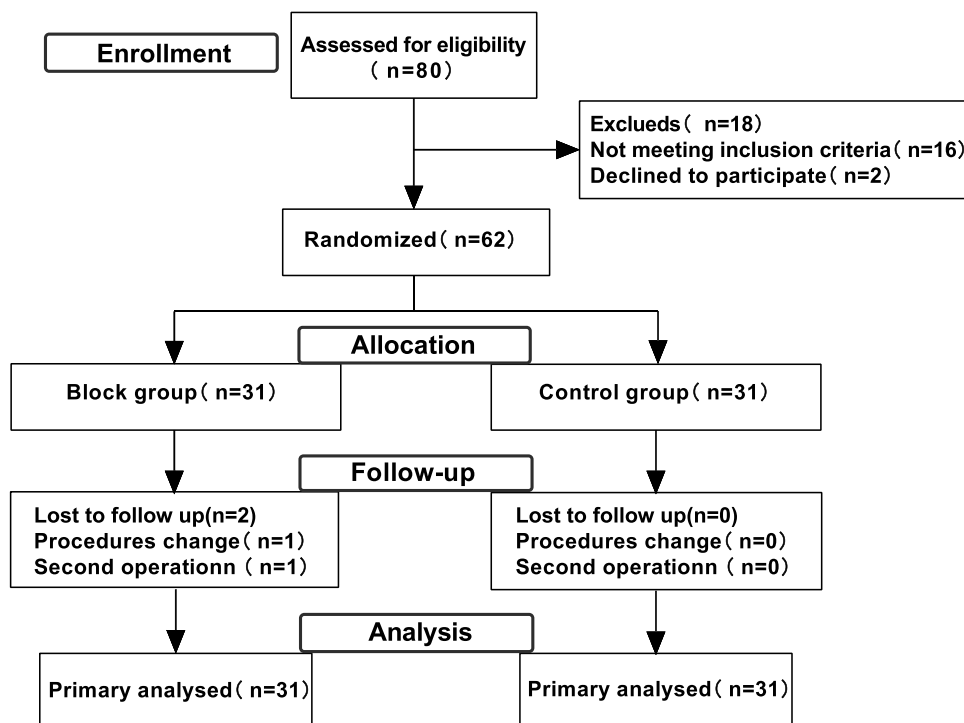


Figure 1 Flow diagram of patients enrolled.

Results

A total of 80 patients were recruited to participate in this study. Exactly 18 patients (16 patients did not meet the inclusion criteria, and 2 declined to participate) were excluded. Finally, 62 patients were randomized and received either of the study interventions (31 in the block group and 31 in the placebo group). All participants received the allocated nerve block per protocol and were included in the intention-to-treat analysis for the primary outcome (Figure 1). Age, weight, height, BMI, ASA class, operation time and extent of operation were not significantly different between the two groups (Table 1).

Table 1 Patient Characteristics and Intraoperative Data

Variable	Block Group (n=31)	Control Group (n=31)	p
Age, Y	33.4 ± 9.1	35.3 ± 8.3	0.389
Weight, kg	56.5 ± 6.2	54.1 ± 5.1	0.099
Height, cm	159.8 ± 3.8	159.9 ± 5.3	0.956
BMI, kg/m ²	22.2 ± 2.7	21.2 ± 1.8	0.089
ASA			0.908
I	25 (80.6%)	26 (83.9%)	
II	6 (19.4%)	5 (16.1%)	
Duration of surgery, min	137.1 ± 29.5	138.3 ± 35.7	0.886
Total thyroidectomy	10 (32.3%)	9 (29%)	0.901

Notes: Data presented as the mean ± SD, and enumeration data are presented as n (%). P < 0.05 was considered statistically significant.

Abbreviations: ASA, American Society of Anesthesiologists; BMI, body mass index.

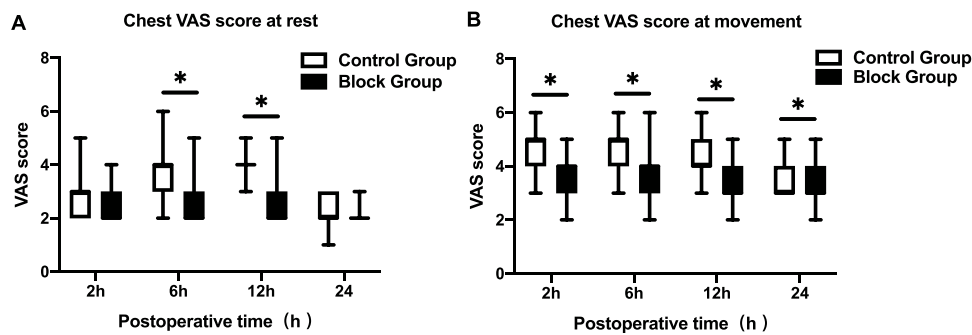


Figure 2 Chest VAS score at rest and during movement. Postoperative VAS scores during the first 24 hours after surgery. **(A)** Chest VAS score at rest; **(B)** Chest VAS score at movement. Data are presented as the median (interquartile range) and displayed as box-and-whisker plots. P values were calculated using the Mann–Whitney *U*-test, and all tests were two-sided. * $P < 0.05$.

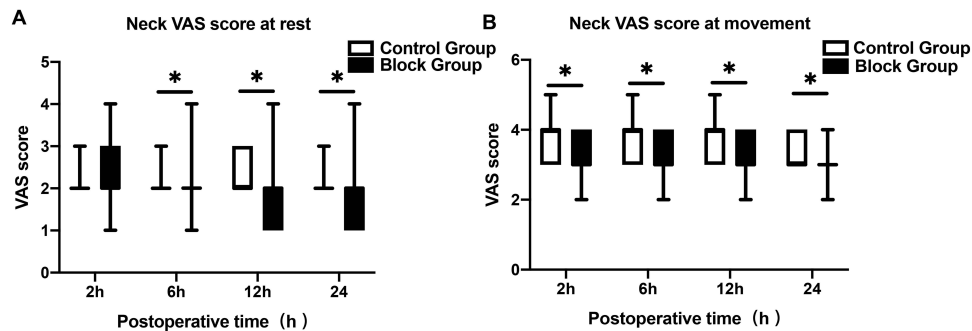


Figure 3 Neck VAS score at rest and during movement. Postoperative VAS scores during the first 24 hours after surgery. **(A)** Neck VAS score at rest; **(B)** Neck VAS score at movement. Data are presented as the median (interquartile range) and displayed as box-and-whisker plots. P values were calculated using the Mann–Whitney *U*-test, and all tests were two-sided. * $P < 0.05$.

Primary outcome: In the chest area, the block group had lower VAS scores than the control group at 6 h after surgery at rest (block group=2 [2–3]; control group=4[3–4]; $p < 0.001$) (Figure 2A).

Secondary outcomes: The resting VAS scores of the chest at 12 h and the neck at 6, 12 and 24 h in the block group were significantly lower than those in the control group (Figures 2A and 3A). Compared with the control group, the block group VAS scores for the chest and neck areas significantly decreased during movement at 2, 6, 12 and 24 h after surgery (Figures 2B and 3B). Remifentanyl consumption during surgery was lower in the block group than in the control group, with a pseudo-median between-group difference of -0.49 (95% CI: -0.064 to -0.033 , calculated with the use of Mann–Whitney *U*-test and Hodges–Lehmann estimate of CIs for pseudo-medians) (Table 2). The analgesic demand rate and

Table 2 Analgesia, Nausea, Vomiting and Pain Treatment Satisfaction

Variable	Block Group (n=31)	Control Group (n=31)	P
Intraoperative remifentanyl ($\mu\text{g}/\text{kg min}$)	0.145 (0.119–0.158)	0.188 (0.169–0.211)	0.000
Analgesic requirements	6 (20.7%)	28 (90.3%)	0.000
Butorphanol consumption (mg)	0 (0–0)	2 (1–2)	0.000
Nausea or vomiting	3 (10.7%)	10 (32.3%)	0.039
Adverse event	0 (0%)	0 (0%)	1.000
Patient satisfaction score	2 (2–3)	3 (2–3)	0.032

Notes: Data presented as median (interquartile range) and enumeration data are presented as n (%). $P < 0.05$ was considered statistically significant. Adverse event: Pneumothorax, local anesthetic toxicity, hematoma, bleeding, pain at site of injection, postoperative hoarseness, dyspnea and Horner's syndrome.

analgesic drug consumption at 24 h after operation were compared between the two groups. The analgesic demand rate in the block group was 20.7%, which was significantly lower than that in the control group (90.3%). The postoperative butorphanol consumption in the block group was lower than that in the control group. The incidence of postoperative nausea and vomiting was lower in the block group (10.7%) than in the control group (32.3%). No significant adverse reactions and complications related to nerve block were observed in both groups. The pain treatment satisfaction at discharge was significantly lower in the placebo group than in the block group (Table 2).

Discussion

In this randomized controlled trial, ultrasound-guided TTPB combined with ICPB can provide good analgesia after trans-areolar endoscopic thyroidectomy, reduce the postoperative rescue analgesia rate and improve patient satisfaction with pain treatment at discharge.

Trans-areolar endoscopic thyroidectomy involves extensive tissue dissection, which can lead to great postoperative pain. Although such procedure is classified as a minimally invasive surgery, it is actually a maximally invasive one.⁸ The main invasion originates from subcutaneous dissection of the chest and neck area, and regional sensation is supported by the intercostal and cervical plexus nerves, respectively. An inappropriate plane invasion can exacerbate pain in the chest area.³ Bijkerk et al⁹ observed that blocking the anterior cutaneous branch of the T2-5 intercostal nerve significantly affected the medial breast image limit and the sensation of areola and nipple in healthy female subjects. TTPB refers to the injection of local anaesthetics between the intercostal and transversus thoracis muscles, and this fascial space is perforated by the anterior cutaneous branch of the intercostal nerve, which innervates the sternum and supports internal mammary sensation.¹⁰ Cadaveric studies have shown that a single-point injection to the T4-5 intercostal space can block the anterior cutaneous branch of the T2-6 intercostal nerve, and compared with injection at T3-4, injection of local anaesthetics at T4-5 has a wider spread and is a more ideal choice.¹¹

In this study, at rest after surgery, the VAS scores at 6 and 12 h in the chest area of the block group decreased, which indicates that TTPB provided a certain analgesic effect during the early postoperative period. No significant difference was observed in the pain scores between the two groups at 2 and 24 h after surgery, and this finding was possibly associated with the use of sufentanil in our anesthesia induction protocol. Meanwhile, at 24 h after surgery, the intensity of chest pain may not be clinically different between the two groups. During movement, the VAS scores of the block group were lower than those of the control group at each assessment time point, which may be due to aggravated pain during exercise, and the analgesic effect of TTPB was highlighted. Other types of surgery have confirmed the analgesic effect of TTPB on the anterior chest wall. Hamed et al¹² applied a transverse thoracic plane block in patients undergoing open-heart surgery and found observed that TTPB reduced postoperative pain scores, reduced and postoperative opioid use and shortened the time of tracheal intubation. Abdelbaser et al¹³ applied transverse thoracic plane block in children undergoing open-heart surgery and drew similar conclusions.

Intercostal nerve block is an important analgesic method for anterior chest wall surgery, but it requires injection at multiple points on the left and right sides, which is cumbersome and increases the risk of infection. In addition, epidural, paravertebral nerve, pectoral nerves block (PECS) and serratus anterior plane blocks have been used for analgesia in anterior chest wall surgery.¹⁴ However, they all have their own shortcomings. Epidural block or paravertebral nerve block operation is complex and involves a risk of epidural haematoma, which renders it inapplicable for patients with coagulopathy.¹⁵ PECS and serratus anterior plane blocks act poorly on the anterior cutaneous branch of the intercostal nerve and are prone to cause analgesia insufficiency in the medial mammary region.^{16,17} Parasternal sternocostal fascia block is far from the thoracic artery and pleura, and its site is easier to identify under ultrasound,¹⁸ it is considered a safer block method than TTPB; however, with the popularisation of ultrasound technology, the safety performance of TTPB has been effectively guaranteed.¹⁹

Superficial cervical plexus block has a good analgesic effect on cervical incisional thyroidectomy,²⁰ but a limited number of studies focused on deeper sensory innervation, including the effects on sternocleidomastoid and sublingual muscles involved in endoscopic thyroid surgery. ICPB refers to the injection of local anaesthetics to the space between the prevertebral and cuffed fascia; it is thought to provide a more complete analgesia, especially for deep structures that may have autonomic sympathetic or visceral distribution of pain.²¹ Syal et al²¹ compared the analgesic effects of superficial cervical nerve block and ICPB in cervical

incision thyroidectomy and observed that compared with superficial cervical nerve block, ICPB resulted in lower postoperative pain scores and decreased need for salvage analgesia. In this study, at 6, 12 and 24 h after the operation, the pain score at rest of the neck area in the block group was lower than that in the control group, which indicates that the ICPB provided effective analgesia for the early postoperative period after endoscopic thyroidectomy. This finding is inconsistent with the results reported by Kim et al²² on transaxillary endoscopic thyroidectomy, possibly because transaxillary endoscopic thyroidectomy mainly addresses unilateral thyroid glands, whereas our study included more bilateral thyroidectomies with greater extent and pain intensity. VAS scores were significantly lower in the ICPB group during swallowing and coughing movements in the early postoperative period, which further confirmed the analgesic effect of cervical nerve block on endoscopic thyroidectomy. With the development of the concept of rapid recovery, it is important to encourage patients to resume diet and exercise as soon as possible. Anatomically, ICPB carries the risk of phrenic nerve block,²³ but Kim et al²⁴ discovered through prospective observations that ICPB using 0.2 mL/kg 0.25% ropivacaine at the C4-5 intervertebral level did not cause ipsilateral hemidiaphragmatic paralysis, which may suggest that ICPB has no significant effect on the phrenic nerve. Opperer et al²⁵ came to a similar conclusion by investigating the effect of different depths of cervical plexus block on phrenic nerve movement. No complications related to phrenic nor vagal block, such as drastic intraoperative hemodynamic changes, postoperative hoarseness, dyspnoea and Horner's syndrome, were observed in this study. This outcome may be related to our choice of local anaesthetics as far away as possible from the carotid artery and slow bolus injection when performing the block, or general anaesthesia possibly masks the associated symptoms. Furthermore, Calderon et al²⁶ reported that although the diffusion of local anaesthetics into the posterior cervical space was observed during ICPB, the spread of local anaesthetics beyond the prevertebral fascia was not detected, which may also be important evidence supporting the concept of the protective quality of prevertebral fascia.

Previous analgesic methods mainly used oral or intravenous analgesics, but the use of perioperative opioids is being re-examined given social concerns about opioid abuse²⁷ In this study, remifentanyl was used during surgery in both groups because from an anatomical point of view, the TTPB does not cover the entire peri-areolar area. The breast skin is innervated by anterior and lateral cutaneous branches of the T2-6 and the nipple/nipple-areola complex primarily by anterior and lateral cutaneous branches of the T3-5 intercostal nerves; The study did not use block such as serratus anterior block to block the lateral rami of the mammary gland. Moreover, the supraclavicular nerves are also important for the upper part of the breast²⁸ and probably for the endoscopic trocar part. However, the remifentanyl dose, postoperative opioid demand rate and demand in the block group were significantly lower than those in the control group, which indicate good frugal opioid effects. A meta-analysis showed that superficial cervical plexus block did not reduce the incidence of postoperative nausea and vomiting,²⁰ and in this study, the incidence of nausea and vomiting in the control group was higher than that in the block group, which may be an adverse effect of postoperative rescue analgesia with butorphanol. Notably, we cannot rule out that pain discomfort in the neck is induced, which needs to be explored in further trials.

Patient satisfaction with treatment is an important reflection of patient-centred care. The Likert scale is a commonly used assessment method for measuring attitudes of respondents towards a particular question and has been widely used in measuring patient satisfaction with treatment. In this study, we investigated patient satisfaction with anaesthesia and analgesia treatment at the time of discharge. The results showed that patients in the block group were more satisfied with pain treatment at discharge than the control group. This finding may be related to a variety of factors. Firstly, nerve block was performed after general anaesthesia, without any discomfort to the patients. Secondly, the patients' postoperative pain was reduced, especially the pain during deep breathing, swallowing and coughing, which lessened the need for rescue analgesia. Moreover, the incidence of nausea and vomiting was lower, which improved the comfort of patients. In addition, ultrasound-guided fascial nerve block has fewer complications, such as infection.²⁹ In this study, no adverse reactions related to nerve blockade, such as pneumothorax, local anaesthetic toxicity, haematoma nor infection, have occurred.

Limitations

This study encountered certain limitations. Firstly, this study did not evaluate the effect after blocking, but ultrasound showed the spread range of local anaesthetics regardless of transversus thoracis or ICPB,³⁰ thus, we believe that the block was effective. Secondly, the concentrations of local anaesthetics used in this study were based on previous studies, and whether different concentrations of local anaesthetics would have an effect on analgesic efficacy remains to be further investigated. Thirdly, acute pain after surgery may result in long-term pain. This study did not follow up the long-term

pain of patients, and the next step will be to investigate this issue. Fourthly, this research was a single-center study, and the selection of patients was female, which has an influence on the credibility of our conclusions. However, despite these limitations, our results demonstrate that combining transversus thoracis block with ICPB decreases pain scores and analgesic use after trans-areolar endoscopic thyroidectomy.

Conclusion

Ultrasound-guided TTB combined with ICPB can provide effective analgesia in the early postoperative period after trans-areolar endoscopic thyroidectomy, especially with regard to pain during deep breathing, coughing and swallowing. Similarly, perioperative opioid use and the incidence of postoperative nausea and vomiting were reduced, and patient satisfaction with pain treatment was improved.

Data Sharing Statement

We would like to share all the individual participant data. The data in this study available from the corresponding author (Weidong Liang, lwd0929@gmu.edu.cn) on reasonable request in two years after this article published online.

Ethics Approval

The authors are accountable for all aspects of the work in ensuring that questions related to the accuracy or integrity of any part of the work are appropriately investigated and resolved. This study was performed in accordance with the Declaration of Helsinki (as revised in 2013), all participants provided written informed consent. The study protocol was approved by the Ethics Committee of Ganzhou People's Hospital (TY-ZKY2021-013-01; January 21, 2022). It was registered at the Chinese Clinical Trial Registry (ChiCTR2200058084) before patient enrollment.

Acknowledgments

This work was supported by the Science and Technology Project of Jiangxi Provincial Health Commission, No.202210876.

The authors thank Huamin Liu, research assistant, for help with data analysis guidance. They also thank the Department of Anesthesiology, Ganzhou People's Hospital for supporting this study.

Disclosure

All authors have completed the ICMJE uniform disclosure form. The authors have no conflicts of interest to declare.

References

1. Jia G, Tian Z, Xi H, Feng S, Wang X, Gao X. Comparison of the breast and areola approaches for endoscopic thyroidectomy in patients with microcarcinoma. *Oncol Lett.* 2017;13:231–235.
2. Sun H, Zheng H, Wang X, Zeng Q, Wang P, Wang Y. Comparison of transoral endoscopic thyroidectomy vestibular approach, total endoscopic thyroidectomy via areola approach, and conventional open thyroidectomy: a retrospective analysis of safety, trauma, and feasibility of central neck dissection in the treatment of papillary thyroid carcinoma. *Surg Endosc.* 2020;34:268–274. doi:10.1007/s00464-019-06762-6
3. Zhang W, Wu QH, Jiang ZG, Qiu M. Subcutaneous dissection area contributes less to endoscopic thyroidectomy-related invasiveness. *Surg Endosc.* 2016;30:4272–4278.
4. Shin S, Chung WY, Jeong JJ, Kang SW, Oh YJ. Analgesic efficacy of bilateral superficial cervical plexus block in robot-assisted endoscopic thyroidectomy using a transaxillary approach. *World J Surg.* 2012;36:2831–2837. doi:10.1007/s00268-012-1780-0
5. Elzahaby IA, Fathi A, Abdelwahab K, et al. Endoscopic thyroidectomy using the unilateral axillo-breast approach versus the modified anterior chest wall approach: a prospective comparative study. *Surg Laparosc Endosc Percutan Tech.* 2018;28:366–370. doi:10.1097/SLE.0000000000000582
6. Waljee J, Li L, Brummett C, Englesbe M. Iatrogenic opioid dependence in the United States: are surgeons the gatekeepers? *Ann Surg.* 2017;265:728–730. doi:10.1097/SLA.0000000000001904
7. Ferrell JK, Shindo ML, Stack BC Jr et al. Perioperative pain management and opioid-reduction in head and neck endocrine surgery: an American head and neck society endocrine surgery section consensus statement. *Head Neck.* 2021;43:2281–2294. doi:10.1002/hed.26774
8. Lu J, Materazzi G, Miccoli M, Baggiani A, Hu S, Miccoli P. Minimally invasive video assisted thyroidectomy versus endoscopic thyroidectomy via the areola approach: a retrospective analysis of safety, postoperative recovery, and patient satisfaction. *Minerva Chir.* 2012;67:31–37.
9. Bijkerk E, Cornelissen AJM, Sommer M, Van Der Hulst R, Lataster A, Tuinder SMH. Intercostal nerve block of the anterior cutaneous branches and the sensibility of the female breast. *Clin Anat.* 2020;33:1025–1032. doi:10.1002/ca.23532
10. Fujii S, Bairagi R, Roche M, Zhou JR. Transversus thoracis muscle plane block. *Biomed Res Int.* 2019;2019:1716365. doi:10.1155/2019/1716365

11. Fujii S, Vissa D, Ganapathy S, Johnson M, Zhou J. Transversus thoracic muscle plane block on a cadaver with history of coronary artery bypass grafting. *Reg Anesth Pain Med.* 2017;42:535–537. doi:10.1097/AAP.0000000000000607
12. Hamed MA, Boules ML, Sobhy MM, Abdelhady MA. The analgesic efficacy of ultrasound-guided bilateral transversus thoracic muscle plane block after open-heart surgeries: a randomized controlled study. *J Pain Res.* 2022;15:675–682.
13. Abdelbaser II, Mageed NA. Analgesic efficacy of ultrasound guided bilateral transversus thoracis muscle plane block in pediatric cardiac surgery: a randomized, double-blind, controlled study. *J Clin Anesth.* 2020;67:110002. doi:10.1016/j.jclinane.2020.110002
14. Chin KJ. Thoracic wall blocks: from paravertebral to retrolaminar to serratus to erector spinae and back again - a review of evidence. *Best Pract Res Clin Anaesthesiol.* 2019;33:67–77.
15. Smith LM, Barrington MJ. Ultrasound-guided blocks for cardiovascular surgery: which block for which patient? *Curr Opin Anaesthesiol.* 2020;33:64–70. doi:10.1097/ACO.0000000000000818
16. Tighe S, Karmakar M. Serratus plane block: do we need to learn another technique for thoracic wall blockade? *Anaesthesia.* 2013;68:1103–1106. doi:10.1111/anae.12423
17. Abu Elyazed M, Abdelghany M, Mostafa S. The analgesic efficacy of pecto-intercostal fascial block combined with pectoral nerve block in modified radical mastectomy: a prospective randomized trial. *Pain Physician.* 2020;23:485–493.
18. Jeleu L, Hristov S, Ovtsharoff W. Variety of transversus thoracis muscle in relation to the internal thoracic artery: an autopsy study of 120 subjects. *J Cardiothorac Surg.* 2011;6:11. doi:10.1186/1749-8090-6-11
19. Sepolvere G, Tognu A, Tedesco M, Coppolino F, Cristiano L. Avoiding the internal mammary artery during parasternal blocks: ultrasound identification and technique considerations. *J Cardiothorac Vasc Anesth.* 2021;35:1594–1602. doi:10.1053/j.jvca.2020.11.007
20. Mayhew D, Sahgal N, Khirwadkar R, Hunter JM, Banerjee A. Analgesic efficacy of bilateral superficial cervical plexus block for thyroid surgery: meta-analysis and systematic review. *Br J Anaesth.* 2018;120:241–251. doi:10.1016/j.bja.2017.11.083
21. Syal K, Chandel A, Goyal A, Sharma A. Comparison of ultrasound-guided intermediate vs subcutaneous cervical plexus block for postoperative analgesia in patients undergoing total thyroidectomy: a randomised double-blind trial. *Indian J Anaesth.* 2020;64:37–42. doi:10.4103/ija.IJA_483_19
22. Kim JS, Lee J, Soh EY, et al. Analgesic effects of ultrasound-guided serratus-intercostal plane block and ultrasound-guided intermediate cervical plexus block after single-incision transaxillary robotic thyroidectomy: a prospective, randomized, controlled trial. *Reg Anesth Pain Med.* 2016;41:584–588. doi:10.1097/AAP.0000000000000430
23. Pandit J, Dutta D, Morris J. Spread of injectate with superficial cervical plexus block in humans: an anatomical study. *Br J Anaesth.* 2003;91:733–735. doi:10.1093/bja/aeg250
24. Kim HY, Soh EY, Lee J, et al. Incidence of hemi-diaphragmatic paresis after ultrasound-guided intermediate cervical plexus block: a prospective observational study. *J Anesth.* 2020;34:483–490. doi:10.1007/s00540-020-02770-2
25. Opperer M, Kaufmann R, Meissnitzer M, et al. Depth of cervical plexus block and phrenic nerve blockade: a randomized trial. *Reg Anesth Pain Med.* 2022;47:205–211. doi:10.1136/rapm-2021-102851
26. Calderon A, Zetlaoui P, Benatir F, et al. Ultrasound-guided intermediate cervical plexus block for carotid endarterectomy using a new anterior approach: a two-centre prospective observational study. *Anaesthesia.* 2015;70:445–451. doi:10.1111/anae.12960
27. Brummett CM, Waljee JF, Goesling J, et al. New persistent opioid use after minor and major surgical procedures in us adults. *JAMA Surg.* 2017;152:e170504. doi:10.1001/jamasurg.2017.0504
28. Smeele HP, Bijkerk E, van Kuijk SMJ, Lataster A, van der Hulst R, Tuinder SMH. Innervation of the female breast and nipple: a systematic review and meta-analysis of anatomical dissection studies. *Plast Reconstr Surg.* 2022;150:243–255. doi:10.1097/PRS.00000000000009306
29. Alakkad H, Naeeni A, Chan VW, et al. Infection related to ultrasound-guided single-injection peripheral nerve blockade: a decade of experience at toronto western hospital. *Reg Anesth Pain Med.* 2015;40:82–84. doi:10.1097/AAP.0000000000000181
30. Murata H, Hida K, Hara T. Transverse thoracic muscle plane block: tricks and tips to accomplish the block. *Reg Anesth Pain Med.* 2016;41:411–412.