


Efficacy of Ultrasound-Guided Thoracic Paravertebral Block on Postoperative Quality of Recovery in Patients Undergoing Percutaneous Nephrolithotomy: A Randomized Double-Blind Placebo-Controlled Trial

Zhirong Yan^{1,*}, Huifen Lin^{2,*}, Ying Yang³, Jialin Yang³, Xueshan Li², Yusheng Yao^{3,4} 

¹Department of Anesthesiology, Fujian Maternity and Child Health Hospital, College of Clinical Medicine for Obstetrics & Gynecology and Pediatrics, Fujian Medical University, Fuzhou, People's Republic of China; ²Department of Anesthesiology, Affiliated Sanming First Hospital of Fujian Medical University, Sanming, People's Republic of China; ³Department of Anesthesiology, Shengli Clinical Medical College of Fujian Medical University, Fujian Provincial Hospital, Fuzhou, People's Republic of China; ⁴Fujian Provincial Key Laboratory of Critical Care Medicine, Fuzhou, People's Republic of China

*These authors contributed equally to this work

Correspondence: Yusheng Yao, Shengli Clinical Medical College of Fujian Medical University, Fujian Provincial Hospital, No.134 Dongjie Street, Fuzhou, People's Republic of China, Tel +86-13559939629, Fax +86-591-88217841, Email fjslyys@126.com

Purpose: This study aimed to examine the effectiveness of ultrasound-guided thoracic paravertebral block on postoperative quality of recovery in patients undergoing percutaneous nephrolithotomy.

Patients and Methods: In this randomized, double-blind, placebo-controlled trial, we enrolled patients scheduled for unilateral percutaneous nephrolithotomy. Patients were randomly allocated to receive thoracic paravertebral block either with 20 mL of 0.5% ropivacaine (PVB group) or an equal volume of saline (control group). The primary outcome was the quality of patient recovery at 24 h postoperatively, assessed using the 15-item Quality of Recovery scale. The secondary outcomes included the area under the curve of pain scores over time, time to first rescue analgesia, and postoperative 24 h morphine consumption.

Results: We analyzed the data of 70 recruited participants. The median Quality of Recovery-15 score at 24 h postoperatively was 127 (interquartile range, 117–133) in the PVB group, which was significantly higher than 114 (interquartile range, 109–122) in the control group, with a median difference of 10 points (95% confidence interval, 5–14; $P < 0.001$). The area under the curve of pain scores over time was lower in patients receiving thoracic PVB than in those receiving saline block ($P < 0.001$). The median time to first rescue analgesia in the PVB group (10.8 h, interquartile range 7.1–22.8 h) was longer than that in the control group (1.9 h, interquartile range 0.5–4.3 h) ($P < 0.001$). Similarly, the median postoperative 24-hour morphine consumption was nearly half as low in the PVB group as in the control group ($P < 0.001$). The occurrence of postoperative nausea and vomiting, and pruritus were significantly higher in the control group ($P = 0.016$ and $P = 0.023$, respectively).

Conclusion: Preoperative ultrasound-guided single injection of thoracic paravertebral block with ropivacaine improved the postoperative quality of recovery and analgesia in patients undergoing percutaneous nephrolithotomy.

Keywords: pain management, quality of recovery, regional anesthesia, ultrasonography

Introduction

Percutaneous nephrolithotomy (PCNL) is the first-line therapeutic strategy for patients with renal stones ≥ 2 cm in size.¹ Although PCNL is a minimal access procedure, patients frequently report postoperative pain and discomfort in the nephrostomy tract. Inadequately controlled pain may delay patient recovery, negatively affect the patient's experience

with the health care system, and even prolong hospital stay.² Traditional pain management with opioids may result in many detrimental side effects, such as respiratory depression, dizziness, postoperative nausea and vomiting (PONV), and constipation.³ Therefore, regional anesthesia-based multimodal analgesic strategies have evolved rapidly in recent years.⁴ This may help reduce perioperative opioid dosage, alleviate postoperative pain, and enhance recovery after surgery.

Ultrasound-guided thoracic paravertebral block (PVB), first described by Hara et al,⁵ is an effective regional anesthetic technique. It provides ipsilateral somatic motor and sensory nerve blocks in multiple contiguous segments, relieving somatic and visceral pain. Some studies have reported ultrasound-guided thoracic PVB for postoperative analgesia in patients undergoing PCNL.^{6,7} They focused primarily on physiological endpoints assessed by an observer, such as pain intensity or the incidence of adverse events. However, these indices can only reflect the transient status as part of overall recovery. Recently, the quality of recovery from the patient's perspective has become an important endpoint of patients' early postoperative health status. To date, the effectiveness of thoracic PVB on the quality of recovery following PCNL has still not been elucidated.

Therefore, in this investigator-initiated, prospective, single-center, double-blind, randomized, placebo-controlled trial, we tested the hypothesis that preoperative ultrasound-guided thoracic PVB would provide better early recovery in patients receiving PCNL.

Methods

Study Design

Ethical approval (Identified number S202046, Chairperson Professor Yin Jingping, on September 27, 2020) was reviewed and granted by the Ethical Committees of Sanming First Hospital, Sanming, China. The participants provided written informed consent during the preoperative anesthesia consultation. Before enrolling the first participant, we registered the study protocol in the Chinese Clinical Trial Registry (ChiCTR2100044013). No methods or study outcomes changed after the study commenced. We conducted the trial in accordance with the guidelines described in the Declaration of Helsinki, the Good Clinical Practice principles, and local regulatory requirements.

Participants

We included adult participants (aged 18–65 years) with an American Society of Anesthesiologists (ASA) physical status of I–II who underwent elective unilateral percutaneous nephrolithotomy. Exclusion criteria included the presence of coagulation disorders, anatomical abnormalities of the genitourinary tract, local infection in the block site, allergy to the study drugs, inability to understand Mandarin, cognitive or psychiatric disorders, preexisting chronic pain or intake of any analgesic drug before surgery, and history of medication or alcohol abuse.

Randomization and Blinding

The participants were randomized in a ratio of 1:1 to receive thoracic PVB using either 0.5% ropivacaine (PVB group) or 0.9% saline (control group) using computer-generated random allocation sequences. The group assignments were concealed in consecutively numbered sealed opaque envelopes. On the day of surgery, a research assistant not involved in the trial opened the envelope and prepared the allocated study medicines (0.5% ropivacaine or 0.9% saline) in identified syringes. An independent researcher who performed thoracic PVB was not involved in further intraoperative anesthesia management or data collection, analysis, and interpretation. Therefore, the participants, surgical team, attending anesthetist, nursing staff, and data collector were concealed from the group allocation.

Ultrasound-Guided Thoracic PVB

Upon arrival in the operating theater, participants received standardized monitoring and intravenous premedication with midazolam (2 mg). Approximately 30 min before surgery, a single experienced anesthesiologist performed the ultrasound-guided thoracic paravertebral block (M-Turbo, FUJIFILM SonoSite, USA), as described by Cowie et al.⁸ The transducer (C60x/5–2 MHz, FUJIFILM SonoSite, USA), covered by a sterile transparent plastic sheath, was placed transversely on the eleventh thoracic vertebral spinous process and moved laterally until the transverse process and

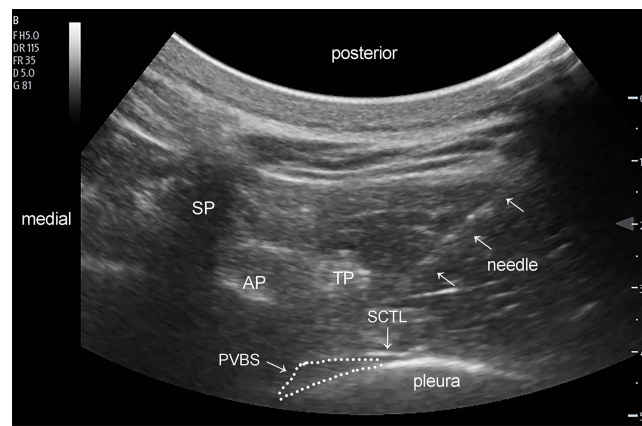


Figure 1 Ultrasound image of in-plane needle advancement into the thoracic paravertebral space at the eleventh thoracic vertebral level.

Abbreviations: AP, articular process; PVBS, paravertebral space; SCTL, superior costotransverse ligament; SP, spinous process; TP, transverse process.

pleura were visualized. We inserted a 22-gauge, 80-mm needle (Stimuplex D; B. Braun, Germany) through the superior costotransverse ligament toward the intended paravertebral space using an in-plane technique (Figure 1). After negative aspiration, 20 mL of the allocated study medicines (0.5% ropivacaine or 0.9% saline) was slowly injected into the T11 paravertebral space.

General Anesthesia and Surgical Protocol

General anesthesia was induced with sufentanil ($0.5 \mu\text{g kg}^{-1}$), etomidate (0.15 mg kg^{-1}), and rocuronium (0.6 mg kg^{-1}). Following endotracheal intubation, dexamethasone (8 mg) and tropisetron (5 mg) were administered as antiemetic prophylaxes. Anesthesia was maintained using inhaled sevoflurane (0.7–1.3 age-adjusted minimal alveolar concentration) to achieve hemodynamic parameters (heart rate and blood pressure) within 80–120% of the preoperative values. At the end of the surgical procedure, neuromuscular blockade was reversed with sugammadex 2 mg kg^{-1} as deemed necessary. Participants were transferred to the PACU after tracheal extubation.

All procedures were performed in the prone position by a designated surgical team. A urethral catheter was first inserted into the renal pelvis, and an ultrasound-guided renal puncture was conducted using an 18-gauge needle. The nephrostomy tract was dilated with fascial dilators up to 24 French. The stone was fragmented using a pneumatic lithotripter and/or a holmium laser via nephroscopy. Antegrade ureteroscopy was routinely performed to extract the residual stone fragments from the ureter. A 16-French nephrostomy catheter was placed after the surgery and removed in the direction of the surgical team.

For postoperative analgesia, participants were administered intravenous parecoxib (40 mg) before surgery, followed by 40 mg twice daily during the first 72 h postoperatively. All participants received morphine patient-controlled intravenous analgesia (PCIA) without basal infusion for rescue analgesia. Only if the numeric rating scale (NRS) pain score exceeded three were the participants instructed to utilize morphine (2 mg) boluses at 10-minute intervals. When participants experienced PONV, intravenous droperidol (0.625 mg) in the PACU or tropisetron (5 mg) in the ward was administered.

Outcomes

The primary outcome was the quality of patient recovery at 24 h postoperatively, which was evaluated using the Chinese version of the 15-item Quality of Recovery (QoR-15) questionnaire.⁹ The QoR-15 scale (range 0–150, in which 150 is the best possible outcome) invited participants to answer 15 subjective questions on five dimensions: pain, physical comfort, physical independence, psychological support, and emotional state. Each item was scored on an 11-point numeric rating scale (NRS) ranging from 0 to 10.¹⁰

The secondary outcomes included area under the curve (AUC) of the NRS pain scores over time, time to first rescue analgesia, postoperative 24-hour morphine consumption, and patient satisfaction. Pain intensity at rest and during activity

(from the supine to the sitting position) was evaluated 1, 3, 6, 12, and 24 h after surgery using the NRS (0 to 10, where 0=no pain and 10=worst pain imaginable). The time to first rescue analgesia was defined as the interval between the end of surgery and the first PCIA dose of opioids. Patient satisfaction with pain management was assessed 24 h postoperatively using a 5-point Likert scale: 1=very dissatisfied, 2=somewhat dissatisfied, 3=neither satisfied nor dissatisfied, 4=somewhat satisfied and 5=very satisfied.¹¹ Thoracic PVB-related adverse events (bleeding, pneumothorax, intrathecal injection, or local anesthetic systemic toxicity) and opioid-related side effects (nausea, vomiting, dizziness, or pruritus) were monitored and documented during the follow-up period. The outcomes were recorded by an independent researcher unaware of the group assignments.

Statistical Analysis

The sample size was estimated according to the QoR-15 score at 24 h postoperatively using Power Analysis & Sample Size (PASS) software 15.0 (NCSS LLC, Kaysville, USA). Based on the pilot study ($n=10$), the QoR-15 score 24 h postoperatively was 115 ± 9.5 . A difference of 8 points in the QoR-15 score between the groups was established as clinically significant.¹² Thus, a sample size of 74 participants (37 per group) would provide 90% power to detect an intervention effect with a 2-sided significance level of 0.05, considering a 15% dropout rate.

Data were analyzed using IBM SPSS Statistics for Windows (Version 25.0, IBM Corp., Armonk, NY, USA) and R statistical software (R version 4.0.5, R Foundation for Statistical Computing Platform). According to the Shapiro–Wilk test, continuous variables are presented as mean (SD) or median [IQR]. Group differences were compared using the independent-samples *t* test or Mann–Whitney *U*-test. Categorical variables were reported as numbers (proportions) and compared using Pearson's chi-squared or Fisher's exact test. The time to first rescue analgesia was analyzed using Kaplan–Meier curves and compared using a Log rank test. The hazard ratio and 95% confidence intervals (CI) were calculated using Cox proportional hazard regression models. Statistical significance was defined as a two-sided *P* value of <0.05 .

Results

We assessed 78 eligible participants between March 2021 and February 2022 at Sanming First Hospital, Fujian Province, China. Four participants were excluded because they did not meet the inclusion criteria or refused to participate. Following randomization, one participant in the PVB group and two in the control group were eliminated from the study because of conversion to retrograde intrarenal stone surgery. Additionally, one participant in the control group experienced postoperative delirium and failed to complete the Q-15 questionnaire. Consequently, we analyzed the data of 70 recruited participants. [Figure 2](#) shows the adapted Consolidated Standards of Reporting Trials (CONSORT) flow diagram.¹³ Baseline characteristics were balanced between the two groups ([Table 1](#)).

Primary Outcome

As presented in [Figure 3](#), the median QoR-15 score at 24 h postoperatively was 127 (IQR, 117–133) in patients receiving thoracic PVB, which was increased by 10 points (95% CI 5–14, $P<0.001$) compared with 114 (IQR, 109–122) in the control group. Except for the psychological support dimension, patients who received thoracic PVB scored higher on the dimensions of pain (2 points), physical comfort (4 points), physical independence (1 point), and emotional state (3 points) ([Supplementary Figure 1](#)).

Secondary Outcomes

The NRS pain score was lower in the PVB group than in the control group, both at rest and during activity, up to 12 hours postoperatively ($P<0.001$, [Figure 4](#)). However, no significant difference in pain intensity was identified 24 h postoperatively (rest, $P=0.096$; activity, $P=0.062$). Similarly, administering a single-shot thoracic PVB with 0.5% ropivacaine before surgery reduced the AUC of the NRS pain scores over the first 24 h ($P<0.001$, [Table 2](#)). As shown in [Figure 5](#), the median time to first rescue analgesia in the PVB group (10.8 h, IQR 7.1–22.8 h) was longer than that in the control group (1.9 h, IQR 0.5–4.3 h) ($P<0.001$). The Cox regression model revealed that the risk of postoperative rescue analgesia requirement in the PVB group was 0.21 (95% CI 0.12–0.35, $P<0.001$) compared with the control group. The

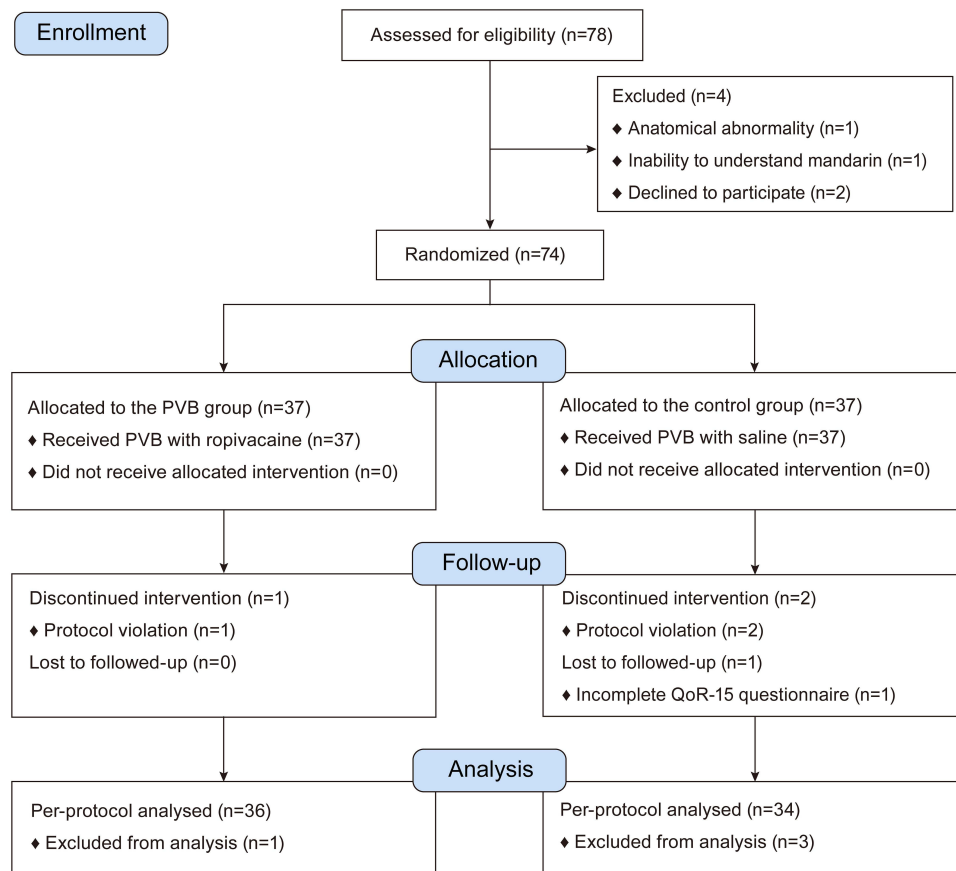


Figure 2 Consolidated Standards of Reporting Trials (CONSORT) flow diagram of the study.

Notes: Schulz KF, Altman DG, Moher D. CONSORT 2010 statement: updated guidelines for reporting parallel group randomized trials. *BMJ*. 2010;340:c332. Copyright: © 2010 Schulz et al. Creative Commons Attribution License.¹³.

Abbreviation: PVB, paravertebral block.

cumulative postoperative 24-hour morphine consumption was nearly half less in participants receiving thoracic PVB with ropivacaine than in those receiving saline block ($P < 0.001$). Correspondingly, thoracic PVB with ropivacaine increased patient satisfaction scores by 1 point (95% CI 1–2; $P < 0.001$). Additionally, PONV occurred in 2 of 36 (6%) participants receiving thoracic PVB with ropivacaine, which was lower than that in 9 of 34 (26%) participants in the control group (relative risk=0.52, 95% CI 0.35–0.78; $P = 0.016$). None of the participants in the PVB group reported pruritus, but 5 of 34

Table 1 Baseline Characteristics

	PVB Group (n=36)	Control Group (n=34)	P value
Age, years	53 [40–61]	51 [48–56]	0.972
Female, n (%)	14 (39%)	18 (53%)	0.238
BMI, kg m ⁻²	22.9 (2.6)	23.9 (3.3)	0.163
Weight, kg	60.8 (10.8)	62.4 (9.6)	0.522
ASA physical status, n (%)			0.459
I	18 (50%)	14 (41%)	
II	18 (50%)	20 (59%)	

(Continued)

Table 1 (Continued).

	PVB Group (n=36)	Control Group (n=34)	P value
Comorbidities, n (%)			
COPD	2 (6%)	3 (9%)	0.669
Diabetes	6 (17%)	9 (26%)	0.318
Hypertension	10 (28%)	8 (24%)	0.684
Myocardial ischemia	7 (19%)	8 (24%)	0.677
Surgical time, min	70 [60–95]	73 [60–100]	0.464
Stone location, n (%)			
Right	18 (50%)	16 (47%)	0.806
Left	18 (50%)	18 (53%)	
Stone size, mm	24.5 [19.8–27]	25 [21.3–28.8]	0.572
Nephrostomy, n (%)	31 (86%)	29 (85%)	>0.99
Nephrostomy tube removal time, hour	29.4 (4.3)	30.5 (5.1)	0.381
Preoperative global QoR-15 score	134 [125–139]	133 [123–138]	0.601

Notes: Data are presented as mean (SD), median [IQR], or n (%).

Abbreviations: ASA, American Society of Anesthesiologists; BMI, body mass index; COPD, chronic obstructive pulmonary disease; PVB, paravertebral block; QoR, quality of recovery.

(15%) in the control group reported pruritus ($P=0.023$, Table 2). No thoracic PVB-related adverse events (such as pneumothorax, bleeding, local anesthetic systemic toxicity, or intrathecal injection) were observed.

Discussion

This study found that patients receiving single-shot thoracic PVB before PCNL achieved a higher QoR-15 score (better recovery) at 24 h postoperatively than patients receiving general anesthesia alone. Furthermore, thoracic PVB provided

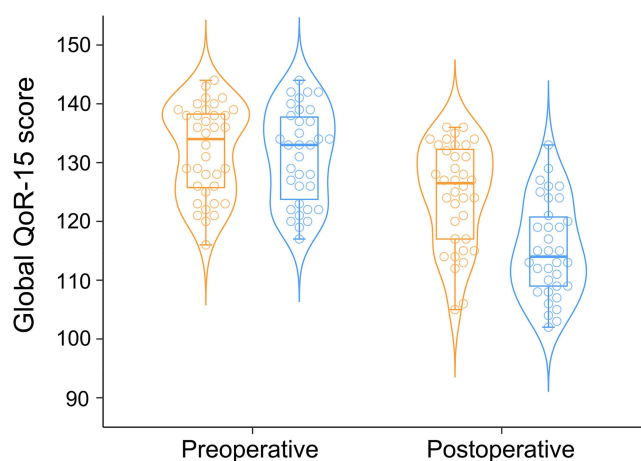


Figure 3 Beeswarm-violin plots show the global QoR-15 scores before and 24 hours after surgery.

Notes: Administration of a thoracic paravertebral block with ropivacaine (orange) improved the global QoR-15 scores by 10 points (95% CI 5–14) compared with the control group (blue) 24 h postoperatively. Each circle in the bee swarm plot represents a sample. The violin plot visualizes the distribution shape of the numerical data using kernel density estimation. Median values are shown as solid lines within the boxes of 25th and 75th percentile values. The whiskers represent data within 1.5 times the interquartile range. Data were compared using the Mann–Whitney *U*-test. Asterisks indicate statistical significance between the two groups ($P<0.05$).

Abbreviations: QoR-15, 15-item quality of recovery questionnaire; PVB, paravertebral block.

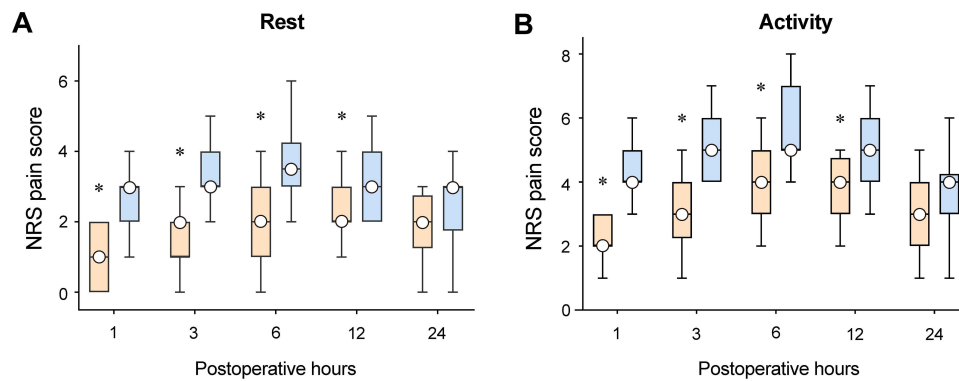


Figure 4 Box plots of postoperative NRS pain scores at rest (A) and during activity (B) in patients allocated to the PVB (Orange) and control (blue) groups. **Notes:** Box edges represent the 25th and 75th percentiles. White dots within the boxes represent medians, and whiskers represent the range. Data were compared using the Mann–Whitney *U*-test. Asterisks indicate statistical significance between the two groups (Bonferroni-adjusted $P < 0.05$). **Abbreviations:** NRS, numeric rating scale; PVB, paravertebral block.

superior postoperative pain alleviation, including a longer time to first rescue analgesia, lower AUC of pain scores, and postoperative cumulative morphine consumption. These findings indicate that ultrasound-guided single-injection thoracic PVB facilitates the quality of recovery in patients undergoing PCNL.

The QoR-15 questionnaire is an excellent patient-centered instrument for assessing the complex and multidimensional processes of postoperative recovery. Substantial evidence has shown that the QoR-15 is valid, reliable, responsive, and clinically acceptable.^{14,15} The QoR-15 has been recommended as one of six standardized endpoints for perioperative clinical trials evaluating patient comfort and pain after surgery.¹⁶ An updated analysis indicated that a score change of six points in the QoR-15 signifies a clinically important improvement.¹⁷ Our study showed that the global QoR-15 score at 24 h postoperatively was 10 points higher in the PVB group than in the control group. This result supported our

Table 2 Secondary Outcomes During the Study Period

	PVB Group (n=36)	Control Group (n=34)	P value
Expired fraction of sevoflurane, %	1.5 [1.4–1.6]	1.85 [1.7–1.9]	<0.001
Length of PACU stay, min	15 [10–15]	15 [15–20]	0.005
Total PCIA morphine dose, mg	19 [2–28]	37 [26–52]	<0.001
AUC of NRS pain scores over 24 hours			
At rest	50.5 [31.9–61.3]	72.5 [53.0–78.4]	<0.001
During activity	82.0 [65.8–98.1]	111.3 [90.3–124.6]	<0.001
Time to first rescue analgesia, hour	10.8 [7.1–22.8]	1.9 [0.5–4.3]	<0.001
Occurrence of PONV, n (%)	2 (6%)	9 (26%)	0.016
Occurrence of dizziness, n (%)	3 (8%)	8 (24%)	0.081
Occurrence of pruritus, n (%)	0	5 (15%)	0.023
Occurrence of CRBD, n (%)	2 (6%)	4 (12%)	0.422
PVB-related adverse event, n (%)	0	0	NA
Patient satisfaction score	4 [4–5]	3 [2–4]	<0.001

Notes: Data are presented as mean (SD), median [IQR], or n (%).

Abbreviations: AUC, area under the curve; CRBD, catheter-related bladder discomfort; NA, not applicable; NRS, numeric rating scale; PACU, postanesthesia care unit; PCIA, patient-controlled intravenous analgesia; PONV, postoperative nausea and vomiting; PVB, paravertebral block.

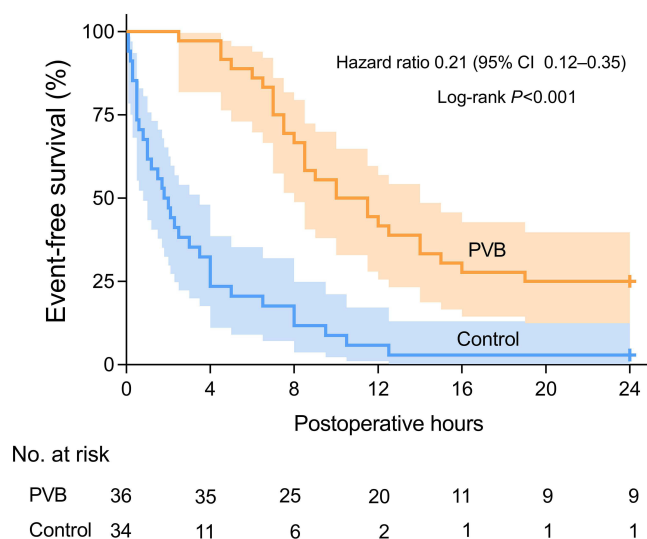


Figure 5 Kaplan–Meier curves depicted rescue analgesia-free survival of participants randomized to the PVB (Orange) and control (blue) groups. Solid lines represent the percentage of participants free from rescue analgesia. The shaded areas indicate the 95% confidence intervals. Cross marks represent that follow-up was censored at 24 hours postoperatively.

Abbreviation: PVB, paravertebral block.

hypothesis that preoperative administration of thoracic PVB may improve the postoperative quality of recovery compared with general anesthesia alone.

Similar to Baldea et al¹⁸ our findings showed that thoracic PVB with ropivacaine provided better analgesia than placebo in the early postoperative period after PCNL. In a randomized prospective study, Yayik et al compared PVB with peritubal infiltration for PCNL, and they stated that PVB decreased opioid consumption and pain scores in the early postoperative period.¹⁹ Hatipoglu Z et al also found that PVB achieved better effective analgesia than intravenous tramadol alone in patients following PCNL.⁷ Postoperative pain after PCNL originates from a lithotripsy tract, typically in the subcostal or 10th to 11th intercostal spaces.²⁰ To achieve adequate analgesia after PCNL, we should block the somatic and visceral nerves innervating the skin, muscle tissue, kidneys, and ureters. Our results indicate that a single injection of thoracic PVB may effectively block the nerves above this area. In addition, ultrasound-guided multiple- and single-injection thoracic PVB provide equivalent dermatomal spread and duration of analgesia.²¹ Therefore, we prefer single-injection thoracic PVB in patients undergoing PCNL to reduce execution time and patient discomfort. However, further research is needed to identify whether a novel long-acting local anesthetic or continuous local anesthetic infusion via a catheter can extend and improve postoperative analgesia.²²

Landmark-based thoracic PVB readily leads to many undesirable events (eg, vascular puncture, pleural puncture, and pneumothorax), and the overall block failure rate is approximately 10%, which impedes this regional anesthesia technique from being utilized in clinical practice.^{23,24} Ultrasound offers real-time image guidance to perform thoracic paravertebral block, helps identify the depth of the paravertebral space, and confirms correct needle tip placement, ultimately improving the feasibility of thoracic PVB and the safety profile.^{25,26} Given that ropivacaine is associated with comparable effective anesthesia, less motor block, and reduced central nervous system and cardiovascular toxicity compared to bupivacaine,²⁷ clinicians have proposed ropivacaine for PVB as a safer option. Therefore, ultrasound-guided thoracic PVB with ropivacaine has gained popularity for anesthesia and analgesia in some settings. Our findings indicated that PVB should be incorporated into postoperative pain management in patients undergoing PCNL, and the requirement of opioids and occurrence of opioid-related side effects would be less or minimal.

This study has several limitations. First, we did not assess the dermatomal sensory distribution of the thoracic PVB and determined block failure before and after the surgery to reduce the risk of unblinding. Nevertheless, the time to first opioid requirement provided some information about the dermatomal spread of thoracic PVB. Second, the follow-up period was only 24 h postoperatively. We believe that the efficacy of a preoperative single-shot thoracic paravertebral

block would not be greater than 24 h after PCNL. Third, we recruited participants using strict selection criteria at a single center, which may limit the generalizability of our findings. Further multicenter studies in the real world are needed to confirm our findings. Fourth, to comply with our clinical practice, intravenous parecoxib (a potent and selective inhibitor of cyclooxygenase-2) was routinely used for all cases, which may partly preclude the advantages of PVB, particularly as PCNL is a minimally access procedure.

Conclusion

In this randomized controlled trial, a single preoperative ultrasound-guided injection of thoracic PVB facilitated postoperative recovery in patients who underwent PCNL. Moreover, thoracic PVB improves postoperative analgesia and reduces postoperative opioid consumption.

Abbreviations

ASA, American Society of Anesthesiologists; AUC, area under the curve; BMI, body mass index; COPD, chronic obstructive pulmonary disease; PACU, post anesthesia care unit; PCNL, percutaneous nephrolithotomy; PCIA, patient-controlled intravenous analgesia; PONV, postoperative nausea and vomiting; PVB, paravertebral block; QoR-15, 15-item quality of recovery questionnaire; NRS, numerical rating scale.

Data Sharing Statement

The individual deidentified participant data used to support the findings of this study can be accessed by the corresponding author (Dr. Yusheng Yao, fjslyys@126.com).

Author Contributions

All authors made a significant contribution to the work reported, whether that is in the conception, study design, execution, acquisition of data, analysis and interpretation, or in all these areas; took part in drafting, revising or critically reviewing the article; gave final approval of the version to be published; have agreed on the journal to which the article has been submitted; and agree to be accountable for all aspects of the work.

Funding

This study was supported by the Natural Science Foundation of Fujian Province (grant number 2021J01378) and Medical Innovation Project of Fujian Province (grant number 2022CXA007).

Disclosure

The authors declare no conflicts of interest.

References

1. Pradère B, Doizi S, Proietti S, et al. Evaluation of Guidelines for Surgical Management of Urolithiasis. *J Urol.* 2018;199(5):1267–1271.
2. Wick EC, Grant MC, Wu CL. Postoperative Multimodal Analgesia Pain Management With Nonopioid Analgesics and Techniques: a Review. *JAMA Surg.* 2017;152(7):691–697.
3. Stein C. New concepts in opioid analgesia. *Expert Opin Investig Drugs.* 2018;27(10):765–775.
4. Mancel L, Van Loon K, Lopez AM. Role of regional anesthesia in Enhanced Recovery After Surgery (ERAS) protocols. *Curr Opin Anesthesiol.* 2021;34(5):616–625.
5. Hara K, Sakura S, Nomura T, Saito Y. Ultrasound guided thoracic paravertebral block in breast surgery. *Anaesthesia.* 2009;64(2):223–225.
6. Liu Y, Yu X, Sun X, et al. Paravertebral block for surgical anesthesia of percutaneous nephrolithotomy: care-compliant 3 case reports. *Medicine.* 2016;95(28):e4156.
7. Hatipoglu Z, Gulec E, Turkcan M, et al. Comparative study of ultrasound-guided paravertebral block versus intravenous tramadol for postoperative pain control in percutaneous nephrolithotomy. *BMC Anesthesiol.* 2018;18(1):24.
8. Cowie B, McGlade D, Ivanusic J, et al. Ultrasound-guided thoracic paravertebral blockade: a cadaveric study. *Anesth Analg.* 2010;110(6):1735–1739.
9. Bu XS, Zhang J, Zuo YX. Validation of the Chinese version of the quality of recovery-15 score and its comparison with the post-operative quality recovery scale. *Patient.* 2016;9(3):251–259.
10. Stark PA, Myles PS, Burke JA. Development and psychometric evaluation of a postoperative quality of recovery score: the QoR-15. *Anesthesiology.* 2013;118(6):1332–1340.

11. Silverberg JI, Gelfand JM, Margolis DJ, et al. Patient burden and quality of life in atopic dermatitis in US adults: a population-based cross-sectional study. *Ann Allergy Asthma Immunol.* 2018;121(3):340–347.
12. Myles PS, Myles DB, Galagher W, et al. Minimal Clinically Important Difference for Three Quality of Recovery Scales. *Anesthesiology.* 2016;125(1):39–45.
13. Schulz KF, Altman DG, Moher D. CONSORT 2010 statement: updated guidelines for reporting parallel group randomized trials. *BMJ.* 2010;340:c332.
14. Kleif J, Waage J, Christensen KB, et al. Systematic review of the QoR-15 score, a patient-reported outcome measure measuring quality of recovery after surgery and anaesthesia. *Br J Anaesth.* 2018;120(1):28–36.
15. Myles PS, Shulman MA, Reilly J, et al. Measurement of quality of recovery after surgery using the 15-item quality of recovery scale: a systematic review and meta-analysis. *Br J Anaesth.* 2022;128(6):1029–1039.
16. Myles PS, Boney O, Botti M, et al. Systematic review and consensus definitions for the Standardized Endpoints in Perioperative Medicine (StEP) initiative: patient comfort. *Br J Anaesth.* 2018;120(4):705–711.
17. Myles PS, Myles DB. An Updated Minimal Clinically Important Difference for the QoR-15 Scale. *Anesthesiology.* 2021;135(5):934–935.
18. Baldea KG, Patel PM, Delos Santos G, et al. Paravertebral block for percutaneous nephrolithotomy: a prospective, randomized, double-blind placebo-controlled study. *World J Urol.* 2020;38(11):2963–2969.
19. Yayik AM, Ahiskalioglu A, Demirdogen SO, et al. Ultrasound-guided low thoracic paravertebral block versus peritubal infiltration for percutaneous nephrolithotomy: a prospective randomized study. *Urolithiasis.* 2020;48(3):235–244.
20. Knoll T, Daels F, Desai J, et al. Percutaneous nephrolithotomy: technique. *World J Urol.* 2017;35(9):1361–1368.
21. Uppal V, Sondekoppam RV, Sodhi P, et al. Single-Injection Versus Multiple-Injection Technique of Ultrasound-Guided Paravertebral Blocks: a Randomized Controlled Study Comparing Dermatomal Spread. *Reg Anesth Pain Med.* 2017;42(5):575–581.
22. Banerjee M, Baranwal A, Saha S, et al. EN3427: a novel cationic aminoindane with long-acting local anesthetic properties. *Anesth Analg.* 2015;120(4):941–949.
23. Lönnqvist PA, MacKenzie J, Soni AK, et al. Paravertebral blockade. *Failure Rate Complications Anaesthesia.* 1995;50(9):813–815.
24. Ardon AE, Lee J, Franco CD, et al. Paravertebral block: anatomy and relevant safety issues. *Korean J Anesthesiol.* 2020;73(5):394–400.
25. Niesen AD, Jacob AK, Law LA, et al. Complication rate of ultrasound-guided paravertebral block for breast surgery. *Reg Anesth Pain Med.* 2020;45(10):813–817.
26. Krediet AC, Moayeri N, van Geffen GJ, et al. Different Approaches to Ultrasound-guided Thoracic Paravertebral Block: an Illustrated Review. *Anesthesiology.* 2015;123(2):459–474.
27. McClellan KJ, Faulds D. Ropivacaine: an update of its use in regional anesthesia. *Drugs.* 2000;60(5):1065–1093.

Publish your work in this journal

The Journal of Pain Research is an international, peer reviewed, open access, online journal that welcomes laboratory and clinical findings in the fields of pain research and the prevention and management of pain. Original research, reviews, symposium reports, hypothesis formation and commentaries are all considered for publication. The manuscript management system is completely online and includes a very quick and fair peer-review system, which is all easy to use. Visit <http://www.dovepress.com/testimonials.php> to read real quotes from published authors.

Submit your manuscript here: <https://www.dovepress.com/journal-of-pain-research-journal>