

Intrabiliary Ascariasis: A Case Report of an Uncommon Cause of Acute Abdomen and Obstructive Jaundice in Children

Kibruyisfaw Weldeab Abore ¹, Tigist Bacha ²

¹Department of Pediatrics, Yirgalem Hospital Medical College, Yirgalem, Ethiopia; ²Department of Pediatrics and Child Health, St. Paul Millennium Hospital Medical College, Addis Ababa, Ethiopia

Correspondence: Kibruyisfaw Weldeab Abore, Department of Pediatrics, Yirgalem Hospital Medical College, Yirgalem, Ethiopia, Email kibruyisfaww@gmail.com

Background: Intrabiliary ascariasis is an uncommon cause of biliary colic and obstructive jaundice among children due to the small size of the ampullary orifice. A high index of suspicion for patients living in an endemic area and radiologic examination are crucial for diagnosis and treatment.

Case Presentation: A 12-year-old male Ethiopian child presented with colicky right upper quadrant pain, nausea, and vomiting for 3 days. Physical examination showed slightly icteric sclera and slightly tender hepatomegaly. Laboratory and ultrasound examinations were suggestive of obstructive jaundice secondary to intra-biliary ascariasis. The child was admitted and followed by conservative management including maintenance fluid, nil per mouth, and analgesics. The abdominal pain and icterus resolved on his second and third day of admission, respectively. A follow-up ultrasound showed that the worm had migrated from the common bile duct. The patient was dewormed with a single dose of oral albendazole 400mg and discharged home. Currently, the patient is well and attending school.

Conclusion: Although biliary ascariasis is an uncommon cause of acute abdomen and obstructive jaundice, it should be suspected among patients from endemic areas presenting with suggestive clinical and laboratory features. Conservative treatment is the treatment of choice for uncomplicated biliary ascariasis patients.

Keywords: intrabiliary ascariasis, acute abdomen, Ethiopia

Background

Ascariasis, a nematode infestation of *Ascaris Lumbricoides*, is a common public health problem affecting predominantly developing nations including Ethiopia.¹ It is estimated to affect up to 1.2 billion individuals worldwide.^{2,3} Ascariasis is associated with poor sanitation and hygiene as it is acquired through oro-fecal transmission after ingesting an ovum which later on changes to a larva.¹ During its life cycle, *Ascaris* can affect various organs including the intestine, biliary tracts, the lungs, and the bladder.^{1,3} Although it is uncommon in children, *Ascaris* can migrate through the ampulla of Vater and cause biliary colic as well as obstructive jaundice due to mechanical obstruction.² Here, we present a case of a 12-year-old child that presented with obstructive jaundice secondary to intrabiliary ascariasis.

Case Presentation

This is a case of a 12-year-old male child from Yirgalem city in southern Ethiopia who presented to Yirgalem General Hospital pediatric emergency with right upper quadrant pain of 3 days duration which was severe, colicky, and lasted around 10 minutes per episode with no aggravating or relieving factors. The pain was followed by nausea and non-bilious vomiting. He had a history of passing *Ascaris* worm one month back for which he was treated with oral albendazole at the local health center. Otherwise, the patient had an unremarkable history. Physical examination revealed that the vital signs were within the normal range and there was a slightly icteric sclera. The liver was slightly tender with a total liver span of 11cm.

Initial laboratory investigation revealed a normal complete blood count and ova of *Ascaris lumbricoides* on stool examination. Liver enzyme Aspartate transaminase (AST) was 86U/L, and alanine transaminase (ALT) was 141U/L. The total and direct bilirubin was 1.84 and 1.31 mg/dl, respectively. Abdominal ultrasound done on the same day showed two adjacent, well-defined, tubular, and hyperechoic structure with a central lucency on subcostal axial view seen within the common bile duct (CBD) and right intrahepatic duct (Figure 1). The CBD was dilated to 1 cm, and the proximal intrahepatic duct is slightly dilated (Figure 2). The report concluded that there were two *Ascaris* worms within the biliary tree.

The patient was admitted to the wards with the assessment of obstructive jaundice secondary to intrabiliary ascariasis for conservative management. He was kept nil per mouth and was put on maintenance fluid. The pain subsided on the second day of admission and the icterus disappeared on the third day of admission. The direct bilirubin had also dropped to 0.54 mg/dl on the third day of admission. A follow-up ultrasound on his fifth post-admission day showed that the duct was empty and the worm had moved out of the biliary system. Liver function test done on the Sixth day showed that ALT has returned to 36 U/L and AST was 48 U/L. Subsequently, he was dewormed with albendazole 400mg single dose and was discharged home on his seventh admission day. Currently, he is doing well with no symptoms, and he has returned to his school.

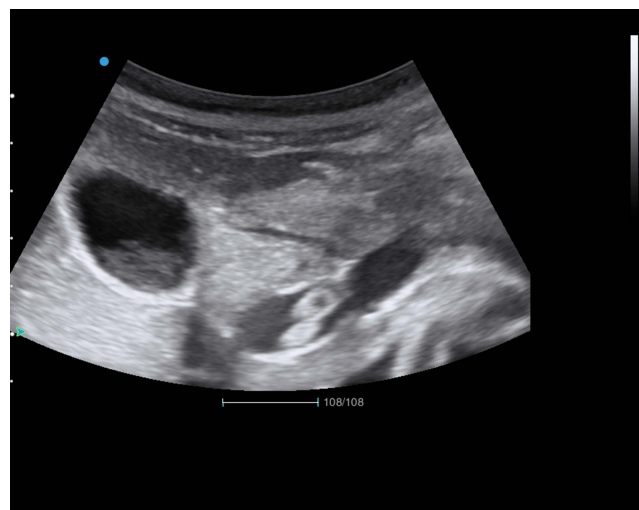


Figure 1 Ultrasound image showing two adjacent *Ascaris* worms in the common bile duct.

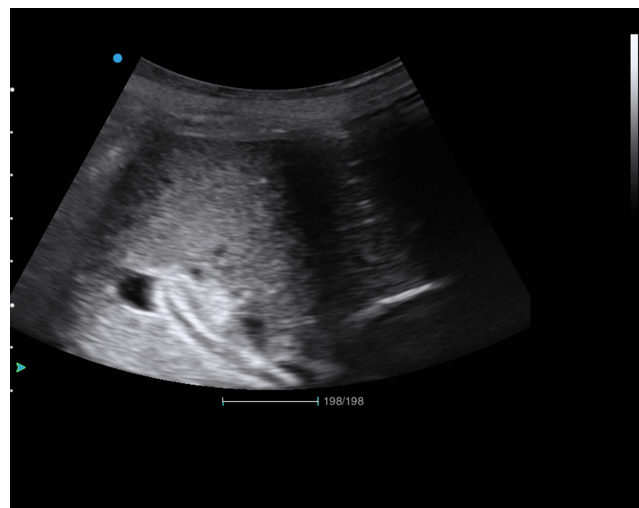


Figure 2 Subcostal axial view showing hyperechoic structures in the common bile duct.

Discussion

The presentation of patients that are infested with *Ascaris* could range from asymptomatic to patients presenting with a life-threatening complication like cholangitis, hepatic abscess, pancreatitis, and peritonitis.² *Ascaris* worm has a high tendency to wander through orifices, especially when there is a high worm burden. Uncommon presentations that occur as a result of the migration of an adult worm via the papilla of Vater into the hepatobiliary system are biliary colic, obstructive jaundice, and ascending cholangitis.⁴

Compared to the adult population, hepatobiliary ascariasis is unusual among the pediatric age group due to the small size of the papilla of Vater which does not easily allow passage of adult worms.² Common risk factors for hepatobiliary ascariasis include heavy worm burden, pregnancy, and previous surgery involving the sphincter of the ampulla of Vater.^{2,5} Similar to our case, the most common symptom of uncomplicated intrabiliary *Ascaris* among children is colicky right upper quadrant pain.

However, various hepatobiliary diseases can mimic intrabiliary ascariasis. If a child presents with biliary colic and/or jaundice, it is important to consider other potential differential diagnoses such as cholelithiasis, cholecystitis, biliary tract stricture, and extrinsic compression of the bile ducts.^{6,7} The diagnosis of hepatobiliary ascariasis is reached through clinical examination and radiologic investigation. Ultrasound is the preferred investigative modality with excellent sensitivity which remarkably increased the diagnosis of biliary ascariasis.²

Conservative management with close follow-up of clinical, laboratory, and radiologic conditions is the preferred treatment modality for patients presenting with biliary ascariasis without complications. Deworming with anthelmintic drugs should be done after the worm spontaneously returns to the small intestine to prevent the dead *Ascaris* from further occluding the biliary tract. Most patients respond to conservative management within 3–5 days with a reported success reaching up to 90%.^{8,9} Endoscopic and surgical removal of worms is reserved for those patients with complications or those who did not respond to conservative management.^{2,8}

Conclusion

Ascariasis is a major public health burden in developing nations including Ethiopia. Patient presentation with ascariasis varies depending on the involved organ. Although not common, biliary ascariasis should be considered as one differential diagnosis for acute abdomen among children from *Ascaris* endemic area.

Data Sharing Statement

The data set and images supporting the conclusions of this case report are included within the article.

Ethical Approval

Ethical clearance was obtained from Yirgalem hospital medical college review board.

Consent for Publication

Informed consent was obtained from the patient's parents for the publication of this case report. Potential identifiers of the patient were excluded from the report.

Acknowledgment

We are grateful to Yirgalem hospital medical college for providing the ethical clearance to conduct this study. We would also like to thank the family of the patient for providing the consent for this study.

Author Contributions

All authors made a significant contribution to the work reported, whether that is in the conception, study design, execution, acquisition of data, analysis and interpretation, or in all these areas; took part in drafting, revising or critically reviewing the article; gave final approval of the version to be published; have agreed on the journal to which the article has been submitted; and agree to be accountable for all aspects of the work.

Funding

The authors received no funding for the study.

Disclosure

The authors declare that they have no conflicts of interest in this work.

References

1. Hadush A, Pal M. Ascariasis: public health importance and its status in Ethiopia. *Air Water Borne Dis.* 2016;5(1):126. doi:10.4172/2167-7719.1000124
2. Chowdri NA, Wani MA, Nisar I, Mehraj A. Worm Infestation Still a Tropical Problem: surgical Issues. *Indian J Surgery.* 2021;1–7. doi:10.1007/s12262-021-02827-w
3. Al-Tameemi K, Kabakli R. Ascaris lumbricoides: epidemiology, diagnosis, treatment, and control. *Asian J Pharm Clin Res.* 2020;13(4):8–11. doi:10.22159/ajpcr.2020.v13i4.36930
4. Smădeanu R, Leșanu G, Nicolaescu R, et al. Ascaris as a cause of acute recurrent pancreatitis in a child. *Romanian J Med PRactice.* 2021;16(4):79. doi:10.37897/RJMP.2021.S4.19
5. Temesgen R, Abebe H, Abera Y. Hepatobiliary and Pancreatic Duct Ascariasis: an Unusual Cause of Obstructive Jaundice and Severe Acute Cholangitis. *Int Med Case Rep J.* 2022;15:281. doi:10.2147/IMCRJ.S369442
6. Inyang B, Koshy FS, George K, et al. An Overview of Ascariasis Involvement in Gallbladder Disease: a Systematic Review of Case Reports. *Cureus.* 2022;14(12):e32545. doi:10.7759/cureus.32545
7. Springer. *Imaging Acute Abdomen in Children*, editor, Avni FE. Switzerland. Springer Nature. 2018. 198–201.
8. Baba A, Shera A, Bhat M, Hakim S, Sheikh K, Shah O. Management of biliary ascariasis in children living in an endemic area. *Eur J Pediatric Surgery.* 2010;20(03):187–190. doi:10.1055/s-0030-1249036
9. Ramareddy RS, Alladi A, Siddapa O, Deepti V, Akthar T, Mamata B. Surgical complications of Ascaris lumbricoides in children. *J Indian Assoc Pediatr Surg.* 2012;17(3):116. doi:10.4103/0971-9261.98130

International Medical Case Reports Journal

Dovepress

Publish your work in this journal

The International Medical Case Reports Journal is an international, peer-reviewed open-access journal publishing original case reports from all medical specialties. Previously unpublished medical posters are also accepted relating to any area of clinical or preclinical science. Submissions should not normally exceed 2,000 words or 4 published pages including figures, diagrams and references. The manuscript management system is completely online and includes a very quick and fair peer-review system, which is all easy to use. Visit <http://www.dovepress.com/testimonials.php> to read real quotes from published authors.

Submit your manuscript here: <https://www.dovepress.com/international-medical-case-reports-journal-journal>