

# Optic Neuritis in a Pediatric Patient with Kikuchi–Fujimoto Disease: A Case Report and Review of the Literature

Shengfang Bao, Hua Huang, Yingying Jin, Fei Ding, Zhen Yang, Xuemei Xu, Chenxi Liu, Xiqiong Han, Liping Wang, Jingyi Lu, Jiani Ma, Yanliang Jin

Department of Rheumatology & Immunology, Shanghai Children's Medical Center, School of Medicine, Shanghai Jiao Tong University, Shanghai, 200127, People's Republic of China

Correspondence: Yanliang Jin, Email [jinyanliang@scmc.com.cn](mailto:jinyanliang@scmc.com.cn)

**Abstract:** Kikuchi-Fujimoto disease (KFD), also known as histiocytic necrotizing lymphadenitis, is a rare, benign, and self-limiting condition characterized by lymph node inflammation. While KFD is rarely associated with ocular manifestations, our case report highlights bilateral optic neuritis in a 13-year-old male patient with KFD. We also provide a comprehensive review of similar cases in the literature.

**Keywords:** Kikuchi-Fujimoto disease, optic neuritis, neuromyelitis optica spectrum disorder, vision deficiency

## Introduction

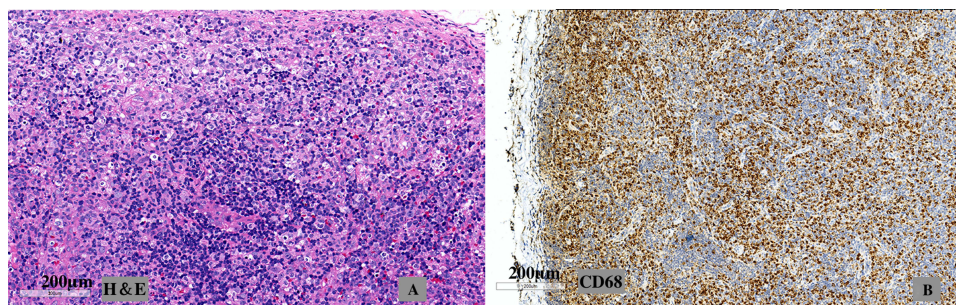
Kikuchi-Fujimoto disease (KFD), also referred to as histiocytic necrotizing lymphadenitis, is a rare, benign, and self-limiting condition characterized by lymph node inflammation. However, the urgent intervention is required in systemic complications of the KFD, which involve generalized lymphadenopathy, arthralgia, rash, night sweats, weight loss, leucopenia, and neurological involvement, including aseptic meningitis, peripheral neuropathy, kinetic tremor and cerebellar ataxia.<sup>1</sup>

While KFD is seldom associated with ocular manifestations, it has been found to present in various forms, including uveitis, retinal vein vasculitis, and optic neuritis (observed in 4 patients, including our case and another patient with neuromyelitis optica spectrum disorder, NMO).<sup>2–4</sup> Alongside the limited instances of optic neuritis associated with KFD in the existing literature, our case report adds to the knowledge by presenting a 13-year-old male patient with KFD and bilateral optic neuritis.

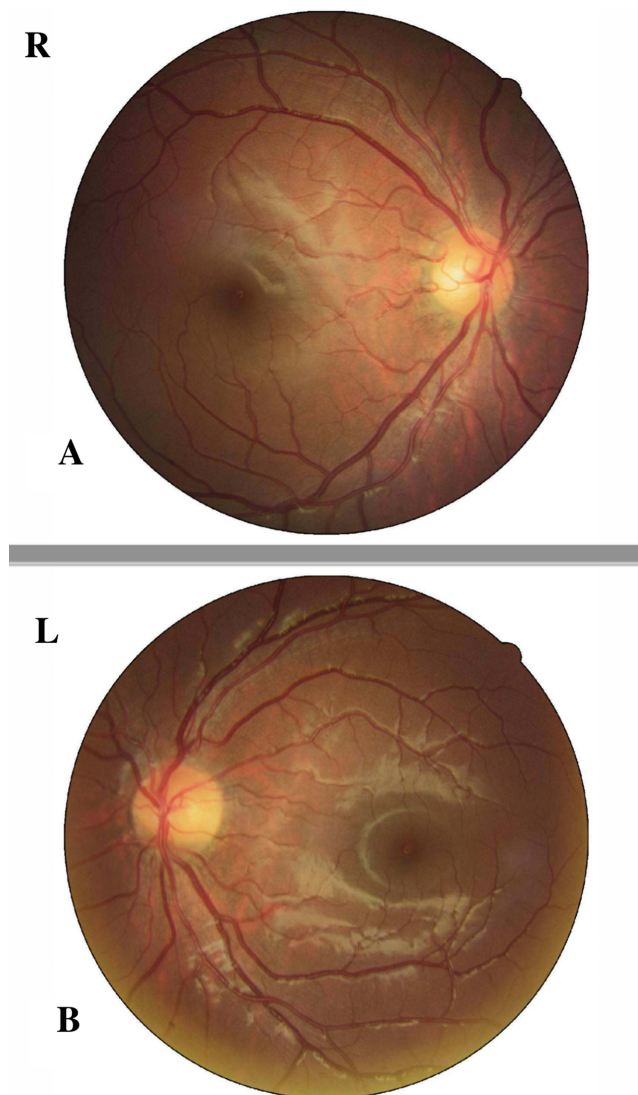
## Case Report

A 13-year-old male patient presented with a recent complaint of fever and vision deficiency in his both eyes. Three months prior to his visit, he had undergone a neck lymph node biopsy, which led to a diagnosis of KFD. The lymph node biopsy revealed the paracortical necrosis without hematoxylin bodies, and the immunohistochemistry showed the positive lysozyme and CD68, consistent with KFD (Figure 1). There was no history of prior radiation treatment history. At the time of his complaint of fever and vision deficiency, he was undergoing treatment with 5 mg of prednisone per day. Except for the KFD, he was healthy previously and was of the Chinese Han ethnicity.

The patient exhibited normal extraocular muscle motility. Funduscopic examination revealed no significant findings (Figure 2). There was no evidence of an afferent pupillary defect (APD). However, static automated perimetry revealed a loss in the visual field in the lower nasal areas of the right eye, and a loss of the upper visual field of the left eye. Compared with reference values,<sup>5</sup> visual Evoked Potential (VEP) found that the P100 latency was prolonged (right: 125ms, left: 120ms), and there was a reduction in the P100 amplitude (right: 3.1  $\mu$ V, left: 9.0  $\mu$ V). The visual acuity and the rest of neurological and physical exam remained normal.



**Figure 1** (A) Cervical lymph node biopsy section: areas of lymphocytic proliferation, apoptotic necrosis, and histiocytes infiltration. (Hematoxylin and Eosin staining). (B) CD68(+) histiocytes visualized on immunohistochemical staining.



**Figure 2** Fundus images of both eyes. The optic disc was not swollen in our case and the retrobulbar optic neuritis was considered.

Laboratory tests revealed elevated levels of erythrocyte sedimentation rate (ESR), C-reactive protein (CRP), and interleukin (IL)-6/-8/-10 and interferon (IFN)- $\gamma$  levels, while the other blood parameters fell within normal ranges. The cerebrospinal fluid (CSF) analysis revealed the following parameters: white blood cell count within normal range at  $0 \times 10^6/L$ , chloride concentration of 122 mmol/L, glucose level of 3.2 mmol/L, lactate dehydrogenase (LDH) of 59 U/L, CSF protein concentration of 333 mg/L. The Pandy test result was negative.

We further ruled out the infection via the metagenomic next-generation sequencing (mNGS),<sup>6</sup> an unbiased method for broad identification of pathogens by sequencing thousands of DNA fragments simultaneously and independently in both the blood and the CSF sample.

The method used for antibody testing was cell-based assay (CBA). Demyelinating antibody tests (AQP4, MOG, GFAP, MBP) and autoimmune encephalitis antibody tests (NMDAR, LGI1, GABABR, CASPR2, AMPAR1, AMPAR2) yielded negative results in both blood and CSF. Oligoclonal bands suggested disruption of the blood–brain barrier (Table 1).

**Table 1** Characteristics and Manifestations of Cases with KFD and on/NMOSD

Study	Our case	Arslan et al <sup>4</sup>	Bouquet et al <sup>2</sup>	Kaku et al <sup>3</sup> (Case with NMOSD)
Age(years)	12	12	30	26
Gender	Male	Female	Female	Female
Time	Three months after the diagnosis of KFD	One year after the diagnosis of KFD	Simultaneous	One year after the diagnosis of KFD, the following day of the induced labor because of the preeclampsia at 36 weeks' gestation
Clinic manifestations	Abnormal vision and fever for a week	Mild color deficiency, specifically red desaturation, in her right eye for a month	Rapidly progressive painless loss of vision of the left eye for 2 weeks associated with impairment in the right visual field	Abnormal vision, headache and paraparesis
Laboratory examination	Elevated ESR/CRP, IL-6/-8/-10 and IFN- $\gamma$ levels	Elevated ESR/CRP levels, other blood test values within the normal ranges	Speckled ANA to 1/800, no abnormality in blood cell count or serum CRP	Not mentioned in the report
CSF	Negative of the pathogen and the autoantibody	Not performed	Negative	CSF and serum IgG-neuromyelitis optica antibodies (also known as aquaporin-4 antibodies) were positive
MRI	A slight thickening and T2 hyperintense signal of the orbital anterior segments of the both optic nerve	Moderate asymmetric T2 hyperintense signal of the right optic nerve. Asymmetric enhancement and thickening of the orbital and intracanalicular segments of the right optic nerve compared with the left, compatible with optic neuritis	T2-hyperintensity of posterior left optic nerve and chiasma, with gadolinium enhancement on T1-weighted sequences; No encephalic or medullar high signal	Brain MRI revealed hyperintensities in bilateral occipital lobes suggestive of PRES along with a lesion in the medulla; Spine MRI revealed an extensive cord lesion spanning from C5 to T10 spinal segments consistent with transverse myelitis
Treatment	IVIg 2g/kg, prednisone 2mg/kg/d	20 mg oral prednisone administration daily that was tapered over three weeks, 375 mg/m <sup>2</sup> rituximab for four weeks	The patient spontaneously recovered normal visual acuity and visual field in 4 weeks, with resolution of MRI abnormalities	Receiving treatment with plasmapheresis and continued prednisone 60 mg/d
Follow-up	Recovered normal visual field in 10 days	Complete resolution with the same color vision in both eyes recovered after one year	No ON relapse or neurological event occurred in a 3-year follow-up	Not mentioned in the report

**Abbreviations:** KFD, Kikuchi-Fujimoto disease; ON, Optic Neuritis; NMOSD, neuromyelitis optica spectrum disorder; IVIG, intravenous immunoglobulin; CSF, cerebrospinal fluid.

Autoantibodies were negative, including anti-double-stranded-DNA (dsDNA), anti-nucleosome, anti-histone, anti-ribosomal P protein, anti-Smith, anti-u1-ribonucleoprotein, anti-Sjögren's syndrome antigen A (SSA)/Ro52, anti-SSA/Ro60, anti-SSB/La, anti-neutrophil cytoplasmic antibodies and rheumatoid factor.

Magnetic resonance imaging (MRI) scans of the brain and orbits with contrast revealed several findings. The imaging indicated a slight thickening and T2 enhancement of the orbital anterior segments of both optic nerves, consistent with optic neuritis (Figure 3). The brain parenchyma showed normal without evidence of mass, or hemorrhage. The MRI of the spinal cord was performed and negative. Malignancy screening, including chest CT and the ultrasound of the abdomen, the pelvis, and testicles, was negative as well.

Normal visual field was restored within 2 days after intravenous immunoglobulin (IVIG) treatment. Although his visual symptoms improved, the fever persisted. Consequently, prednisone was administered at a dose of 2 mg/kg/day, leading to a relief of his fever.

A follow-up ophthalmology exam after one week demonstrated complete resolution with similar visual field in both eyes. Written informed consent was obtained from the patient's parents.

## Discussion

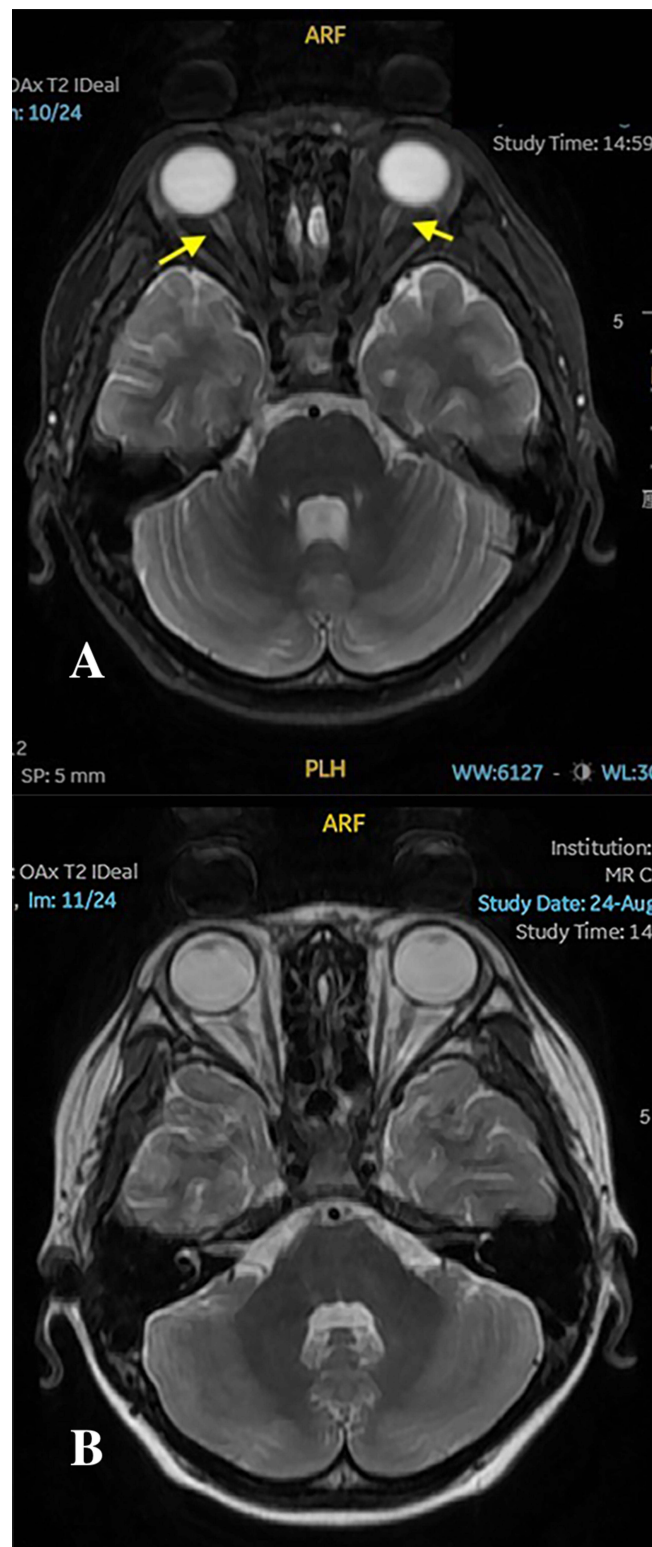
KFD, a rare condition characterized by the histiocytic necrotizing lymphadenitis, typically affects young East Asian females, with a male/female ratio of 1:1.3–4.<sup>1</sup> However, KFD in the pediatric population has a male predominance. A male/female ratio of 1.9:1 and a median age of 10 years in the childhood-onset KFD were previously reported in our hospital.<sup>7</sup> KFD is rarely reported with ocular manifestations, including uveitis, retinal vein, optic neuritis, lacrimal gland involvement, oculomotor palsy, and etc.<sup>4</sup> Our case of a 13-year-old male patient with the KFD and the bilateral optic neuritis illustrates the possibility of considering this association.

Optic neuritis, marked by the acute inflammation of the optic nerve, ranks among the common causes of optic neuropathy.<sup>8</sup> Infection, neoplasm and systemic autoimmune disorders are suspected factors for optic neuritis. In our case, blood/CSF culture and mNGS were negative, so infectious factors were excluded. Bone marrow puncture was performed to rule out neoplastic causes. And three months ago, the lymph node biopsy suggested KFD rather than the tumor. Apart from the infection and the neoplasm, both optic neuritis and KFD have been reported to be associated with systemic autoimmune disorders, such as systemic lupus erythematosus (SLE).<sup>7</sup> In our case, however, clinical presentation and laboratory assessments did not substantiate a diagnosis of SLE. Meanwhile, the optic neuritis occurred 3 months after the diagnose of the KFD in our case. Except for the case of Bouquet et al<sup>2</sup> that the optic neuritis and the KFD occurred simultaneously, the other two reported cases by Arslan et al<sup>4</sup> and Kaku et al<sup>3</sup> of the optic neuritis and the NMOSD occurred one year after the diagnosis of the KFD, respectively. Therefore, we suspected that the optic neuritis in our case might be associated with KFD, as reported in previous cases.<sup>2–4</sup> The basis for the potential association between KFD and optic neuritis lies in the similarity of their cytokine pathways, such as elevated levels of IFN- $\gamma$  and IL-6.<sup>9,10</sup> Meanwhile, the elevation in cytokine levels might also be associated with the symptom of fever during the course of our case. However, the pathogenesis of the optic neuritis and the KFD still needs further investigation. The hypothesized mechanism is as follows. Following the onset of the KFD, lymphocytes may undergo hyperactivation, leading to the elevated production of inflammatory cytokines.<sup>9</sup> This heightened cytokine activity subsequently triggers the activation of T cells, and consequently, CD8+ T cells or antibodies may target and attack neuron.<sup>9</sup>

In comparison to previous studies,<sup>2,4</sup> this case improves upon the differentiation of optic neuritis from other possibilities through comprehensive spinal magnetic resonance imaging (MRI) and antibody profiling in CSF. These measures help distinguish optic neuritis from conditions such as tumor, multiple sclerosis (MS), acute disseminated encephalomyelitis (ADEM), and NMOSD. Notably, a case of NMOSD following optic neuritis in an adult with a history of KFD has been reported in the previous literature.<sup>3</sup> In our case, MRI findings and CSF tests found no positive evidence. To be noticed, early identification of myelin oligodendrocyte glycoprotein-IgG associated disorders (MOGAD) and NMOSD is crucial because patients with these conditions are at risk of permanent vision loss and neurological disability resulting from relapses.<sup>11</sup>

In the recommendation for optic neuritis treatment, intravenous methylprednisolone (IVMP) pulse therapy is recommended during the acute phase, especially those with bilateral eye involved.<sup>12–14</sup> Although high-dose intravenous





**Figure 3 (A)** A slight thickening and T2 hyperintense signal of the orbital anterior segments of the both optic nerve. The yellow arrow indicates the slight thickening of the nerve. **(B)** T2WI of the optic nerve.

corticosteroids do not significantly alter the long-term visual prognosis, they do accelerate initial recovery.<sup>14</sup> However, in our case, the reason for not using IVMP initially was that this pediatric patient had been on steroids for a period during the treatment of KFD. Additionally, before initiating the IVMP therapy, time was required for completing procedures

such as the bone puncture and the MRI for differential diagnosis. After the initial IVIG, the child's visual field did indeed improve, but the body temperature did not subside. When infectious and neoplastic factors were ruled out, 2mg/kg IVMP was promptly added, and the fever was relieved very soon. IVMP was continued for 5 days and then changed to the oral administration.

Further studies are necessary to testify whether a combination of the IVIG and the prednisone might lead to good outcomes at the acute stage.<sup>13,14</sup> It remains controversial whether the IVIG therapy could exhibit promising outcomes in reducing relapse and delaying the progression from the optic neuritis to the MS.<sup>15</sup> Surveying the limited case reports, one case of the simultaneous onset of KFD and optic neuritis exhibited spontaneous remission.<sup>2</sup> Furthermore, in another previous pediatric case report of the KFD with the optic neuritis by the Mayo Clinics,<sup>4</sup> steroids and the anti-CD20 therapy were performed and achieved good results. In a case of the NMOSD in an adult patient following the KFD, plasma exchange was conducted.<sup>3</sup> The choice of treatment method still depends.

The recurrence rates differed between adult patients (28% and 35% at 5 and 10 years of follow-up) and pediatric patients (only 5%).<sup>16,17</sup> Meanwhile, Optic Neuritis Treatment Trial (ONTT) reported 50% of adult optic neuritis patients, especially those with lesions on MRI develop MS after 15 years of follow-up.<sup>18</sup> While in children, the meta-analysis reported that 9–32% developed MS after 6.3 years of the follow-up.<sup>19,20</sup> Even though the reported cases of the optic neuritis in the KFD were limited, there have been no documented instances of recurrence so far.<sup>2–4</sup> All in all, the ongoing monitoring is necessary for patients with optic neuritis. To be noticed, the only predictor of 1-year visual acuity was visual acuity at baseline. This may correlate with the mechanism of “point of no return”, which means crossing the line of damage leads to the permanent neurological disability.<sup>21</sup>

## Limitation

The relationship between KFD and optic neuritis remains to be studied.

## Conclusion

In summary, this case underscores the importance of paying more attention to the optic neuritis associated with the KFD. Vigilant monitoring and multidisciplinary evaluations, including specialized imaging, serological and CSF assessments, are crucial for the accurate diagnosis and the timely intervention. Further research and comprehensive studies are warranted to elucidate the intricate connections between KFD and optic neuritis, shedding more light on this rare association.

## Ethical Approval and Consent

This was a study based on a retrospective chart review. The trial protocol was approved by the ethics committee of Shanghai Children's Medical Center (SCMCIRB-K2022068-1). Written informed consent was obtained from the parents.

## Consent to Publish

The patient and the guardian consented to the submission of the case report to the journal.

## Funding

The study was supported by Clinical Research Center for Children's Systemic Lupus Erythematosus, School of Pediatrics, School of Medicine, Shanghai Jiao Tong University (ELYZX202102).

## Disclosure

The authors report no conflicts of interest in this work.

## References

1. Mahajan VK, Sharma V, Sharma N, et al. Kikuchi-Fujimoto disease: a comprehensive review. *World J Clin Cases*. 2023;11(16):3664–3679. doi:10.12998/wjcc.v11.i16.3664
2. Bouquet F, Maillart E, Vignal C, et al. Optic neuritis revealing Kikuchi-Fujimoto disease. *Mult Scler*. 2014;20(8):1140–1142. doi:10.1177/1352458514525000

3. Kaku M, Shin S, Goldstein M, et al. Neuromyelitis optica spectrum disorder in a patient with Kikuchi-Fujimoto disease. *Neurol Neuroimmunol Neuroinflamm.* 2016;3(3):e221. doi:10.1212/NXI.0000000000000221
4. Arslan A, Kraus CL, Izbudak I. Optic neuritis as an isolated presentation of Kikuchi–Fujimoto disease in a pediatric patient. *Balkan Med J.* 2020;37(3):172–173. doi:10.4274/balkanmedj.galenos.2019.2019.11.88
5. Tekavcic-Pompe M, Stirn-Kranjc B, Breclj J, Breclj J. Optic neuritis in children--clinical and electrophysiological follow-up. *Doc Ophthalmol.* 2003;107(3):261–270. doi:10.1023/B:DOOP.0000005335.28820.05
6. Tang W, Zhang Y, Luo C, et al. Clinical application of metagenomic next-generation sequencing for suspected infections in patients with primary immunodeficiency disease. *Front Immunol.* 2021;12:696403. doi:10.3389/fimmu.2021.696403
7. Liu C, Jin Y, Huang H, et al. Kikuchi-Fujimoto disease as the initial manifestation of systemic lupus erythematosus complicated with macrophage activation syndrome: two case reports and a review of literature. *BMC Pediatr.* 2022;22(1):673. doi:10.1186/s12887-022-03703-6
8. Benard-Seguin E, Costello F. Optic neuritis: current challenges in diagnosis and management. *Curr Opin Neurol.* 2023;36(1):10–18. doi:10.1097/WCO.0000000000001128
9. Wang X, Shi Z, Zhao Z, et al. The causal relationship between neuromyelitis optica spectrum disorder and other autoimmune diseases. *Front Immunol.* 2022;13:959469. doi:10.3389/fimmu.2022.959469
10. Deckert-Schlüter M, Schlüter D, Schwendemann G. Evaluation of IL-2, sIL2R, IL-6, TNF-alpha, and IL-1 beta levels in serum and CSF of patients with optic neuritis. *J Neurol Sci.* 1992;113(1):50–54. doi:10.1016/0022-510X(92)90264-L
11. Kuhlmann T, Moccia M, Coetzee T, et al. Multiple sclerosis progression: time for a new mechanism-driven framework. *Lancet Neurol.* 2023;22(1):78–88. doi:10.1016/S1474-4422(22)00289-7
12. Gise RA, Heidary G. Update on pediatric optic neuritis. *Curr Neurol Neurosci Rep.* 2020;20(3):4. doi:10.1007/s11910-020-1024-x
13. Wingerchuk DM, Banwell B, Bennett JL, et al. International consensus diagnostic criteria for neuromyelitis optica spectrum disorders. *Neurology.* 2015;85(2):177–189. doi:10.1212/WNL.0000000000001729
14. Bennett JL, Costello F, Chen JJ, et al. Optic neuritis and autoimmune optic neuropathies: advances in diagnosis and treatment. *Lancet Neurol.* 2023;22(1):89–100. doi:10.1016/S1474-4422(22)00187-9
15. Pozzilli C, Pugliatti M, Vermersch P, et al. Diagnosis and treatment of progressive multiple sclerosis: a position paper. *Eur J Neurol.* 2023;30(1):9–21. doi:10.1111/ene.15593
16. Hoorbakht H, Bagherkashi F. Optic neuritis, its differential diagnosis and management. *Open Ophthalmol J.* 2012;6(1):65–72. doi:10.2174/1874364101206010065
17. Yeh EA, Graves JS, Benson LA, et al. Pediatric optic neuritis. *Neurology.* 2016;87(9 Suppl 2):S53–8. doi:10.1212/WNL.0000000000002822
18. Optic Neuritis Study Group. Visual function 15 years after optic neuritis: a final follow-up report from the optic neuritis treatment trial. *Ophthalmology.* 2008;115(6):1079–1082.e5. doi:10.1016/j.ophtha.2007.08.004
19. Waldman AT, Stull LB, Galetta SL, et al. Pediatric optic neuritis and risk of multiple sclerosis: meta-analysis of observational studies. *J Aapos.* 2011;15(5):441–446. doi:10.1016/j.jaapos.2011.05.020
20. Chang MY, Pineles SL. Pediatric optic neuritis. *Semin Pediatr Neurol.* 2017;24(2):122–128. doi:10.1016/j.spen.2017.04.004
21. Banerjee A, Ng J, Coleman J, et al. Outcomes from acute attacks of neuromyelitis optica spectrum disorder correlate with severity of attack, age and delay to treatment. *Mult Scler Relat Disord.* 2019;28:60–63. doi:10.1016/j.msard.2018.12.010

## Publish your work in this journal

The Journal of Inflammation Research is an international, peer-reviewed open-access journal that welcomes laboratory and clinical findings on the molecular basis, cell biology and pharmacology of inflammation including original research, reviews, symposium reports, hypothesis formation and commentaries on: acute/chronic inflammation; mediators of inflammation; cellular processes; molecular mechanisms; pharmacology and novel anti-inflammatory drugs; clinical conditions involving inflammation. The manuscript management system is completely online and includes a very quick and fair peer-review system. Visit <http://www.dovepress.com/testimonials.php> to read real quotes from published authors.

Submit your manuscript here: <https://www.dovepress.com/journal-of-inflammation-research-journal>