

Minimally Invasive Direct Internal Cycloplexy in the Management of Goniotomy-Related Cyclodialysis Cleft with Hypotony Maculopathy

Masato Matsuo ^{1,2}, Sho Ichioka¹, Akiko Harano ¹, Yuji Takayanagi¹, Masaki Tanito¹

¹Department of Ophthalmology, Shimane University Faculty of Medicine, Izumo, Japan; ²Department of Ophthalmology, Gifu University Graduate School of Medicine, Gifu, Japan

Correspondence: Masato Matsuo, Department of Ophthalmology, Shimane University Faculty of Medicine, Enya 89-1, Izumo, Shimane, 693-8501, Japan, Tel +81-853-20-2284, Fax +81-853-20-2278, Email matsuondmc@gmail.com

Introduction: Although ab-interno trabeculotomy-related (goniotomy-related) surgeries has a favorable safety profile, cyclodialysis cleft refractory to conservative management could occur, thereby requiring additional surgical treatment. External and, more recently, internal cycloplexy have been attempted to treat cyclodialysis clefts with hypotony maculopathy, however the traditional methods require conjunctival or scleral incisions and have been inappropriate for glaucoma patients who need to undergo future trabeculectomy. Therefore, we report two cases who underwent a novel reliable technique for suture fixation of the detached ciliary body onto the original scleral bed directly through the intraocular approach without conjunctival or scleral incision, minimally invasive direct internal cycloplexy, in the management of goniotomy-related cyclodialysis cleft with hypotony maculopathy.

Case Description: Goniotomy-related cyclodialysis cleft exceeded 45° and vision-threatening hypotony maculopathy was observed in two eyes in two patients with normal tension glaucoma and myopia gravis without a prior history of trauma who had undergone Kahook Dual Blade goniotomy combined with cataract surgery. The patients were followed conservatively for a while, however the cyclodialysis clefts and hypotony maculopathies did not resolve. Therefore, a 72-year-old man underwent minimally invasive direct internal cycloplexy on postoperative day 65 after the goniotomy, and another 67-year-old man underwent minimally invasive direct internal cycloplexy on postoperative day 149. In both cases, topical antibiotic and steroid eye drops were prescribed postoperatively. The cyclodialysis clefts were repaired successfully; however, the latter patient developed delayed-onset acute transient ocular hypertension 33 days after minimally invasive direct internal cycloplexy and required glaucoma medications. The hypotony maculopathies resolved approximately 3 months after suturing, and eventually visual acuity improved from preoperative levels and good intraocular pressure control was achieved in both. No further postoperative complications have been observed to date.

Conclusion: We successfully managed two cases of goniotomy-related cyclodialysis cleft with hypotony maculopathy using minimally invasive direct internal cycloplexy.

Keywords: cycloplexy, cyclodialysis cleft, hypotony maculopathy, ab-interno trabeculotomy, surgical complication

Introduction

Ab-interno trabeculotomy-related surgery (AITS), ie, minimally invasive glaucoma surgery, has gained in popularity recent years. Compared with trabeculectomy, the gold standard for ocular surgery, AITS offers a moderate reduction in intraocular pressure (IOP) and glaucoma with medication due to the favorable safety profile, ability to be combined with cataract surgery, and no need for postoperative procedures.¹ IOP control can be achieved by eliminating aqueous flow resistance by cleavage of the trabecular meshwork (TM) and inner walls of Schlemm's canal, which restores the natural outflow pathways.^{2,3} Kahook Dual Blade (KDB, New World Medical, Rancho Cucamonga, CA, USA) goniotomy is a well-known AITS that employs a single-use ophthalmic knife with two parallel blades designed to remove a strip of TM tissue and the inner wall of Schlemm's canal without injuring surrounding tissues.^{4,5} Although KDB goniotomy has a favorable safety profile, cyclodialysis cleft could occur in up to 1.2% of cases refractory to conservative management,

thereby requiring additional treatment as with the other AITs.^{3–9} Blunt ocular trauma is the most common cause of cyclodialysis clefts, and such iatrogenic causes secondary to ocular surgery are not uncommon.¹⁰

Cyclodialysis cleft with hypotony maculopathy is a rare complication that occurs due to the disruption of the circumferential insertion of the meridional ciliary muscle fibers into the scleral spur. This creates an abnormal secondary pathway for the drainage of aqueous humor into the suprachoroidal space, resulting in chronic ocular hypotony via both increased aqueous outflow and decreased aqueous production.^{3,7,9–11} Many treatment options exist for managing cyclodialysis clefts. The conservative approach is with cycloplegics, whereas semiconservative methods include laser photocoagulation, transscleral diathermy, and cryotherapy. These methods are optimal for small clefts of less than 30°–45° when the patient is not fit for or does not consent to surgery despite their unpredictable and suboptimal outcomes.^{10–13}

Therefore, surgical management is selected for clefts wider than 30–45°. Traditionally, external direct cycloplexy has been performed, which involves suture fixation of the detached ciliary body (CB) onto the original scleral wall under direct visualization through the extraocular approach.^{10–13} However the procedure is also problematic due to the need for surgical expertise, a suboptimal success rate (50%), and associated complications.^{10,11} External indirect cycloplexy also has some drawbacks, such as the need for multiple sutures perpendicular to the corneal limbus, suture-related complications, and difficulty when performed with the blind technique, resulting in incomplete sutures.^{10,14,15}

Thus, internal cycloplexy techniques are increasingly recommended because of the easier procedures, offering higher success rates and better safety profiles and are thus viable alternatives to external cycloplexy.^{10,16,17} In the two cases reported here, the extent of cyclodialysis clefts exceeded 45° with vision-threatening hypotony maculopathy. Given these conditions, we chose to perform internal direct cycloplexy, which we have previously reported for traumatic cyclodialysis repair.¹⁸ Moreover, since existing internal direct cycloplexy methods require conjunctival or scleral incision, which is inappropriate for patients who might undergo trabeculectomy, a filtration surgery, we devised a new suture fixation technique, minimally invasive direct internal cycloplexy (MIDIC), for approaching the ciliary sulcus through a corneal incision without creating a conjunctival or scleral incision.

Case Presentation

Case 1

A 72-year-old man was referred for treatment of normal tension glaucoma (NTG) and cataract in the right eye (OD). He also had myopia gravis and epiretinal membrane (ERM). No complications of systemic diseases or a prior history of trauma were noted. Our initial examination revealed a best corrected visual acuity (BCVA) of 20/50 with a manifest refraction of S-7.5D=C-1.25D A × 50°, and IOP was 17 mmHg without medication. Gonioscopy revealed Shaffer's grade IV open angle with no abnormal angle findings. Slit-lamp examination revealed a moderate cataract, mild ERM, and optic disk cupping with a vertical cup-to-disk (C/D) ratio of 0.8. Humphrey visual field test showed early glaucomatous visual field loss with a mean deviation (MD) of -4.95 dB. The axial length was 28.6 mm, as measured with an OA-2000 optical biometer (Tomey, Nagoya, Japan). Therefore, we performed KDB goniotomy combined with cataract surgery and resected the inferior nasal TM by 90°. At that time, a cyclodialysis cleft was inadvertently created along with anterior chamber hemorrhage. Ophthalmic solutions of 1.5% levofloxacin and 0.1% betamethasone sodium phosphate were prescribed four times a day for 1 month postoperatively.

On postoperative day (POD) 6, the patient's BCVA was 20/1000, and IOP was 5 mmHg OD. A 90-degree nasal cyclodialysis cleft was revealed with gonioscopy. Anterior segment optical coherence tomography (AS-OCT) confirmed the nasal cyclodialysis cleft and anterior chamber-superior choroidal space traffic along with a 360-degree ciliochoroidal detachment. On POD 24, the BCVA was 20/100 with a manifest refraction of S-3.0D=C-1.5D A × 20°, and IOP was 7 mmHg. OCT further indicated hypotony maculopathy. On POD 59, the BCVA was 20/100 with a manifest refraction of -2.0 and IOP of 5 mmHg, with no improvement in angle findings and worsening of hypotony maculopathy. Gonioscopy confirmed the post-goniotomy cyclodialysis cleft of about 90° (Figure 1A–D). The patient agreed to the surgical repair, and MIDIC was performed on POD 65.

On POD 7 after MIDIC, the BCVA was 20/100 with a manifest refraction of S-0.75D=C-2.5D A × 20° and IOP of 3 mmHg OD. The nasal cyclodialysis cleft and anterior chamber-superior choroidal space traffic were repaired, along

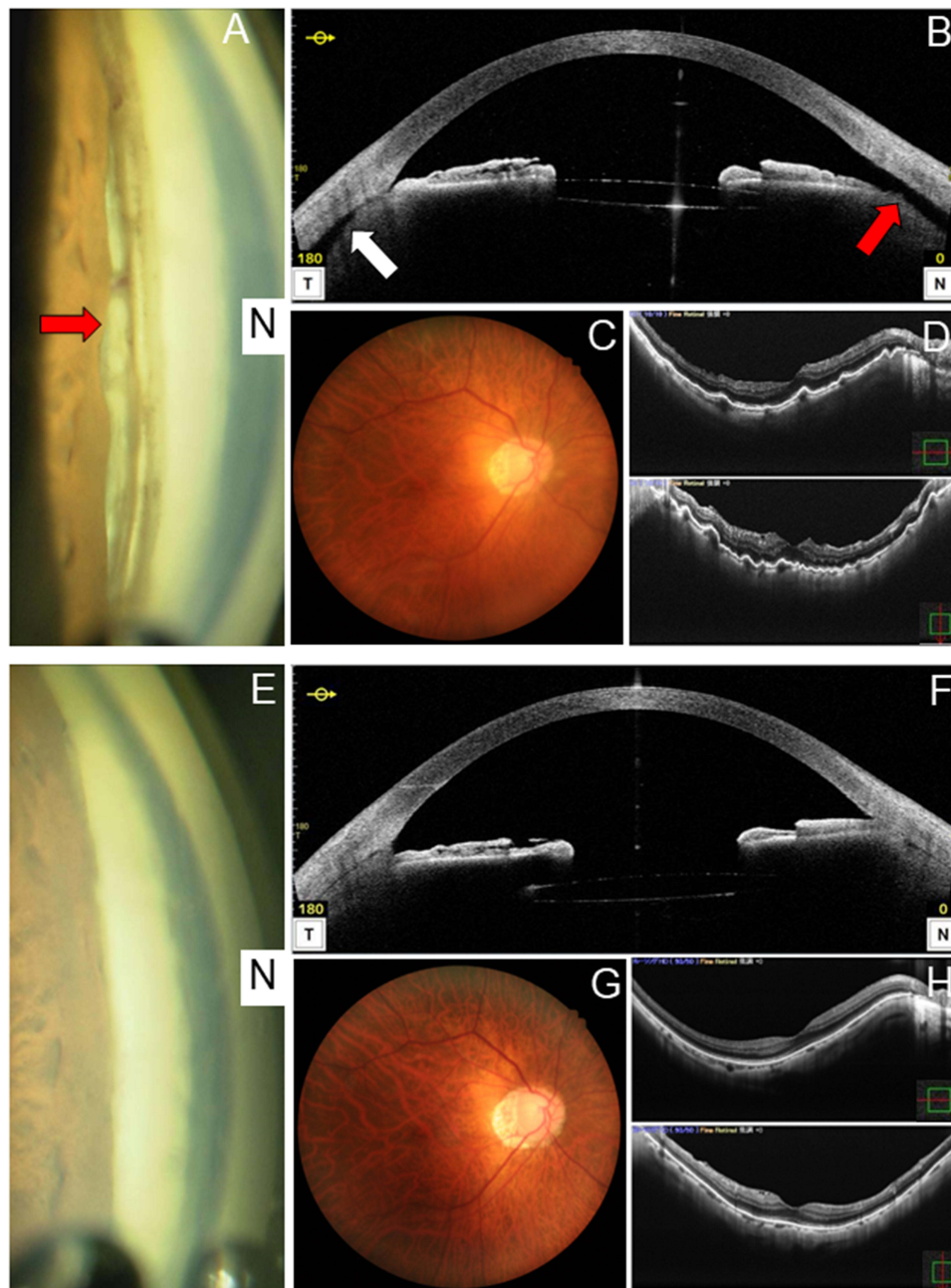


Figure 1 Angle and fundus findings before and after minimally invasive direct internal cyclopepsy in case 1. **(A)** Preoperative gonioscopy in the nasal angle. The red arrow indicates a post-goniotomy cyclodialysis cleft of about 90°. **(B)** Preoperative anterior segment optical coherence tomography (AS-OCT) in the horizontal direction confirming the presence of a cleft (red arrow) along with a 360-degree ciliochoroidal detachment (white arrow). Anterior chamber-superior choroidal space traffic is clear. **(C)** Preoperative fundus camera image showing mild dilation and vascular tortuosity. **(D)** Preoperative OCT showing chorioretinal folds, which indicates hypotony maculopathy. **(E)** Postoperative gonioscopy finding in the nasal angle. The cyclodialysis cleft is repaired. Scattered peripheral anterior synechiae formations are visible after the cyclopepsy. **(F)** Postoperative AS-OCT in the horizontal direction confirming repair of the cleft and disappearance of the ciliochoroidal detachment. **(G)** Postoperative fundus camera image showing mild dilation and vascular tortuosity are improved. **(H)** Postoperative OCT finding showing improved chorioretinal folds and the return of the retinal shape to normal, which indicates the resolution of hypotony maculopathy.

with decreasing ciliochoroidal detachment. On POD 21, the BCVA was 20/40 with a manifest refraction of S-1.0D=C-3.0D A × 30° and IOP of 15 mmHg. The ciliochoroidal detachment had disappeared by then. On POD 103, the BCVA was 20/20 with a manifest refraction of S-2.0D = C-2.0D A × 20° and IOP of 9 mmHg, with resolution of the hypotony maculopathy (Figure 1E–H). Finally, BCVA improved from preoperative levels, and good IOP control was achieved. No postoperative complications have been observed to date.

Case 2

A 67-year-old man was referred for treatment of NTG and cataract OD. He also had myopia gravis. No complications of systemic diseases or a prior history of trauma were noted. Our initial examination revealed a BCVA of 20/40 with a manifest refraction of S-5.0D = C-1.0D A × 80° and IOP of 15 mmHg. Medications included topical administration of 0.002% omidenepag isopropyl (OMDI) QID and 0.4% ripasudil hydrochloride hydrate BID for glaucoma. Gonioscopy revealed Shaffer's grade IV open angle with no abnormal angle findings. Slit-lamp examination revealed a moderate cataract and optic disk cupping with a vertical C/D ratio of 0.8. Humphrey visual field test showed moderate glaucomatous visual field loss with MD of -6.83. The axial length OD was 27.0 mm, as measured using the optical biometer. Therefore, we performed KDB goniotomy combined with cataract surgery and resected the inferior nasal TM by 90° in the same manner. At that time, a cyclodialysis cleft was inadvertently created along with anterior chamber hemorrhage. Antimicrobial and steroidal ophthalmic solutions of 1.5% levofloxacin and 0.1% betamethasone sodium phosphate were prescribed four times a day for 1 month postoperatively. The OMDI eye drops was discontinued.

On POD 6, the patient's BCVA was 20/250 with a manifest refraction of S-3.5D and IOP of 8 mmHg OD. A 45-degree nasal cyclodialysis cleft was revealed with gonioscopy and a 360-degree gonioscopic camera, Gonioscope GS-1 (Nidek Co., Gamagori, Japan).¹⁹ AS-OCT confirmed the nasal cyclodialysis cleft along with a 360-degree ciliochoroidal detachment. However, a continuous channel was not visible from the anterior chamber to the suprachoroidal space in the cross-sectional image. On POD 31, the BCVA was 20/100 with a manifest refraction of S-2.5D and IOP of 8 mmHg, with OCT revealing postoperative macular edema (ME) and hypotony maculopathy. Therefore, the ripasudil eye drops were discontinued, and 0.1% nepafenac eye drops were prescribed three times a day for 1 month. On POD 73, the BCVA was 20/50 with a manifest refraction of S-2.75D = C-1.0D × 70° and IOP of 7 mmHg. ME improved, but hypotony maculopathy was still present. On POD 108, the BCVA was 20/50 with a manifest refraction of S-2.0D = C-1.25D A × 70° and IOP of 8 mmHg, without resolution of cyclodialysis and hypotony maculopathy. Gonioscopy and the 360-degree gonioscopic camera confirmed the post-goniotomy cyclodialysis cleft of about 45° (Figure 2A–D). The patient agreed to the surgical repair, and MIDIC was performed on POD 149.

On POD 7 after the MIDIC, the BCVA was 20/50 with a manifest refraction of S-2.5D=C-1.0D A × 60° and IOP of 8 mmHg OD. The nasal cyclodialysis cleft had been repaired, along with decreasing ciliochoroidal detachment. On POD 33, the patient suddenly developed an elevated IOP of 61 mmHg, which was stabilized with 0.005% latanoprost QID, 2% dorzolamide hydrochloride and 0.5% timolol maleate ophthalmic drops BID, and oral 250 mg acetazolamide BID. On the next day, POD 34, IOP had dropped to 12 mmHg, and acetazolamide oral medication was terminated. On POD 82, the BCVA was 20/40 with a manifest refraction of S-3.5D and IOP of 11 mmHg OD. Topical administration of latanoprost and dorzolamide-timolol had been prescribed. The ciliochoroidal detachment disappeared, and hypotony maculopathy was resolved (Figure 2E–H). Finally, the BCVA improved from preoperative levels, and good IOP control was achieved. No further postoperative complications have been observed to date.

MIDIC

The technique developed and described in this series is demonstrated in [Supplementary Video SI](#). Because the needle passes under the iris in the posterior chamber and is inserted into the ciliary sulcus, this procedure is indicated for pseudophakic or aphakic eyes, or eyes undergoing cataract surgery at the same time. After sub-Tenon's anesthesia with 2% lidocaine, side ports were made in the bilateral corneas. The anterior and posterior chamber spaces were maintained with viscoelastic material, 1% sodium hyaluronate, and the extent of cyclodialysis was monitored with a Swan–Jakob lens (Figure 3A) and marked externally (Figure 3B). A double-needle suture was prepared by tying together two PC9 single sutures (Alcon Laboratories, Fort Worth, Texas, USA). One of the PC9 needles was introduced through the corneal incision on the opposite side of the cyclodialysis and, using the marking site as a landmark, was inserted into the ciliary sulcus by sliding it under the iris, with care taken to avoid damaging the anterior lens capsule (Figure 3C). The needle was then passed through the cyclodialysis and sclera and onto the conjunctiva about 2.0 mm posterior to the limbus. The contralateral needle was inserted about 30° away from the first insertion point and was then passed outside the eye and onto the conjunctiva in the same manner. These two punctures were then sutured on the conjunctiva to create a mattress suture (Figure 3D). If the extent of cyclodialysis was longer than 30°, additional sutures were added for each additional

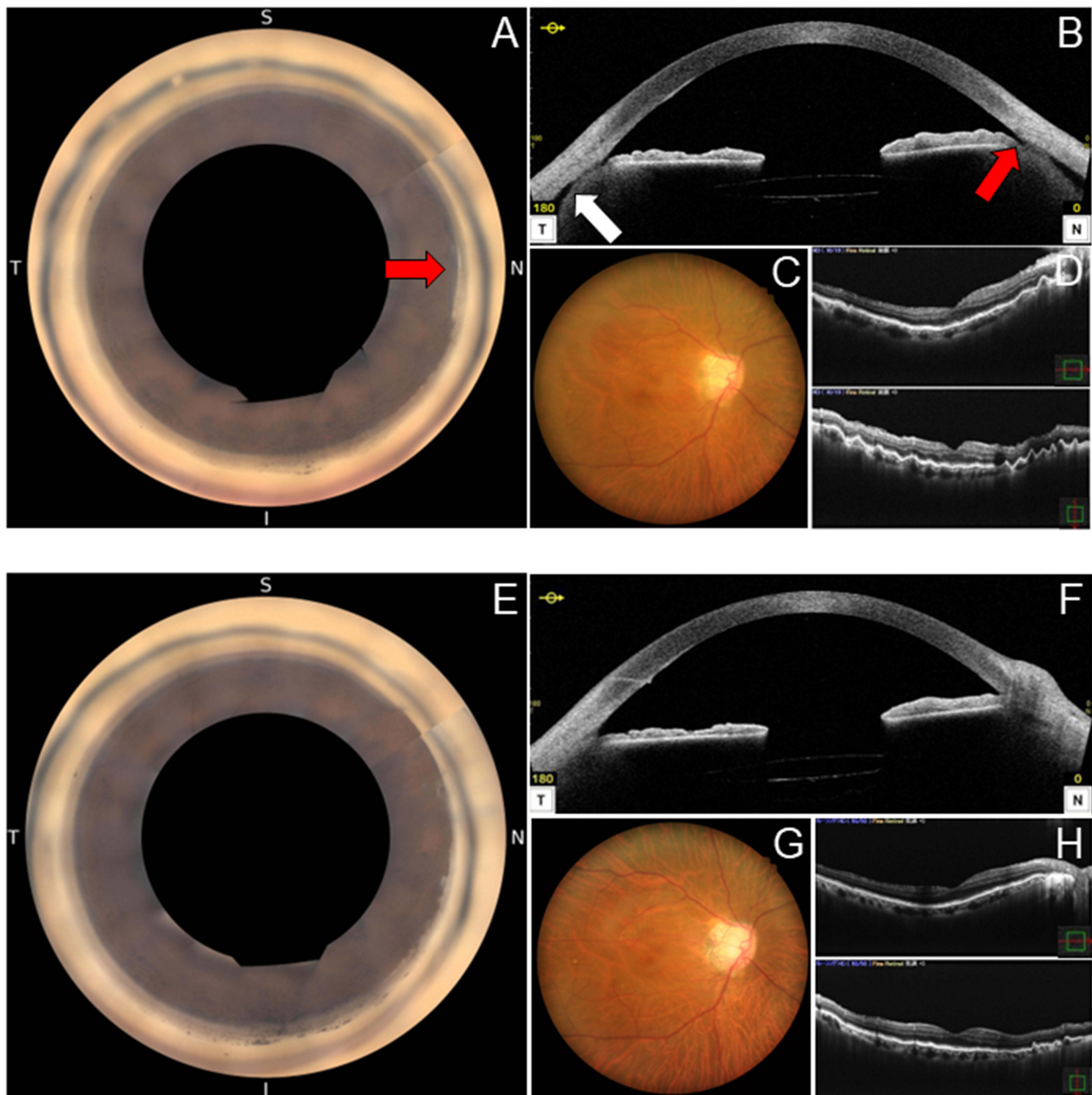


Figure 2 Angle and fundus findings before and after minimally invasive direct internal cyclopexy in case 2. **(A)** Preoperative 360-degree gonioscopic camera image. Red arrow indicates a post-goniotomy cyclodialysis cleft of about 45°. **(B)** Preoperative anterior segment optical coherence tomography (AS-OCT) in the horizontal direction confirming the disinsertion of the ciliary body from the scleral spur (red arrow) along with a shallow 360-degree ciliochoroidal detachment (white arrow). Anterior chamber-superior choroidal space traffic is not clear. **(C)** Preoperative fundus camera photo showing mild dilation and tortuosity of retinal veins. **(D)** Preoperative OCT showing chorioretinal folds, which indicates hypotony maculopathy. **(E)** Postoperative 360-degree gonioscopic camera image showing the cyclodialysis cleft is repaired. Scattered peripheral anterior synechiae formations after the cyclopexy are observed in the nasal angle. **(F)** Postoperative AS-OCT in the horizontal direction confirming the repair of the cleft and disappearance of the ciliochoroidal detachment. **(G)** Postoperative fundus camera image showing improvements in mild dilation and tortuosity of retinal veins. **(H)** Postoperative OCT showing improved chorioretinal folds and the return of the retinal shape to normal, which indicates the resolution of hypotony maculopathy.

30°. Finally, the sutures were placed parallel to the corneal limbus, and a knot is implanted under the conjunctiva by rotating the mattress suture (Figure 3E). The Swan–Jakob was used to confirm that the cyclodialysis was repaired (Figure 3F), and the viscoelastic material was aspirated and removed. The operation was completed with corneal wound hydration. The mattress sutures were left in place postoperatively. As postoperative eye drops, antimicrobial, 1.5%

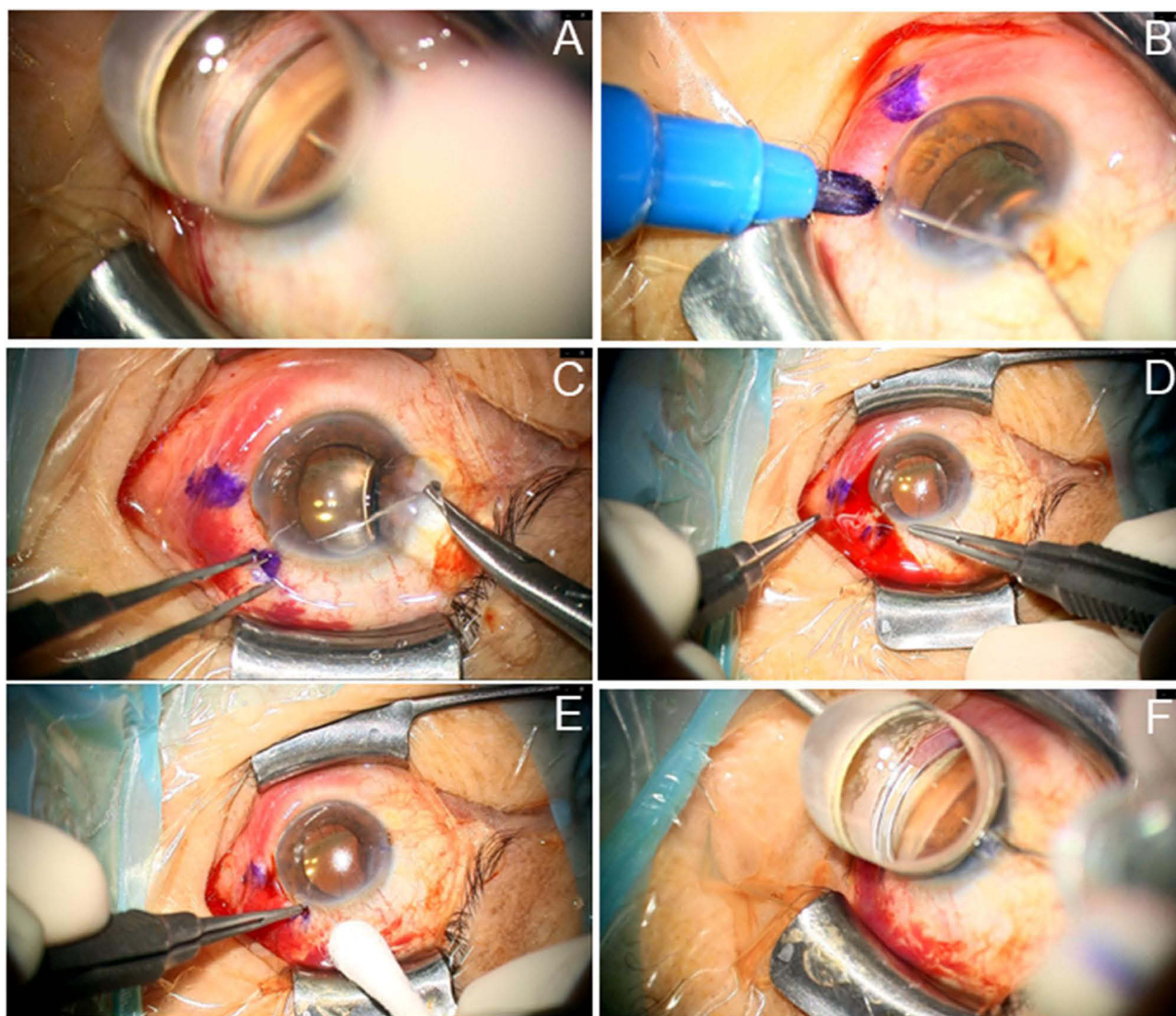


Figure 3 Continuous still images from the intraoperative video of minimally invasive direct internal cyclopexy being performed in case 2. (A and B) Confirmation and marking of the extent of cyclodialysis. (C) Intraocular insertion of PC-9 double needles into the ciliary sulcus at the site of cyclodialysis. (D) Mattress suture at the cyclodialysis site (internal direct cyclopexy). (E) Subconjunctival implantation of the knot. (F) Confirmation of the repair of cyclodialysis.

levofloxacin and steroid, and 0.1% betamethasone sodium phosphate ophthalmic solutions four times a day were used for one month.

Discussion

Hypotony can be defined both statistically and clinically. The statistical definition of hypotony is IOP less than 6.5 mmHg, which is more than 3 standard deviations below the mean, whereas the clinical definition of hypotony is IOP low enough to cause vision loss.^{20,21} Therefore, the two cases in this series showed clinical hypotony. Moreover, many ocular hypotensive eyes maintain good vision and do not develop problems, and harmful effects on the eyes are less common with an IOP greater than 4 mmHg.²¹ However, the two patients who had IOP of more than 4 mmHg at all measurement points before MIDIC developed vision-threatening hypotony maculopathy, which may have been due to the associated risk factors with male sex and myopia, as reported in a retrospective case-control study.²⁰ Moreover, previous cases with cyclodialysis cleft and hypotony maculopathy after AITS all had myopia, and more than half had myopia gravis with an axial length of 26.5 mm or more.^{3,7} The two present cases also had myopia gravis, which may present a higher risk for cyclodialysis cleft formation and hypotony maculopathy after AITS.

The postoperative IOP spikes after cyclohexy suggesting the successful closure of the cleft often occurs in the first week but is not mandatory.¹² The patient who underwent MIDIC at 2 months after KDB goniotomy showed no postoperative IOP spike despite a relatively wide cyclodialysis cleft range of 90°. Alternatively, the other one who underwent MIDIC at 5 months after KDB goniotomy developed an IOP spike on POD 33 from the cyclohexy and required oral and topical medications for IOP control despite a cyclodialysis cleft range of 45°. The frequency of IOP spike after direct external cyclohexy during the first 7 PODs was 61%–83%, and no relationship was found between the postoperative IOP spike and the extent of residual anatomical angle damage, suggesting that functional angle damage is the important additional factor in acute, transient ocular hypertension.^{11,12} As in the previous report, the current IOP spike was not related to the degree of angle damage. Moreover, the IOP spike may be due to the transient imbalance between the increase in aqueous humor production associated with the resolution of ciliochoroidal detachment and the recovery from the dysfunction of conventional aqueous humor outflow after Schlemm's canal due to prolonged ocular hypotension. Therefore, a longer duration of hypotony may have resulted in the current delayed-onset IOP spike after cyclohexy.

An accurate diagnosis of cyclodialysis and exact assessment of its localization and extent are essential in treatment planning and postoperative follow-up. In diagnosis, AS-OCT has an advantage of capturing higher-resolution images at some level of depth without requiring ocular contact. In the present cases, AS-OCT was able to clearly visualize the improvement in ciliochoroidal detachment, which cannot be assessed by gonioscopy. However, despite the good visualization and the precise cross-sectional imaging directly over the cleft, a continuous channel could not be observed from the anterior chamber to the suprachoroidal space in case 2, as has been previously observed.¹¹ Therefore, the localization and extent of the cleft is difficult to evaluate with AS-OCT. However, the 360-degree gonioscopic camera, as well as gonioscopy, was able to evaluate the localization and extent of the cleft. Moreover, it allowed for detailed confirmation of the angle changes, including the cleft repair and peripheral anterior synechia formation postoperatively as with a previous report.¹⁹ Therefore, the combination of these instruments will be of great help for pre- and postoperative angle assessments for treating cyclodialysis clefts.

In both cases, no postoperative complications such as ocular infection or recurrent cyclodialysis have been observed since MIDIC was performed. Immediately after the surgery, the sutures are exposed on the ocular surface. However, because there is little tissue damage from the surgery and the fine sutures are tied tightly, the sutures are submerged under the conjunctiva or subconjunctiva a few days after the surgery and are not directly exposed to the ocular surface. Therefore, the risk of ocular infection would not be high. However, postoperative ocular trauma could expose the patient to the risk of infection or recurrence, as with any other surgeries.

Conclusion

In conclusion, we devised a new technique of suture fixation of the detached CB onto the original scleral bed directly through the intraocular approach with minimal invasion for cyclodialysis cleft with vision-threatening hypotony maculopathy after AITS. We further demonstrated it in clinical practice, with good results. To our knowledge, the technique is the first direct cyclohexy used for cyclodialysis cleft repair after AITS that precludes the need for conjunctival or scleral incision, which is optimal for patients with glaucoma. Moreover, MIDIC is a simple, practical, and reliable treatment for goniotomy-related cyclodialysis cleft and could be applied for cyclodialysis clefts caused by other causes, including trauma.

Abbreviations

AS-OCT, anterior segment optical coherence tomography; AITS, ab-interno trabeculotomy-related surgery; BCVA, best corrected visual acuity; CB, ciliary body; ERM, epiretinal membrane; IOP, intraocular pressure; KDB, Kahook Dual Blade; MD, mean deviation; ME, macular edema; MIDIC, minimally invasive direct internal cyclohexy; NTG, normal tension glaucoma; OD, cataract in the right eye; OMDI, omdenepag isopropyl; POD, postoperative day; TM, trabecular meshwork.

Data Sharing Statement

All data generated or analyzed during this study are included in this article. Further enquiries can be directed to the corresponding author.

Ethics Approval and Consent to Participate

This study adhered to the tenets of the Declaration of Helsinki. The institutional review board of Shimane University Hospital did not require an ethics committee review process to report this case. The patients provided written informed consent for participation in this case report.

Consent for Publication

The patients provided written informed consent for publication of this case report and any accompanying pictures.

Funding

This work was supported by the Japan Society for the Promotion of Science (JSPS) KAKENHI (Grant Numbers: 20K18382 and 23K15928).

Disclosure

The authors have no conflicts of interest to declare for this work.

References

1. Tanito M, Matsuo M. Ab-interno trabeculotomy-related glaucoma surgeries. *Taiwan J Ophthalmol*. 2019;9(2):67–71. doi:10.4103/tjo.tjo_38_19
2. Tamm ER. The trabecular meshwork outflow pathways: structural and functional aspects. *Exp Eye Res*. 2009;88(4):648–655. doi:10.1016/j.exer.2009.02.007
3. Ishida A, Mochiji M, Manabe K, Matsuoka Y, Tanito M. Persistent hypotony and annular ciliochoroidal detachment after microhook ab interno trabeculotomy. *J Glaucoma*. 2020;29(9):807–812. doi:10.1097/ijg.0000000000001560
4. Kornmann HL, Fellman RL, Feuer WJ, et al. Early results of goniotomy with the kahook dual blade, a novel device for the treatment of glaucoma. *Clin Ophthalmol*. 2019;13:2369–2376. doi:10.2147/oph.s224643
5. Seibold LK, Soohoo JR, Ammar DA, Kahook MY. Preclinical investigation of ab interno trabeculectomy using a novel dual-blade device. *Am J Ophthalmol*. 2013;155(3):524–529.e2. doi:10.1016/j.ajo.2012.09.023
6. Falkenberry S, Singh IP, Crane CJ, et al. Excisional goniotomy vs trabecular microbypass stent implantation: a prospective randomized clinical trial in eyes with mild to moderate open-angle glaucoma. *J Cataract Refract Surg*. 2020;46(8):1165–1171. doi:10.1097/j.jcrs.0000000000000229
7. Shue A, Levine RM, Gallousis GM, Teng CC. Cyclodialysis cleft associated with kahook dual blade goniotomy. *J Curr Glaucoma Pract*. 2019;13(2):74–76. doi:10.5005/jp-journals-10078-1255
8. Portney DS, Michelson SJ, Besirli CG, Shah M. Cryotherapy for the management of refractory hypotony secondary to post-goniotomy cyclodialysis cleft. *Am J Ophthalmol Case Rep*. 2020;20:100876. doi:10.1016/j.ajoc.2020.100876
9. Osman EA, AlMobarak F. Ciliochoroidal effusion with persistent hypotony after trabectome surgery. *Indian J Ophthalmol*. 2015;63(3):272–274. doi:10.4103/0301-4738.156936
10. Selvan H, Gupta V, Gupta S. Cyclodialysis: an updated approach to surgical strategies. *Acta Ophthalmol*. 2019;97(8):744–751. doi:10.1111/aos.14210
11. Ioannidis AS, Bunce C, Barton K. The evaluation and surgical management of cyclodialysis clefts that have failed to respond to conservative management. *Br J Ophthalmol*. 2014;98(4):544–549. doi:10.1136/bjophthalmol-2013-303559
12. Agrawal P, Shah P. Long-term outcomes following the surgical repair of traumatic cyclodialysis clefts. *Eye*. 2013;27(12):1347–1352. doi:10.1038/eye.2013.183
13. Berk TA, An JA, Ahmed IIK. Inadvertent cyclodialysis cleft and hypotony following ab-interno trabeculotomy using the trabectome device requiring surgical repair. *J Glaucoma*. 2017;26(8):742–746. doi:10.1097/ijg.0000000000000719
14. Chadha N, Lamba T, Belyea DA, Merchant KY. Indirect cyclopexy for treatment of a chronic traumatic cyclodialysis cleft with hypotony. *Clin Ophthalmol*. 2014;8:591–594. doi:10.2147/OPHTH.S55938
15. Feiler DL, Browne AW, Rachitskaya AV, et al. Indirect cyclopexy for repair of cyclodialysis clefts. *Retina*. 2019;39(1):S177–S181. doi:10.1097/iae.0000000000002091
16. Wang C, Peng XY, You QS, et al. Internal cyclopexy for complicated traumatic cyclodialysis cleft. *Acta Ophthalmol*. 2017;95(6):639–642. doi:10.1111/aos.13463
17. Gupta S, Selvan H, Gupta V. Single-suture single-knot ab interno cyclopexy for extensive posttraumatic cyclodialysis: modified sewing machine technique. *J Cataract Refract Surg*. 2019;45(1):3–7. doi:10.1016/j.jcrs.2018.08.031
18. Imamachi K, Ichioka S, Takayanagi Y, Tsutsui A, Shimizu H, Tanito M. Central serous chorioretinopathy resolution after traumatic cyclodialysis repair. *Am J Ophthalmol Case Rep*. 2022;26:101507. doi:10.1016/j.ajoc.2022.101507
19. Matsuo M, Inomata Y, Kozuki N, Tanito M. Characterization of peripheral anterior synechiae formation after microhook ab-interno trabeculotomy using a 360-degree gonio-camera. *Clin Ophthalmol*. 2021;15:1629–1638. doi:10.2147/oph.s306834
20. Fannin LA, Schiffman JC, Budenz DL. Risk factors for hypotony maculopathy. *Ophthalmology*. 2003;110(6):1185–1191. doi:10.1016/s0161-6420(03)00227-6
21. Pederson J. Ocular hypotony. *Trans Ophthalmol Soc*. 1986;105:220–226.

International Medical Case Reports Journal

Dovepress

Publish your work in this journal

The International Medical Case Reports Journal is an international, peer-reviewed open-access journal publishing original case reports from all medical specialties. Previously unpublished medical posters are also accepted relating to any area of clinical or preclinical science. Submissions should not normally exceed 2,000 words or 4 published pages including figures, diagrams and references. The manuscript management system is completely online and includes a very quick and fair peer-review system, which is all easy to use. Visit <http://www.dovepress.com/testimonials.php> to read real quotes from published authors.

Submit your manuscript here: <https://www.dovepress.com/international-medical-case-reports-journal-journal>