

# Long-term follow-up of children thought to have temporary brittle bone disease

Colin R Paterson<sup>1</sup>  
Elizabeth A Monk<sup>2</sup>

<sup>1</sup>Department of Medicine (retired),

<sup>2</sup>School of Accounting and Finance,  
University of Dundee, Dundee,  
Scotland

**Background:** In addition to nonaccidental injury, a variety of bone disorders may underlie the finding of unexplained fractures in young children. One controversial postulated cause is temporary brittle bone disease, first described in 1990.

**Methods:** Eighty-five patients with fractures showing clinical and radiological features of temporary brittle bone disease were the subject of judicial hearings to determine whether it was appropriate for them to return home. Sixty-three patients did, and follow-up information was available for 61 of these. The mean follow-up period was 6.9 years (range 1–17, median 6).

**Results:** We found that none of the children had sustained any further injuries that were thought to represent nonaccidental injury; no child was re-removed from home. Three children had fractures. In each case there was general agreement that the fractures were accidental. Had the original fractures in these children been the result of nonaccidental injury, it would have been severe and repeated; the average number of fractures was 9.1.

**Conclusion:** The fact that no subsequent suspicious injuries took place after return home is consistent with the view that the fractures were unlikely to have been caused by nonaccidental injury, and that temporary brittle bone disease is a distinctive and identifiable disorder.

**Keywords:** fractures, osteogenesis imperfecta, temporary brittle bone disease, nonaccidental injury

## Introduction

The child found to have unexplained fractures presents an acute problem of diagnosis. To many observers, the failure of parents to provide an explanation for fractures found radiologically is, in itself, evidence for nonaccidental injury. It is said that the lack of explanation must represent a failure to tell the truth about their own or their partner's actions. However, unexplained fractures in childhood are also the hallmark of many forms of brittle bone disease, and great harm can be done by an inaccurate diagnosis of nonaccidental injury.

Over the last 35 years, attention has been drawn to the brittle bone diseases that may cause difficulties in diagnosis. The best known of these is osteogenesis imperfecta, a large group of heritable disorders, mainly but not exclusively caused by defects of collagen. Despite its better recognition and the availability of biochemical investigations, failure to identify these cases appropriately still occurs.<sup>1</sup> Less common causes of fractures include vitamin D deficiency rickets, scurvy (vitamin C deficiency), and Menkes syndrome, an inborn error of copper metabolism.<sup>2–4</sup> Preterm birth has long been recognized as a cause of bone disease that may include fractures.<sup>5</sup>

Correspondence: Colin R Paterson  
Temple Oygates, Longforan, Dundee  
DD2 5HS, Scotland  
Tel +44 1382 360240  
Email c.s.paterson@btinternet.com

Over the last 20 years, we and others have drawn attention to the probable existence of a disorder distinct from osteogenesis imperfecta, which has been called temporary brittle bone disease.<sup>6–10</sup> In this condition, fractures, and often very large numbers of fractures, occur in the first year of life, mainly in the first 6 months. These patients have distinctive clinical and radiological features in common.<sup>7,8</sup> As with classical osteogenesis imperfecta, there is usually a gross discrepancy between the radiological and clinical evidence of injury. The causes of this disorder are not yet known. Factors postulated include preterm birth, defects in collagen maturation, disorders causing reduced fetal movement, vitamin and mineral deficiencies, and heritable factors. The condition may be heterogeneous and multifactorial.

In some of these patients, the initial clinical diagnosis was thought to be osteogenesis imperfecta but the lack of subsequent fractures led to the questioning of this diagnosis. In a much greater number, the initial diagnosis was nonaccidental injury, not least because temporary brittle bone disease, with a preponderance of rib fractures and metaphyseal abnormalities, resembles one widely accepted pattern ascribed to nonaccidental injury.<sup>11,12</sup> Inevitably, this disorder had been the subject of controversy, with some saying that it probably does not exist or questioning the frequency with which it occurs.<sup>13–15</sup> The present study was undertaken to ascertain the outcome when children are returned to their parents after a diagnosis of temporary brittle bone disease.

## Methods

Over the period 1985–2000, CRP was asked to investigate 239 cases of unexplained fractures in young children. Strenuous efforts were made to exclude other causes of fractures, including osteogenesis imperfecta, rickets, accidental injury, and nonaccidental injury. After these exclusions, 132 children had a pattern of clinical and radiological features consistent with temporary brittle bone disease, including findings of fractures without commensurate physical evidence of injury. Of these, 104 had fractures as the principal or only clinical problem; patients with additional problems, such as subdural bleeding, will be discussed in a separate paper. In 85 cases, CRP was involved in formal hearings to determine whether it was appropriate for the child to return to his or her parents. These 85 cases (from the US, the UK, Sweden, and New Zealand) form the basis of this report.

The cases had been referred by their parents' legal representative (73 cases), by a guardian *ad litem* (one case), by a general practitioner (five cases), by a pediatrician (one case),

by police personnel (two cases), and by a local authority social work department (three cases).

Over the period in question, 63 of the children were returned to their parents (with conditions in 45 cases). Six children were fostered indefinitely with other family members, and 15 were removed permanently from the families. One child had sustained fractures in local authority foster care and was returned to her natural mother following a hearing.

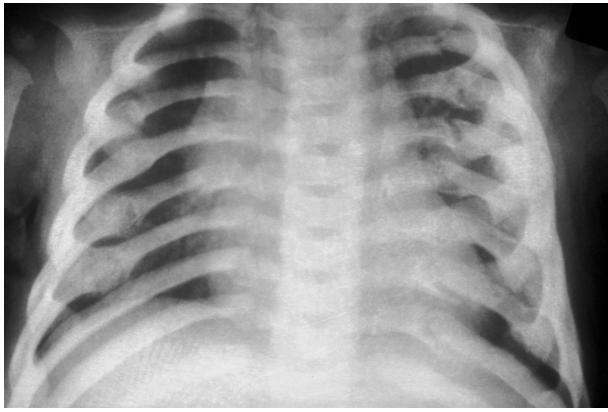
Table 1 summarizes the demographic and clinical findings in the group of 63 patients returned to their parents. While most of the infants were born at or near term, nine were born at less than 36 weeks' gestation and two at less than 32 weeks. In ascertaining the number of fractures, the figures shown are those reported radiologically at the time of presentation or soon thereafter. There was seldom any dispute about the diaphyseal fractures or the rib fractures (Figure 1). The figures for metaphyseal fractures or metaphyseal abnormalities (Figure 2) were sometimes the subject of arguments in detail. In addition to the fractures listed in Table 1, eight patients had lucencies in the parietal bones of the skull. In six cases, it was not possible to distinguish true fractures from parietal fissures; two had clinical or radiological features indicative of true fractures. Four patients had clavicular fractures. Two patients had vertebral compression fractures (at T2 and at T11). One patient had a fracture of the left acromion. Most of the patients had fractures of different ages when first investigated. Follow-up was mainly by telephone calls to the parents and other family members. In a few cases personal visits were also made. Follow-up beyond the age of 18 years was disregarded.

## Results

Of the 63 children returned to their parents, some follow-up proved possible in 61 cases. The follow-up period was for an average of 6.9 years (range 1–17 years, median six years). None of the children sustained further injuries that were thought to represent nonaccidental injury; no child was re-removed from the parents.

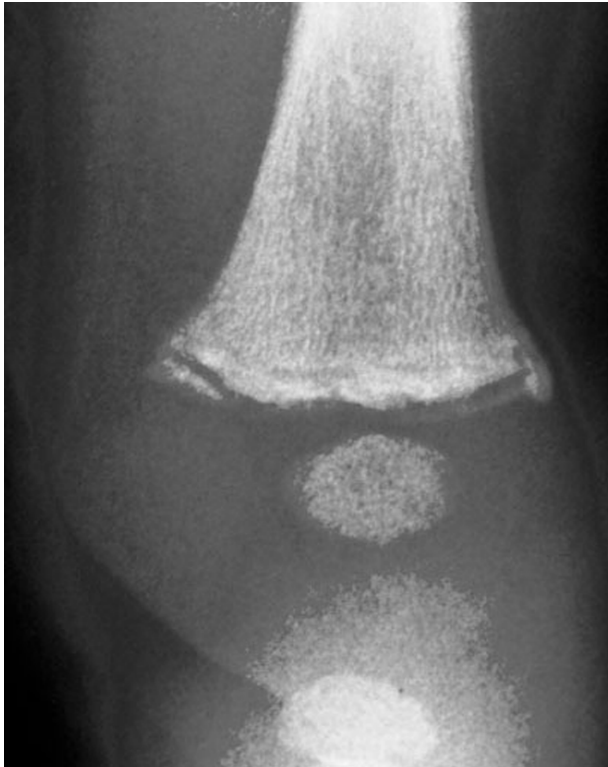**Table 1** Demographic and clinical details of the 63 patients (38 boys and 25 girls) returned to their parents

	Mean	Standard deviation
Gestation (weeks)	37.7	3.2
Birth weight (g)	2967	681
Age when first fracture found (months)	3.2	2.1
Total number of fractures	9.1	6.0
Number of diaphyseal fractures	1.1	1.2
Number of rib fractures	5.4	5.6
Number of metaphyseal abnormalities	2.5	2.9



**Figure 1** Multiple fractures of the ribs at different ages in a 3-month-old girl thought to have temporary brittle bone disease.

After return home, three patients had further fractures at ages two, six, and seven years. In each case, there was general agreement at the time that these fractures had innocent explanations. One girl sustained a fractured radius and ulna at age two years when jumping into a chair at a mothers' and toddlers' group with many witnesses. One boy had a fractured radius and ulna while playing at a neighbor's house at the age of six years. One very energetic boy sustained a fractured metatarsal at the age of six years and a fractured metacarpal



**Figure 2** Metaphyseal fracture of the lower left femur in a 2-month-old girl thought to have temporary brittle bone disease. In this child, the metaphyseal abnormalities were symmetrically distributed.

at age seven years while playing with friends. One severely preterm child died at the age of 22 months from a progressive neurological disorder identified at birth. Following their involvement in the care proceedings, 11 of the parents separated and in two further families there was significant dysfunction, despite the return of the child in question.

## Discussion

It is widely accepted that following an episode of abuse, the child has a substantial risk of further injury or death. An older report stated that there was a 50% chance of further injury and a 10% chance of death if a child is returned home without appropriate precautions.<sup>16</sup> In a more recent survey, the risk of additional abuse to children returned home after therapeutic intervention in the family was estimated to be 20%–37%.<sup>17</sup> The risk was greatest after physical abuse. Such considerations underlie the civil proceedings in relation to children with unexplained fractures. The motive for the proceedings is the protection of the child.

Our findings are strikingly different, with no evidence at all to support subsequent allegations of abuse. The patients outlined here had very large numbers of fractures and, had these resulted from abuse, would have represented severe and repeated abuse. In none of these cases of allegedly severe abuse was there any evidence of subsequent nonaccidental injury, raising doubt about the initial diagnosis of nonaccidental injury.

The concept that there is a distinctive bone disorder causing multiple unexplained fractures in early childhood has been controversial.<sup>14,15</sup> The indicators that temporary brittle bone disease is an intrinsic bone disease causing fractures include the following. First, the patients have many clinical and radiological features in common.<sup>7,8</sup> Other authors have described patients who were clearly similar without using the term temporary brittle bone disease.<sup>18,19</sup> Second, the fractures in these patients are not accompanied by superficial evidence of injury that might be expected if they were caused by inflicted injury.<sup>9</sup> Third, an identical clinical picture has been found in children who sustain fractures in medical care when abuse can be excluded with some confidence.<sup>10,18</sup> Fourth, as this paper shows, children returned to their parents have not had subsequent suspicious injuries. For all these reasons, we believe that temporary brittle bone disease is a real disorder and that such fractures should not be attributed to nonaccidental injury.

## Acknowledgments

We are indebted to Dr Elspeth Paterson for reviewing this paper in draft and to Ms Kirsteen Bovill for excellent secretarial help.

## Disclosure

CRP received normal fees for investigating most of these cases and, when needed, for providing evidence in court.

## References

1. Paterson CR, McAllion SJ. Classical osteogenesis imperfecta and allegations of nonaccidental injury. *Clin Orthop Rel Res.* 2006;452:260–264.
2. Keller KA, Barnes PD. Rickets vs abuse: A national and international epidemic. *Pediatr Radiol.* 2008;38:1210–1216.
3. Paterson CR. Vitamin D deficiency rickets and allegations of non-accidental injury. *Acta Paediatr.* 2009;98:2008–2012.
4. Paterson CR. Multiple fractures in infancy: Scurvy or nonaccidental injury? *Orthop Res Rev.* 2010;2:45–48.
5. Dabezies EJ, Warren PD. Fractures in very low birth weight infants with rickets. *Clin Orthop Rel Res.* 1997;335:233–239.
6. Paterson CR. Osteogenesis imperfecta and other bone disorders in the differential diagnosis of unexplained fractures. *J R Soc Med.* 1990;83:72–74.
7. Paterson CR, Burns J, McAllion SJ. Osteogenesis imperfecta: The distinction from child abuse and the recognition of a variant form. *Am J Med Genet.* 1993;45:187–192.
8. Miller ME. Temporary brittle bone disease: A true entity? *Semin Perinatol.* 1999;23:174–182.
9. Miller ME. The lesson of temporary brittle bone disease: All bones are not created equal. *Bone.* 2003;33:466–474.
10. Paterson CR. Temporary brittle bone disease: Fractures in medical care. *Acta Paediatr.* 2009;98:1935–1938.
11. Ablin DS, Greenspan A, Reinhart M, Grix A. Differentiation of child abuse from osteogenesis imperfecta. *AJR Am J Roentgenol.* 1990;154:1035–1046.
12. Kemp AM, Dunstan F, Harrison S, et al. Patterns of skeletal fractures in child abuse: Systematic review. *BMJ.* 2008;337:859–862.
13. Smith R. Osteogenesis imperfecta, non-accidental injury, and temporary brittle bone disease. *Arch Dis Child.* 1995;72:169–176.
14. Mendelson KL. Critical review of ‘temporary brittle bone disease’. *Pediatr Radiol.* 2005;35:1036–1040.
15. Jenny C. Evaluating infants and young children with multiple fractures. *Pediatrics.* 2006;118:1299–1303.
16. Galleno H, Oppenheim WL. The battered child syndrome revisited. *Clin Orthop Rel Res.* 1982;162:11–19.
17. Terling T. The efficacy of family reunification practices: Reentry rates and correlates of reentry for abused and neglected children reunited with their families. *Child Abuse Negl.* 1999;23:1359–1370.
18. Tsuji M, Hirata H, Hasegawa M, Uchida A. An infant with unexplained multiple rib fractures during treatment in a neonatal intensive care unit. *Turk J Pediatr.* 2008;50:377–379.
19. Hyman CJ. Response to Paterson. *Acta Paediatr.* 2010;99:1281.

### Pediatric Health, Medicine and Therapeutics

### Publish your work in this journal

Pediatric Health, Medicine and Therapeutics international, peer-reviewed, open access journal publishing original research, reports, editorials, reviews and commentaries. All aspects of health maintenance, preventative measures and disease treatment interventions are addressed within the journal. Practitioners from all disciplines are invited to submit

Submit your manuscript here: <http://www.dovepress.com/pediatric-health-medicine-and-therapeutics-journal>

Dovepress

their work as well as healthcare researchers and patient support groups. The manuscript management system is completely online and includes a very quick and fair peer-review system. Visit <http://www.dovepress.com/testimonials.php> to read real quotes from published authors.