

Clinical utility of DaTscan™ (123I-Ioflupane Injection) in the diagnosis of Parkinsonian Syndromes

Andreas-Antonios
Roussakis
Paola Piccini
Marios Politis

Centre for Neuroinflammation and
Neurodegeneration, Imperial College
London, London, United Kingdom

Abstract: The diagnosis of movement disorders including Parkinsonian syndromes and essential tremor is mainly clinical. The most common diagnostic errors for Parkinson's disease include misdiagnoses such as Parkinson plus syndromes and cases of essential tremor. In this article, we discuss the clinical utility of DaTscan™ (123I-Ioflupane injection) and its diagnostic value in Parkinson's disease and the other Parkinsonian syndromes. Single photon emission computed tomography with 123I-Ioflupane can be useful to assist in the diagnosis of uncertain cases of Parkinsonism. An accurate diagnosis can aid clinicians in making correct decisions that are related to the overall management and treatment of Parkinson's disease, avoiding common therapeutic errors.

Keywords: DaTscan, SPECT, 123I-Ioflupane, ¹²³I-β-FP-CIT, Parkinsonism

An introduction to diagnostic issues in Parkinson's disease

Parkinson's disease (PD) is a chronic, progressive neurodegenerative disorder characterized by motor and nonmotor symptoms.¹ PD is the second most common neurodegenerative disorder after dementia² affecting approximately 1%–2% of the general population.³ The cardinal pathological feature of PD is the depletion of dopamine in the substantia nigra pars compacta.⁴

The diagnosis of PD is essentially clinical and is based on identifying clinical characteristics related to striatal dopamine depletion, which typically manifest as motor signs and symptoms (tremor, bradykinesia, and rigidity).⁵ In fact, a good response to dopaminergic medication is consistent with a typical case of idiopathic PD. However, a typical clinical image may not be fully manifested in early PD; nonmotor symptoms, such as sleep disorders and hyposmia may precede motor symptoms⁶ while depression, dementia, and fatigue can dominate over motor symptoms. In addition, comorbidity with neuropsychiatric conditions can act as confounding factors in the diagnostic process.

PD diagnosis is usually straightforward; however, common diagnostic errors can hamper the clinical management of true idiopathic PD cases. The most common diagnostic errors include misdiagnosed cases as dystonic or essential tremor (ET), progressive supranuclear palsy (PSP), multiple systemic atrophy (MSA), dementia with Lewy bodies (DLB), drug induced Parkinsonism, small vessel disease, and psychogenic disorders.

Correspondence: Marios Politis
Imperial College London,
Hammersmith Hospital Campus,
Centre for Neuroinflammation and
Neurodegeneration,
Neurology Imaging Unit,
1st floor, B Block, Du Cane Road, W12
0NN, London, UK
Tel +44 20 8383 3751
Fax +44 20 3313 4320
Email marios.politis@imperial.ac.uk

An overview of current diagnostic strategies for movement disorders, such as clinical examinations, blood tests, and neuropsychological evaluations

PD diagnosis is based on information gathered from medical history and detailed neurological examination that focuses on the motor symptoms of the disorder. The United Kingdom PD brain bank criteria⁷ are widely used in clinical practice with an estimated specificity of 98.6% and a sensitivity of 91.1% in diagnosing idiopathic PD (Table 1).⁸

Nonmotor symptoms of PD are assessed through several questionnaires that can be also used to record PD progression and severity. Depression is amongst the most common nonmotor features in PD affecting approximately 35% of patients.⁹ The clinical criteria for depression, as described in the *Diagnostic and Statistical Manual of Mental Disorders*, fourth edition, text revision (DSM-IV-TR), the first part of the unified PD rating scale (UPDRS-I),¹⁰ or the Hamilton depression rating scale (HAM-D17)¹¹ can be used to evaluate depressive disorder in early PD. To the best of our knowledge, the Parkinson's fatigue scale (PFS-16) is the first rating scale of fatigue based on information acquired from the patients' perspective.¹²

The time of dementia onset in PD varies. Cognitive impairment tends to be diagnosed within the first 3–5 years after the diagnosis of PD.¹³ The mini mental status examination (MMSE)¹⁴ and the Montreal cognitive assessment (MoCA)¹⁵ questionnaires can nevertheless be used to evaluate cognitive decline in PD. Specifically, MoCA has been suggested to provide higher sensitivity for mild cognitive impairment in early PD than MMSE, while the latter seems to better follow up the progression of cognition problems.¹⁶ Still, both rating scales have not been assessed for their ability to differentiate the diagnosis of dementia in PD from DLB.

Olfactory function is impaired in approximately 90% of PD patients notably at a pre-symptomatic phase around 2–7 years prior to the time that typical motor symptoms appear.^{17,18}

Table 1 UK Parkinson's Disease Society Brain Bank clinical diagnostic criteria: Diagnosis of Parkinsonian syndrome

Bradykinesia (slowness of initiation or voluntary movement with progressive reduction in speed and amplitude of repetitive actions), and at least one of the following:
Muscular rigidity;
4–6 Hz rest tremor;
postural instability not caused by primary visual, vestibular, cerebellar, or proprioceptive dysfunction.

Notes: Reproduced with permission of BMJ Publishing Group Ltd. Original Source: Hughes AJ, Daniel SE, Kilford L, Lees AJ. Accuracy of clinical diagnosis of idiopathic Parkinson's disease: a clinic-pathological study of 100 cases. *J Neurol Neurosurg Psychiatry*. 1992;55(3):181–184.⁷

Testing of odor discriminating ability with the 40-item University of Pennsylvania identification smell test (UPSIT-40)¹⁹ and the 16-item identification smell test²⁰ could have potential differential diagnostic value. However, positive results from olfactory testing are apparently not robust enough to suggest idiopathic PD. In addition, olfactory irregularity is not exclusive for PD; it has been also described in patients with PSP, MSA, ET, and Alzheimer's disease (AD).²¹

Parasomnias and sleep disorders are amongst the most frequent nonmotor symptoms in PD and can mostly occur as disrupted sleep, sleep behavior disorders (rapid eye movement behavior disorder), sleep apnea, or insomnia.²² The PD sleep scale²³ and the Pittsburgh sleep quality index²⁴ can be used to monitor the stature of sleep, possible sleep problems, and their impact on the quality of life.

Several genomic loci have been related with sporadic PD cases,²⁵ namely, as familial parkinsonian syndromes (familial PSs) which are directly related to gene mutations. These have been reported to less than 10% of cases diagnosed with PD; of which, PARK8 (Leucine-rich repeat kinase 2, LRRK2, dardarin) and PARK1/PARK4 (α -synuclein, SNCA) have been found to cause autosomal dominant parkinsonism^{27–29} whilst, PARK2 (Parkinson protein 2, E3 ubiquitin protein ligase, PARKIN), PARK6 [phosphatase and tensin homolog (PTEN)-induced putative kinase 1, PINK1] and PARK7 (Parkinson protein 7, protein DJ1, DJ-1) have been identified as responsible for causing autosomal recessive disease.^{30–32} However, sufficient knowledge in order to generate a genomic classification for the vast majority of PD patients and thus determine particular genetic profiles that could impact clinical practice is lacking. Serologic genetic tests are therefore rarely used in routine care for diagnostic purposes unless there is strong evidence of a familiar genetic background where counseling is indicated. Overall, there is no study to our knowledge that focuses on PD diagnosis and compares the strength of these tests against single photon emission computed tomography (SPECT) with 123Iodine-ioflupane.

Review of chemistry, formulation, and mechanism of action of 123I-Ioflupane injection (DaTscan™)

Neuroimaging techniques, such as magnetic resonance imaging (MRI), transcranial sonography, positron emission tomography (PET), and SPECT can be employed to detect structural and functional changes in vivo and therefore support a PD diagnosis. Specifically, PET and SPECT techniques can be utilized to sensitively detect dopamine terminal loss in unspecified clinical cases of Parkinsonism.

N-(3-Fluoropropyl)-2 β -carbomethoxy-3 β -(4-[¹²³I]iodophenyl) nortropane (123I-Ioflupane or ¹²³I- β -FP-CIT; DaTscan™, GE Healthcare Ltd, Little Chalfont, UK) is a radio-iodinated cocaine analogue and is synthesized by the trialkyltin nonradioactive precursor SnFP-CT which is prepared from nor- β -CIT.³³ An enhanced synthesis has also been proposed, which utilizes N-monofluoroalkyl tropanes and fluoroalkyl iodides or fluoroalkyl sulfonate esters. Briefly, the synthetic process includes ¹²³I labeling of the prepared tropane intermediate FP-CIT. The effective dose of this compound for adults and elderly in the striatum³⁴ is 185 MBq/4.35 mSv (per 70 kg individual; Table 2; Figure 1).

123I-Ioflupane is a SPECT radioligand with high in vivo affinity for dopamine transporter (DAT).³⁶ DAT is a sodium chloride dependent protein in dopaminergic terminals and is responsible for the reuptake of dopamine from the synaptic cleft back to the presynaptic neurons.³⁷ Following the intravenous injection of 123I-Ioflupane, radioactive decay of ¹²³I emits γ radiation. This can be detected externally through a γ camera which records the iodine radioactivity of several DAT-rich subregions of the brain. The main metabolic product of 123I-Ioflupane is FP-CIT acid, a polar compound that is unable to cross the blood-brain barrier. The other metabolites include nor- β -CIT and free iodine. Forty eight hours postinjection, about 60% of the injected radioactivity is excreted in the urine; fecal excretion is estimated to be at approximately 14%.³⁸

I-Ioflupane (β -FP-CIT) labelled^{39,40} with ¹¹C or ¹²⁵I rapidly reaches high concentrations in the human striatum as suggested by autoradiography postmortem in vitro studies in humans, which was also confirmed by striatal accumulation of ¹¹C- β -FP-CIT through PET in vivo imaging in a *Cynomolgus* monkey.³⁹

However, 123I-Ioflupane has also been suggested to bind to the serotonin transporter (SERT) in humans.⁴¹ This theory was generated following a study in rats that noted high 123I-Ioflupane uptake in the hypothalamus.⁴² In the same study, acute challenge

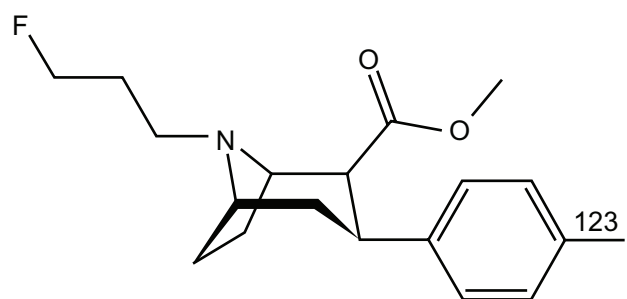


Figure 1 Chemical structure of 123I-Ioflupane.

with vanoxerine (also known as GBR 12,909) administration (which blocks DAT), led to significant reductions in the striatal uptake of 123I-Ioflupane while fluvoxamine (a selective serotonin reuptake inhibitor) did not significantly affect the striatal uptake. On the other hand, fluvoxamine did reduce the uptake of the tracer in the serotonin-rich hypothalamus.⁴²

Effectiveness of 123I-Ioflupane in differential diagnosis

123I-Ioflupane has been granted a marketing authorisation by The European Medicines Agency³⁴ valid throughout the European Union in July 2000 (renewed in July 2010) and by the US Food and Drug Administration⁴³ for the United States in January 2011. 123I-Ioflupane is indicated for assessing the loss of functional dopaminergic neuron terminals in the striatum in patients with clinically uncertain PSs which include PSP, MSA, DLB, drug-induced Parkinsonism, and small vessel diseases other than idiopathic PD.

In clinical practice, SPECT with 123I-Ioflupane can be reported as normal or abnormal through subjective visual rating of the 123I-Ioflupane signal. In other words, the examiner must observe SPECT images and judge to what extent the tracer is accumulated in the striatum based on background signal, which is assumed to be devoid of dopaminergic neurons. As a result, DAT imaging evaluation can vary greatly since the individual examiner's opinion is based on their expertise and knowledge.⁴⁴ Reduced DAT striatal binding is therefore suggested to depict reduced DAT availability which reflects striatal dopaminergic deficit.

123I-Ioflupane is indicated to discriminate between PSs and ET. In addition, it is indicated to assist in the differential diagnosis between probable DLB and AD. Hence, whereas the main diagnostic question refers to the integrity of the dopaminergic circuit in the striatum, DAT imaging can be utilized to investigate this and differentiate PD, PSP, MSA, or DLB from ET, secondary Parkinsonism, AD, and Huntington's disease, in which the pathology is not related to dopaminergic depletion in the striatum.⁴⁵ DAT imaging can therefore

Table 2 Summarized characteristics of 123I-Ioflupane³⁵

IUPAC name	N-(3-Fluoropropyl)-2 β -carbomethoxy-3 β -(4-[¹²³ I]iodophenyl)nortropane
Abbreviation	[¹²³ I]FP-CIT, [¹²³ I] β -CIT-FP
Synonyms	123I-Ioflupane, DaTscan™
Target	DAT [IC_{50} = 3.5 nM] Serotonin Transporter [IC_{50} = 9.73 nM]

Note: Adapted with permission of Molecular Imaging and Contrast Agent Database (MICAD). Leung K. N-(3-Fluoropropyl)-2 β -carbomethoxy-3 β -(4-[¹²³I]iodophenyl) nortropane. Bethesda: National Center for Biotechnology Information; 2004–2013. Available from: <http://www.ncbi.nlm.nih.gov/books/NBK22986/>.³⁵ DaTscan™, GE Healthcare Ltd, Little Chalfont, UK.

Abbreviations: DAT, dopamine transporter; IC_{50} , half maximal inhibitory concentration; IUPAC, International Union of Pure and Applied Chemistry.

be particularly useful in the early stages of cases where bradykinesia and rigidity do not manifest as motor symptoms.

In such cases where the tremor is the dominant motor symptom, the diagnosis of either PD or ET is often based on clinical facts without performing DAT imaging. In some of these cases, a misdiagnosed case of ET can actually develop PD. It has been shown that patients with known ET have an approximately four times higher risk in developing PD than controls.⁴⁶ In such cases, future imaging studies with 123I-Ioflupane could possibly investigate the prognostic value of DAT imaging.

DP008–003⁴⁷ and PDT–304⁴⁸ studies were open randomized trials for assessing the efficacy of 123I-Ioflupane for DAT binding. The DP008-003 study was designed to estimate the accuracy of 123I-Ioflupane SPECT in confirming known clinical cases of PD against ET and healthy volunteers. PDT-304 was based on the diagnostic value of DAT imaging; in this study, the confirmation was clinical and came afterwards. Both studies were criticized by de la Fuente-Fernández in 2012.⁴⁹ The accuracy of 123I-Ioflupane was calculated with a sensitivity of 98% and a specificity of 67% for a possible and probable PD diagnosis in true early PD cases. In already established PD diagnoses, the specificity raises to 94%. However, this ability has not been questioned against neuropathological confirmation. Overall, future comparative studies can clarify this point and increase the accuracy of 123I-Ioflupane in differential diagnoses.

Among PD, PSP, and MSA, the uptake of 123I-Ioflupane has been found to be significantly more reduced in PSP patients than in PD or MSA cases; specifically when using putamen as a region of interest.⁵⁰ Of interest, putamen/caudate ratios were calculated in the same study⁵⁰ and it was suggested that PSP patients follow a different pattern of dopaminergic degeneration compared to idiopathic PD. Another study⁵¹ suggests that patients with PSs and not PD, eventually show a decrease in dopamine D2 receptors, availability. However, this stemmed from comparisons of imaging data between 123I-Ioflupane and ¹²³I-iodobenzamide (IBZM), which is a radiotracer specific to postsynaptic dopamine D2 receptors. An ¹²³I-IBZM SPECT can be therefore useful only for supporting abnormal imaging with 123I-Ioflupane.

SPECT with 123I-Ioflupane has been employed in a group of patients with corticobasal ganglionic degeneration and showed variable nigrostriatal reductions of the tracer characterized by greater hemispheric asymmetry compared to PD. Despite prominent bilateral disease, about 10% of corticobasal ganglionic degeneration patients of the same series

had normal DAT imaging, which may suggest supranigral pathology for corticobasal ganglionic degeneration.⁵²

SPECT with 123I-Ioflupane focused on striatal DAT availability is able to differentiate PD from ET with a sensitivity of 95% and a specificity of 93%.⁴⁷ Also, idiopathic PD can be differentiated from secondary PD through SPECT with 123I-Ioflupane. However, the diagnostic accuracy of 123I-Ioflupane is suggested to be low between idiopathic PD and atypical PSs.⁵³ Parkinsonism due to vascular background is sometimes hard to distinguish from true idiopathic PD cases; vascular lesions are often found incidentally in elderly patients in MRI scans. However, a rather symmetrical uptake of striatal 123I-Ioflupane has been suggested to relate to vascular Parkinsonism.^{54,55} Thus, new prospective studies are needed to determine the prognostic value of 123I-Ioflupane for the diagnosis of vascular Parkinsonism.

123I-Ioflupane SPECT for DLB patients has been found to correlate with neuropathological validation of the disorder. Following postmortem analysis in eight patients with DLB compared to nine with AD, SPECT imaging with 123I-Ioflupane almost 10 years before autopsy, was found to have a sensitivity and specificity of 88% and 100% for DLB diagnosis.⁵⁶

123I-Ioflupane can be also employed to differentiate PD from psychogenic Parkinsonism, where nigrostriatal innervation should remain intact. 123I-Ioflupane SPECT data have suggested undamaged dopaminergic nigrostriatal terminals in case studies with psychogenic Parkinsonism.^{57,58}

Advantages and disadvantages of 123I-Ioflupane

123I-Ioflupane is used in routine clinical practice through subjective visual rating, a fact that weakens its robustness. However, objectivity may come through a region of interest approach or voxel-based techniques that can enhance its wide clinical use.⁴⁴

From a methodology point of view, images of SPECT with 123I-Ioflupane can be quantified through several methods such as a region of interest (ROI), one-shape analysis of the uptake, Statistical Parametric Mapping (SPM) analysis based on ROI/background ratios, and principal component analysis.⁵⁹ Others are based on the machine learning paradigm that can be applied to the SPECT images through computer-aided diagnosis systems that can assist the diagnosis of PSs.⁶⁰ An interesting method for quantitative measure of uptake has been proposed to assist the diagnosis of uncertain PSs and possibly measure disease progression⁵⁹. This method combines principal components analysis and provides an automatic

classification as PS or nonPS with an accuracy measured at approximately 94.8%. Further to this work, another group proposed an improved automatic computer-aided diagnosis system with similar results (accuracy of approximately 94%).⁶¹ Hence, image quantification can provide objectivity in order to avoid incorrect qualification for bilateral symmetric reduction sometimes found in MSA or PSP.

123I-Ioflupane has been proven to increase the diagnostic confidence for uncertain Parkinsonian cases when they clinically resemble idiopathic PD. When the clinical evaluation is not clear and there is a need for assessing in vivo the striatal dopaminergic deficit in movement disorders, SPECT with 123I-Ioflupane is indicated to support the clinical diagnosis. Less diagnostic errors enhance good clinical practice and reduce further costs and inappropriate anti-Parkinsonian treatment.

A recent study collected 1701 ¹²³I-FP-CIT SPECT scans of patients with uncertain clinical PSs. A cost-effectiveness analysis model was applied in this registry and it was shown that DAT imaging is influential in the diagnosis and further pharmacological management of patients with uncertain PSs.⁶² To this point, another study has proposed potential cost savings in treatment of PD.⁶³ However, future cost-effectiveness studies should focus on the prognostic value of SPECT imaging with ¹²³I-FP-CIT SPECT in order to avoid management errors and side effects that increase treatment costs. Moreover, the cost of SPECT imaging is much less compared to other functional imaging techniques such as PET. Overall, it is a safe and well tolerated investigation.⁶⁴

Conclusion

123I-Ioflupane is a powerful and widely used SPECT radiotracer for assisting differential diagnosis in PSs where the pathology refers to a striatal dopaminergic deficit. A pathological confirmation from postmortem data following SPECT imaging with 123I-Ioflupane is sine qua non for estimating the accuracy and the prognostic value of this compound. SPECT with 123I-Ioflupane can also be used to monitor treatment assessing several dopaminergic medications.

Disclosure

The authors report no conflicts of interest in this work.

References

1. Tolosa E, Wenning E, Poewe W. The diagnosis of Parkinson's disease. *Lancet Neurol.* 2006;5(1):75–86.
2. de Lau LM, Breteler MM. Epidemiology of Parkinson's disease. *Lancet Neurol.* 2006;5(6):525–535.
3. Nussbaum RL, Ellis CE. Alzheimer's disease and Parkinson's disease. *N Engl J Med.* 2003;348(14):1356–1364.
4. Macphee GJ, Stewart DA. Parkinson's disease. *Rev Clin Gerontol.* 2006;16:1–21.
5. Lees AJ, Hardy J, Revesz T. Parkinson's disease. *Lancet.* 2009;373(9680):2055–2066.
6. Chaudhuri KR, Martinez-Martin P, Brown RG, et al. The metric properties of a novel non-motor symptoms scale for Parkinson's disease: results from an international pilot study. *Mov Disord.* 2007;22(13):1901–1911.
7. Hughes AJ, Daniel SE, Kilford L, Lees AJ. Accuracy of clinical diagnosis of idiopathic Parkinson's disease: a clinic-pathological study of 100 cases. *J Neurol Neurosurg Psychiatry.* 1992;55(3):181–184.
8. Hughes AJ, Daniel SE, Ben-Shlomo Y, Lees AJ. The accuracy of diagnosis of parkinsonian syndromes in a specialist movement disorder service. *Brain.* 2002;125(Pt4):861–870.
9. Reijnders JS, Ehrt U, Weber WE, Aarsland D, Leentjens AF. A systematic review of prevalence studies of depression in Parkinson's disease. *Mov Disord.* 2008;23(2):183–189.
10. Fahn S, Elton RL; for UPDRS program members. Unified Parkinson's disease rating scale. In: Fahn S, Marsden CD, Goldstein M, Calne DB, editors. *Recent Developments in Parkinson's Disease.* Florham Park: Macmillan Healthcare Information; 1987;2:153–163, 293–304.
11. Hamilton M. A rating scale for depression. *J Neurol Neurosurg Psychiatry.* 1960;23:56–62.
12. Brown RG, Dittner A, Findley L, Wessely SC. The Parkinson fatigue scale. *Parkinsonism Relat Disord.* 2005;11(1):49–55.
13. Evans JR, Mason SL, Williams-Gray CH, et al. The natural history of treated Parkinson's disease in an incident, community based cohort. *J Neurol Neurosurg Psychiatry.* 2011;82(10):1112–1118.
14. Folstein MF, Folstein SE, McHugh PR. "Mini-mental state". A practical method for grading the cognitive state of patients for the clinician. *J Psychiatr Res.* 1975;12(3):189–198.
15. Nasreddine ZS, Phillips NA, Bédirian V, et al. The Montreal Cognitive Assessment, MoCA: a brief screening tool for mild cognitive impairment. *J Am Geriatr Soc.* 2005;53(4):695–699.
16. Lessig S, Nie D, Xu R, Corey-Bloom J. Changes on brief cognitive instruments over time in Parkinson's disease. *Mov Disord.* 2012;27(9):1125–1128.
17. Doty RL, Deems DA, Stellar S. Olfactory dysfunction in Parkinsonism: a general deficit unrelated to neurologic signs, disease stage, or disease duration. *Neurology.* 1988;38(8):1237–1244.
18. Doty RL. Olfactory dysfunction in Parkinson disease. *Nat Rev Neurol.* 2012;8(6):329–339.
19. Doty RL, Shaman P, Dann M. Development of the University of Pennsylvania Smell Identification Test: a standardized microencapsulated test of olfactory function. *Physiol Behav.* 1984;32(3):489–502.
20. Hummel T, Sekinger B, Wolf SR, Pauli E, Kobal G. 'Sniffin' sticks': olfactory performance assessed by the combined testing of odor identification, odor discrimination and olfactory threshold. *Chem Senses.* 1997;22(1):39–52.
21. Müller A, Müngersdorf M, Reichmann H, Strehle G, Hummel T. Olfactory function in Parkinsonian syndromes. *J Clin Neurosci.* 2002;9(5):521–524.
22. Louter M, Aarden WC, Lion J, Bloem BR, Overeem S. Recognition and diagnosis of sleep disorders in Parkinson's disease. *J Neurol.* 2012;259(10):2031–2040.
23. Chaudhuri KR, Pal S, DiMarco A, et al. The Parkinson's disease sleep scale: a new instrument for assessing sleep and nocturnal disability in Parkinson's disease. *J Neurol Neurosurg Psychiatry.* 2002;73(6):629–635.
24. Buysse DJ, Reynolds CF 3rd, Monk TH, Berman SR, Kupfer DJ. The Pittsburgh Sleep Quality Index: a new instrument for psychiatric practice and research. *Psychiatry Res.* 1989;28(2):193–213.
25. Hardy J, Cai H, Cookson MR, Gwinn-Hardy K, Singleton A. Genetics of Parkinson's disease and Parkinsonism. *Ann Neurol.* 2006;60(4):389–398.
26. Tan EK, Jankovic J. Genetic testing in Parkinson disease: promises and pitfalls. *Arch Neurol.* 2006;63(9):1232–1237.

27. Polymeropoulos MH, Lavedan C, Leroy E, et al. Mutation in the alpha-synuclein gene identified in families with Parkinson's disease. *Science*. 1997;276(5321):2045–2047.
28. Paisán-Ruiz C, Jain S, Evans EW, et al. Cloning of the gene containing mutations that cause PARK8-linked Parkinson's disease. *Neuron*. 2004;44(4):595–600.
29. Zimprich A, Müller-Mysok B, Farrer M, et al. The PARK8 locus in autosomal dominant Parkinsonism: confirmation of linkage and further delineation of the disease-containing interval. *Am J Hum Genet*. 2004;74(1):11–19.
30. Kitada T, Asakawa S, Hattori N, et al. Mutations in the parkin gene cause autosomal recessive juvenile Parkinsonism. *Nature*. 1998;392(6676):605–608.
31. Bonifati V, Rizzu P, van Baren MJ, et al. Mutations in the DJ-1 gene associated with autosomal recessive early-onset Parkinsonism. *Science*. 2003;299(5604):256–259.
32. Valente EM, Abou-Sleiman PM, Caputo V, et al. Hereditary early-onset Parkinson's disease caused by mutations in PINK1. *Science*. 2004;304(5674):1158–1160.
33. Neumeyer JL, Wang S, Gao Y, et al. N-omega-fluoroalkyl analogs of (1R)-2 beta-carbomethoxy-3 beta-(4-iodophenyl)-tropane (beta-CIT): radiotracers for positron emission tomography and single photon emission computed tomography imaging of dopamine transporters. *J Med Chem*. 1994;37(11):1558–1561.
34. European Medicines Agency. *Summary of Product Characteristics*. London: European Medical Agency; 2011. Available from: http://www.ema.europa.eu/docs/en_GB/document_library/EPAR_-_Product_Information/human/000266/WC500035355.pdf. Accessed November 9, 2012.
35. Leung K. N-(3-Fluoropropyl)-2β-carbomethoxy-3β-(4-[123I]iodophenyl) nortropane. In: *Molecular Imaging and Contrast Agent Database (MICAD) [Internet]*. Bethesda: National Center for Biotechnology Information; 2004–2013.
36. Booij J, Andringa G, Rijks LJ, et al. [123I]FP-CIT binds to the dopamine transporter as assessed by biodistribution studies in rats and SPECT studies in MPTP-lesioned monkeys. *Synapse*. 1997;27(3):183–190.
37. Giros B, Caron MG. Molecular characterization of the dopamine transporter. *Trends Pharmacol Sci*. 1993;14(2):43–49.
38. Booij J, Busemann Sokole E, Stabin MG, Janssen AG, de Bruin K, van Royen EA. Human biodistribution and dosimetry of [123I]FP-CIT: a potent radioligand for imaging of dopamine transporters. *Eur J Nucl Med*. 1998;25(1):24–30.
39. Lundkvist C, Halldin C, Swahn CG, et al. [O-methyl-11C]beta-CIT-FP, a potential radioligand for quantitation of the dopamine transporter: preparation, autoradiography, metabolite studies, and positron emission tomography examinations. *Nucl Med Biol*. 1995;22(7):905–913.
40. Günther I, Hall H, Halldin C, Swahn CG, Farde L, Sedvall G. [125I] beta-CIT-FE and [125I] beta-CIT-FP are superior to [125I] beta-CIT for dopamine transporter visualization: autoradiographic evaluation in the human brain. *Nucl Med Biol*. 1997;24(7):629–634.
41. Booij J, de Jong J, de Bruin K, Knol R, de Win MM, van Eck-Smit BL. Quantification of striatal dopamine transporters with 123I-FP-CIT SPECT is influenced by the selective serotonin reuptake inhibitor paroxetine: a double-blind, placebo-controlled, crossover study in healthy control subjects. *J Nucl Med*. 2007;48(3):359–366.
42. Lavalaye J, Knol RJ, de Bruin K, Reneman L, Janssen AG, Booij J. [123I] FP-CIT binding in rat brain after acute and sub-chronic administration of dopaminergic medication. *Eur J Nucl Med*. 2000;27(3):346–349.
43. Food and Drug Administration. *Center for Drug Evaluation and Research*. Silver Spring, Maryland, USA: Food and Drug Administration; 2011. Available from: http://www.accessdata.fda.gov/drugsatfda_docs/nda/2011/022454sOrig1s000Lb1.pdf. Accessed November 9, 2012.
44. Scherfler C, Nocker M. Dopamine transporter SPECT: how to remove subjectivity? *Mov Disord*. 2009;24 Suppl 2:S721–S724.
45. Benamer HT, Oertel WH, Patterson J, et al. Prospective study of presynaptic dopaminergic imaging in patients with mild Parkinsonism and tremor disorders: part 1. Baseline and 3-month observations. *Mov Disord*. 2003;18(9):977–984.
46. Benito-León J, Louis ED, Bermejo-Pareja F; Neurological Disorders in Central Spain Study Group. Risk of incident Parkinson's disease and Parkinsonism in essential tremor: a population based study. *J Neurol Neurosurg Psychiatry*. 2009;80(4):423–425.
47. Benamer TS, Patterson J, Grosset DG, et al. Accurate differentiation of Parkinsonism and essential tremor using visual assessment of [123I]-FP-CIT SPECT imaging: the [123I]-FP-CIT study group. *Mov Disord*. 2000;15(3):503–510.
48. Marshall VL, Reiningner CB, Marquardt M, et al. Parkinson's disease is overdiagnosed clinically at baseline in diagnostically uncertain cases: a 3-year European multicenter study with repeat [123I]FP-CIT SPECT. *Mov Disord*. 2009;24(4):500–508.
49. de la Fuente-Fernández R. Role of DaTSCAN and clinical diagnosis in Parkinson disease. *Neurology*. 2012;78(10):696–701.
50. Antonini A, Benti R, De Notaris R, et al. 123I-Ioflupane/SPECT binding to striatal dopamine transporter (DAT) uptake in patients with Parkinson's disease, multiple system atrophy, and progressive supranuclear palsy. *Neurol Sci*. 2003;24(3):149–150.
51. Plotkin M, Amthauer H, Klaffke S, et al. Combined 123I-FP-CIT and 123I-IBZM SPECT for the diagnosis of parkinsonian syndromes: study on 72 patients. *J Neural Transm*. 2005;112(5):677–692.
52. Cilia R, Rossi C, Frosini D, et al. Dopamine transporter SPECT imaging in corticobasal syndrome. *PLoS One*. 2011;6(5):e18301.
53. Vlaar AM, de Nijs T, Kessels AG, et al. Diagnostic value of 123I-ioflupane and 123I-iodobenzamide SPECT scans in 248 patients with parkinsonian syndromes. *Eur Neurol*. 2008;59(5):258–266.
54. Zijlmans JC, Daniel SE, Hughes AJ, Révész T, Lees AJ. Clinicopathological investigation of vascular Parkinsonism, including clinical criteria for diagnosis. *Mov Disord*. 2004;19(6):630–640.
55. Contrafatto D, Mostile G, Nicoletti A, et al. [(123I)]FP-CIT-SPECT asymmetry index to differentiate Parkinson's disease from vascular Parkinsonism. *Acta Neurol Scand*. 2012;126(1):12–16.
56. Walker Z, Jaros E, Walker RW, et al. Dementia with Lewy bodies: a comparison of clinical diagnosis, FP-CIT single photon emission computed tomography imaging and autopsy. *J Neurol Neurosurg Psychiatry*. 2007;78(11):1176–1181.
57. Tolosa E, Coelho M, Gallardo M. DAT imaging in drug-induced and psychogenic Parkinsonism. *Mov Disord*. 2003;18 Suppl 7:S28–S33.
58. Gaig C, Martí MJ, Tolosa E, et al. 123I-Ioflupane SPECT in the diagnosis of suspected psychogenic Parkinsonism. *Mov Disord*. 2006;21(11):1994–1998.
59. Towey DJ, Bain PG, Nijran KS. Automatic classification of 123I-FP-CIT (DaTSCAN) SPECT images. *Nucl Med Commun*. 2011;32(8):699–707.
60. Illan IA, Gorz JM, Ramirez J, Segovia F, Jimenez-Hoyuela JM, Ortega Lozano SJ. Automatic assistance to Parkinson's disease diagnosis in DaTSCAN SPECT imaging. *Med Phys*. 2012;39(10):5971–5980.
61. Segovia F, Gorz JM, Ramirez J, Alvarez I, Jimenez-Hoyuela JM, Ortega SJ. Improved Parkinsonism diagnosis using a partial least squares based approach. *Med Phys*. 2012;39(7):4395–4403.
62. Van Laere K, Everaert L, Annemans L, Gonce M, Vandenberghe W, Vander Borgh T. The cost effectiveness of 123I-FP-CIT SPECT imaging in patients with an uncertain clinical diagnosis of Parkinsonism. *Eur J Nucl Med Mol Imaging*. 2008;35(7):1367–1376.
63. Antonini A, Berto P, Lopatriello S, Tamma F, Annemans L, Chambers M. Cost-effectiveness of 123I-FP-CIT SPECT in the differential diagnosis of essential tremor and Parkinson's disease in Italy. *Mov Disord*. 2008;23(15):2202–2209.
64. Kupsch AR, Bajaj N, Weiland F, et al. Impact of DaTscan SPECT imaging on clinical management, diagnosis, confidence of diagnosis, quality of life, health resource use and safety in patients with clinically uncertain parkinsonian syndromes: a prospective 1-year follow-up of an open-label controlled study. *J Neurol Neurosurg Psychiatry*. 2012;83(6):620–628.

Degenerative Neurological and Neuromuscular Disease

Dovepress

Publish your work in this journal

Degenerative Neurological and Neuromuscular Disease is an international, peer-reviewed, open access journal focusing on research into degenerative neurological and neuromuscular disease, identification of therapeutic targets and the optimal use of preventative and integrated treatment interventions to achieve improved outcomes, enhanced

survival and quality of life for the patient. The manuscript management system is completely online and includes a very quick and fair peer-review system. Visit <http://www.dovepress.com/testimonials.php> to read real quotes from published authors.

Submit your manuscript here: <http://www.dovepress.com/degenerative-neurological-and-neuromuscular-disease-journal>