

Visual and subjective outcomes of phototherapeutic keratectomy after Descemet's stripping endothelial keratoplasty

Bryan S Lee^{1,2}
David R Hardten²

¹Department of Ophthalmology, University of Washington, Seattle, WA, ²Minnesota Eye Consultants, Minneapolis, MN, USA

Background: Patients with endothelial disease also often have scarring or surface corneal disease. This study examined the outcomes of phototherapeutic keratectomy (PTK) performed in patients with prior Descemet's stripping endothelial keratoplasty (DSEK).

Methods: This retrospective case series examined all patients undergoing PTK after DSEK in a single private practice. The primary outcome was best-corrected visual acuity, with secondary outcomes of change in spherical equivalent versus targeted change, change in endothelial cell count, improvement in corneal topography, and subjective satisfaction with vision.

Results: For the ten patients who met the inclusion criteria, mean best-corrected visual acuity improved from logarithm of the minimum angle of resolution (logMAR) 0.43 to 0.36 ($P=0.24$) at the most recent postoperative visit. PTK treatments that included a refractive component showed good predictability of 1.13 diopters spherical equivalent/diopter attempted. There was no evidence of a decrease in endothelial cell count from PTK, even with the use of mitomycin C ($P=0.95$). Subjectively, 80% of patients noted improvement in their vision.

Conclusion: PTK after DSEK has the potential to improve patients' vision with high levels of patient satisfaction, even though many patients had significant ocular comorbidities. Surgeons should consider using PTK to treat anterior corneal pathology following DSEK.

Keywords: phototherapeutic keratectomy, Descemet's stripping endothelial keratoplasty, anterior basement membrane dystrophy, irregular astigmatism

Introduction

Patients with corneal endothelial disease frequently have corneal scarring as a result of chronic corneal edema or concomitant surface disease. Fuchs' endothelial dystrophy and anterior basement membrane dystrophy are common conditions, so it is fairly common for a patient to have both problems. Furthermore, eyes with Fuchs' dystrophy have greater higher order aberrations than age-matched controls, and Descemet's stripping endothelial keratoplasty (DSEK) does not appear to change the higher order aberrations.¹

Patients with both anterior and posterior pathology could have a full-thickness corneal transplant, but endothelial keratoplasty has multiple advantages over penetrating keratoplasty. These include faster healing time, decreased induction of astigmatism, improved globe integrity, and less risk of rejection with accordingly less need for antirejection medication.^{2,3} Therefore, a staged procedure with endothelial keratoplasty followed by phototherapeutic keratectomy (PTK) to treat anterior scarring could provide an attractive alternative to a full-thickness graft.

Correspondence: Bryan S Lee
Department of Ophthalmology, University of Washington, Campus Box 359608, 325 Ninth Ave, Seattle, WA 98104, USA
Tel +1 206 685 1916
Fax +1 206 685 7055
Email leemd@uw.edu

To our knowledge, there have been two published case reports on PTK after DSEK.^{4,5} Hongyok et al reported on two patients who had PTK with mitomycin C for subepithelial fibrosis after DSEK with best corrected visual acuity improvement from 20/400 to 20/40 in one and from 20/100 to 20/40 in another. Awdeh et al also had two patients with subepithelial fibrosis but did not use mitomycin C, with one going from 20/70 to 20/40 and the second 20/40 to 20/25.

In this paper, we report on a series of a relatively high number of patients with PTK after DSEK and report the results not only of objective criteria such as best corrected visual acuity (BCVA) but also of subjective data such as quality of vision and satisfaction. Secondary outcomes of interest include changes in refraction, endothelial cell count, and corneal topography.

Materials and methods

This retrospective case series included all of the patients in a single practice who had PTK after DSEK. These patients were identified by Current Procedural Terminology codes in billing records, and the data were then de-identified for analysis. Twelve patients (12 eyes) underwent PTK after DSEK between 2008 and 2012. Patients with conditions that were thought to limit visual potential significantly and those with less than 6 months of follow-up were excluded.

One patient had severe glaucoma after DSEK, with maximum intraocular pressures over 40 mmHg. The patient eventually required insertion of a glaucoma drainage device and four-drop medical therapy, but the vision was judged to have been so severely compromised by glaucoma that this patient was excluded from the analysis. Another patient had only 3 months of postoperative care before being lost to follow-up and was therefore excluded as well.

Surgical technique

PTK was performed based on the surgeon's recommendation for each patient's clinical situation. The surgeons used the Star S4 VISX laser (Abbott Medical Optics, Abbott Park, IL, USA) for all cases. In five cases, the laser treatment was conventional PTK, with removal of the corneal epithelium using 70% isopropyl alcohol followed by mechanical superficial keratectomy with light brushing of the surface of the cornea with a blunt spatula, followed by a smoothing treatment that removed several microns of tissue. In two cases, the treatment consisted of conventional PTK combined with a refractive treatment. In the other three cases, there was corneal scar noted, and the surgeon believed that epithelial removal combined with the refractive treatment pattern

would treat the area of scar adequately, so we regarded this as PTK also. Of the five cases with a refractive treatment component, two were CustomVue[®] wavefront-guided treatments (Abbott Medical Optics), and three were conventional photorefractive keratectomy (PRK) treatments. Mitomycin C 0.2 mg/mL was used after excimer laser at the surgeon's discretion and was used in nine of the ten study patients with a time ranging from 15 to 90 seconds.

Data analysis

Objective data included BCVA, refraction, and corneal topography, and subjective data included the patient's chief complaint and the history of present illness from preoperative and postoperative visits. Some of the patients had pre-PTK and post-PTK endothelial cell counts, so these were recorded when available.

Two-tailed Student's *t*-tests were used to compare the primary outcome, ie, pre-PTK and post-PTK BCVA, with an alpha of 0.05. Postoperative data points were 1, 3, 6, 12, and 24 months after PTK. Secondary outcomes included subjective satisfaction with PTK at the most recent clinic visit, change in the regularity of astigmatism on topography, change in endothelial cell count by specular microscopy, and change in spherical equivalent versus the targeted change.

Results

The ten patients (ten eyes) in this case series all had at least 6 months of follow-up following PTK after DSEK (mean 776 days, range 455–1442 days, standard deviation 328). The mean age at DSEK was 72.0±11.2 (59–74) years and at PTK was 73.5±10.9 (61–95) years, ie, a mean interval of 492±242 (177–941) days. Eight patients (80%) had Fuchs' dystrophy as the underlying reason for DSEK, with two having pseudophakic corneal edema. All patients were pseudophakic. The indications for PTK were irregular astigmatism (100%), anterior basement membrane dystrophy (90%), scar (50%), and anisometropia (10%). None of the patients had recurrent epithelial erosions.

Ocular comorbidity was common in the group. Four patients had macular disease, including epiretinal membrane (n=1), neovascular age-related macular degeneration (n=1), dry macular degeneration (n=1), and pigmentary changes (n=2). Six had clinically significant blepharitis or dry eye syndrome, and three had either ocular hypertension or glaucoma.

The mean pre-DSEK BCVA was logarithm of the minimum angle of resolution (logMAR) 0.68±0.57, and the peak mean post-DSEK BCVA was logMAR 0.33±0.22

($P=0.04$). Immediately prior to PTK, the mean BCVA had declined to logMAR 0.43 ± 0.28 . For the study group, the BCVA after PTK was logMAR 0.375 ± 0.34 at 6 months ($n=9$, $P=0.8$), 0.45 ± 0.25 at 12 months ($n=9$, $P=0.7$), and 0.31 ± 0.17 at 24 months ($n=7$, $P=0.3$). The mean BCVA at the most recent clinic visit was 0.36 ± 0.22 ($P=0.24$). Fifty percent of patients had $\geq 20/40$ vision on their last visit, and 20% were 20/50 (Figure 1).

Two patients (20%) lost one line of their pre-PTK BCVA at their most recent post-PTK visit (Figure 2). The patient who lost two lines of vision had BCVA 20/25 before PTK and also at the 6-month postoperative visit but was 20/40 on the most recent visit, when no refraction was performed. The patient who lost one line of vision had age-related macular degeneration and had a decline in BCVA from 20/40 to 20/50.

For the patients with conventional PTK treatment only, the outcome was an improvement from logMAR 0.64 to 0.50 ($P=0.17$). For all patients, mean refraction changed from a spherical equivalent of $+0.81\pm 2.2$ (range -4 to $+2.75$) diopters to -0.5 ± 1.5 (range -2.75 to $+2.88$) diopters. For the five with a refractive component to their PTK, the BCVA was 0.22 both pre-PTK and post-PTK ($P=1.0$) with a mean preoperative spherical equivalent of 0.125 ± 2 (-0.625 to $+3.75$) diopters and postoperative spherical equivalent of -0.75 ± 0.54 (-1.75 to -0.50) diopters. Comparing the

actual change in spherical equivalent with the targeted change for patients with a refractive treatment component, there was a 1.13 diopter change per diopter of targeted change with an r^2 correlation of 0.98 for the study group (Figure 3).

The endothelial cell count did not differ substantially after PTK for patients with pre-laser and post-laser data available ($n=5$). The mean cell counts were $1,701\pm 688$ (606–2,342) pre-PTK and $1,595\pm 549$ (822–2,110) post-PTK ($P=0.95$). The surgeon noted improvement in five of the eight patients who had post-PTK topography, while there was no comment for the other three.

Table 1 shows the patients' subjective impression of their vision pre-PTK and post-PTK. Eighty percent noted definite improvement in vision, including all three who had a decrease in BCVA. Of the two who were not as satisfied, one felt that his vision "may be dimmer" but had unchanged BCVA. The other thought their vision "fluctuated" but had retinal disease that was thought to be vision-limiting and improved from logMAR 0.7 to 0.54.

There were no complications attributable to PTK in the study group. One patient had a steroid injection for episcleritis performed elsewhere that led to a pressure spike but subsequently had a return to a normal pressure. Two patients had mild amounts of residual basement membrane changes seen at the slit lamp examination after PTK. No DSEK graft failed

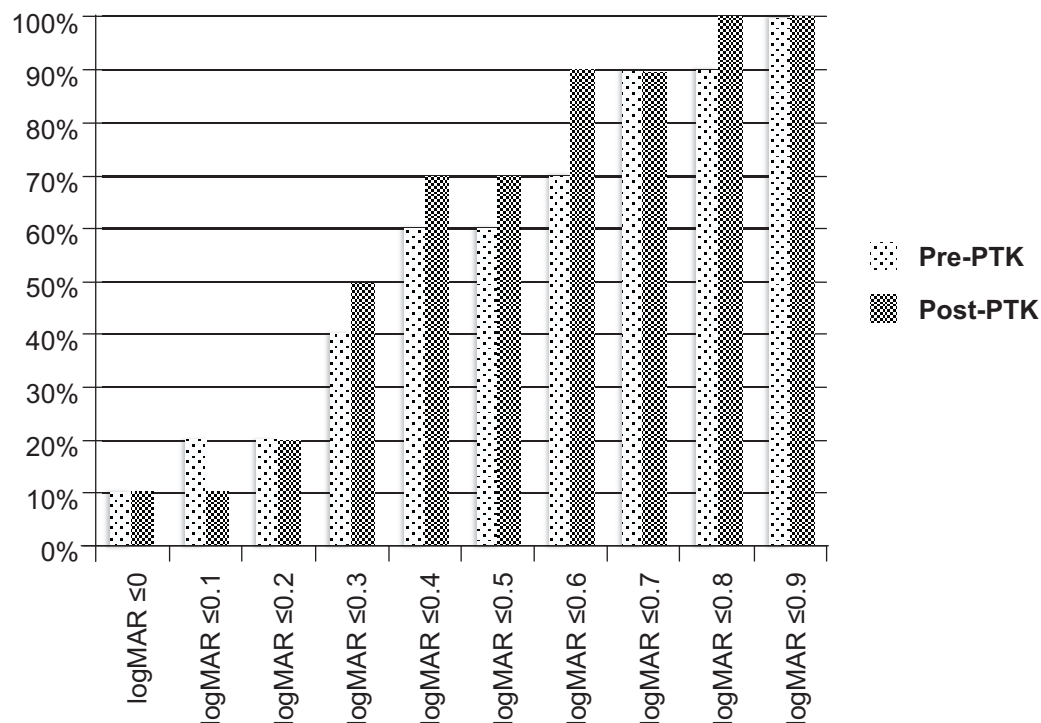


Figure 1 Percentage of patients in the study population with a given level of best-corrected visual acuity before PTK and on the final postoperative visit. **Abbreviations:** logMAR, logarithm of the minimum angle of resolution; PTK, phototherapeutic keratectomy.

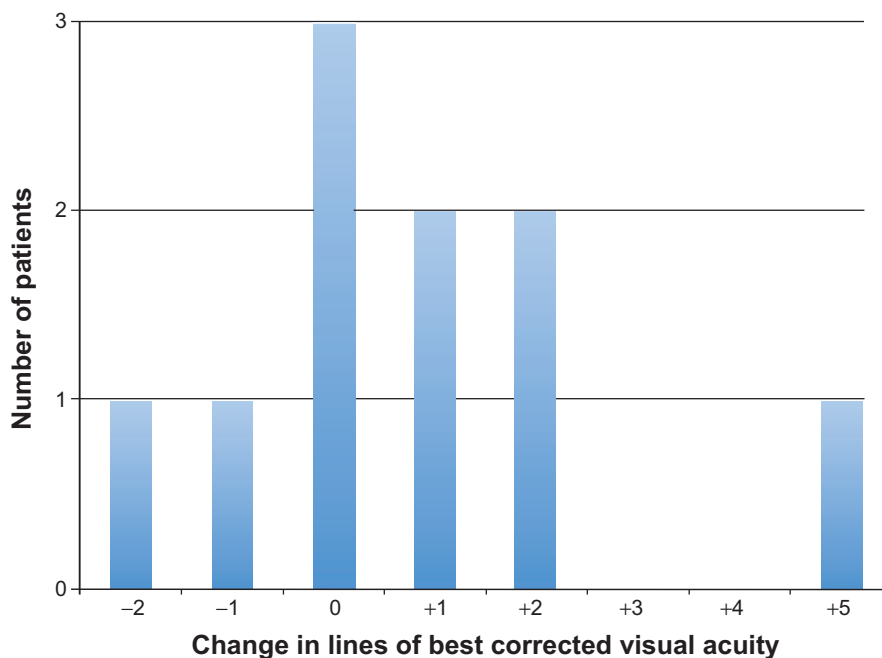


Figure 2 Distribution of change in lines of acuity at the most recent post-phototherapeutic keratectomy visit. The patient who lost two lines of vision had best-corrected visual acuity of 20/25 pre-phototherapeutic keratectomy and at the postoperative month 6 visit but was 20/40 at postoperative year 2, when refraction was not performed.

during the study, although guttae were noted in one patient and mild folds posteriorly in another.

Discussion

This case series did not show a statistically significant improvement in the primary outcome measure, ie, BCVA, after PTK. However, patients were highly subjectively

satisfied with their vision, and there were improvements in corneal topography and visual quality noted postoperatively, although these were not masked evaluations.

PTK performed with a refractive component demonstrated good predictability in change in spherical equivalent achieved. This is similar to a series reporting the outcomes of three laser-assisted in situ keratomileusis and two PRK procedures after DSEK that found uncorrected visual acuity ranged from 20/20 to 20/40 and BCVA from 20/20 to 20/30.⁶ Four of the patients were hyperopic pre-laser, and there was no difference in outcome for the laser-assisted in situ keratomileusis patients versus PRK patients. In that study, the patients had better visual potential, refracting to BCVA 20/20 to 20/30 preoperatively. In contrast, most patients

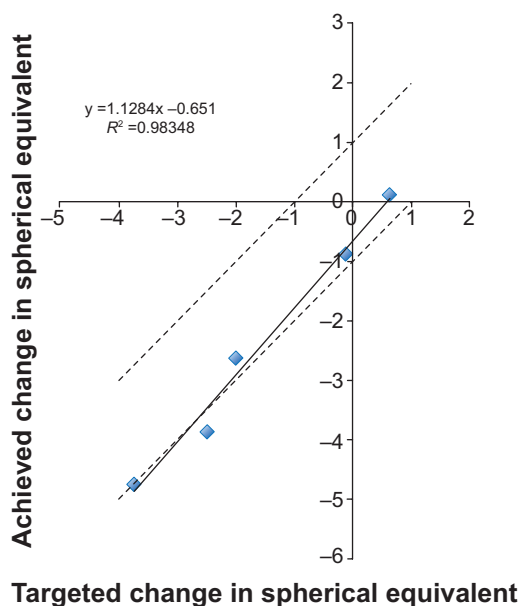


Figure 3 For the five patients who had a refractive component to their phototherapeutic keratectomy, the actual change in spherical equivalent is compared with the targeted change. The dashed lines show which points were within ± 1 diopter of the target.

Table I Comments at postoperative visits from patients undergoing phototherapeutic keratectomy

| Patient | Comment |
|---------|---|
| 1 | “happy” with vision |
| 2 | “satisfied” now that “finally got prescription right in glasses” |
| 3 | “loves” new glasses |
| 4 | vision “seems fine”; eyes “comfortable” |
| 5 | vision “may be dimmer” (noted to have edema from Fuchs’ endothelial dystrophy in the contralateral eye) |
| 6 | vision “fluctuates” |
| 7 | “better comfort” with less photophobia |
| 8 | vision “improved” |
| 9 | “improved but still not as good as the other eye” |
| 10 | “progressing”; better than the other eye |

in our case series did not achieve such a high visual acuity after DSEK. However, our patients likely had more scarring and higher order aberrations because the approach in these patients more often required broad-based smoothing with a therapeutic procedure. Furthermore, many of the patients in our case series had retinal disease and ocular hypertension or glaucoma.

Even in patients without an improvement in Snellen acuity from PTK, most were more satisfied with their vision after laser. This suggests that the laser procedure improved the quality of vision in ways not completely captured by Snellen acuity. However, setting appropriate patient expectations before undergoing PTK is important, as for any surgery.

Previous studies have raised the possibility that mitomycin C could have a toxic effect on native corneal endothelium.⁷⁻⁹ However, studies in patients undergoing refractive surgery have generally not shown harm.¹⁰⁻¹² In this case series, the available endothelial cell counts failed to show any decrease in the DSEK graft from the use of mitomycin C, although this involved only a small number of patients and the variability of specular microscopy seemed significant, given that it is unlikely a patient truly increased their endothelial cell count by 1,344 cells/mm² post-PTK.

The limitations of this study include its small size and the fact that both the patient and surgeon were not blinded to the treatment. This could have affected patients' subjective assessments of the outcome. Additionally, each patient's treatment was individualized and determined by the surgeon, with different treatment algorithms, nomograms, and mitomycin C use.

Future studies should include more patients and standardize the treatment further. It also would be valuable to determine which patients with both anterior and endothelial corneal disease would benefit more from a penetrating keratoplasty instead of a staged approach of DSEK followed by PTK. Potentially, a randomized controlled trial could help answer this question. Given the advantages that DSEK offers in terms of shorter healing time, superior globe

integrity, fewer sutures, and fewer postoperative visits, combining DSEK and PTK is a successful approach for many patients.

Disclosure

DRH is a consultant for Abbott Medical Optics. Otherwise, there are no funding sources relevant to this paper. BSL has no conflicts of interest to declare.

References

1. Patel SV, Baratz KH, Maguire LJ, Hodge DO, McLaren JW. Anterior corneal aberrations after Descemet's stripping endothelial keratoplasty for Fuchs' endothelial dystrophy. *Ophthalmology*. 2012; 119:1522-1529.
2. Bahar I, Kaiserman I, Levinger E, Sansanayudh W, Slomovic AR, Rootman DS. Retrospective contralateral study comparing Descemet stripping automated endothelial keratoplasty with penetrating keratoplasty. *Cornea*. 2009;28:485-488.
3. Bahar I, Kaiserman I, McAllum P, Slomovic A, Rootman D. Comparison of posterior lamellar keratoplasty techniques to penetrating keratoplasty. *Ophthalmology*. 2008;115:1525-1533.
4. Hongyok T, Kim A, Jun AS, Ladas JG, Chuck RS. Phototherapeutic keratectomy with mitomycin C after Descemet stripping automated endothelial keratoplasty. *Br J Ophthalmol*. 2010;94:378-379.
5. Awdeh RM, Abbey AM, Vroman DT, et al. Phototherapeutic keratectomy for the treatment of subepithelial fibrosis and anterior corneal scarring after Descemet stripping automated endothelial keratoplasty. *Cornea*. 2012;31:761-763.
6. Ratanasit A, Gorovoy MS. Laser-assisted in situ keratomileusis or photorefractive keratectomy after Descemet stripping automated endothelial keratoplasty. *Cornea*. 2011;30:787-789.
7. Avisar R, Apel I, Avisar I, Weinberger D. Endothelial cell loss during pterygium surgery: importance of timing of mitomycin C application. *Cornea*. 2009;28:879-881.
8. Storr-Paulsen T, Norregaard JC, Ahmed S, Storr-Paulsen A. Corneal endothelial cell loss after mitomycin C-augmented trabeculectomy. *J Glaucoma*. 2008;17:654-657.
9. Bahar I, Kaiserman I, Lange AP, et al. The effect of mitomycin C on corneal endothelium in pterygium surgery. *Am J Ophthalmol*. 2009; 147:447-452.
10. de Benito-Llopis L, Teus MA, Ortega M. Effect of mitomycin-C on the corneal endothelium during excimer laser surface ablation. *J Cataract Refract Surg*. 2007;33:1009.
11. Teus MA, de Benito-Llopis L, Alio JL. Mitomycin C in corneal refractive surgery. *Surv Ophthalmol*. 2009;54:487-502.
12. Zhao LQ, Wei RL, Ma XY, Zhu H. Effect of intraoperative mitomycin-C on healthy corneal endothelium after laser-assisted subepithelial keratectomy. *J Cataract Refract Surg*. 2008;34:1715-1719.

Clinical Ophthalmology

Publish your work in this journal

Clinical Ophthalmology is an international, peer-reviewed journal covering all subspecialties within ophthalmology. Key topics include: Optometry; Visual science; Pharmacology and drug therapy in eye diseases; Basic Sciences; Primary and Secondary eye care; Patient Safety and Quality of Care Improvements. This journal is indexed on

Submit your manuscript here: <http://www.dovepress.com/clinical-ophthalmology-journal>

Dovepress

PubMed Central and CAS, and is the official journal of The Society of Clinical Ophthalmology (SCO). The manuscript management system is completely online and includes a very quick and fair peer-review system, which is all easy to use. Visit <http://www.dovepress.com/testimonials.php> to read real quotes from published authors.