

# Inner retinal damage after exposure to green diode laser during a laser show

Sohee Jeon  
Won Ki Lee

Department of Ophthalmology,  
Seoul St Mary's Hospital,  
College of Medicine, The Catholic  
University of Korea, Seoul, Korea

**Abstract:** Here we report two cases of retinal damage after exposure to a 510 nm laser diode during a laser show. The first patient was a 20-year-old female who presented with decreased visual acuity in her right eye after visiting a dance party with a diode laser show (wavelength 510 nm, power 2 mW), although she did not directly see the light. Retinal examination revealed a sub-internal limiting membrane hemorrhage and a small laser burn. The second patient was a 20-year-old female who visited for decreased vision in her left eye. She described similar events as the first patient. An exposure to green diode laser can result in retinal damage. It is strongly recommended that certified personnel operate laser devices used in indoor laser shows under strict regulation.

**Keywords:** green diode laser, sub-internal limiting membrane hemorrhage, inner retinal damage

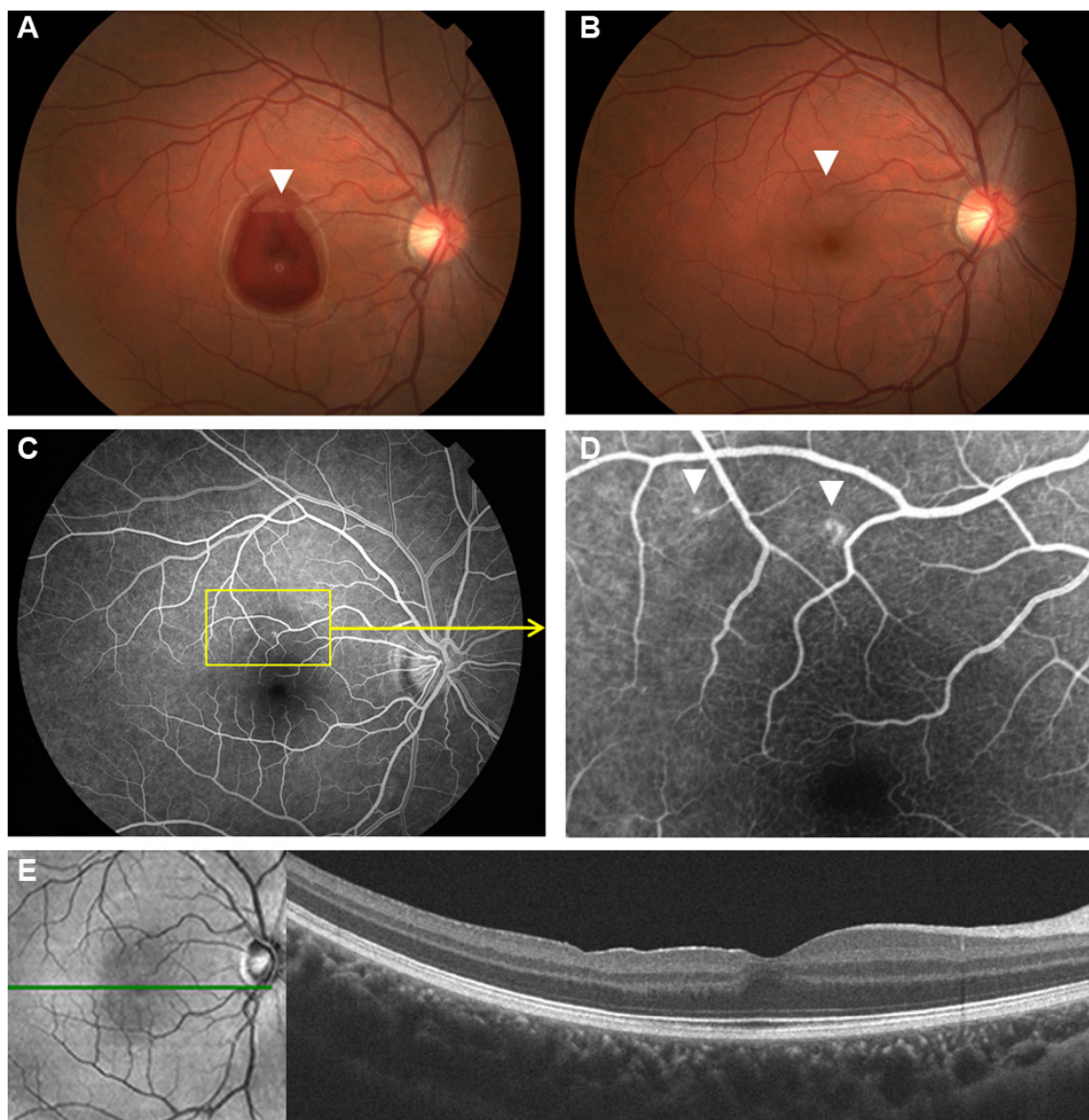
## Introduction

A recent report of bilateral retinal injuries from hand-held lasers by Yiu et al raised awareness of the hazards of recreational lasers.<sup>1</sup> The report referred to a class 4, high-powered 1,250 mW laser that was manufactured from the 445 nm blue diode of a dismantled home theater projector. Retinal injuries from commercial lasers have been shown in previous papers to have a fairly low incidence.<sup>2</sup> However, the incidence of ocular injuries has appeared to increase as personal lasers have come into widespread use.<sup>1,3-5</sup> We recently encountered two patients who presented with sub-internal limiting membrane hemorrhage after exposure to a 2 mW-powered 510 nm diode laser, which is usually considered relatively safe, during a laser show.

## Case I

A 20-year-old healthy female presented with decreased visual acuity in her right eye that developed several hours after visiting a party with laser shows. On examination, her best corrected visual acuity (BCVA) in the right eye was 20/800. Retinal examination revealed a sub-internal limiting membrane hemorrhage and a small, round, whitish lesion superior to the fovea that was consistent with a mild laser burn (Figure 1A). A pars plana vitrectomy was performed to remove the hemorrhage, and BCVA recovered to 20/20 without scotoma on visual field examination. Fluorescent angiography and spectral-domain optical coherent tomography were performed 2 months after the incident, and two small hyperfluorescent dot lesions were observed on fluorescent angiography (Figure 1B–D). Spectral-domain optical coherent tomography showed mild atrophic changes in the inner retina (Figure 1E).

Correspondence: Won Ki Lee  
Department of Ophthalmology,  
Seoul St Mary's Hospital,  
College of Medicine, The Catholic  
University of Korea, 505 Banpo-Dong,  
Seocho-Gu, Seoul, 137-701, Korea  
Email wklee@catholic.ac.kr



**Figure 1** Images from case 1.

**Notes:** (A) At initial presentation, a sub-ILM hemorrhage at the posterior pole and a small, round, whitish lesion were detected (arrowhead). (B) After removal of the sub-ILM hemorrhage, no other structural abnormality was detected except for the previously detected lesion (arrowhead). (C), Fluorescent angiography revealed small window defects resulting from retinal pigment epithelium changes 2 months after the accident (enlarged in (D)). Arrowheads indicate window defects. (E) Spectral domain optical coherent tomography (OCT) showed mild atrophic changes in the inner retina. The green line represents the en face location of the OCT image.

**Abbreviation:** ILM, internal limiting membrane.

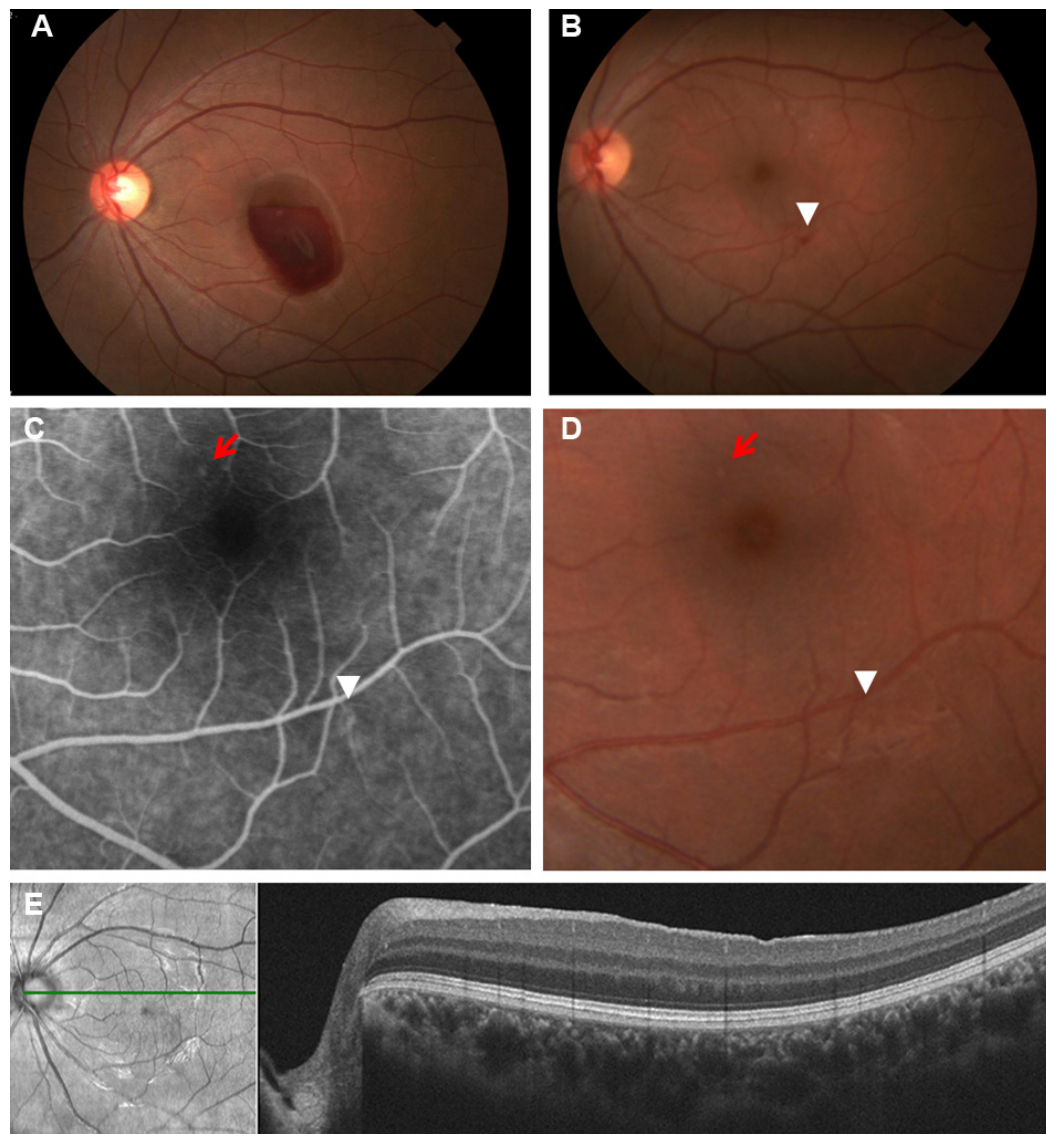
## Case 2

A 20-year-old female without any significant medical history visited the emergency department because of decreased vision in her left eye. She had been to the same dance club as the patient in case 1 the day prior to presentation in the emergency department, and described similar events (Figure 2A). The BCVA in her left eye was 20/800. After removing the sub-internal limiting membrane hemorrhage, a tiny intraretinal hemorrhage at the lower margin of the sub-internal limiting membrane hemorrhage was detected, along with a small burn at the superior margin (Figure 2B and D).

One week after vitrectomy, BCVA recovered to 20/20 without scotoma on a 24-2 visual field examination. Fluorescent angiography taken 2 weeks after the incident revealed small window defects (Figure 2C). Spectral-domain optical coherent tomography showed mild atrophic changes in the inner retina (Figure 2E).

## Discussion

Both patients in this report stated that they were unsure when their injuries occurred. They each recalled that a randomly aimed laser beam might have been directed into their



**Figure 2** Images from case 2.

**Notes:** (A) Fundus image at initial presentation showed sub-ILM hemorrhage. (B) After removal of the sub-ILM hemorrhage, intraretinal hemorrhage was detected (arrowhead). (C) Enlarged postoperative fluorescein angiographic image taken 2 weeks after the accident revealed another small window defect at the superior margin of the sub-ILM hemorrhage (red arrow) and at the previously detected area (white arrowhead). (D) Enlarged photograph of (B). Depigmented retinal lesions were noted in the fundus image (arrow and arrowhead). (E) Spectral-domain optical coherent tomography (OCT) showed mild atrophic changes in the inner retina. The green line represents the en face location of the OCT image.

**Abbreviation:** ILM, internal limiting membrane.

eyes. They stated that they had drunk a couple of beers but denied the use of illicit substances that night. The findings of mild retinal burns apart from the fovea in both patients support these statements. Although the precise mechanism of injury in the two patients presented herein is unknown, it is highly probable that exposure to the diode laser resulted in contraction of the retina and disruption of the adjacent microvasculature.

The importance of these cases is that the 510 nm diode laser used in these laser shows was graded as a class 3R device by the International Electrotechnical Commission

60825-1 standard.<sup>6</sup> It has been considered safe under 5 mW if handled carefully with restricted beam viewing. The persons in charge of the shows denied any kind of manipulation of the laser device, especially in terms of power output. Damage to the eye by accidental laser exposure depends on the power of the laser, wavelength, exposure time, and various individual factors. We speculate that multiple factors, such as repeated exposure to lasers that lasts for several hours, high body temperature while dancing, and the possibility of beam viewing while in a drunken state resulted in retinal damage from a relatively low-powered laser diode.

Importantly, both patients in this report had otherwise normal eyes and vision, and the retinal damage appeared to be caused by a class 3R device. Although a low-powered class 3R device has been considered relatively safe, to our knowledge, no comprehensive studies have investigated its effects on the eyes. Our cases emphasize the importance of strictly regulating the production and operation of laser devices for indoor laser shows, regardless of the safety level.

## Disclosure

The authors report no conflicts of interest in this work.

## References

1. Yiu G, Itty S, Toth CA. *JAMA Ophthalmol*. 2014;132(3):245–246.
2. Barkana Y, Belkin M. Laser eye injuries. *Surv Ophthalmol*. 2000;44(6):459–478.
3. Ziahosseini K, Doris JP, Turner GS. Laser eye injuries. Maculopathy from handheld green diode laser pointer. *BMJ*. 2010;340:c2982.
4. Mainster MA, Stuck BE, Brown J Jr. Assessment of alleged retinal laser injuries. *Arch Ophthalmol*. 2004;122(8):1210–1217.
5. Boosten K, Van Ginderdeuren R, Spileers W, et al. Laser-induced retinal injury following a recreational laser show: two case reports and a clinicopathological study. *Bull Soc Belge Ophtalmol*. 2011;317:11–16.
6. International Electrotechnical Commission. Safety of laser products – Part 1: Equipment classification and requirements. International Electrotechnical Commission. 2nd ed. 2007. Available from: [http://webstore.iec.ch/webstore/webstore.nsf/ArtNum\\_PK/37864!opendocument](http://webstore.iec.ch/webstore/webstore.nsf/ArtNum_PK/37864!opendocument). Accessed September 12, 2014.

### Clinical Ophthalmology

#### Publish your work in this journal

Clinical Ophthalmology is an international, peer-reviewed journal covering all subspecialties within ophthalmology. Key topics include: Optometry; Visual science; Pharmacology and drug therapy in eye diseases; Basic Sciences; Primary and Secondary eye care; Patient Safety and Quality of Care Improvements. This journal is indexed on

Submit your manuscript here: <http://www.dovepress.com/clinical-ophthalmology-journal>

Dovepress

PubMed Central and CAS, and is the official journal of The Society of Clinical Ophthalmology (SCO). The manuscript management system is completely online and includes a very quick and fair peer-review system, which is all easy to use. Visit <http://www.dovepress.com/testimonials.php> to read real quotes from published authors.