

Nasolacrimal duct obstruction following radioactive iodine ^{131}I therapy in differentiated thyroid cancers: review of 19 cases

Khalid Hussain Al-Qahtani¹
 Mushabbab Al Asiri²
 Mutahir A Tunio²
 Naji J Aljohani³
 Yasser Bayoumi⁴
 Iqbal Munir⁵
 Ayman AlAyoubi⁶

¹Department of Otolaryngology – Head and Neck Surgery, College of Medicine, Advanced Head and Neck Oncology, King Saud University, ²Radiation Oncology, Comprehensive Cancer Center, King Fahad Medical City, ³Endocrinology and Thyroid Oncology, King Fahad Medical City, Riyadh, Saudi Arabia; ⁴Radiation Oncology, NCI, Cairo University, Cairo, Egypt; ⁵Nuclear Medicine Sulaiman Al-Habib Hospital, ⁶Clinical Ophthalmology, King Fahad Medical City, Riyadh, Saudi Arabia

Background: Radioactive iodine ^{131}I therapy has long been used in the treatment of differentiated thyroid cancers (DTC). While salivary and lacrimal glandular complications secondary to ^{131}I therapy are well documented, there is little in the literature addressing nasolacrimal duct obstruction (NLDO). We aimed to evaluate the frequency of ^{131}I therapy-acquired NLDO, its correlation to ^{131}I therapy doses, and the surgical treatment outcome of this rare side effect.

Methods: From 2000–2012, a retrospective review of 864 among 1,192 patients with confirmed DTC who were treated with ^{131}I therapy was performed to examine the frequency of NLDO, its causative factors, as well as imaging, surgical intervention, and outcomes.

Results: Nineteen (2.2%) patients were identified with NLDO. The mean age was 51.9 ± 10.5 years (range: 39–72 years). Fifteen (78.9%) were female and four were male (21.1%). The mean individual ^{131}I doses were 311.1 ± 169.3 millicurie (mCi) (range: 150–600 mCi). The mean duration between the date of ^{131}I therapy and the occurrence of NLDO was 11.6 ± 4.1 months (range: 6.5–20). Fourteen (73.7%) patients had bilateral epiphora. Computed tomography dacryography allowed for the detection of all NLDO. Eighteen (94.7%) patients underwent dacryocystorhinostomy. Complete recovery was obtained in 14 (73.7%) patients. Age >45 years and ^{131}I therapy doses >150 mCi were significantly correlated with NLDO ($P=0.02$ and $P=0.03$, respectively).

Conclusion: NLDO is an underestimated complication of ^{131}I therapy in DTC patients. Clinicians should be aware of this rare complication for prompt intervention.

Keywords: nasolacrimal duct obstruction, radioactive iodine 131 therapy, differentiated thyroid cancers

Introduction

The use of post-thyroidectomy adjuvant radioactive iodine ^{131}I therapy is associated with dramatic decreases in locoregional recurrences, distant metastasis, and disease-related mortality in patients with differentiated thyroid carcinomas (DTC).¹ Although generally well tolerated, ^{131}I therapy is associated with substantial, albeit rare, side effects. While gastrointestinal problems, salivary and lacrimal gland complications, gonadal dysfunction, and second malignancies are well documented side effects of ^{131}I therapy, there is scant literature addressing nasolacrimal duct obstruction (NLDO).^{2,3} Different studies have mentioned that the incidence of NLDO was around 3% among DTC patients treated with ^{131}I therapy. The common presentation is an excessive overflow of tears (epiphora). Other signs and symptoms are the medial canthus mass, recurrent conjunctivitis, or infection (dacryocystitis).⁴

In the Kingdom of Saudi Arabia, DTC has become the second most common malignancy, behind only breast cancer, accounting for more than 10% of all cancers among

Correspondence: Mutahir A Tunio
 Radiation Oncology, Comprehensive
 Cancer Center, King Fahad Medical City,
 Riyadh, Saudi Arabia
 Tel +966 1288 9999
 Fax +966 1288 5754
 Email mkhairuddin@kfmc.med.sa

women.⁵ The majority of these patients require adjuvant ¹³¹I therapy at some point; only a small proportion of these patients can be at risk of ¹³¹I therapy-acquired NLDO, which was the aim of our study. We also aimed to determine the correlation between NLDO and ¹³¹I therapy along with other clinical and treatment parameters in DTC patients receiving ¹³¹I therapy in our population.

Methods

After formal approval from the institutional ethics committee, the medical records of 864 patients, among a total of 1,192 patients, with confirmed DTC who were treated with ¹³¹I therapy in two major tertiary care hospitals during the period from July 2000–December 2012 were reviewed using a computer-based institutional database system. Patients with NLDO were retrieved in the following manner:

- Demographic information (age at diagnosis and sex), as well as data regarding symptomatology, clinical procedures (anterior rhinoscopy and Jones fluorescein dye test), and ¹³¹I therapy doses in millicurie (mCi) were collected.
- Information on the different diagnostic imaging modalities used, including dacryoscintigraphy, computed tomography (CT) dacryography of the neck, and fluorodeoxyglucose positron emission tomography, was collected.
- Data regarding the surgical intervention used, including balloon dilation, stenting, dacryocystorhinostomy (DCR), type of DCR (external or endoscopic endonasal), symptoms relief, and duration of relief were also recorded.
- Any discrepancies in data acquisition were resolved by directly questioning the patients and treating physicians (ear, nose, and throat, oncology, ophthalmology, and nuclear medicine).
- However, no attempt to systematize other associated sinonasal problems (potential confounders) of the patients was performed.

Statistical analysis

The primary endpoint was the frequency of NLDO. All descriptive data were reported as the mean \pm standard deviation, and percentages. The secondary endpoint was the correlation of NLDO with ¹³¹I therapy (as tested by Pearson's correlation coefficients). Efforts were made to minimize the effects of potential confounders, which were controlled using multivariate analysis. Statistical analyses were performed using the computer program SPSS version 16.0. The Kaplan–Meier method was used to predict the cumulative risk of NLDO in our series.

Results

Among the 864 DTC patients who were treated with ¹³¹I therapy, 19 (2.2%) were identified with NLDO (Table 1). No event of NLDO was seen in any patient who was untreated with ¹³¹I therapy or was treated with ¹³¹I therapy doses below 150 mCi. The mean age of the study population was 51.9 ± 10.5 years (range: 39–72 years), and our population consisted of 15 females (78.9%) and four males (21.1%), with a female-to-male ratio of 3.7:1. The mean individual ¹³¹I dose was 311.1 ± 169.3 mCi (range: 150–600 mCi). The mean duration between the date of ¹³¹I therapy and the occurrence of apparent NLDO was 11.6 ± 4.1 months (range: 6.5–20 months).

Fourteen (73.7%) patients had bilateral epiphora. Dacryoscintigraphy allowed for the detection of 16 NLDO with a sensitivity of 84.2% (95% confidence interval [CI]: 60.4–96.4) and a specificity of 99.6% (95% CI: 98.9–99.9), while CT dacryography detected all cases of NLDO with a sensitivity of 100% (95% CI: 82.2–100) and a specificity of 100% (95% CI: 82.2–100).

DCR was performed in 32 completely stenosed nasolacrimal ducts of 18 (94.7%) patients – either bilaterally (63.2%) or unilaterally (26.3%). Three patients (15.8%) had endoscopic endonasal DCR. Observation was planned for one patient; but the patient had partial relief and was considered for DCR. Among the DCR patients, complete recovery was obtained in 14 (73.7%) patients, and partial relief was obtained in three (15.8%) patients. The success rates of external DCR and endoscopic endonasal DCR were 85.7% and 66.7%, respectively.

A significant correlation between NLDO and ¹³¹I therapy doses above 150 mCi was seen ($R=0.92$; $R^2=0.86$; $P=0.03$). Multivariate analysis showed that ¹³¹I therapy doses above 150 mCi and an age >45 years were important prognosticators (Figure 1).

Discussion

Acquired NLDO secondary to ¹³¹I therapy is an extremely rare complication in patients with DTC. In our cohort, the frequency of NLDO of 2.2% is consistent with other reported results (Table 2).^{6–10} The incidence rate of NLDO in the general population is lacking, despite a detailed medical literature search. In the majority of cases, the diagnosis is made upon the basis of spontaneous reporting of epiphora by the patients.⁶ This diagnostic delay leads to complete stenosis of the nasolacrimal ducts, and thus renders these patients to aggressive treatment.⁶ In the clinical setting, the Jones fluorescein dye test is of significant value in NLDO patients. One Australian study has demonstrated that a negative

Table 1 Patients' characteristics

Patient	Age (years)/sex	Diagnosis	¹³¹ I dose (mCi)	Symptoms	Onset from last ¹³¹ I treatment (months)	DSG	CT dacryography	Treatment	Symptom control
1	49/F	PTC	300	Bilateral epiphora	8	+	+	E-DCR	Complete
2	41/F	T3N1M0	600	Right eye epiphora	13	+	+	Observation	Partial
3	65/F	T3N1M1	400	Bilateral epiphora	7	+	+	E-DCR	Complete
4	53/F	T3N1M1	150	Right eye epiphora	10	+	+	E-DCR	Complete
5	69/F	T4N1M0	450	Bilateral epiphora	12	+	+	E-DCR	Complete
6	47/F	PTC	150	Left eye epiphora	11	+	+	EE-DCR	Complete
7	51/F	T4N0M0	550	Blurring of vision	20	+	+	EE-DCR	Partial
8	39/F	T3N1M1	150	Bilateral epiphora	6.5	-	+	E-DCR	Complete
9	47/M	T2N1M0	300	Bilateral epiphora	12.5	+	+	E-DCR	Complete
10	72/F	PTC	300	Right eye dacryocystitis	8	+	+	E-DCR	Complete
11	42/F	T3N1M0	550	Bilateral epiphora	15	+	+	E-DCR	Partial
12	42/M	PTC	150	Left eye epiphora	7.3	-	+	E-DCR	Complete
13	58/F	T2N1M0	210	Bilateral epiphora	14	+	+	E-DCR	Complete
14	45/M	PTC	350	Bilateral epiphora	14	+	+	E-DCR	Complete
15	46/F	T3N1M1	300	Bilateral epiphora	9	+	+	E-DCR	Partial
16	66/F	T2N1M0	300	Bilateral epiphora	12	-	+	EE-DCR	Complete
17	39/F	PTC	200	Bilateral epiphora	6.5	+	+	E-DCR	Complete
18	56/M	T2N1M1	600	Bilateral epiphora	19	+	+	Left eye observation Right eye E-DCR	Complete
19	60/F	T2N1M1	600	Bilateral epiphora	17	+	+	E-DCR	Complete
		T4N0M1							

Abbreviations: ¹³¹I, radioactive iodine; DSG, dacryoscintigraphy; CT, computed tomography; F, female; PTC, papillary thyroid carcinoma; E-DCR, external dacryocystorhinostomy; FTC, follicular thyroid carcinoma; EE-DCR, endoscopic endonasal dacryocystorhinostomy; M, male.

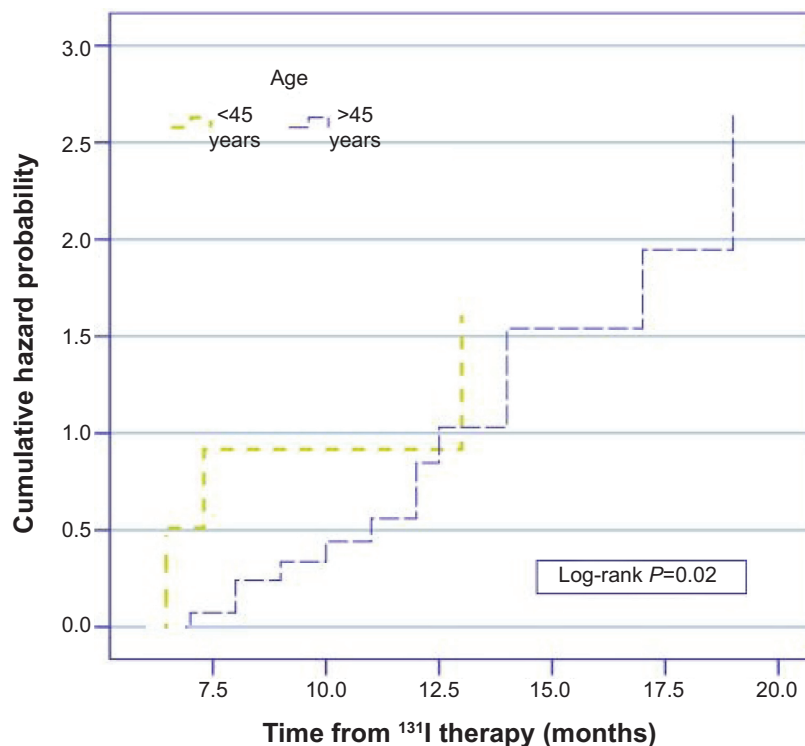


Figure 1 Kaplan–Meier curve of the cumulative hazard risk of ¹³¹I-acquired nasolacrimal duct obstruction.
Abbreviation: ¹³¹I, radioactive iodine I31.

single-drop Jones fluorescein dye test is also predictive of symptomatic improvement after DCR in patients with NLDO.¹¹

The postulated mechanism for ¹³¹I therapy-acquired NLDO is the direct uptake of ¹³¹I in the nasolacrimal duct membrane epithelial cells via the sodium (Na⁺)/iodide (I) symporter (NIS) leading to radiation-induced cell damage (inflammation and fibrosis/stenosis).⁹ The NIS is a membrane glycoprotein that mediates ¹³¹I uptake in the thyroid gland and several other extrathyroid tissues (salivary glands, lacrimal glands, and ciliary body of the eye).¹² Recently, Morgenstern et al¹³ have reported the overexpression of NIS in the nasolacrimal ducts using reverse transcriptase polymerase chain reaction and immunohistochemical analyses. In addition to the presence of sinonasal disease at the time of ¹³¹I therapy, the treatment may theoretically further decrease the flow in the nasolacrimal ducts and thus increase the exposure to ¹³¹I, which is secreted through the lacrimal system.³

The diagnosis of ¹³¹I therapy-acquired NLDO is challenging. Other possible causes (allergic or viral conjunctivitis, keratoconjunctivitis sicca, trichiasis, canaliculitis, iritis, and functional causes of excessive tears) should be ruled out to reach a definitive diagnosis of ¹³¹I therapy-acquired NLDO.¹⁴ ¹³¹I therapy-acquired NLDO is defined as: 1) the presence of NLDO in ¹³¹I therapy-treated patients; 2) an ¹³¹I dose–NLDO relationship; 3) immediate onset of symptoms after

¹³¹I therapy; and 4) the bilateral nature of NLDO in most of cases. CT dacryography using diluted contrast medium was found to be an easy and highly sensitive tool to evaluate NLDO in our cohort, which endorsed the findings of Garcier et al.¹⁵

Patients with incomplete NLDO have an excellent outlook with the use of balloon dilation and stenting, as complete recovery of symptoms is observed in 100% of cases.³ Although the literature supports the hypothesis of complete symptom recovery with observation alone, in a few cases of incomplete NLDO, we did not find that observation was a feasible option. The reason for this can be explained by the fact that NLDO is possibly a chronic radiation-induced injury that progresses over a period of time.¹⁶ The DCR success rate of 78.9% in our cohort is consistent with the findings of Fonseca et al.⁶ However, the endoscopic endonasal DCR success rate of 60% is much inferior to that reported in the literature, which warrants more personnel training in this area in our region.¹⁷

Because NLDO impairs the quality of life of a patient significantly, prevention of NLDO is a key issue. Currently, there is no mechanism available to stop the blockage of ¹³¹I uptake in the nasolacrimal ducts via the NIS during ¹³¹I therapy,³ and there is scant data available regarding the prophylactic use of 2-(S)-(3-aminopropylamino) ethylphosphorothioic acid (amifostine) during ¹³¹I therapy.¹⁸ Further, the effectiveness of topical saline drops, nasolacrimal duct massage,

Table 2 Different case studies and reports of ¹³¹I therapy-acquired NLDO reported in the literature

Study	NLDO N	Total patients treated with ¹³¹ I therapy	Age (years)	Mean individual ¹³¹ I dose (mCi)	Onset from last ¹³¹ I therapy (months)	Symptoms	Treatment	Symptoms relief
Kloos et al ³	10 (2.6%)	390	47.8 (range: 13–74)	180±15	6.5±1.4 (range: 3–16)	Epiphora, bilateral (50%) Epiphora, unilateral (50%)	Observation (30%) Balloon dilation (30%) DCR (40%)	Partial (60%) Complete (40%)
Sun and Hatipoglu ⁴	1	–	23	150	6	Epiphora, bilateral	DCR	Complete
Fonseca et al ⁶	17	–	30–80	571 (range: 200–1,200)	13.2 (range: 4–30)	Epiphora, bilateral (64.7%) Epiphora, unilateral (35.3%)	DCR (100%)	Complete (82.4%) Partial (17.6%)
Shepler et al ⁷	1	–	50	150	6	Epiphora, unilateral	Observation (5 years), DCR	Complete
Burns et al ⁸	26 (4.6%)	563	–	525 (range: 200–951)	13	–	Balloon dilation, DCR	–
Brockmann et al ⁹	1	–	54	700	6	Epiphora, bilateral	DCR	Complete
Savage et al ¹⁰	2	–	–	–	–	Epiphora, bilateral	–	–
Present study	19 (2.2%)	864	51.9 (range: 39–72)	311.1±169.3	11.6±4.1 (range: 65–20)	Epiphora, bilateral (73.7%) Epiphora, unilateral (26.3%)	Observation (5.3%) DCR (94.7%)	Partial (21.1%) Complete (78.9%)

Note: Data are presented as mean or mean ± standard deviation, except where otherwise indicated.

Abbreviations: ¹³¹I, radioactive iodine 131; NLDO, nasolacrimal duct obstruction; N, number; mCi, millicurie; DCR, dacryocystorhinostomy.

and delaying ¹³¹I therapy in patients with acute or chronic sinonasal problems as preventive measures needs to be tested. Low ¹³¹I therapy doses, whenever possible, can reduce the incidence of NLDO.¹⁹

The limitations of our study were: 1) no systematic attempt to screen for NLDO or the presence of other potential confounders (sinonasal problems) was performed; and 2) the presence of possible selection and recall bias in our cohort.

Conclusion

In conclusion, NLDO following ¹³¹I therapy in DTC patients is an under-recognized and rare complication, especially at higher ¹³¹I doses (>150 mCi). A multidisciplinary approach (nuclear medicine/oncology, ear, nose, and throat, and ophthalmology) is very important in the prevention and treatment of NLDO.

Author contributions

KHAQ and MAA designed the concept of the study. MAT, MAA, and YB carried out data collection; NJA, IM, and AAA carried out manuscript writing. MAT, YB, and AAA performed statistical analysis. All authors read and approved the final manuscript. All authors contributed toward data analysis, drafting and revising the paper and agree to be accountable for all aspects of the work.

Disclosure

The authors report no conflicts of interest in this work.

References

- Patel SS, Goldfarb M. Well-differentiated thyroid carcinoma: the role of post-operative radioactive iodine administration. *J Surg Oncol*. 2013;107(6):665–672.
- Fard-Esfahani A, Emami-Ardekani A, Fallahi B, et al. Adverse effects of radioactive iodine-131 treatment for differentiated thyroid carcinoma. *Nucl Med Commun*. 2014;35(8):808–817.
- Kloos RT, Duvuuri V, Jhiang SM, Cahill KV, Foster JA, Burns JA. Nasolacrimal drainage system obstruction from radioactive iodine therapy for thyroid carcinoma. *J Clin Endocrinol Metab*. 2002;87(12):5817–5820.
- Sun GE, Hatipoglu B. Epiphora after radioactive iodine ablation for thyroid cancer. *Thyroid*. 2013;23(2):243–245.
- Hussain F, Iqbal S, Mehmood A, Bazarbashi S, ElHassan T, Chaudhri N. Incidence of thyroid cancer in the Kingdom of Saudi Arabia, 2000–2010. *Hematol Oncol Stem Cell Ther*. 2013;6(2):58–64.
- Fonseca FL, Lunardelli P, Matayoshi S. [Lacrimal drainage system obstruction associated to radioactive iodine therapy for thyroid carcinoma]. *Arq Bras Oftalmol*. 2012;75(2):97–100. Portuguese.
- Shepler TR, Sherman SI, Faustina MM, Busaidy NL, Ahmadi MA, Esmaeli B. Nasolacrimal duct obstruction associated with radioactive iodine therapy for thyroid carcinoma. *Ophthalm Plast Reconstr Surg*. 2003;19(6):479–481.
- Burns JA, Morgenstern KE, Cahill KV, Foster JA, Jhiang SM, Kloos RT. Nasolacrimal obstruction secondary to I(131) therapy. *Ophthalm Plast Reconstr Surg*. 2004;20(2):126–129.

9. Brockmann H, Wilhelm K, Joe A, Palmedo H, Biersack HJ. Nasolacrimal drainage obstruction after radioiodine therapy: case report and a review of the literature. *Clin Nucl Med*. 2005;30(8):543–545.
10. Savage MW, Sobel RK, Hoffman HT, Carter KD, Finkelstein MW, Shriver EM. Salivary gland dysfunction and nasolacrimal duct obstruction: stenotic changes following I-131 therapy. *Ophthal Plast Reconstr Surg*. Epub 2014 May 15.
11. O'Donnell BA, Clement CI. Assessing patients with epiphora who are patent to syringing: clinical predictors of response to dacryocystorhinostomy. *Ophthal Plast Reconstr Surg*. 2007;23(3):173–178.
12. Jhiang SM, Cho JY, Ryu KY, et al. An immunohistochemical study of Na⁺/I⁻ symporter in human thyroid tissues and salivary gland tissues. *Endocrinology*. 1998;139(10):4416–4419.
13. Morgenstern KE, Vadysirisack DD, Zhang Z, et al. Expression of sodium iodide symporter in the lacrimal drainage system: implication for the mechanism underlying nasolacrimal duct obstruction in I(131)-treated patients. *Ophthal Plast Reconstr Surg*. 2005;21(5):337–344.
14. Fard-Esfahani A, Farzanefer S, Fallahi B, et al. Nasolacrimal duct obstruction as a complication of iodine-131 therapy in patients with thyroid cancer. *Nucl Med Commun*. 2012;33(10):1077–1080.
15. Garcier JM, Napon M, Chiambaretta F, et al. [CT dacryography without selective lacrimal duct catheterization: review of 39 patients]. *J Radiol*. 2002;83(11):1743–1747. French.
16. Pediatric Eye Disease Investigator Group. A randomized trial comparing the cost-effectiveness of 2 approaches for treating unilateral nasolacrimal duct obstruction. *Arch Ophthalmol*. 2012;130(12):1525–1533.
17. Ali MJ, Psaltis AJ, Bassiouni A, Wormald PJ. Long-term outcomes in primary powered endoscopic dacryocystorhinostomy. *Br J Ophthalmol*. Epub 2014 Jul 4.
18. Bohuslavizki KH, Klutmann S, Jenicke L, et al. Salivary gland protection by S-2-(3-aminopropylamino)-ethylphosphorothioic acid (amifostine) in high-dose radioiodine treatment: results obtained in a rabbit animal model and in a double-blind multi-arm trial. *Cancer Biother Radiopharm*. 1999;14(5):337–347.
19. Mallick U, Harmer C, Hackshaw A. The HiLo trial: a multicentre randomised trial of high- versus low-dose radioiodine, with or without recombinant human thyroid stimulating hormone, for remnant ablation after surgery for differentiated thyroid cancer. *Clin Oncol (R Coll Radiol)*. 2008;20(5):325–326.

Clinical Ophthalmology

Dovepress

Publish your work in this journal

Clinical Ophthalmology is an international, peer-reviewed journal covering all subspecialties within ophthalmology. Key topics include: Optometry; Visual science; Pharmacology and drug therapy in eye diseases; Basic Sciences; Primary and Secondary eye care; Patient Safety and Quality of Care Improvements. This journal is indexed on

Submit your manuscript here: <http://www.dovepress.com/clinical-ophthalmology-journal>

PubMed Central and CAS, and is the official journal of The Society of Clinical Ophthalmology (SCO). The manuscript management system is completely online and includes a very quick and fair peer-review system, which is all easy to use. Visit <http://www.dovepress.com/testimonials.php> to read real quotes from published authors.