

Antitumor activity of larotrectinib in tumors harboring *NTRK* gene fusions: a short review on the current evidence

This article was published in the following Dove Press journal:
OncoTargets and Therapy

Biagio Ricciuti¹
Carlo Genova²
Lucio Crinò³
Massimo Libra⁴
Giulia Costanza Leonardi^{4,5}

¹Department of Medical Oncology, Thoracic Oncology Unit, Santa Maria della Misericordia Hospital, University of Perugia, Perugia, Italy; ²Lung Cancer Unit, Ospedale Policlinico San Martino, Genova 16132, Italy; ³Department of Medical Oncology, Istituto Scientifico Romagnolo per lo Studio e la Cura dei Tumori, Meldola, Italy; ⁴Department of Biomedical and Biotechnological Sciences, Pathology and Oncology Section, University of Catania, Catania, Italy; ⁵Department of Pathology, Children's Hospital, Boston, MA, USA

Abstract: The development of deep-sequencing methods is now unveiling a new landscape of previously undetected gene fusion across different tumor types. Chromosomal translocation involving the *NTRK* gene family occur across a wide range of cancers in both children and adults. Preclinical studies have demonstrated that chimeric proteins encoded by *NTRK* rearrangements have oncogenic properties and drive constitutive expression and ligand-independent activation. Larotrectinib (ARRY470, LOXO101, Vitrakvi) is a highly and potent inhibitor of TRKA, TRKB, and TRKC, and has demonstrated remarkable antitumor activity against TRK-fusion-positive cancers with a favorable side-effect profile in phase I/II clinical trials. In November 2018, the US Food and Drug Administration granted accelerated approval to larotrectinib for adult and pediatric patients with solid tumors harboring *NTRK* gene fusions without known acquired resistance mutation. In this review, we discuss the clinical activity and safety profile of larotrectinib, focusing on the clinical trials that led to its first global approval.

Keywords: NTRK, chromosomal rearrangements, larotrectinib, resistance

Introduction

Chromosomal translocations are well-known oncogenic drivers in hematological and solid malignancies, and targeting gene fusions has become a highly effective strategy to treat rearrangement-driven cancers.¹⁻⁴ Somatic chromosomal rearrangements involving the *NTRK1*, *NTRK2*, or *NTRK3* genes occur in approximately 1% of all solid cancers and have been observed across a wide spectrum of tumor types.^{5,6} *NTRK1*, *NTRK2*, and *NTRK3* encode TRKA, TRKB, and TRKC, which consist in single-pass transmembrane proteins with high affinity for NGF, BDNF, and NT3.⁷ Upon binding with their respective ligands, TRKA, TRKB, and TRKC undergo conformational changes that lead to the activation of different downstream pathways, including Ras–Raf–MAPK, PI3K–Akt–mTOR and PLCc–PKC.^{7,8} In normal conditions, these receptors are involved in central nervous system development and maturation.⁹ However, the unrestrained activation of TRK-dependent pathways resulting from TRK fusion proteins leads to cell transformation, growth, and proliferation. Typically, TRK fusion proteins arise from chromosomal rearrangements involving the 5' region of a partner gene that is expressed by the progenitor tumor cell and the 3' region of one of the *NTRK* genes.⁸ The resultant mRNA fusion transcript encodes an in-frame protein encompassing the N-terminus of the fusion partner and the C-terminus of the TRK protein, including the tyrosine-kinase domain.⁸

Correspondence: Biagio Ricciuti
Department of Medical Oncology,
Thoracic Oncology Unit, Santa Maria
della Misericordia Hospital, University of
Perugia, I Piazzale Menghini, Perugia,
Piazzale Menghini 06129, Italy
Tel +39 075 578 4185
Fax +39 075 578 4185
Email biagio.ricciuti@gmail.com

Studies based on in vitro and in vivo models have recently shown that inhibiting the kinase activity of the TRK fusion proteins represents a promising therapeutic strategy.^{10–14} Accordingly, several clinical trials are currently ongoing to evaluate the efficacy of tyrosine-kinase inhibitors (TKIs) in NTRK fusion-positive tumors.

Although gene rearrangements represent the most common oncogenic alteration affecting the *NTRK* genes, point mutations, in-frame deletions, and alternative splicing of the *NTRK* gene family have also been reported to confer oncogenic properties.^{15,16} However, whether *NTRK* point mutations have any predictive value with regard to tyrosine-kinase inhibition is still unclear.

In this review, we summarize the clinical development of the pan-TRK inhibitor larotrectinib for the treatment of adult and pediatric patients with solid tumors harboring *NTRK* gene fusions.

NTRK gene fusion in cancer

Chromosomal fusion events involving the carboxyterminal-kinase domain of TRK and different upstream aminoterminal partners have been identified across different tumor types in both children and adults (Figure 1).⁵ Preclinical models and early clinical data indicate that these fusions lead to oncogene addiction, regardless of tissue of origin, and it has been estimated they occur in approximately 1% of all solid tumors.⁸ The increasing diffusion of sequencing technologies and availability of potential treatment strategies will likely boost the number of patients diagnosed with an *NTRK* gene fusion.

Lung cancer

NTRK rearrangements occur in a very small fraction of patients with lung cancer. Using fluorescent in situ hybridization (FISH) and targeted next-generation sequencing (NGS), Vaishnavi et al detected NTRK fusions in three of 91 (3.3%) patients with lung cancer and identified two novel NTRK fusion partners (*NTRK-MPRIP* and *NTRK-CD74*).¹⁷ Additionally, a novel *TRIM24-NTRK2* gene fusion has been identified in lung adenocarcinoma using a computational pipeline for the identification of gene fusions to the entire RNAseq data set from the Cancer Genome Atlas.⁴ More recently, in a phase I study of entrectinib for *NTRK*-rearranged solid tumors, Fargo et al used an anchored multiplex PCR for detection of fusion transcripts involving NTRK1.¹⁸ Among 1,378 patients screened, one patient with lung adenocarcinoma harbored a novel *SQSTM1-NTRK1* fusion transcript and one patient harbored a previously described *TPM3-NTRK1* rearrangement.¹⁹ Although the reported incidence of *NTRK1* fusion was 0.1%, the discrepancy with previous studies is likely to reflect the different sample size and the population screened for this study.

Colorectal cancer

Since its first identification in 1986, *NTRK* fusion has subsequently been documented in approximately 0.5%–2.0% of patients with colorectal cancer.^{20,21} Different studies have shown that *TPM3-NTRK1* gene rearrangement is a recurrent event in colorectal carcinoma.^{20–22} Along with *TPM3-NTRK1*-fusion, *TPR-NTRK1*-fusion has also been reported in colorectal tumors.²¹ More recently, a novel oncogenic rearrangement was identified in a patient with liver and adrenal gland metastases of colorectal

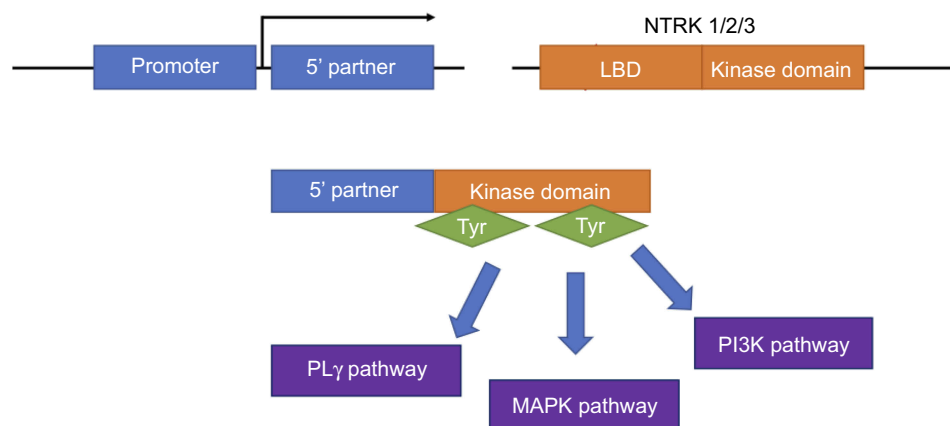


Figure 1 NTRK gene fusions.

Abbreviations: LBD, ligand binding domain; Tyr, tyrosine.

cancer and involved *LMNA* as a partner gene.²³ In a single-institution retrospective study in heavily pretreated colorectal cancer patients, *NTRK* fusion was detected in 2.5% of cases.²⁴ Pietrantonio et al found a nearly doubled incidence (4%, n=13) of *NTRK* fusions in a cohort of 346 colorectal cancer patients. Of note, ten of 13 patients with *NTRK* fusion (76.9%) also had high microsatellite instability.²⁵

Papillary thyroid cancer

Two years after the identification of *NTRK* fusions in colorectal cancer, *NTRK* rearrangements were detected in four patients with papillary thyroid carcinoma (PTC).²⁶ Subsequent studies revealed that *NTRK* rearrangements in PTC commonly involve the tyrosine-kinase domain of *NTRK1* and the 5-terminal of three different partner genes (*TRKT1*, *TRKT2*, and *TRKT3*). In all three fusion variants, the chimeric protein has cytoplasmic localization and shows constitutive phosphorylation of the kinase domain.²⁷

The current estimated incidence of *NTRK1* fusion in PTC is <12%.⁴ However, the prevalence of these rearrangements varies broadly across different studies, ranging from ≥15% in the Italian population to <10% in the Japanese, Chinese, and French.^{28–31} Importantly, *ETV6-NTRK3* is a common chromosomal rearrangement in radiation-associated thyroid cancer, as was identified in 14.5% (nine of 62) of subjects exposed to radiation after the Chernobyl disaster.³² In addition, *NTRK* fusion oncogenes have recently been detected in 26% (seven of 27) of a small cohort of pediatric patients with PTC.³³

Miscellaneous tumors

NTRK rearrangements have been reported in 92%–100% of secretory breast cancer and mammary analogue secretory carcinoma of the salivary gland, showing specific clinical and pathological correlates. Regardless of site of origin, these alterations arise from the same chromosomal rearrangement t(12;15)(p12;q26.1) that results in *ETV6-NTRK3*–fusion.^{34–36} *NTRK* rearrangements have increasingly been reported also in brain tumors. Frattini et al identified two in-frame fusions encompassing the *NTRK1* gene (*BCAN-NTRK1*–and *NFASC-NTRK1*) among 185 glioblastoma samples.³⁷ More recently, *NTRK1* rearrangements were described in 3% (three of 115) of glioblastomas using anchored multiplex PCR. The development and diffusion of highly sensitive and specific techniques, such as targeted NGS for routine clinical testing, has led to the

identification of *NTRK* fusions in a wide spectrum of rare tumors, including gastrointestinal stromal tumor, infantile fibrosarcoma, and other types of soft-tissue cancer, with prevalence ranging from 1% of adult-type sarcoma to 92% of congenital fibrosarcoma.^{8,38}

NTRK-detection methods

To date, no clinical or pathological features have been associated with *NTRK* alterations, apart from reported mutual exclusivity with other driver alterations, such as *EGFR* mutations or *aALK* in non-small-cell lung cancer.¹⁴ Therefore, there is no clear indication of which patients should be tested for *NTRK* fusion, and *NTRK* fusion should be considered in a wide patient population.³⁹

In spite of the recent approval of larotrectinib and the status of breakthrough therapy designation granted to entrectinib by the US Food and Drug Administration, no companion diagnostic test has been determined so far. The design of trials involving larotrectinib and other TRK inhibitors has allowed the use of either NGS or FISH, according to the procedures of each designated laboratory. As such, different methods can potentially be used, although NGS has been employed more often than others.^{38,40} The main advantage of NGS lies in its ability to test multiple genes simultaneously with a limited amount of tissue. This feature is extremely valuable in tumors where *NTRK* alterations are rare and where other potentially actionable molecular targets might be present, as in the case of non-small-cell lung cancer. However, not all NGS platforms are designed to detect *NTRK* fusions, representing a potential pitfall. Furthermore, it has been observed that DNA-based NGS assays might occasionally be unable to detect some fusions involving *NTRK2* or *NTRK3*, due to the presence of large intronic regions; therefore, the use of RNA-based fusion assays in substitution or as complements to DNA-based strategies has been proposed.^{37,40–43}

Compared to NGS, other common techniques, such as FISH and reverse-transcription (RT) PCR have a shorter turnaround time and are less expensive. However, neither of these allows for wide parallel detection of multiple genomic alterations. In particular, FISH would imply the need for multiple runs to determine the presence of fusions in all the three *NTRK* genes.⁴⁴ On the other hand, RT-PCR is designed to identify only known rearrangements, and is hence unable to detect novel fusions.⁴⁵ These characteristics make such strategies as FISH or RT-PCR viable alternatives to NGS for tumors with a high frequency of *NTRK* rearrangements involving known fusion genes (especially

infantile tumors, such as infantile fibrosarcomas or mesoblastic nephromas), while NGS should be employed in tumors with low prevalence of *NTRK* fusion or when other potential drivers can be involved.⁴⁶

Immunohistochemistry (IHC) is potentially able to detect TRK protein overexpression, which might represent an indirect proof of functional *NTRK* rearrangements. Notably, two different case series employing IHC with a pan-TRK antibody in different solid tumors showed excellent concordance with *NTRK* fusions, with high sensitivity (95%–97%) and specificity (97%–100%).^{47,48} More recently, Gatalica et al screened 11,502 tumor samples for 53 gene fusions and sequencing of 592 genes, with simultaneous IHC study of TrkA/B/C. The authors identified 31 cases (0.27% of the entire cohort) with *NTRK* fusion. Strong and uniform Trk expression was detected with pan-Trk IHC in seven of eight *NTRK1* fusion cases and eight of nine *NTRK2* fusion cases, while *NTRK3* fusion cases were positive in only six of eleven (55%) cases, with overall sensitivity of 75%.⁴⁹ In another study conducted by Feng et al, 12 of 164 (7%) tumors for which the Trk IHC-specific staining was more than zero tumor

cells demonstrated the presence of *NTRK* fusion by ISH, while ten of 88 (11%) cases for which IHC-specific staining was >25% of tumor cells demonstrated presence of fusion on ISH, suggesting lower sensitivity for IHC compared to the the aforementioned studies.⁵⁰

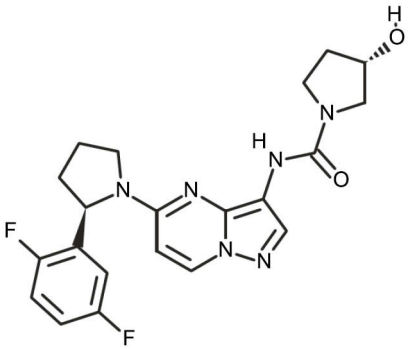
In light of these data, IHC has been proposed as a potential screening tool for *NTRK* fusions, although further validation and confirmatory molecular assessment of positive cases are advised. Finally, liquid biopsy is acquiring increasing relevance in cancer diagnostics, and *NTRK* rearrangements might potentially be assessed through circulating free DNA in peripheral blood.⁵¹

Safety and efficacy of larotrectinib in tumors harboring *NTRK* gene fusions

Pharmacodynamic

Larotrectinib (ARRY470, LOXO101, Vitrakvi) is a highly selective and potent inhibitor of TRKA, TRKB and TRKC. It blocks the ATP-binding site of TRK-family receptors with an in vitro 50% inhibitory constant of

Table 1 Larotrectinib summary

Chemical structure	
Molecular formula	C ₂₁ H ₂₂ F ₂ N ₆ O ₂
IUPAC name	(3-{(S)-[N]-[5-[(2-{R)-2-(2,5-difluorophenyl)pyrrolidin-1-yl]pyrazolo[1,5-a]pyrimidin-3-yl]-3-hydroxypyrrolidine-1-carboxamide
Molecular weight	428.444 g/mol
Pharmacodynamic	Highly selective and potent inhibitor of TRKA, TRKB, and TRKC
Mean absolute bioavailability (capsules)	34%
Maximum concentration	788 ng/mL
AUC (0–24 hours)	4,351 ng/h/mL
Mean volume of distribution V_{ss}	48 L
Mean clearance (Cl/F)	98 L/h
Half-life	0.5–2 hours
Excretion	58% fecal 39% (20% unchanged) renal

Abbreviations: IUPAC, international union of pure and applied chemistry; NSCLC, non-small-cell lung cancer; GIST, gastrointestinal stromal tumor.

5–11 nmol/L (Table 1).^{8,52} When evaluated on a panel of 226 non-TRKs, larotrectinib showed minimal or no activity, including no relevant hERG inhibition.^{8,52} In vitro assays of TRK-expressing tumors showed that larotrectinib inhibition of TRKs induce cellular apoptosis and G₁ cell-cycle arrest.⁵² In vivo experiments on athymic nude mice treated with larotrectinib confirmed a dose-dependent tumor inhibition.⁵²

Pharmacokinetics

Larotrectinib is quickly absorbed and reaches peak plasma concentration 0.5–2 hours after oral administration. In both children and adults, the mean half-life of larotrectinib is 1.5–2 hours.⁴⁴ Larotrectinib shows a linear pharmacokinetic profile across different dosing schedules, with no accumulation after repeated dosing. Food-intake restrictions were not required in clinical trials, and larotrectinib administration was allowed via nasogastric and gastrostomy tubes in patients who were unable to take the drug orally. In healthy subjects, the AUC of orally administered larotrectinib solution was similar to that of the capsules and maximum concentration was 36% greater with the oral solution. Although the AUC of larotrectinib was similar, maximum concentration was reduced by 35% after oral administration of a single 100 mg capsule of larotrectinib with a high-fat meal. Larotrectinib is primarily metabolized by CYP3A4 isoenzymes and eliminated by biliary and renal excretion.⁴⁴ Detailed pharmacokinetic parameters are reported in Table 1.

Clinical efficacy and safety of larotrectinib in solid tumors

Efficacy and safety data of larotrectinib in patients harboring *NTRK*-rearranged tumors derive from a developmental program that includes three clinical trials: a phase I trial in adults (NCT02122913), a phase I/II trial in children (SCOUT, NCT02637687), and a phase II basket trial in adults and adolescents (NCT02576432).

The SCOUT trial (NCT02637687) is a three-arm, multicenter, phase I/II study in patients aged 1 months to 21 years with primary central nervous system tumors or locally advanced/metastatic solid tumors that have relapsed and progressed and for which no standard treatments exist. A protocol amendment also allows patients with locally advanced infantile fibrosarcoma who would require mutilating surgery to achieve complete resection of the tumor. *NTRK* fusion status was not mandatory for

enrollment (except for patients who were between 1 months and 1 years of age); however, the study was enriched with TRK-translocated tumors, due to investigators' choice of testing for *NTRK* fusions at local institutions. The phase I dose-escalation portion of the SCOUT trial has been published, while the phase I follow-up and phase II part are ongoing. In the phase I dose-escalation part, the maximum tolerated dose was not reached and a dose of 100 mg/m² twice daily (maximum 100 mg per dose) was recommended for the phase II portion of the study. Fifteen patients with known *NTRK* fusions were evaluable for efficacy, with 14 (93%CI 68–100) achieving an objective response: two a complete response (CR) and 12 a partial response (PR) according to the independent radiology review and RECIST version 1.1. All patients without documented *NTRK* translocation experienced disease progression as best response. Two patients with known *NTRK* fusions developed disease progression while on the study.⁴⁴

Overall, five pediatric patients with locally advanced *NTRK*-translocated sarcomas (three with fibrosarcoma, two with other sarcomas) were treated with neoadjuvant larotrectinib.^{44,51} All five patients achieved a PR and proceeded to surgical resection. Surgical resection was R0 in three patients, R1 in one, and R2 in one. Among patients with R0 resection, complete pathological response was achieved in two cases and a near-to-complete response in one case. These patients were started on follow-up, and were disease free at 7–15 months after surgery. The two patients with R1 and R2 residual disease after surgical excision were resumed on larotrectinib, obtaining excellent disease control after seven to 20 cycles. No post-operative complications were associated with larotrectinib in the adjuvant setting.^{44,53}

An integrated safety and efficacy analysis of the first 55 consecutive patients enrolled in the larotrectinib development-program trials was recently published. This report included children from the phase I portion of the SCOUT trial (NCT02637687), as well as adult and adolescent patients from the dose-escalation phase 1 (NCT02122913) and phase 2 NAVIGATE (NCT02576432) trials. The primary end point was best overall response assessed by an independent radiology review committee according to RECIST criteria version 1.1. Secondary end points included the overall response rate according to the investigator's assessment, duration of response, progression-free survival, and safety. Analyses were performed according to the intention-to-treat principle. The maximum tolerated dose of

larotrectinib was not reached in any of the trials in either the pediatric or adult population. A dose of 100 mg twice daily was selected for adults and children who had a body-surface area of at least 1 m². As previously mentioned, the SCOUT trial defined a twice-daily dose of 100 mg/m² selected for children who had a body-surface area of <1 m².³⁸ The study population included patients with age ranging from 4 months to 76 years and a heterogeneous number of cancer diagnoses, including mammary analogue secretory carcinoma of the salivary gland, infantile fibrosarcoma and other soft-tissue sarcoma, thyroid tumors, lung tumors, colon tumors, melanomas, gastrointestinal stromal tumors, and primary central nervous system tumors. Only patients with known *NTRK*-translocation status were included in the pooled analysis. At the primary data cutoff, the overall response rate was 75% (95% CI 61%–85%), seven patients (13%) had CR, 34 (62%) had PR, 13% had stable disease, five (9%) had progression, and two were not evaluable for response, due to clinical deterioration. Median time to response was 1.8 (0.9–6.4) months, and after a median follow-up of 8.3 months, the median duration of response had not been reached. At 1 year, 71% of patients had ongoing response and 55% were progression-free. Median progression-free survival was not reached after a median follow-up duration of 9.9 months.³⁸ The first patient with an *NTRK* fusion tumor enrolled in the clinical trial was still on treatment after 27 months.^{38,50} In a recent update of this cohort, including an additional 35 *NTRK*-rearranged patients, larotrectinib confirmed remarkable activity in *NTRK*-positive tumors. Six patients with PR deepened to CR, and after almost 13 months of median follow-up, median duration of response and progression-free survival had not been reached. Among the 35 newevaluable patients, the overall response rate by investigator assessment was 74%.⁵⁴

Within the first 55 patients, the majority of adverse events (93%) were grade 1 or 2. Treatment-related adverse events of grade 3 occurred in <5% of patients and included increased AST or ALT, nausea, dizziness, anemia and decreased neutrophil count. No treatment-associated grade 4 or 5 toxicity was reported. Larotrectinib dose reduction was necessary in eight patients (15%) due to grade 2 or 3 events (increase in AST or ALT [n=4], dizziness [n=2], and decrease in absolute neutrophil count [n=2]), and in all cases response to treatment was maintained at lower doses. None of the patients who responded to larotrectinib discontinued the study drug due to the development of AEs.³⁸ An extension of the safety-data analysis on all patients treated with

larotrectinib across the trials, independently of *NTRK* fusion status, confirmed the tolerability profile of the drug, but reported warnings and precautions for potential development of neurotoxicity, hepatotoxicity, and embryo–fetal toxicity.⁵⁵ Neurological adverse events of any grade occurred in 53% of patients, including grade 3 and grade 4 neurological adverse events in 6% and 0.6% (one single case of encephalopathy) of patients, respectively. Hepatotoxicity of any grade occurred in 45% of patients, including grade 3 increased AST or ALT in 6% of patients and one patient with grade 4 increased ALT. Embryo–fetal toxicity concern derives from literature reports on human subjects with congenital mutations leading to changes in TRK signaling and findings from animal studies.⁵⁴

More recently, in a phase I dose-escalation study in patients with advanced solid tumors, eight of 70 patients enrolled had documented *NTRK* gene fusion. Among these, responses were observed in seven patients harboring *NTRK* gene fusions and one patient with *NTRK1* gene amplification. After independent and central radiology review, all patients with *NTRK* gene fusions were confirmed to have had an objective response (including two CRs and six PRs). Of note, none of the patients with *NTRK* point mutations experienced an objective response. Most treatment-related adverse events were grade 1 or 2, while 19% of patients (13 of 70) had grade 3 adverse events, which was anemia in 6% of cases. None of the patients enrolled in this trial had a grade 4 or 5 treatment-related adverse event.⁵⁵

Resistance mechanisms to larotrectinib

Oncogene-addicted tumors amenable to targeted therapies invariably develop acquired resistance to TKIs, which occur often by secondary mutation affecting the drug-binding site or by the activation of bypass tracks. Consistently with this assumption, acquired resistance to TKIs has also been reported in patients with fusion-driven cancers, including *NTRK*-positive patients who progressed on or following larotrectinib in phase I/II studies (Table 2). Among six patients with progressive disease as their best response to larotrectinib, one had received a TRK inhibitor prior to trial enrollment and was found to harbor the *NTRK3*^{G263R} mutation, known to interfere with larotrectinib binding to the receptor. For three of the five remaining patients, IHC on tumor material showed lack of expression of TRK fusion, which raised concerns of false-positive

Table 2 Secondary NTRK mutations in patient with acquired resistance to larotrectinib

NTRK rearrangement	NTRK mutation	Mutation detail	Cancer type
TPR-NTRK1	p.G595R	Solvent-front mutations	NSCLC
TPM3-NTRK1	p.G667S	xDFG mutations	
	p.G595R	Solvent-front mutations	Colorectal cancer
	p.F589L	Gatekeeper mutations	
LMNA-NTRK1	p.G595R	Solvent-front mutations	Colorectal cancer
LMNA-NTRK1	p.F589L+	Gatekeeper mutations	Cholangiocarcinoma
	GNAS p.Q227H		
CTRC-NTRK1	p.A608D	Solvent-front mutations	Pancreas
IRF2BP2-NTRK1	p.G595R	Solvent-front mutations	Thyroid
ETV6-NTRK3	Not tested	Not tested	Salivary gland
TPM3-NTRK1	p.G595R	Solvent-front mutations	Sarcoma
ETV6-NTRK3	p.G623R	Solvent-front mutations	Sarcoma
ETV6-NTRK3	p.G623R	Solvent-front mutations	GIST
	p.G696A	xDFG mutations	

Note: Data from Drilon et al.³⁸

Abbreviations: NSCLC, non-small-cell lung cancer; GIST, gastrointestinal stromal tumor.

tumor testing at a local institution or that the identified translocation was not expressed at protein level. In the same cohort, ten patients developed progression after an initially documented objective response or stable disease for at least 6 months. Importantly, *NTRK*-resistant secondary mutations were identified in all nine patients who underwent tumor sampling or plasma sampling after progression, and included *NTRK1*^{G595R}, *NTRK3*^{G623R}, *NTRK1*^{F589L}, *NTRK1*^{G667S}, and *NTRK3*^{G696A}.³⁸ Although data from structural modeling analyses of these mutants have indicated that the resultant amino-acid substitutions prevent the binding of larotrectinib to the kinase because of steric hindrance,^{38,56} in vitro kinase assays have shown that G595R-mutant TRKA has increased ATP affinity compared with that of the normal protein, suggesting that other factors are involved in determining the resistant phenotype.⁵⁷ Of note, a novel highly selective second-generation pan-TRK inhibitor (LOXO195) has been developed to overcome G595R-mediated resistance to TRK inhibitors, and is currently being investigated in a multi-center, open-label phase I/II clinical trial (NCT03215511).

Conclusion

The development of highly sensitive deepsequencing methods is now unveiling a new landscape of gene fusions across different tumor types. *NTRK* rearrangements define a unique subset of patients with advanced solid cancer, and have recently been established as clinically targetable genomic alterations. Phase I/II studies have shown that larotrectinib is safe and effective in patients with *NTRK*

fusions, regardless of age, cancer type, and fusion partner. The availability of promising targeted treatment calls for the integration of *NTRK* status into the diagnostic workflow for all tumor types, including those in which *NTRK* fusions have not yet been described. Recent data indicate that the annual incidence of *NTRK*-rearranged cancers is approximately 2,500–3,000 in the US, which implies that there is a subset of patients that might benefit from a targeted approach, regardless of histology.^{39,49} In addition, novel agents designed to overcome resistance to larotrectinib are under clinical investigation, and are expected further to improve outcomes of patients with *NTRK*-rearranged solid tumors.

Disclosure

CG reports personal fees from AstraZeneca, BMS, Boehringer Ingelheim, MSD, and Roche outside the submitted work. The authors report no other conflicts of interest in this work.

References

1. Takeuchi K, Soda M, Togashi Y, et al. RET, ROS1 and ALK fusions in lung cancer. *Nat Med*. 2012;18:378–381. doi:10.1038/nm.2658
2. Dupain C, Harttrampf AC, Urbinati G, Geoerger B, Massaad-Massade L. Relevance of fusion genes in pediatric cancers: toward precision medicine. *Mol Ther Nucleic Acids*. 2017;6:315–326. doi:10.1016/j.omtn.2017.01.005
3. Paratala BS, Chung JH, Williams CB, et al. RET rearrangements are actionable alterations in breast cancer. *Nat Commun*. 2018;9(1):4821. doi:10.1038/s41467-018-07341-4
4. Stransky N, Cerami E, Schalm S, Kim JL, Lengauer C. The landscape of kinase fusions in cancer. *Nat Commun*. 2014;5:4846. doi:10.1038/ncomms5972

5. Amatu A, Sartore-Bianchi A, Siena S. NTRK gene fusions as novel targets of cancer therapy across multiple tumour types. *ESMO Open*. 2016;1:e000023. doi:10.1136/esmoopen-2015-000023
6. Martin-Zanca D, Hughes SH, Barbacid M. A human oncogene formed by the fusion of truncated tropomyosin and protein tyrosine kinase sequences. *Nature*. 1986;319:743–748. doi:10.1038/319743a0
7. Reichardt LF. Neurotrophin-regulated signalling pathways. *Philos Trans R Soc B*. 2006;361:1545–1564. doi:10.1098/rstb.2006.1894
8. Vaishnavi A, Le AT, Doebele RC. TRKking down an old oncogene in a new era of targeted therapy. *Cancer Discov*. 2015;5:25–34. doi:10.1158/2159-8290.CD-14-0765
9. Huang EJ, Reichardt LF. TRK receptors: roles in neuronal signal transduction. *Annu Rev Biochem*. 2003;72:609–642. doi:10.1146/annurev.biochem.72.121801.161629
10. Russell JP, Powell DJ, Cunnane M, et al. The TRK-T1 fusion protein induces neoplastic transformation of thyroid epithelium. *Oncogene*. 2000;19:5729–5735. doi:10.1038/sj.onc.1203922
11. Tognon C, Knezevich SR, Huntsman D, et al. Expression of the ETV6-NTRK3 gene fusion as a primary event in human secretory breast carcinoma. *Cancer Cell*. 2002;2:367–376. doi:10.1016/S1535-6108(02)00180-0
12. Tognon C, Garnett M, Kenward E, Kay R, Morrison K, Sorensen PH. The chimeric protein tyrosine kinase ETV6-NTRK3 requires both Ras-Erk1/2 and PI3-kinase-Akt signaling for fibroblast transformation. *Cancer Res*. 2001;61:8909–8916.
13. Edel MJ, Shvarts A, Medema JP, Bernards R. An in vivo functional genetic screen reveals a role for the TRK-T3 oncogene in tumor progression. *Oncogene*. 2004;23:4959–4965. doi:10.1038/sj.onc.1207444
14. Ricciuti B, Brambilla M, Metro G, et al. Targeting NTRK fusion in non-small cell lung cancer: rationale and clinical evidence. *Med Oncol*. 2017;34(6):105. doi:10.1007/s12032-017-0967-5
15. Ding L, Getz G, Wheeler DA, et al. Somatic mutations affect key pathways in lung adenocarcinoma. *Nature*. 2008;455:1069–1075. doi:10.1038/nature07270
16. Marchetti A, Felicioni L, Pelosi G, et al. Frequent mutations in the neurotrophic tyrosine receptor kinase gene family in large cell neuroendocrine carcinoma of the lung. *Hum Mutat*. 2008;29:609–616. doi:10.1002/humu.20707
17. Vaishnavi A, Capelletti M, Le AT, et al. Oncogenic and drug-sensitive NTRK1 rearrangements in lung cancer. *Nat Med*. 2013;19(11):1469–1472. doi:10.1038/nm.3352
18. Farago AF, Le LP, Zheng Z, et al. Durable clinical response to entrectinib in NTRK1-rearranged non-small cell lung cancer. *J Thorac Oncol*. 2015;10(12):1670–1674. doi:10.1097/01.JTO.0000473485.38553.f0
19. Zheng Z, Liebers M, Zhelyazkova B, et al. Anchored multiplex PCR for targeted next-generation sequencing. *Nat Med*. 2014;20(12):1479–1484. doi:10.1038/nm.3729
20. Ardini E, Bosotti R, Borgia AL, et al. The TPM3-NTRK1 rearrangement is a recurring event in colorectal carcinoma and is associated with tumor sensitivity to TRKA kinase inhibition. *Mol Oncol*. 2014;8(8):1495–1507. doi:10.1016/j.molonc.2014.06.001
21. Creancier L, Vandenberghe I, Gomes B, et al. Chromosomal rearrangements involving the NTRK1 gene in colorectal carcinoma. *Cancer Lett*. 2015;365(1):107–111. doi:10.1016/j.canlet.2015.05.013
22. Martin-Zanca D, Hughes SH, Barbacid M. A human oncogene formed by the fusion of truncated tropomyosin and protein tyrosine kinase sequences. *Nature*. 1986;319(6056):743–748. doi:10.1038/319743a0
23. Sartore-Bianchi A, Ardini E, Bosotti R, et al. Sensitivity to entrectinib associated with a novel LMNA-NTRK1 gene fusion in metastatic colorectal cancer. *J Natl Cancer Inst*. 2016;108:1. doi:10.1093/jnci/djv306
24. Sartore-Bianchi A, Amatu A, Bonazzina E, et al. Pooled analysis of clinical outcome of patients with chemorefractory metastatic colorectal cancer treated within phase I/II clinical studies based on individual biomarkers of susceptibility: a single-institution experience. *Target Oncol*. 2017;12(4):525–533. doi:10.1007/s11523-017-0505-6
25. Pietrantonio F, Di Nicolantonio F, Schrock AB, et al. ALK, ROS1, and NTRK rearrangements in metastatic colorectal cancer. *J Natl Cancer Inst*. 2017;109:12. doi:10.1093/jnci/djx007
26. Bongarzone I, Pierotti MA, Monzini N, et al. High frequency of activation of tyrosine kinase oncogenes in human papillary thyroid carcinoma. *Oncogene*. 1989;4:1457–1462.
27. Greco A, Miranda C, Pierotti MA. Rearrangements of NTRK1 gene in papillary thyroid carcinoma. *Mol Cell Endocrinol*. 2010;321:44–49. doi:10.1016/j.mce.2009.10.009
28. Bongarzone I, Vigneri P, Mariani L, et al. RET/NTRK1 rearrangements in thyroid gland tumors of the papillary carcinoma family: correlation with clinicopathological features. *Clin Cancer Res*. 1998;4:223–228.
29. Delvincourt C, Patey M, Flament JB, et al. Ret and trk proto-oncogene activation in thyroid papillary carcinomas in French patients from the Champagne-Ardenne region. *Clin Biochem*. 1996;29:267–271.
30. Wajjwalku W, Nakamura S, Hasegawa Y, et al. Low frequency of rearrangements of the ret and trk proto-oncogenes in Japanese thyroid papillary carcinomas. *Jpn J Cancer Res*. 1992;83:671–675.
31. Liu RT, Chou FF, Wang CH, et al. Low prevalence of RET rearrangements (RET/PTC1,RET/PTC2,RET/PTC3, and ELKS-RET) in sporadic papillary thyroid carcinomas in Taiwan Chinese. *Thyroid*. 2005;15:326–335. doi:10.1089/thy.2005.15.326
32. Leeman-Neill RJ, Kelly LM, Liu P, et al. ETV6-NTRK3 is a common chromosomal rearrangement in radiation-associated thyroid cancer. *Cancer*. 2014;120(6):799–807. doi:10.1002/cncr.28484
33. Prasad ML, Vyas M, Horne MJ, et al. NTRK fusion oncogenes in pediatric papillary thyroid carcinoma in northeast United States. *Cancer*. 2016;122(7):1097–1107. doi:10.1002/cncr.29887
34. Skalova A, Vanecek T, Sima R, et al. Mammary analogue secretory carcinoma of salivary glands, containing the ETV6-NTRK3 fusion gene: a hitherto undescribed salivary gland tumor entity. *Am J Surg Pathol*. 2010;34(5):599–608. doi:10.1097/PAS.0b013e3181d9efcc
35. Tognon C, Knezevich SR, Huntsman D, et al. Expression of the ETV6-NTRK3 gene fusion as a primary event in human secretory breast carcinoma. *Cancer Cell*. 2002;2(5):367–376.
36. Skalova A, Vanecek T, Majewska H, et al. Mammary analogue secretory carcinoma of salivary glands with high-grade transformation: report of 3 cases with the ETV6-NTRK3 gene fusion and analysis of TP53, beta-catenin, EGFR, and CCND1 genes. *Am J Surg Pathol*. 2014;38(1):23–33. doi:10.1097/PAS.0000000000000088
37. Zheng Z, Liebers M, Zhelyazkova B, et al. Anchored multiplex PCR for targeted next-generation sequencing. *Nat Med*. 2014;20:1479–1484. doi:10.1038/nm.3729
38. Drilon A, Laetsch TW, Kummar S, et al. Efficacy of larotrectinib in TRK fusion-positive cancers in adults and children. *N Eng J Med*. 2018;378(8):731–739. doi:10.1056/NEJMoa1714448
39. Farago AF, Taylor MS, Doebele RC, et al. Clinicopathologic features of non-small-cell lung cancer harboring an NTRK gene fusion. *JCO Precis Oncol*. Epub 2018 Jul 23.
40. Drilon A, Siena S, Ou SI, et al. Safety and antitumor activity of the multitargeted pan-TRK, ROS1, and ALK inhibitor entrectinib: combined results from two phase I trials (ALKA-372-001 and STARTRK-1). *Cancer Discov*. 2017;7(4):400–409. doi:10.1158/2159-8290.CD-16-1237
41. Abel HJ, Al-Kateb H, Cottrell CE, et al. Detection of gene rearrangements in targeted clinical next-generation sequencing. *J Mol Diagn*. 2014;16(4):405–417. doi:10.1016/j.jmoldx.2014.03.006
42. Abel HJ, Duncavage EJ. Detection of structural DNA variation from next generation sequencing data: a review of informatic approaches. *Cancer Genet*. 2013;206(12):432–440. doi:10.1016/j.cancergen.2013.11.002

43. Benayed R, Offin MD, Mullaney KA, et al. Comprehensive detection of targetable fusions in lung adenocarcinomas by complementary targeted DNaseq and RNAseq assays. *J Clin Oncol*. 2018;36(15_suppl.):12076. doi:10.1200/JCO.2018.36.15_suppl.12076
44. Laetsch TW, DuBois SG, Mascarenhas L, et al. Larotrectinib for paediatric solid tumours harbouring NTRK gene fusions: phase 1 results from a multicentre, open-label, phase 1/2 study. *Lancet Oncol*. 2018;19(5):705–714. doi:10.1016/S1470-2045(18)30119-0
45. Bourgeois JM, Knezevich SR, Mathers JA, Sorensen PH. Molecular detection of the ETV6-NTRK3 gene fusion differentiates congenital fibrosarcoma from other childhood spindle cell tumors. *Am J Surg Pathol*. 2000;24(7):937–946.
46. Cocco E, Scaltriti M, Drilon A. NTRK fusion-positive cancers and TRK inhibitor therapy. *Nat Rev Clin Oncol*. 2018;15(12):731–747. doi:10.1038/s41571-018-0113-0
47. Rudzinski ER, Lockwood CM, Stohr BA, et al. Pan-Trk immunohistochemistry identifies NTRK rearrangements in pediatric mesenchymal tumors. *Am J Surg Pathol*. 2018;42(7):927–935. doi:10.1097/PAS.0000000000001062
48. Hechtman JF, Benayed R, Hyman DM, et al. Pan-Trk immunohistochemistry is an efficient and reliable screen for the detection of NTRK fusions. *Am J Surg Pathol*. 2017;41(11):1547–1551. doi:10.1097/PAS.0000000000000911
49. Gatalica Z, Xiu J, Swensen J, et al. Molecular characterization of cancers with NTRK gene fusions. *Mod Pathol*. 2019;32(1):147–153. doi:10.1038/s41379-018-0118-3
50. Feng J, Ebata K, Hansen F, et al. TRK wild-type and fusion protein expression in solid tumors: characterization by immunohistochemistry and in situ hybridization. *Ann Oncol*. 2018;29(Suppl8_80P). doi:10.1093/annonc/mdx807
51. Hofman P. Liquid biopsy and therapeutic targets: present and future issues in thoracic oncology. *Cancers (Basel)*. 2017;9(11). doi:10.3390/cancers9110154
52. Doebele RC, Davis LE, Vaishnavi A, et al. An oncogenic NTRK fusion in a patient with soft-tissue sarcoma with response to the tropomyosin-related kinase inhibitor LOXO-101. *Cancer Discov*. 2015;5(10):1049–1057. doi:10.1158/2159-8290.CD-15-0443
53. DuBois SG, Laetsch TW, Federman N, et al. The use of neoadjuvant larotrectinib in the management of children with locally advanced TRK fusion sarcomas. *Cancer*. 2018;124(21):4241–4247. doi:10.1002/cncr.31701
54. Lassen UN, Albert CM, Kummar S, et al. Larotrectinib efficacy and safety in TRK fusion cancer: an expanded clinical dataset showing consistency in an age and tumor agnostic approach. *Ann Oncol*. 2018;29(Suppl 8):133–148. doi:10.1093/annonc/mdx807
55. Hong DS, Bauer TM, Lee JJ, et al. Larotrectinib in adult patients with solid tumours: a multi-centre, open-label, phase I dose-escalation study. *Ann Oncol*. 2019;30(2):325–331. doi:10.1093/annonc/mdy539
56. Russo M, Misale S, Wei G, et al. Acquired resistance to the TRK inhibitor entrectinib in colorectal cancer. *Cancer Discov*. 2016;6:36–44. doi:10.1158/2159-8290.CD-15-0940
57. Drilon A, Nagasubramanian R, Blake JF, et al. A next-generation TRK kinase inhibitor overcomes acquired resistance to prior TRK kinase inhibition in patients with TRK fusion-positive solid tumors. *Cancer Discov*. 2017;7:963–972. doi:10.1158/2159-8290.CD-17-0507

OncoTargets and Therapy

Dovepress

Publish your work in this journal

OncoTargets and Therapy is an international, peer-reviewed, open access journal focusing on the pathological basis of all cancers, potential targets for therapy and treatment protocols employed to improve the management of cancer patients. The journal also focuses on the impact of management programs and new therapeutic

agents and protocols on patient perspectives such as quality of life, adherence and satisfaction. The manuscript management system is completely online and includes a very quick and fair peer-review system, which is all easy to use. Visit <http://www.dovepress.com/testimonials.php> to read real quotes from published authors.

Submit your manuscript here: <https://www.dovepress.com/oncotargets-and-therapy-journal>