

Surprises in the urinary bladder

Bhushan Wani¹
Suhas Jajoo¹
Navinchandra Wani²
Anil Bhole¹

¹Department of Surgery, Jawaharlal Nehru Medical College, Sawangi (Meghe), Wardha, India; ²Department of Surgery, Annasaheb Chudaman Patil Memorial Medical College, Dhule, India

Abstract: Foreign bodies of the urinary bladder may occur by self insertion, iatrogenic means or migration from the neighbouring organs. The variety of objects found self-inserted is impressive. The patient usually presents with dysuria, poor urinary stream or retention, bloody or purulent urethral discharge, ascending urinary tract infection, urgency, and/or pelvic pain. Management should be tailored according to the nature and dimensions of the foreign body. In the following paper, we report three cases with different presentations that were managed successfully.

Keywords: urinary, bladder, foreign bodies

Introduction

All manner of foreign bodies have been extracted from the bladder. Introduction into the bladder may be through self-insertion, iatrogenic means or migration from adjacent organs; thus extraction should be tailored according to the nature of the foreign body and should minimize bladder and urethral trauma.^{1,2} The possibility of an intravesical foreign body should be considered in any patient presenting with chronic, unexplained lower urinary tract symptoms.

Case 1

A 23-year-old female came with complaints of pain in suprapubic region with increased frequency. An abdominal X-ray showed a 4 × 3 cm calculus having two pointed ends in the pelvis. Suprapubic cystostolithotomy was done and the calculus was found to be encapsulating a pen casing (Figure 1). On obtaining a detailed history, the patient self-reported using the pen casing as a means of masturbation and that it had been retained in her for the past 10 years. It was the only time she had self-inflicted a foreign body in her urethra. She had no history of psychiatric illness or drug addiction.

Case 2

A 70-year-old man presented with burning during micturition and increased frequency. His history revealed that he had a broken rubber catheter inside his bladder which had been introduced by an untrained professional for draining his acute retention 6 hours before. Ultrasonography of the patient's abdomen showed the catheter tube inside the bladder with evidence of mucosal wall trabeculations and cystitis. Cystoscopic removal was attempted, but failed. The broken piece was removed via suprapubic cystostomy, (Figure 2) which also helped in draining the turbid urine and controlling cystitis. The cut end of the catheter had evidence of sticking plaster suggesting that a

Correspondence: Bhushan N Wani
Department of Surgery, Jawaharlal
Nehru Medical College, Sawangi (Meghe),
Wardha 442004, Maharashtra, India
Tel +091 9422757336
Email drbnwani@gmail.com

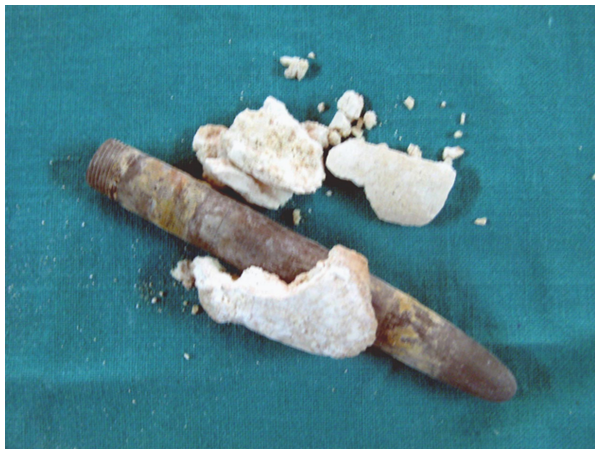

Figure 1 Case 1: Broken oxalate calculus which was encapsulating pen casing.

broken catheter was first fixed with sticking and then used to drain the patient's bladder.

Case 3

A 53-year-old male presented with the inability to void, hematuria, turbid urethral discharge, and a knot of Ryle's tube protruding from his urethra (Figure 3). The patient had a surprising history of retention of urine for which a nonmedical professional had introduced a Ryle's tube instead of a catheter for drainage of a full bladder. A whole Ryle's tube had




Figure 2 Case 2: Broken proximal piece of rubber catheter (indicated by arrow) with distal part compared with normal rubber catheter.

been inserted in the bladder, which got coiled and stuck inside. Attempts for retrieval were subsequently made and the tube was removed half-way, leading to urethral tear. Moreover these attempts made the patient bleed per urethra. The patient came to our hospital after five days. An emergency cystostomy was performed and a coiled loop in the Ryle's tube, forming a knot inside the bladder, was found to be the cause of the retention of the tube. The knotted loop was removed and they cystostomy closed. The patient recovered well, passing good stream after two weeks of catheterization.

Discussion

Foreign bodies in the urinary bladder may occur by self-insertion, iatrogenic means or migration from the neighbouring organs. The most common reasons are for sexual pleasure (ie, eroticism, especially masturbation or sexual gratification), inquisitiveness (particularly in children), as a consequence of psychiatric or senile states, or due to being under the influence of alcohol, but hygienic behavior and attempts to relieve voiding problems have been also reported. The major route for ingress of foreign bodies is via the urethra.³ The variety of objects found self-inserted is impressive and include: sharp objects (eg, needles, lead pencils, copper wire, paper clips, pen-casings); tubes (eg, pieces of Foley catheter, cable, rubber tube, Teflon® beak of resectoscope sheath); soft objects (eg, cotton swabs, tampons, carrot, surgical gauze); parts of animals (eg, bones); plants and vegetables (eg, hay, cucumber); fluids (eg, glue); powders (eg, cocaine); and others (eg, intrauterine devices).^{4,5}

The patient usually presents with dysuria, poor urinary stream or retention, bloody or purulent urethral discharge, ascending urinary tract infection, urgency, and/or pelvic pain.^{1,6} Foreign bodies, when left for a long time, act as a nidus for calculus formation. A few of the known complications are bladder perforation, abscess, and fistula formation. Chronic irritation leading to squamous cell carcinoma of the bladder has also been described.⁷ Finally, intravesical foreign body-induced bladder calculi resulting in obstructive renal failure has been reported in the literature.⁸

Management is aimed at providing complete removal of the foreign body, which should be tailored according to its nature and dimensions, with minimal trauma to the bladder and urethra. Most foreign bodies can be removed transurethrally with cystoscopic grasping forceps. Modifications of conventional instruments have been described to tackle difficult situations.⁹ Open suprapubic

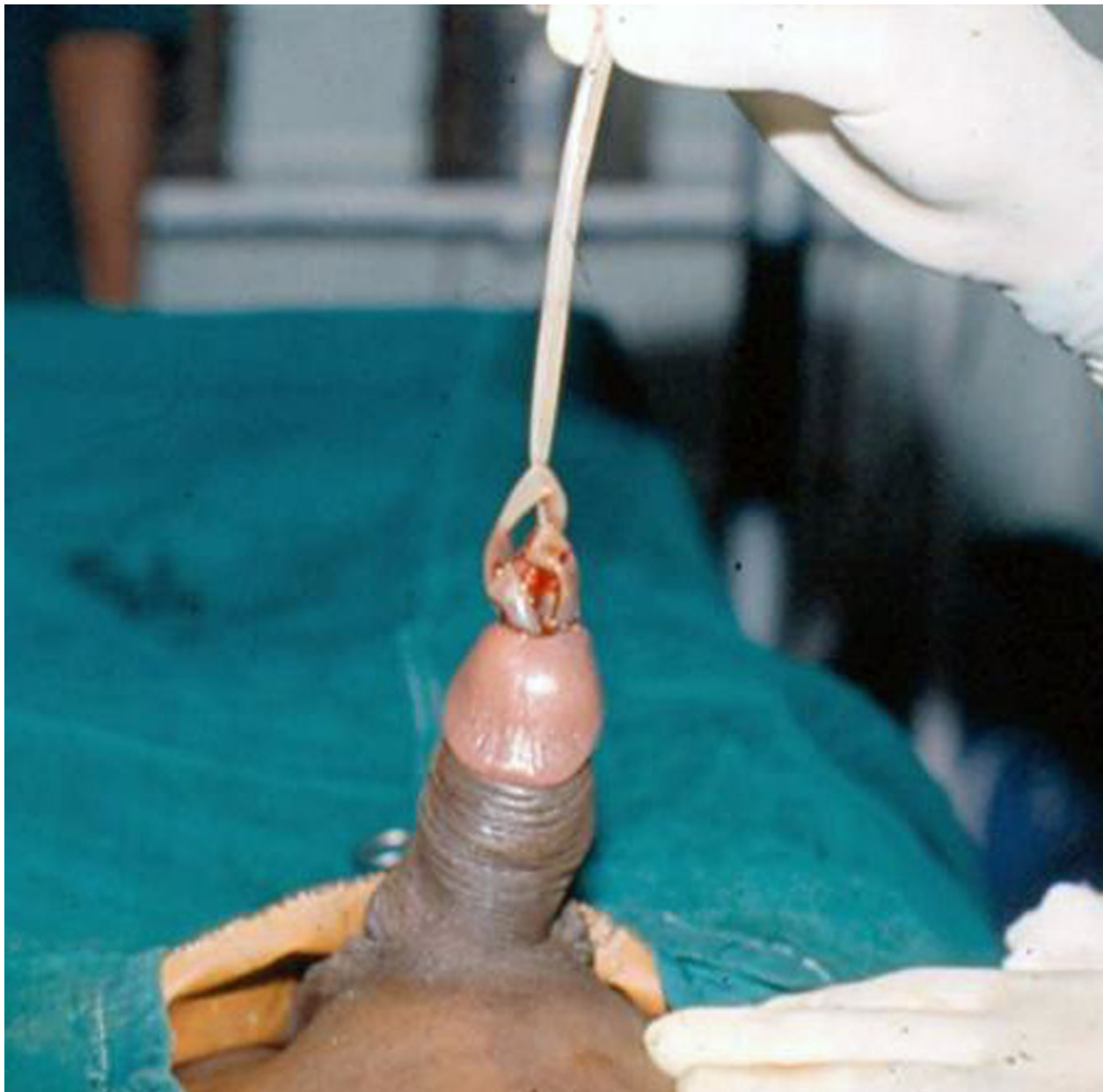

Figure 3 Case 3: Knotted Ryle's tube protruding from penis, with bleeding.

cystostomy is sometimes required for large, impacted foreign body removal. After removal, psychiatric referral is recommended to prevent a repeat of the episode, if the object was self-introduced.⁵

Conclusion

Foreign bodies in the urinary bladder represent a urological challenge that requires prompt management. The suspected history and presenting symptoms are crucial and may lead to further investigations. Intravesical foreign bodies should be included in the differential diagnosis of patients with chronic

lower urinary tract problems. Radiological evaluation is necessary to determine the exact size, number, and nature of the object(s). The most suitable method for removal of intravesical foreign bodies depends on the nature of the foreign body, age of the patient, the available expertise, and equipment. The variety of these objects can be impressive and removal of the foreign body may be quite challenging, requiring imagination and high-level surgical skills.

Disclosures

The authors report no conflicts of interest in this work.

References

1. Rafique M. Intravesical foreign bodies: review and current management strategies. *Urol J*. 2008;5:223–231.
2. Eckford SD, Persad RA, Brewster SF, Gingell JC. Intravesical foreign bodies: five-year review. *Br J Urol*. 1992;69:41–45.
3. Kochakarn W, Pummanagura W. Foreign bodies in the female urinary bladder: 20-year experience in Ramathibodi Hospital. *Asian J Surg*. 2008;31:130–133.
4. Van Ophoven A, De Kernion J. Clinical management of foreign bodies of the genitourinary tract. *J Urol*. 2000;164:274–287.
5. Kenney RD. Adolescent males who insert genitourinary foreign bodies: is psychiatric referral required? *Urology*. 1988;32:127.
6. Sharma UK, Rauniyar D, Shah WF. Intravesical foreign body: case report. *Kathmandu Univ Med J*. 2006;4:342–344.
7. Wyman A, Kinder RB. Squamous cell carcinoma of the bladder associated with intrapelvic foreign bodies. *Br J Urol*. 1988;61:460.
8. Kamal F, Clark AT, Lavallée LT, Roberts M, Watterson J. Intravesical foreign body-induced bladder calculi resulting in obstructive renal failure. *Can Urol Assoc J*. 2008;2:546–548.
9. Walmsley BH. Removal of foreign bodies from the female bladder. *Br J Urol*. 1987;59:196.

Open Access Surgery

Publish your work in this journal

Open Access Surgery is an international, peer-reviewed, open access journal that focuses on all aspects of surgical procedures and interventions. Patient care around the peri-operative period and patient outcomes post surgery are key topics. All grades of surgery from minor cosmetic interventions to major surgical procedures are covered. Novel techniques

Submit your manuscript here: <http://www.dovepress.com/open-access-surgery-journal>

Dovepress

and the utilization of new instruments and materials, including implants and prostheses that optimize outcomes constitute major areas of interest. The manuscript management system is completely online and includes a very quick and fair peer-review system. Visit <http://www.dovepress.com/testimonials.php> to read real quotes from published authors.