

Analysis of Risk Factors for Surgical Complications of Endoscopic Thyroidectomy via Total Areola Approach

Zhonglin Wang¹
Jian Yu²
Shangrui Rao²
Zhe Lin²
Zhongliang Pan²
Xian Shen¹

¹Department of General Surgery, The Second Affiliated Hospital of Wenzhou Medical University, Wenzhou, 325000, Zhejiang, People's Republic of China; ²Department of General Surgery, Wenzhou Central Hospital, Wenzhou, 325000, Zhejiang, People's Republic of China

Background: Increased surgical technology has led broad acceptance endoscopic thyroidectomy and its application in the treatment of thyroid diseases, including thyroid carcinoma. Although the incidence of complications and mortality of thyroid surgery has been significantly reduced, serious complications still occur from time to time. The purpose of this retrospective study is to identify the factors that influence the complications of endoscopic thyroidectomy.

Methods: This study was carried out between January 2012 and December 2019, where a total of 630 patients undergoing endoscopic thyroidectomy via the total areola approach were retrospectively evaluated to identify the key influencing factors of complications.

Results: The study established that the common complications included recurrent laryngeal nerve injury (3.33%), superior laryngeal nerve injury (2.54%), hypocalcemia (8.57%), and the incidence of complications was acceptable. Both univariate and multivariate analysis showed that thyroid carcinoma ($P = 0.041$), operation time lasting more than 150 minutes ($P = 0.034$) and operation before 2017 ($P = 0.001$) were risk factors of recurrent laryngeal nerve injury. We established that operation after 2017 ($P < 0.005$) was the only protective factor of superior laryngeal nerve injury. Thyroid carcinoma ($P=0.04$), operation mode ($P=0.001$), and surgery before 2017 ($P<0.001$) are risk factors for parathyroid injury. Among the clinical groups, operation before 2017 was an independent risk factor for all complications.

Conclusion: For thyroid specialists, after the early learning curve, with the continuous improvement of endoscopic operation technology, high-definition equipment and more sophisticated operation equipment can be used in clinical practice, which can prevent and reduce the occurrence of complications.

Keywords: thyroidectomy, endoscopy, surgical complications, influencing factors

Introduction

It is worth noting that thyroid surgery is usually used in patients with goiter accompanied by obstructive manifestations, failure of medical treatment for hyperthyroidism, and any clinically suspected malignant tumor.^{1,2} As such, with the increase of young female patients in thyroid tumors, patients not only care about the safety and thoroughness of surgical treatment but also care about the beauty effect. Therefore, thyroid surgeons should not only consider the good treatment effect but also consider the quality of life of patients. Since Huscher carried out the first endoscopic thyroidectomy in 1997, many surgeons have reported the experience of endoscopic thyroidectomy using various methods.³⁻⁶ Accumulated clinical

Correspondence: Xian Shen
Department of General Surgery, The Second Affiliated Hospital of Wenzhou Medical University, Wenzhou, 325000, Zhejiang, People's Republic of China
Tel/Fax +86-577-88002609
Email 1396888872@163.com



studies have confirmed that this technique has the same safety and similar clinical effects as open surgery. Essentially, today, endoscopic treatment of papillary thyroid microcarcinoma has been safely completed in a large number of medical institutions in China and South Korea.⁷ On the other hand, the potentially serious complications of endoscopic thyroidectomy cannot be ignored.

For any new technique, surgeons must minimize perioperative complications and assure patient safety.⁸ However, when endoscopic surgery is used, its vision and touch are different from the traditional open thyroidectomy. Due to the complexity of endoscopic thyroidectomy, the perioperative complication rate may increase during the initial learning period. Therefore, better knowledge with the surgical anatomy of the neck, skillful endoscopic techniques, and a strict grasp of the principles of thyroid nodule treatment and the scope of operation is essential to keep complications within reasonable limits.

In this study, we analyzed a variety of clinical factors to evaluate a series of risk factors related to perioperative complications of endoscopic thyroid surgery and proposed some methods to prevent surgical complications.

Methods

A retrospective review was performed using the records of 630 consecutive patients with thyroid tumors who underwent endoscopic thyroidectomy via a total areola approach between January 2012 and December 2019. The operation was performed by two highly qualified thyroid surgeons with systematic training and skilled endoscopic techniques. All patients were diagnosed by clinical examination, ultrasound, necessary fine-needle aspiration cytology (FNAC), and hematology examination. CT scan was performed for evaluating the volume of the thyroid lobe, tumor size, and lymph node metastasis. The Ethics Committee of Wenzhou Central Hospital approved this study, and all patients signed an informed consent. This study was conducted in accordance with the Declaration of Helsinki. The criteria for endoscopic thyroidectomy were as follows: (1) No history of neck surgery and neck radiation, (2) Benign thyroid disease with a diameter less than 5cm, (3) Well-differentiated thyroid carcinoma (less than 45 years old, tumor less than 2cm, and no evidence of local invasion or lymph node metastasis).

We analyzed the patient's demographic factors (age, gender, BMI) and clinical characteristics (operation mode, operation time, and length of hospital stay), Clinical group (Operation in 2012–2016 and Operation in 2017–2019

respectively), pathological characteristics (tumor size, extrathyroidal invasion, number of retrieved lymph nodes), complications (thyroid and flap correlation), etc. We defined transient hypocalcemia and transient superior laryngeal nerve and recurrent laryngeal nerve (RLN) palsy as the recovery of symptoms and normalization of laboratory data within six months after the operation.

Operative Procedure

Routine preparation consisted of general anesthesia and endotracheal intubation. The patient was placed in the supine position with the neck extended slightly. The whole endoscopic surgical procedure was described detailedly in the following. A 10-mm longitudinal incision was made at the interior edge of the right breast areolae; two other 5-mm incisions at the lateral edge of the breast areolae were made (Figure 1). Epinephrine diluted in 0.9%NaCl solution (1:500,000) was injected into the working area under the platysma in the neck and subcutaneously in the anterior chest. A 10-mm trocar and two 5-mm trocars were then punctured into the subcutaneous space. A 10-mm 30° laparoscope (Olympus, Tokyo, Japan) was then introduced through the 10-mm trocar. An ultrasound scalpel (Johnson & Johnson Medical, Cincinnati, OH) and an assistant clamp were then introduced through 5-mm trocar. There was room for manipulation of the thyroid cartilage superiorly to 4 cm below the suprasternal fossa inferiorly and laterally to just beyond the medial border of the sternocleidomastoid muscle

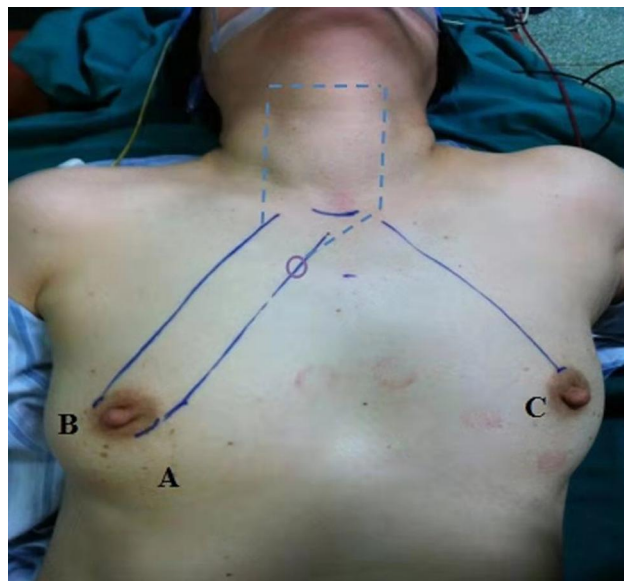


Figure 1 Incisions made around areolas: a one 10-mm incision for endoscopy, b one 5-mm incision for separating pliers and c one 5-mm incision for Harmonic scalpel.

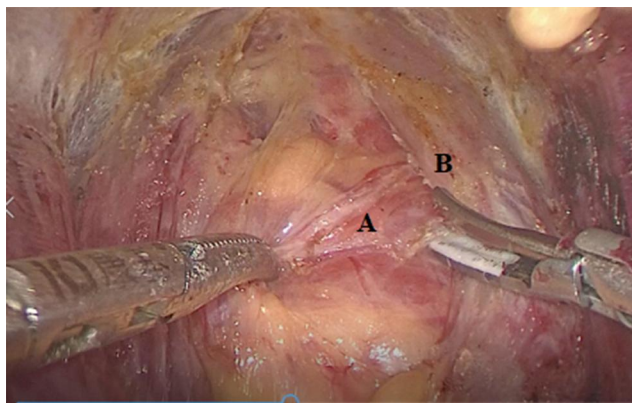


Figure 2 After the neck flap was free, and maintained using low-pressure CO₂ insufflation at 5–6 mmHg. Incision of the linea alba cervicalis and dissection of the thyroid were done using the harmonic scalpel. A: thyroid gland, B: Strap muscles.

under euthyphoria, which was established using the ultrasound scalpel and maintained using low-pressure CO₂ insufflation at 5–6 mmHg. Incision of the linea alba cervicalis and dissection of the thyroid were done using the harmonic scalpel (Figure 2). The middle thyroid vein and inferior thyroid vessels were identified and divided. After the isthmus was divided, the lower lobe of the thyroid gland was drawn upward and bluntly dissected. The parathyroid gland (PTG) was identified and carefully preserved, with an intact blood supply. The superior thyroid vessels were identified and dissected close to the thyroid gland to avoid injuring the superior laryngeal nerve. The recurrent laryngeal nerve (RLN) was traced and dissected with great care during the complete lobectomy procedure. The resected specimen was placed into a removal bag, extracted through the subcutaneous cavity of the 10-mm trocar to the skin incision and sent for frozen histological examination. Ipsilateral CND was made when PTMC was confirmed by the frozen histological examination after about a 30-min wait (Figure 3). The central LN was defined as nodes bordered superiorly by the hyoid bone, inferiorly by the innominate (brachiocephalic) artery, and laterally on each side by the carotid sheaths. The RLN was traced and dissected with great care during ipsilateral CND. This specimen was extracted with the same method and sent for postoperative pathological examination. After adequate irrigation, a single drain was placed in the cavity through the skin incision. Suture of the strap muscles and skin incision was closed with absorbable sutures.

Statistical Analysis

All statistical analyses were performed using SPSS software (version 21.0; SPSS, Chicago, IL). The differences between

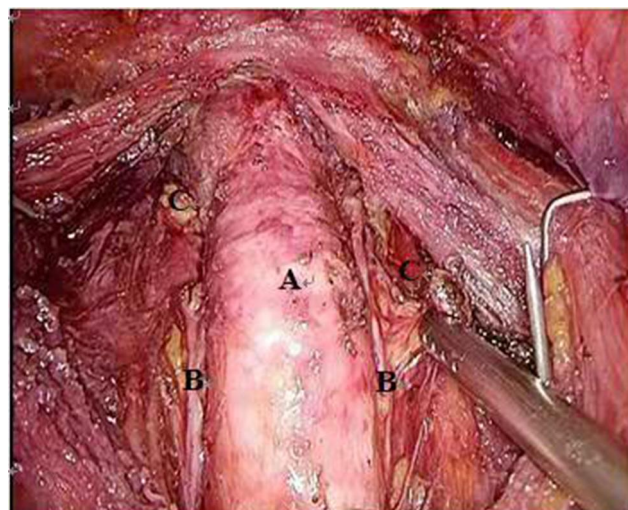


Figure 3 Schematic diagram of operation after endoscopic bilateral total thyroidectomy and bilateral central lymph node dissection. A: trachea, B: RLN, C: parathyroid.

groups were compared using students' test for numeric parameters and Chi-square test for non-numeric parameters. The multivariate analysis combines the significant factors of univariate analysis and through multivariate analysis to determine the independent predictors of complications. P values < 0.05 were considered statistically significant.

Results

The clinicopathological characteristics of 630 patients are summarized in Table 1.

Table 1 Clinical Characteristics of the Patients

Characteristics	
Age, years	38.87±11.57
Gender	
Male	98 (12.8%)
Female	532 (87.2%)
BMI, kg/m ²	22.16±2.0
Type of operation	
Lobectomy	234 (37.1%)
Lobectomy and SND	245 (38.9%)
Total thyroidectomy and SND	151 (24%)
Drainage volume, mL	116.60±23.47
Operation time, min	138.83±34.81
Postoperative hospital stay, days	5.40±1.64
Retrieved lymph node	7.6±3.2

Table 2 Postoperative Complications

Complications	n
Thyroid related complications	
Transient RLN palsy	20 (3.17%)
Permanent RLN palsy	1 (0.16%)
Transient hypocalcemia	54 (8.57%)
Permanent hypocalcemia	1 (0.16%)
Superior laryngeal nerve injury	16 (2.54%)
Flap related complications	
Wound infection	2 (0.32%)
Flap necrosis	0
Flap perforation	0
Recurrence around subcutaneous tunnel	0
Other complications	
Postoperative bleeding	4 (0.63%)
Lymphatic leakage	3 (0.48%)
Deep Venous Thrombosis	1 (0.16%)
Tracheal injury	0

The mean age of the patients was 38.87 ± 11.57 years, and there were 98 male (12.8%) and 532 female patients (87.2%). Among them, 394 patients (62.5%) were thyroid carcinoma, 236 patients (37.5%) were thyroid benign tumors, and the tumor diameter was 0.4–4.5cm. In general, the mean total operation time was 138.83 ± 34.81 minutes, and the mean postoperative hospital stay was 5.40 ± 1.64 days.

The perioperative complications of 630 patients undergoing endoscopic thyroidectomy are shown in Table 2. Among the thyroid-related complications, 20 (3.17%) patients developed hoarseness after the operation, but a satisfactory voice was obtained within 3–6 months. One patient (0.16%) had permanent RLN injury, 16 patients (2.54%) complained of decreased pitch range and fatigue after extended voice use, except for 2 patients, all of them recovered satisfactorily within 3–6 months. 54 patients (8.57%) had transient hypocalcemia, and 1 patient (0.16%) had permanent hypocalcemia. The complications such as flap perforation, flap necrosis, and tumor implantation or recurrence around the subcutaneous tunnel did not appear.

First of all, the relationship between clinical factors and complications was analyzed. Univariate analysis showed that the location of tumor ($P = 0.027$), Hashimoto's thyroiditis ($P = 0.012$), nature of tumor ($P = 0.026$), operation time ($P = 0.002$), operation mode ($P = 0.108$), clinical group ($P = 0.001$) and use of nerve monitor ($P = 0.045$) were related to RLN injury (Table 3). In

logistic regression analysis, thyroid carcinoma ($OR=5.09$, $P=0.041$), operation time lasting more than 150 minutes ($OR=4.20$, $P=0.034$) and operation before 2017 ($OR=2.98$, $P=0.001$) were risk factors of RLN injury. The analysis of risk factors of superior laryngeal nerve injury is shown in Table 4. We found that bilateral thyroid tumors ($P = 0.036$), tumors larger than 2cm ($P = 0.023$), operation mode ($P = 0.029$), clinical groups ($P = 0.006$) and intraoperative use of nerve monitors ($P = 0.023$) are all correlated with superior laryngeal nerve injury. Nearly every variable proved insignificant in the logistic regression analysis, except that operation after 2017 ($OR = 20.3$, $P < 0.005$) was a protective factor.

The 13 parameters that are potential risk factors for parathyroid injury in univariate and multivariate analysis are shown in Table 5. Univariate analysis showed that tumor number ($P= 0.025$), tumor location ($P = 0.019$), tumor properties ($P = 0.005$), Hashimoto's thyroiditis ($P = 0.007$), operation time ($P= 0.021$), operation mode ($P < 0.001$) and clinical group ($P= 0.001$) were significantly related to parathyroid gland injury. Moreover, on entering the data into the logistic regression model, thyroid carcinoma ($OR= 2.88$, $P = 0.04$), operation mode ($OR= 15.29$, $P = 0.001$), and operation before 2017 ($OR= 20.09$, $P < 0.001$) were risk factors for parathyroid gland injury.

Discussion

Since the introduction of endoscopic parathyroidectomy by Dr. Gagner in 1996,⁹ endoscopic thyroidectomy has made long-term progress, and its applications have widened. In recent years, comparative studies of endoscopic thyroidectomy and traditional open thyroidectomy have been reported. There is no significant difference in the technical safety between endoscopic thyroidectomy and open thyroidectomy. They found that endoscopic thyroidectomy has many advantages, including better cosmetic effects.¹⁰ Nowadays, in a large number of medical institutions in China and South Korea, endoscopic treatment of papillary thyroid microcarcinoma has been completed safely.⁷ Despite ongoing refinements in techniques and innovations in surgical instruments, the potentially serious complications of thyroid surgery cannot be ignored. At present, some works of literature have reported their own experience on the complications and prevention of endoscopic thyroidectomy.^{11,12} Since we reviewed the perioperative complications in 630 consecutive cases with endoscopic thyroidectomy, we tried to analyze some clinical factors to guide us to reduce surgical complications.

Table 3 Risk Factors for RLN Injury After Endoscopic Thyroidectomy

Variables	RLN Injury		P value	Multivariate Analysis	
	Yes	No		OR (95% CI)	P value
Gender			0.653		
Male	4	94			
Female	17	515			
Age, years	39.6±11.7	38.2±8.3	0.554		
BMI, kg/m ²	21.9±3.1	22.2±3.3	0.451		
Tumor size, cm			0.853		
≤1.0	10	328			
>1.0 but≤2.0	4	103			
>2.0	7	178			
Number of tumors			0.882		
Single	11	309			
Multiple	10	300			
Tumor location			0.027	6.14 (1.92–19.63)	0.092
Unilateral	7	351			
Bilateral	14	258			
Tumor site			0.893		
Left	5	186			
Right	4	163			
Hashimoto's thyroiditis			0.012	0.43 (0.14–1.32)	0.141
Yes	8	103			
No	13	506			
Tumor properties			0.026	5.09 (0.87–29.86)	0.041
Benign	3	233			
metastasis	18	376			
Extracapsular invasion			0.764		
Positive	2	66			
Negative	12	314			
Operation time			0.002	4.20 (1.12–15.81)	0.034
>150 min	16	252			
<150 min	5	357			
Type of operation			0.132		
Thyroid lobectomy	5	229			
Thyroid lobectomy with CLND*	10	295			
Total thyroidectomy with CLND	6	85			
Clinical group			0.001	18.05 (4.19–77.75)	0.001
2012–2016 years	15	247			
2017–2019 years	6	362			
Intraoperative nerve monitoring			0.045	2.98 (0.34–26.16)	0.325
Yes	1	131			
No	20	478			
N Classification, n			0.692		
N0	8	237			
N1a	6	143			

Note: *Central lymph node dissection.

Table 4 Risk Factors for Superior Laryngeal Nerve Injury After Endoscopic Thyroidectomy

Characteristics	Superior Laryngeal Nerve Injury		P value	Multivariate Analysis	
	Yes	No		OR (95% CI)	P value
Gender			0.733		
Male	2	96			
Female	14	51			
Age, years	39.3±10.8	38.7±9.1	0.583		
BMI, kg/m ²	22.0±2.9	22.1±3.1	0.448		
Tumor size, cm			0.023	2.36 (0.60–9.31)	0.221
≤1.0	5	533			
>1.0 but≤2.0	1	106			
>2.0	10	175			
Number of tumors			0.568		
Single	7	313			
Multiple	9	301			
Tumor location			0.036	9.98 (1.14–87.69)	0.058
Unilateral	5	353			
Bilateral	11	261			
Tumor site			0.848		
Left	4	187			
Right	4	163			
Hashimoto's thyroiditis			0.904		
Yes	3	108			
No	13	506			
Tumor properties			0.599		
Benign	7	229			
Metastasis	9	385			
Extracapsular invasion			0.621		
Positive	1	67			
Negative	8	318			
Operation time			0.541		
>150 min	8	260			
<150 min	8	354			
Type of operation			0.029	5.89 (1.14–30.21)	0.056
Thyroid lobectomy	4	230			
Thyroid lobectomy with CLND	6	299			
Total thyroidectomy with CLND	6	85			
Clinical group			0.006	5.28 (1.27–21.87)	0.004
2012–2016 years	12	250			
2017–2019 years	4	364			
Intraoperative nerve monitoring					
Yes	0	132			
No	16	482			
N Classification, n			0.272		
N0	7	238			
N1a	2	147			

Table 5 Risk Factors for Parathyroid Glands Injury After Endoscopic Thyroidectomy

Characteristics	Parathyroid Glands Injury		P value	Multivariate Analysis	
	Yes	No		OR (95% CI)	P value
Gender			0.829		
Male	8	90			
Female	47	485			
Age, years	37.4±7.3	38.9±6.8	0.601		
BMI, kg/m ²	22.4±3.3	22.9±2.6	0.486		
Tumor size, cm			0.767		
≤1.0	32	306			
>1.0 but≤2.0	8	99			
>2.0	15	170			
Number of tumors			0.025	3.88 (1.55–9.72)	0.104
Single	20	300			
Multiple	35	275			
Tumor location			0.019	1.17 (0.55–2.49)	0.685
Unilateral	23	335			
Bilateral	32	240			
Tumor site			0.753		
Left	13	178			
Right	10	157			
Hashimoto's thyroiditis			0.007	0.39 (0.15–1.05)	0.06
Yes	17	94			
No	38	481			
Tumor properties			0.005	2.88 (1.04–7.88)	0.04
Benign	11	225			
Metastasis	44	350			
Extracapsular invasion			0.864		
Positive	8	60			
Negative	36	290			
Operation time			0.021	1.92 (0.77–4.81)	0.163
>150 min	30	238			
<150 min	25	337			
Type of operation			0.000	15.29 (3.19–73.34)	0.001
Thyroid lobectomy	12	222			
Thyroid lobectomy with CLND	21	284			
Total thyroidectomy with CLND	22	69			
Clinical group			0.001	20.09 (2.89–118.28)	0.000
2012–2016 years	35	227			
2017–2019 years	20	348			
N Classification, n			0.654		
N0	26	219			
N1a	18	131			

The incidence rate of perioperative complications in our study was within an acceptable range and no higher than that of conventional open thyroidectomy. The perioperative complications after endoscopic thyroidectomy via the total areola approach include thyroid-related complications, such as RLN injury, superior laryngeal nerve injury, hypocalcemia, hematoma, and lymphorrhea. There are no specific skin flap-related complications, such as flap perforation, flap necrosis, and tumor implantation or recurrence around the subcutaneous tunnel.

Most of the complications in our study involved RLN injury, superior laryngeal nerve injury, and hypocalcemia. In a traditional thyroidectomy, the incidence of transient and permanent recurrent laryngeal nerve injury increased significantly with the extent of surgery. The incidence of permanent RLN injury was reported to range between 0–4%,^{13,14} and transient RLN injury was 2%.¹⁵ In our patients, the incidence of transient and permanent RLN injury is acceptable, and the incidence of permanent RLN injury is only 0.16%. As shown in the current study, univariate analysis showed that RLN injury was related to bilateral thyroid tumor, Hashimoto's thyroiditis, and thyroid carcinoma, operation time lasting than 150 minutes, operation mode, operation after 2017 and use of intraoperative nerve monitor. When we evaluated with multivariate analysis, we established that thyroid carcinoma and operation time lasting than 150 minutes were the risk factors for the increased incidence of RLN injury. Moreover, with the development of surgery, the incidence of RLN injury decreased significantly after 2017. There is agreement between endocrine and neck surgeons about the extension of therapeutic lymph node dissection in N+ PTC patients, and in the prophylactic treatment of N0 "high risk" patients.¹⁶ Although our study shows that PTC is a risk factor for recurrent laryngeal nerve injury, IONM is a safe and effective technique with high sensitivity and good specificity, which has a high predictive value for postoperative nerve function.¹⁷ It is critical to note this given that the visualization of these vital structures might be easier with the excellent magnification provided by the endoscopic camera, especially the clinical application of high-definition endoscopy in recent years, the fine structure of the neck tissue is more clear and distinguishable, combined with intraoperative nerve monitoring can reduce this complication.

The injury of the external branch of the superior laryngeal nerve is one of the common complications of thyroid surgery. The injury rate of the external branch is

1 – 14%¹⁸ reported in the literature. Notably, thyroid surgeons often focus on the protection of recurrent laryngeal nerve and parathyroid gland but pay less attention to the protection of superior laryngeal nerve.¹⁹ Therefore, there are few reports to analyze the factors of superior laryngeal nerve injury. In this study, the incidence of superior laryngeal nerve injury was 2.54%. We found that bilateral thyroid tumors, tumors larger than 2cm, operation mode, clinical groups, and intraoperative use of nerve monitors were correlated with superior laryngeal nerve injury. However, in the multi-factor analysis, we found that operation after 2017 was an only protective factor. Although it may be due to the small sample size, it difficult to find the best-influencing factors, but the reduction of the injury of the superior laryngeal nerve in the later period is also inseparable from our clinical attention, routine fine anatomy of the superior laryngeal nerve during the operation and the use of nerve monitoring. Hurtado Lopez et al²⁰ thought that searching for and exposing EBSLN in thyroid surgery was an effective way to avoid injury, and the injury rate was significantly lower than that in the group without EBSLN. According to the EBSLN monitoring guidelines for thyroid and parathyroid surgery issued by the international neuromonitoring group (INMSG), electromyography (EMG) induced by intraoperative SLN electrical stimulation is the most accurate method to judge the functional integrity of SLN at present, and it is the most recommended method to use.^{21,22}

On the other side of the spectrum, parathyroid injury is widespread in thyroid surgery. It is noted that the degree and duration of hyperparathyroidism increase with the extent of thyroid surgery.²³ In a total thyroidectomy, the incidence of transient hypocalcemia after conventional open total thyroidectomy is reported to be 19% to 38%, and that of permanent hypocalcemia is 0% to 3%.²⁴ The incidence of endoscopic injury was close to that of open thyroidectomy.²⁵ As shown in the current study, although we found an increase in the incidence of transient and permanent hypocalcemia relative to nerve injury, the incidence rates remained within an acceptable range. Through multivariate analysis, we found that thyroid carcinoma, operation mode, and operation before 2017 were the risk factors of parathyroid injury. However, in recent years, we have mainly grasped two principles. First, we should reserve at least one parathyroid gland and its blood supply in situ as much as possible, or we can not reserve the blood supply to take the initiative to transplant the parathyroid gland. Alternatively, with the protection of the

parathyroid gland by carbon nanoparticle suspension, increasingly thyroid patients benefit.

With the accumulation of experience, as well as the promotion and application of intraoperative nerve monitor, minilab, special hook, and carbon nanoparticles suspension parathyroid negative imaging technology, the indications of endoscopic thyroid carcinoma surgery have been significantly widened. In essence, our study shows satisfactory results with an endoscopic thyroidectomy in a large number of thyroid patients. However, there are still some limitations in this study: first, this one is a retrospective study that was conducted only in a single institution. Besides, further study should collect more clinical factors, which may provide more evidence for the evaluation of complications.

Wound infection and lymphatic leakage were rare. Both of our patients had definite human factors. Among them, one case was the drainage tube which was taken back by the patient after the drainage tube fell off, and the other case was the endoscopic instrument which was accidentally placed in the contaminated area by the chief surgeon during the operation, but it was not found at that time. Both cases were improved by active anti-infection and enhanced drainage, and no re-incision and drainage was carried out. Therefore, strengthening aseptic operations and education during and after the operation can effectively avoid the occurrence of infection. As with open thyroid surgery, lymph leakage may occur after central and lateral lymph node dissection. The left thoracic duct and the right lymphatic duct should be preserved as far as possible. In case of injury, it should be ligated or sutured. For most of the lymphatic (chylous) leakage, only conservative treatment is needed when the drainage volume is not large.

In a nutshell, we believe that once through the learning curve period, surgeons master the standardized endoscopic thyroidectomy techniques, with the high-definition equipment and more sophisticated operation equipment being applied in clinical practice and have a good understanding of the risk factors and preventive measures for possible complications, and then we can safely carry out total areola approach endoscopic thyroidectomy.

Acknowledgments

The authors would like to thank the surgeons from the participating institutes for helping us with this study.

Disclosure

The authors report no conflicts of interest in this work.

References

1. Peiris AN, Peiris P. Role of total thyroidectomy in the treatment of thyroid diseases. *South Med J*. 2006;99(11):1201–1202. doi:10.1097/01.smj.0000243077.54337.fe
2. Filho JG, Kowalski LP. Surgical complications after thyroid surgery performed in a cancer hospital. *Otolaryngol Head Neck Surg*. 2005;132(3):490–494. doi:10.1016/j.otohns.2004.09.028
3. Huscher CS, Chiadini S, Napolitano C, Recher A. Endoscopic right thyroid lobectomy. *Surg Endosc*. 1997;11(8):877. doi:10.1007/s004649900476
4. Ohgami M, Ishii S, Arisawa Y, et al. Scarless endoscopic thyroidectomy: breast approach for better cosmesis. *Surg Laparosc Endosc Percutan Tech*. 2000;10(1):1–4. doi:10.1097/00129689-200002000-00001
5. Ikeda Y, Takami H, Niimi M, Kan S, Sasaki Y, Takayama J. Endoscopic thyroidectomy by the axillary approach. *Surg Endosc*. 2001;15(11):1362–1364. doi:10.1007/s004640080139
6. Shimazu K, Shiba E, Tamaki Y, et al. Endoscopic thyroid surgery through the axillo-bilateral breast approach. *Surg Laparosc Endosc Percutan Tech*. 2003;13(3):196–201. doi:10.1097/00129689-200306000-00011
7. Park KN, Cho SH, Lee SW. Nationwide multicenter survey for current status of endoscopic thyroidectomy in Korea. *Clin Exp Otorhinolaryngol*. 2015;8(2):149–154. doi:10.3342/ceo.2015.8.2.149
8. Perrier ND, Randolph GW, Inabnet WB, Marple BF, VanHeerden J, Kuppersmith RB. Robotic thyroidectomy: a framework for new technology assessment and safe implementation. *Thyroid*. 2010;20(12):1327–1332. doi:10.1089/thy.2010.1666
9. Gagner M. Endoscopic subtotal parathyroidectomy in patients with primary hyperparathyroidism. *Br J Surg*. 1996;83(6):875. doi:10.1002/bjs.1800830656
10. Chung YS, Choe JH, Kang KH, et al. Endoscopic thyroidectomy for thyroid malignancies: comparison with conventional open thyroidectomy[J]. *World J Surg*. 2007;31(12):2302–2306. doi:10.1007/s00268-007-9117-0.
11. Ban EJ, Yoo JY, Kim WW, et al. Surgical complications after robotic thyroidectomy for thyroid carcinoma: a single center experience with 3000 patients. *Surg Endosc*. 2014;28(9):2555–2563. doi:10.1007/s00464-014-3502-1
12. Kim SK, Kang SY, Youn HJ, Jung SH. Comparison of conventional thyroidectomy and endoscopic thyroidectomy via axillo-bilateral breast approach in papillary thyroid carcinoma patients. *Surg Endosc*. 2016;30(8):3419–3425. doi:10.1007/s00464-015-4624-9
13. Hines JR, Winchester DJ. Total lobectomy and total thyroidectomy in the management of thyroid lesions. *Arch Surg*. 1993;128(9):1060–1064. doi:10.1007/BF00451887
14. Wagner HE, Seiler CH. Recurrent laryngeal nerve palsy after thyroid gland surgery. *Br J Surg*. 1994;81(2):226–228. doi:10.1002/bjs.1800810222
15. Rosato L, Avenia N, Bernante P, et al. Complications of thyroid surgery: analysis of a multicentric study on 14,934 patients operated on in Italy over 5 years. *World J Surg*. 2004;28(3):271–276. doi:10.1007/s00268-003-6903-1
16. Calò PG, Medas F, Conzo G, et al. Intraoperative neuromonitoring in thyroid surgery: is the two-staged thyroidectomy justified? *Int J Surg*. 2017;41(Suppl 1):S13–S20. doi:10.1016/j.ijssu.2017.02.001.
17. Conzo G, Docimo G, Mauriello C, et al. The current status of lymph node dissection in the treatment of papillary thyroid cancer. A literature review. *Clin Ter*. 2013;164(4):e343–6. doi:10.7417/CT.2013.1599. PMID: 24045534.

18. Kandil E, Mohamed SE, Deniwar A, et al. Electrophysiologic identification and monitoring of the external branch of superior laryngeal nerve during thyroidectomy. *Laryngoscope*. 2015;125(8):1996–2000. doi:10.1002/lary.25139
19. Joliat GR, Guarnero V, Demartines N, Schweizer V, Matter M. Recurrent laryngeal nerve injury after thyroid and parathyroid surgery: incidence and postoperative evolution assessment. *Medicine (Baltimore)*. 2017;96(17):e6674. doi:10.1097/MD.00000000000006674
20. Hurtado Lopez LM, Pacheco Alvarez MI, Monteseastillo ML, Zaldivar-Ramirez FR. Importance of the intraoperative identification of the external branch of the superior laryngeal nerve during thyroidectomy: electromyographic evaluation. *Thyroid*. 2015;15(5):449–454. doi:10.1089/thy.2005.15.449
21. Mangano A, Dionigi G. The need for standardized technique in intraoperative monitoring of the external branch of the superior laryngeal nerve during thyroidectomy. *Surgery*. 2011;149(6):854–855. doi:10.1016/j.surg.2011.03.004
22. Barczynski M, Randolph GW, Cemea CR, et al. External branch of the superior laryngeal nerve monitoring during thyroid and parathyroid surgery: international Neural Monitoring Study Group standards guideline statement. *Laryngoscope*. 2013;123(S4):S1–S14. doi:10.1002/lary.24301
23. Demeester-Mirkine N, Hooghe L, Van Geertruden J, De Maertelaer V. Hypocalcemia after thyroidectomy. *Arch Surg*. 1992;127(7):854–858. doi:10.1001/archsurg.1992.01420070118021
24. El Malki HO, Abouqal R. Systematic review and meta-analysis of predictors of post-thyroidectomy hypocalcaemia. *Br J Surg*. 2014;101(7):307–320. doi:10.1002/bjs.9384
25. Li Y, Zhou X. Comparison between endoscopic thyroidectomy and conventional open thyroidectomy for papillary thyroid microcarcinoma: a meta-analysis. *J Cancer Res Ther*. 2016;12(2):550–555. doi:10.4103/0973-1482.157353

Cancer Management and Research

Dovepress

Publish your work in this journal

Cancer Management and Research is an international, peer-reviewed open access journal focusing on cancer research and the optimal use of preventative and integrated treatment interventions to achieve improved outcomes, enhanced survival and quality of life for the cancer patient.

The manuscript management system is completely online and includes a very quick and fair peer-review system, which is all easy to use. Visit <http://www.dovepress.com/testimonials.php> to read real quotes from published authors.

Submit your manuscript here: <https://www.dovepress.com/cancer-management-and-research-journal>