

Multiple Pulmonary Metastases of Recurrent Giant Cell Tumor of Bone with Expression of VEGFR-2 Successfully Controlled by Denosumab and Apatinib: A Case Report and Literature Review

Taojun Gong*
Yi Luo*
Yitian Wang
Chuanxi Zheng
Jianguo Fang
Li Min 
Yong Zhou
Chongqi Tu 

Department of Orthopedics, West China Hospital, Sichuan University, Chengdu, Sichuan, 610041, People's Republic of China

*These authors contributed equally to this work

Abstract: Giant cell tumor of bone (GCTB) is a rare, benign, but locally aggressive bone tumor. It has a high tendency for local recurrence, which may increase the incidence of lung metastasis. Currently, an optimal treatment strategy has not been established because of the rarity of pulmonary metastatic GCTB. Denosumab is the preferred regimen for unresectable metastatic lesions; however, there are no alternative treatment options when patients are resistant to denosumab. Apatinib is a small-molecule tyrosine kinase inhibitor that selectively competes for the vascular endothelial growth factor receptor 2 (VEGFR-2) ATP binding site, and several studies have analyzed the effectiveness of apatinib in advanced or metastatic tumors. However, there is no report of apatinib as an anti-angiogenesis therapy for pulmonary metastatic GCTB to date. Here, we present a case of a 26-year-old female who was diagnosed with recurrent and pulmonary metastatic GCTB. Immunohistochemical (IHC) staining indicated that the tumor cells were positive for VEGFR-2. Denosumab was administered to control the metastases; nevertheless, disease progression was confirmed after four months of treatment. Given the IHC results and rapid disease progression, apatinib was added to the treatment strategy. After 42 months of treatment, the patient showed noticeable symptomatic improvement and considerable tumor shrinkage.

Keywords: giant cell tumor of bone, pulmonary metastasis, VEGFR-2, denosumab, apatinib

Introduction

Giant cell tumor of bone (GCTB) is a rare, benign, but locally aggressive bone tumor, accounting for 3%~5% of all primary bone tumors.¹ It typically occurs between the ages of 20–40, is generally more common in females,² and has a high tendency for local recurrence.^{1,3} Pulmonary metastasis rarely occurs, affecting only 1%–3.9% of patients without local recurrence and 6%–21.1% of patients with local recurrence. The overall mortality rate of these patients varies widely from 0 to 23%.⁴

GCTB has been shown to overexpress receptor activator of nuclear factor κB ligand (RANKL), the action of which is specifically blocked by denosumab. Denosumab is a monoclonal antibody specifically targeting human RANKL that inhibits the formation of osteoclast-like giant cells and their precursors. This

Correspondence: Chongqi Tu
Department of Orthopedics, West China Hospital, Sichuan University, Guoxue Xiang No. 37, Chengdu, Sichuan, 610041, People's Republic of China
Email tuchongqibone@hotmail.com

inhibition leads to a reduction or elimination of giant cells and impedes osteolysis, thereby allowing replacement of diseased bone with dense and new bone.⁵ Surgical removal of resectable metastases is the main treatment. For patients with unresectable metastases, denosumab is an option. However, effective systemic therapies for this rare disease are lacking for patients who are resistant to denosumab.

Pathological angiogenesis plays a key role in the invasion, progression, and metastasis of tumor cells. Apatinib is a small-molecule tyrosine kinase inhibitor (TKI) that selectively binds to and strongly inhibits vascular endothelial growth factor receptor 2 (VEGFR-2), which leads to a decrease in vascular endothelial growth factor (VEGF)-mediated endothelial cell migration, proliferation, and tumor microvascular density. Apatinib has been demonstrated to improve progression-free survival and overall survival in patients with advanced gastric cancer.⁶ Recent studies have analyzed the effectiveness of apatinib in advanced or metastatic bone tumors.^{7–10} However, treatment of pulmonary metastatic GCTB with apatinib has not been reported by far.

Case Presentation

A 26-year-old female was referred to our hospital in June 2014 with a complaint of dull pain in the right knee for six months. Physical examination showed tenderness in the proximal right tibia. Radiography and computed tomography (CT) revealed eccentric, well-defined osteolytic destruction in the proximal metaphysis

of the right tibia, suggesting the imaging diagnosis of GCTB (Campanacci grade II) (Figure 1A–D). Chest CT scan (Figure 2A) and single-photon emission CT (Figure 1E) did not reveal any metastatic lesions. An open biopsy from a lateral incision was performed thereafter, and pathological results showed multinucleated osteoclast giant cells with a large number of nuclei scattered among mononuclear tumor cells, which confirmed the diagnosis of a benign GCTB (Figure 3A). Subsequently, the patient underwent intralesional curettage following the biopsy tract. Utilizing high-speed drilling and ethyl alcohol, 1 cm of spongy bone and 1 mm of cortical bone were removed. The remaining cavity was then packed with cement (Figure 4A and B). After the procedures, immobilization was recommended to prevent pathological fracture. However, nine months later, a palpable mass was detected in the right popliteal fossa. Radiography, CT, and magnetic resonance imaging revealed local cortical bone destruction with soft tissue extension (Figure 4C–F) which indicated Campanacci grade III. Chest CT showed no evidence of metastases. Because of the extensive recurrence and stage III rating, the patient underwent wide resection of the lesion with prosthetic reconstruction. Postoperative pathologic features and presence of multinucleated giant cells were detected by immunohistochemical (IHC) staining with a monoclonal antibody against CD68 (PG-M1) and were similar to that of the pre-surgical

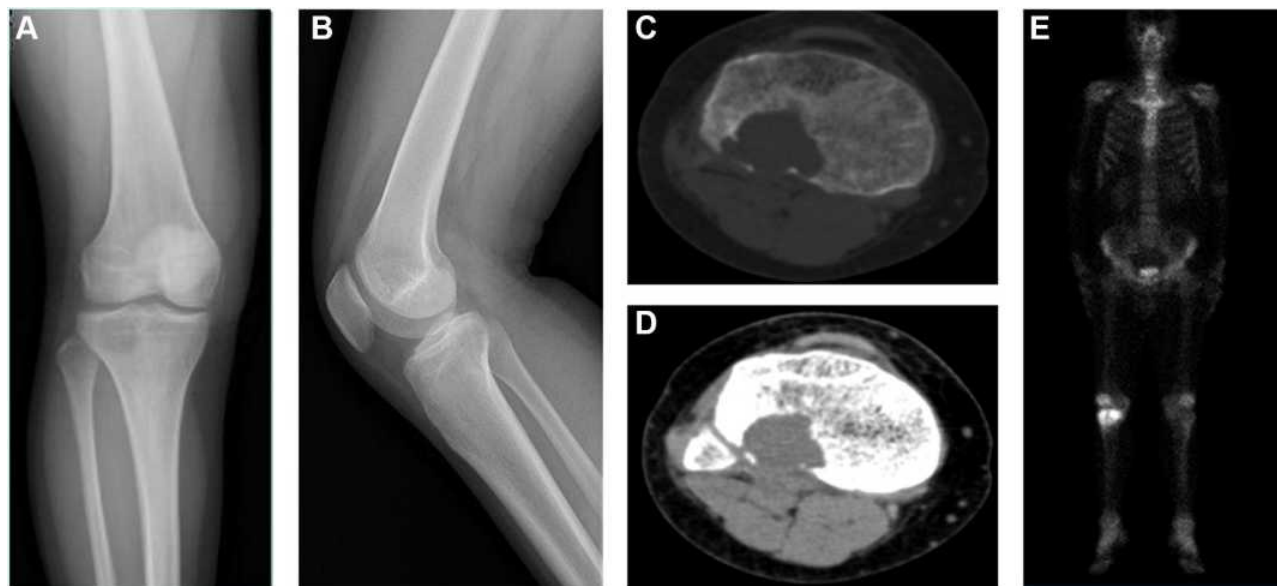


Figure 1 Radiological images of the proximal right tibia. Radiograph (A and B) and CT (C and D) showed osteolytic bony destruction. SPECT (E) images were negative for metastatic lesions.

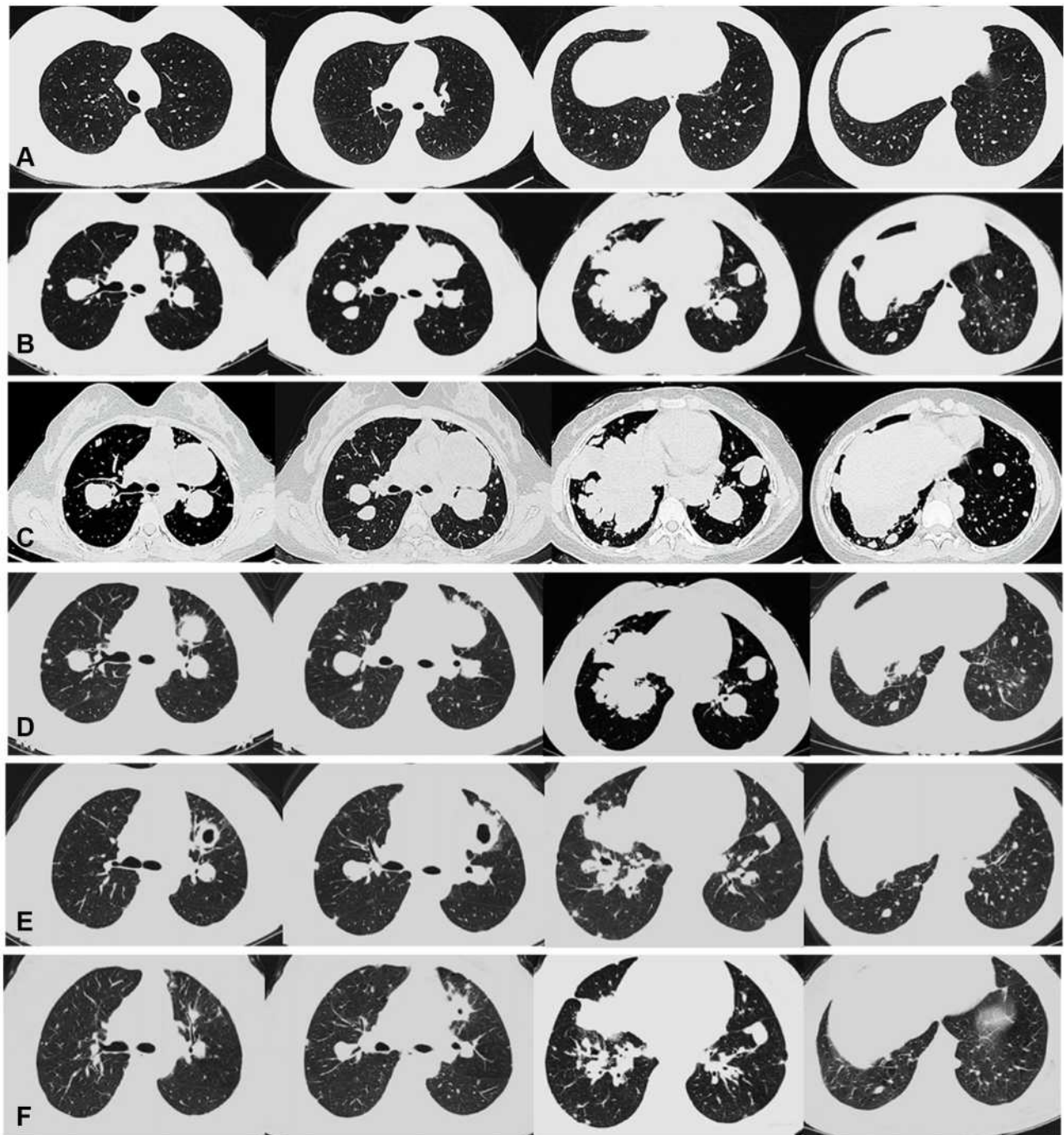


Figure 2 CT of the chest. (A) Local recurrence but without pulmonary metastasis. (B) Multiple pulmonary metastases were found and denosumab initiated. (C) 4 months after denosumab therapy. (D) 3 months after denosumab and apatinib therapy. (E) 15 months after denosumab and apatinib therapy. (F) 33 months after denosumab and apatinib therapy.

specimens, revealing the recurrence of GCTB without malignant transformation (Figure 3B and C). The IHC staining also identified tumor cells positive for VEGFR-2 (Figure 3D). The patient was regularly followed-up every three months in our orthopedic clinic.

Two years after the latest surgery, the patient presented to our clinic with a complaint of hemoptysis. The lung CT scans were evaluated by experienced musculoskeletal surgeons and radiologists who verified more than 100 pulmonary nodules in both lungs (Figure 2B). Although

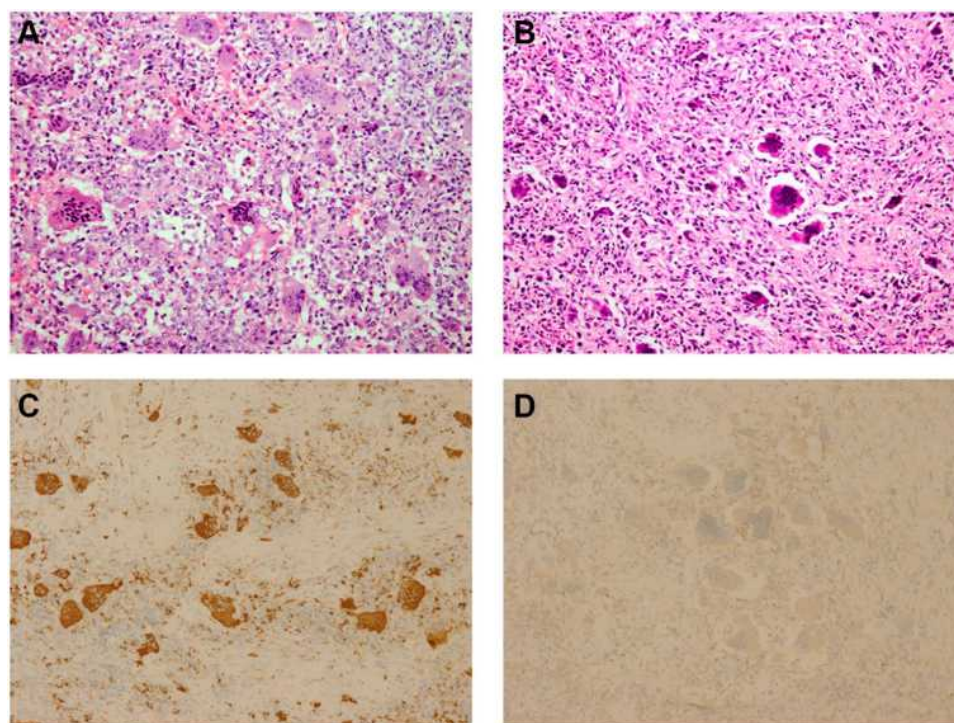


Figure 3 Pathological features of the local lesions. (A) High-magnification observation of numerous multinucleated giant cells (Hematoxylin and eosin stain, 200x). (B) High-magnification observation of local recurrence but without sarcomatous change (Hematoxylin and eosin stain, 200x). (C) Presence of multinucleated giant cells indicates a recurrence of GCTB (Immunohistochemical staining, 100x). (D) Expression of VEGFR-2 as assessed by immunohistochemistry (Immunohistochemical staining, 100x).

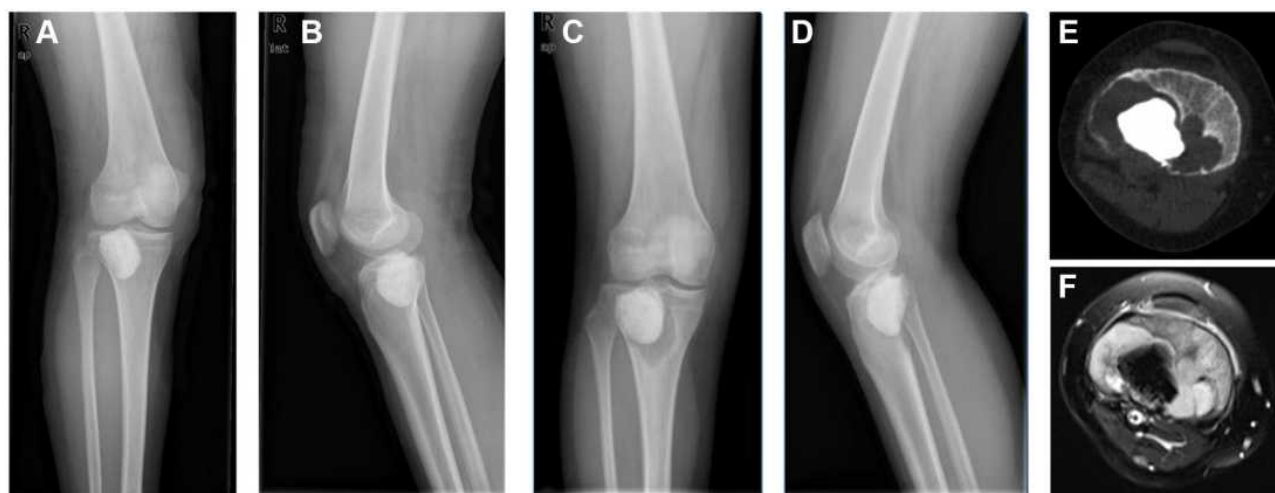


Figure 4 Radiological images of the proximal right tibia. Radiograph (A and B), postoperative films following the curettage and packing with cement; Radiograph (C and D), and CT (E, bone window) showed a circumferential lucency around the bone cement and local cortical bone destruction. MRI (F, T1-weight) showed a soft tissue mass.

biopsy of the lung mass was not performed owing to the refusal of the patient, the imaging diagnosis of metastatic GCTB was considered based on the presence of multiple lesions. Meanwhile, lung cancer was excluded because the level of serum cytokeratin fragment antigen 21-1, a sensitive tumor marker of lung cancer, was negative.

Since both biopsy and resection are traumatic operations with risks and complications, and the multiple metastases could not be completely removed by surgery or benefit from it. On the other hand, our patient could not tolerate chemotherapy because of an Eastern Cooperative Oncology Group performance status score of 3. Therefore,

the patient chose subcutaneous denosumab administration, which was initiated at a dose of 120 mg every 28 days, with additional doses on days 8 and 15 of the first month. The patient was also supplemented with calcium and vitamin D. However, after four months of denosumab therapy, the symptoms of hemoptysis became more severe. The lung CT scan showed the metastatic nodules had increased in size and number, indicating progression of disease (Figure 2C). After multiple interdisciplinary team discussions, and in view of the high-level VEGFR-2 expression and rapidly progression, the patient was tentatively administered the TKI apatinib in combination with denosumab treatment. Denosumab was injected every month with a dose of 120 mg and apatinib was administered with an oral dosage of 500 mg daily. After three months of denosumab and apatinib treatment, the patient showed noticeable improvement of hemoptysis and visibly reduced tumor size (Figure 2D).

At a follow-up of 42 months, chest CT images showed a significant size reduction in the lung nodules. The largest one had greatly decreased in size from 12.2×8.5 cm to 3.5×1.5 cm (Figure 2E and F), and the tumor volume shrinkage rate was 95%. Moreover, the number of metastatic nodules decreased to less than 30. After initiation of apatinib therapy, a few drug-related toxicity reactions were noted, including hand-foot skin syndrome, gastrointestinal discomfort, and hypopigmentation of the hair. All adverse reactions were mild (grade 1 or 2) according to the Common Terminology Criteria for Adverse Events and were easily controlled by symptomatic treatments. The efficacy was evaluated as a significant partial response (PR) to denosumab and apatinib treatment by the Response Evaluation Criteria for Solid Tumors 1.1. The patient is under stable condition at the time of this writing.

Discussion

Although GCTB is classified as a benign tumor, lung metastasis rates vary from 1%–21.1%.^{3,11} Since the incidence of pulmonary metastasis of GCTB is rather rare, there is no definite protocol for the treatment of metastatic GCTB. According to the National Comprehensive Cancer Network guidelines, surgical excision is the mainstay of the treatment for patients with resectable metastases. Denosumab is a recommended regimen for patients with unresectable metastatic lesions.^{1,5,12} Other alternatives include interferon alpha-2b, radiation therapy, or observation. However, interferon therapy has limited efficacy in treating metastases in most patients, and radiation therapy

may increase the risk of malignant transformation. Therefore, we did not recommend those therapies to this patient.

The role of denosumab in controlling unresectable (local or metastatic) tumors has been well established.^{1,5} Luo et al reported seven patients with pulmonary metastatic GCTB who received denosumab treatment. None of these patients showed disease progression during an average of 28.6 months follow-up period. Three patients showed a PR and four patients were stabilized by denosumab treatment.¹³ An open-label, Phase II study incorporated 169 patients with unresectable GCTB treated with denosumab. After a median follow-up of 13 months, 96% (163 of 169) of evaluable patients had no disease progression.¹⁴ Nevertheless, for our patient, denosumab alone was invalid in managing pulmonary metastases, and the disease progressed after four months of denosumab therapy.

As specimens of the lung metastases were not available, we could not determine the pathological features of the metastatic lesions. We speculate whether sarcomatous changes had occurred in the metastatic nodules. Although extremely rare, progressive disease caused by malignant transformation in benign GCTB after denosumab therapy has been reported previously, and most patients treated with cytotoxic chemotherapy had an unfavorable prognosis (Table 1).^{1,16–19} The recurrent bone tumor was positive for VEGFR-2 in our patient, indicating antiangiogenic therapy might be a potential therapeutic target. Although denosumab seemed inadequate to control the pulmonary metastases in our patient, a cessation of denosumab therapy might lead to local recurrence and critical hypercalcemia.^{20,21} Therefore, the patient was administered apatinib but did not discontinue the denosumab treatment completely.

Pathological angiogenesis is important in growth and differentiation processes of numerous tumors. VEGF, overexpressed in many solid tumors including GCTB, is one of the central triggers for angiogenesis.^{22,23} VEGFR-2, which presents a strong tyrosine kinase activity towards pro-angiogenic signals, is the key mediator underlying VEGF-induced phenotypes.²⁴ Apatinib is a small-molecule TKI that selectively competes for the VEGFR-2 ATP binding site, blocking downstream signaling and inhibiting tumor angiogenesis.⁸ This therapy is effective for a wide range of primary malignancies and metastatic lesions, such as advanced gastric cancer, osteosarcoma, rhabdomyosarcoma, synovial sarcoma,

Table I Literature Review of Therapy After Progression of GCTB

Report	Patient (NO.)	Age	Sex	Primary Site	Pulmonary Metastases	Local Recurrence	Follow-Up Time (Year)	Therapy Before Progression	Therapy After Progression	Therapeutic Response
Wang et al ¹⁹	1	16	M	Spine	Yes	Yes	4	Wide resection +denosumab	Sunitinib	SD
Tsukamoto et al ¹⁷	1	29	F	Left pelvis	Yes	Yes	10	Curettage +denosumab	Chemotherapy	Died
Broehm et al ¹⁶	2	59	M	Right pelvis	Yes	Yes	12	Wide resection+ denosumab	Chemotherapy	NM
		56	M	Left femur	No	Yes	7	Curettage +denosumab+ wide resection	Chemotherapy	Died
Aponte-Tinao et al ¹⁸	1	15	F	Right tibia	No	Yes	5	Curettage +denosumab+ wide resection	Amputation	Disease-free
Thomas et al ¹	1	NM	F	NM	Yes	Yes	NM	Denosumab+ resection	NM	Died
Current study	1	26	F	Right tibia	Yes	Yes	3	Wide resection+ denosumab	Apatinib	PR

Abbreviations: GCTB, giant cell tumor of bone; M, male; F, female; SD, stable disease; PR, partial response; NM, not mentioned.

and alveolar soft part sarcoma.^{6–10} Wang et al showed a satisfactory result of the application of apatinib in 6 cases of pulmonary metastatic alveolar soft part sarcoma, namely one complete response and five PRs.¹⁰ Zhu et al reported an objective response rate of 33.3% and a clinical benefit rate of 75.0% when apatinib was administered to 31 advanced sarcoma patients including 18 cases of pulmonary metastases.⁷ To our knowledge, only two case reports discussed the efficiency of tyrosine kinase inhibition in the treatment of GCTB. Wang et al presented a case of GCTB with pulmonary and bone metastases that were treated with denosumab and sunitinib, and their patient's condition was stabilized after four years of treatment.¹⁹ Li et al reported a multicentric GCTB patient treated with apatinib, and CT in the fourth month identified a PR.²⁵ However, both studies lacked pathological evidence supporting the use of TKIs.

We recognize that our report has some limitations. First, we did not obtain the pathologic evidence of pulmonary metastases. The patient did not undergo surgery based on risk considerations and personal preference. Second, it is unclear when denosumab and apatinib treatments should be discontinued, which should be the subject of ongoing research.

Conclusion

We present a case of multiple pulmonary metastases of recurrent GCTB successfully controlled by a novel combination of denosumab and apatinib, indicating that VEGFR-2 may provide an effective therapeutic target to control progressive pulmonary metastatic GCTB. This may provide a reference for the treatment of clinically-related cases.

Abbreviations

GCTB, giant cell tumor of bone; CT, computed tomography; IHC, immunohistochemical; PR, Partial response; VEGF, vascular endothelial growth factor; VEGFR-2, vascular endothelial growth factor receptor 2; TKI, tyrosine kinase inhibitor; SPECT, single-photon emission computed tomography; RANKL, nuclear factor κ B ligand.

Data Sharing Statement

All data used or analyzed during this study are included in this published article.

Ethics Statement

This study was approved by the institutional Ethics Committee of West China Hospital, Sichuan University.

Institutional approval was required for the publication of the case details. The patient provided written, informed consent for the publication of the case details.

Acknowledgments

We thank for the support of Professor Xianliang Zhang, Dr. Yahan Zhang, Department of Pathology, West China Hospital.

Funding

This work was supported, in part, by the Chengdu Science and Technology Program Projects (No. 2017-CY02-00032-GX, Dr. Zhou), the National Natural Science Foundation of China (No. 81801852, Dr. Zhou), and the National Key Research and Development Program of China (No. 2017YFB0702604, Dr. Min).

Disclosure

The authors declare that they have no competing interests.

References

1. Thomas D, Henshaw R, Skubitz K, et al. Denosumab in patients with giant-cell tumour of bone: an open-label, Phase 2 study. *Lancet Oncol.* 2010;11(3):275–280. doi:10.1016/S1470-2045(10)70010-3
2. Mendenhall WM, Zlotecki RA, Scarborough MT, Gibbs CP, Mendenhall NP. Giant cell tumor of bone. *Am J Clin Oncol.* 2006;29(1):96–99. doi:10.1097/01.coc.0000195089.11620.b7
3. Wang J, Liu X, Yang Y, et al. Pulmonary metastasis of giant cell tumour: a retrospective study of three hundred and ten cases. *Int Orthop.* 2021;45(3):769–778. doi:10.1007/s00264-020-04907-0
4. Bertoni F, Present D, Sudanese A, Baldini N, Bacchini P, Campanacci M. Giant-cell tumor of bone with pulmonary metastases. Six case reports and a review of the literature. *Clin Orthop Relat Res.* 1988;237:275–285.
5. Chawla S, Blay JY, Rutkowski P, et al. Denosumab in patients with giant-cell tumour of bone: a multicentre, open-label, phase 2 study. *Lancet Oncol.* 2019;20(12):1719–1729. doi:10.1016/S1470-2045(19)30663-1
6. Li J, Qin S, Xu J, et al. Randomized, double-blind, placebo-controlled Phase III Trial of apatinib in patients with chemotherapy-refractory advanced or metastatic adenocarcinoma of the stomach or gastroesophageal junction. *J Clin Oncol.* 2016;34(13):1448–1454. doi:10.1200/JCO.2015.63.5995
7. Zhu B, Li J, Xie Q, Diao L, Gai L, Yang W. Efficacy and safety of apatinib monotherapy in advanced bone and soft tissue sarcoma: an observational study. *Cancer Biol Ther.* 2018;19(3):198–204. doi:10.1080/15384047.2017.1416275
8. Li J, Zhao X, Chen L, et al. Safety and pharmacokinetics of novel selective vascular endothelial growth factor receptor-2 inhibitor YN968D1 in patients with advanced malignancies. *BMC Cancer.* 2010;10:529. doi:10.1186/1471-2407-10-529
9. Xie L, Guo W, Wang Y, Yan T, Ji T, Xu J. Apatinib for advanced sarcoma: results from multiple institutions' off-label use in China. *BMC Cancer.* 2018;18(1):396. doi:10.1186/s12885-018-4303-z
10. Wang Y, Min L, Zhou Y, et al. The efficacy and safety of apatinib in metastatic alveolar soft part sarcoma: a case series of six patients in one institution. *Cancer Manag Res.* 2019;11:3583–3591. doi:10.2147/CMAR.S198429
11. Yang Y, Huang Z, Niu X, Xu H, Li Y, Liu W. Clinical characteristics and risk factors analysis of lung metastasis of benign giant cell tumor of bone. *J Bone Oncol.* 2017;7:23–28. doi:10.1016/j.jbo.2017.04.001
12. Biermann JS, Chow W, Reed DR, et al. NCCN guidelines insights: bone cancer, version 2.2017. *J Natl Compr Canc Netw.* 2017;15(2):155–167. doi:10.6004/jncn.2017.0017
13. Luo Y, Tang F, Wang Y, et al. Safety and efficacy of denosumab in the treatment of pulmonary metastatic giant cell tumor of bone. *Cancer Manag Res.* 2018;10:1901–1906. doi:10.2147/CMAR.S161871
14. Chawla S, Henshaw R, Seeger L, et al. Safety and efficacy of denosumab for adults and skeletally mature adolescents with giant cell tumour of bone: interim analysis of an open-label, parallel-group, phase 2 study. *Lancet Oncol.* 2013;14(9):901–908. doi:10.1016/S1470-2045(13)70277-8
15. López-Pousa A, Martín Broto J, Garrido T, Vázquez J. Giant cell tumour of bone: new treatments in development. *Clin Transl Oncology.* 2015;17(6):419–430. doi:10.1007/s12094-014-1268-5
16. Broehm CJ, Garbrecht EL, Wood J, Bocklage T. Two cases of sarcoma arising in giant cell tumor of bone treated with denosumab. *Case Rep Med.* 2015;2015:767198. doi:10.1155/2015/767198
17. Tsukamoto S, Righi A, Vanel D, Honoki K, Donati DM, Errani C. Development of high-grade osteosarcoma in a patient with recurrent giant cell tumor of the ischium while receiving treatment with denosumab. *Jpn J Clin Oncol.* 2017;47(11):1090–1096. doi:10.1093/jjco/hyx112
18. Aponte-Tinao LA, Piuzzi NS, Roitman P, Farfalli GL, High-grade Sarcoma A. Arising in a patient with recurrent benign giant cell tumor of the proximal tibia while receiving treatment with denosumab. *Clin Orthop Relat Res.* 2015;473(9):3050–3055. doi:10.1007/s11999-015-4249-2
19. Wang G, Jiang S, Li Z, Dong Y. Denosumab and Sunitinib in the treatment of giant-cell tumor of bone with pulmonary and bone metastases in an adolescent: a case report. *Medicine (Baltimore).* 2019;98(46):e17778. doi:10.1097/MD.00000000000017778
20. Gossai N, Hilgers MV, Polgreen LE, Greengard EG. Critical hypercalcemia following discontinuation of denosumab therapy for metastatic giant cell tumor of bone. *Pediatr Blood Cancer.* 2015;62(6):1078–1080. doi:10.1002/pbc.25393
21. Matcuk GR Jr, Patel DB, Schein AJ, White EA, Menendez LR. Giant cell tumor: rapid recurrence after cessation of long-term denosumab therapy. *Skeletal Radiol.* 2015;44(7):1027–1031. doi:10.1007/s00256-015-2117-5
22. English WR, Lunt SJ, Fisher M, et al. Differential expression of VEGFA isoforms regulates metastasis and response to anti-VEGFA therapy in sarcoma. *Cancer Res.* 2017;77(10):2633–2646. doi:10.1158/0008-5472.CAN-16-0255
23. Zhang J, Dong J, Yang Z, et al. Expression of ezrin, CD44, and VEGF in giant cell tumor of bone and its significance. *World J Surg Oncol.* 2015;13:168. doi:10.1186/s12957-015-0579-5
24. Shibuya M. Vascular endothelial growth factor and its receptor system: physiological functions in angiogenesis and pathological roles in various diseases. *J Biochem.* 2013;153(1):13–19. doi:10.1093/jb/mvs136
25. Li J, Zhou J, Liu Y, Sun X, Song W. Comprehensive treatment for multicentric giant cell tumors of the pelvis and spine using apatinib: a case report and literature review. *J Cancer Res Ther.* 2020;16(5):1020–1026. doi:10.4103/jcrt.JCRT_892_19

Cancer Management and Research

Dovepress

Publish your work in this journal

Cancer Management and Research is an international, peer-reviewed open access journal focusing on cancer research and the optimal use of preventative and integrated treatment interventions to achieve improved outcomes, enhanced survival and quality of life for the cancer patient.

The manuscript management system is completely online and includes a very quick and fair peer-review system, which is all easy to use. Visit <http://www.dovepress.com/testimonials.php> to read real quotes from published authors.

Submit your manuscript here: <https://www.dovepress.com/cancer-management-and-research-journal>