


Comparison of Ultrasound-Guided Modified BRILMA Block with Subcostal Transversus Abdominis Plane Block for Postoperative Analgesia in Laparoscopic Cholecystectomy – A Randomized Controlled Trial

Ravi Saravanan
Rajagopalan Venkatraman 
Urkavalan Karthika

Department of Anesthesiology, SRM
Medical College Hospital and Research
Centre, Kattankulathur, Chennai, 603203,
India

Background and Aims: Subcostal Transversus Abdominis Plane (TAP) block is the standard practice for postoperative analgesia following laparoscopic cholecystectomy. This study aimed to compare the efficacy of modified BRILMA Block (blocking the BRanches of Intercostal nerves at the Level of Mid-Axillary line) with Subcostal TAP block for pain relief following laparoscopic cholecystectomy.

Methods: Sixty cases scheduled for laparoscopic cholecystectomy were randomly divided into two groups: modified BRILMA block (Group B) and Subcostal TAP block (Group T). General anesthesia was standardized for both groups. Blocks were performed with 20 mL of 0.2% Ropivacaine under ultrasound guidance after induction of anesthesia. Patients were administered morphine through patient controlled analgesia (PCA) pump with a bolus dose of 1 mg, 10 min lockout interval, and a basal infusion rate of 0.1 mg/h. The pain was assessed by the Visual Analog Scale (VAS) scores of one to ten. The total morphine consumption, time to first request for rescue analgesia, and VAS scores at rest and with movement, and complications, if any, were recorded.

Results: The morphine consumption in Group B was 5.67 ± 1.98 mg and in Group T was 5.17 ± 1.85 mg, which was found to be statistically insignificant (p -value = 0.317). The time to first request for rescue analgesia was 759.33 ± 80.29 min in Group B which was comparable to 854 ± 93.01 min in Group T and statistically insignificant (p -value = 0.295). The average VAS scores at rest as well as on movement were comparable in both the groups during the entire 24 h postoperative period. No complications were encountered in our study.

Conclusion: Ultrasound-guided modified BRILMA block is equally efficacious as subcostal TAP block in providing postoperative analgesia with similar morphine consumption and no significant difference in VAS scores at rest and movement following laparoscopic cholecystectomy.

Trial Registration Number: CTRI/2020/02/023457.

Keywords: laparoscopic cholecystectomy, intercostal nerves, pain management, patient-controlled analgesia, ultrasound-guided, visual analog scale

Introduction

Laparoscopic cholecystectomy is widely accepted as the gold standard procedure for removal of the gall bladder as it renders many advantages over open surgery like reduced bleeding, less postoperative pain, enhanced respiratory functions, and

Correspondence: Rajagopalan
Venkatraman
Tel +91 9894581455
Email drvenkat94@gmail.com



decreased hospital stay.¹ Pain after laparoscopic cholecystectomy varies in patients ranging from mild to severe, which is usually managed with non-steroidal anti-inflammatory drugs (NSAIDs) and opioids. Anterior abdominal wall blocks are commonly performed nowadays as a part of multimodal analgesia in laparoscopic surgeries. The success rate and safety of these blocks are drastically boosted by the use of ultrasound guidance.

Ultrasound-guided Subcostal Transversus Abdominis Plane (TAP) Block, first explicated by Hebbard et al, is proven to provide adequate analgesia for upper and lower abdominal surgeries.² A local anesthetic (LA) is deposited in the plane between the transversus abdominis and posterior sheath of the rectus muscle in the subcostal region to anesthetize the anterior cutaneous branches of the lower intercostal nerves (T7-T11) which provide unilateral analgesia to the skin, anterior abdominal wall muscles, and parietal peritoneum. Subcostal TAP block is widely practiced for laparoscopic and open surgical procedures in the upper abdomen to provide postoperative pain relief. Serratus - Intercostal interfascial plane block first demonstrated in 2013, blocks the BRanches of the Intercostal nerves at the Level of the MidAxillary line (BRILMA) traversing in this plane at the fourth rib. This block has been effectively used to treat postoperative pain following breast surgeries.^{3,4} Performed at the lower intercostal levels, this modified BRILMA block can render analgesia for upper abdominal surgeries.⁵⁻⁷ There were no Randomized Controlled Trials (RCT) comparing the modified BRILMA block with Subcostal TAP block, and only very few studies are available about the modified BRILMA block to our knowledge. This study was an equivalence trial done to compare the effectiveness of the modified BRILMA block with the subcostal TAP block for postoperative analgesia in laparoscopic cholecystectomy surgeries.

We hypothesized that the modified BRILMA block would provide effective analgesia equivalent to subcostal TAP which is widely performed nowadays for both open and laparoscopic cholecystectomies. The primary objective of our study was to compare the consumption of morphine in the 24 h postoperative period between the groups. The secondary objectives were to compare the time to request for first rescue analgesia, VAS scores at rest and with movement, and complications in the postoperative period.

Methods

After obtaining SRM Medical College Hospital and Research Centre ethical committee approval, this study was performed on patients undergoing laparoscopic cholecystectomy from

20.02.2020 to 20.01.2021 in a tertiary care medical college hospital. This study was registered in Clinical Trials Registry – India (CTRI/2020/02/023457) on 01.02.2020 with patient enrollment started on 20.02.2020 (<http://ctri.nic.in/Clinicaltrials/regtrial.php?trialid=39139andEncHid=13887.38042andmodid=1andcompid=19>) Patients were explained regarding the study, interpretation of the visual analog scale (VAS) scores, and informed consent was obtained. This study was conducted following the ethical guidelines of the declaration of Helsinki. Patients of age group 18 to 60, weighing between 50 and 100 kg and belonging to ASA physical status I and II were included in the study. Those who were unwilling to participate, having an allergy to LA, and having ailments like coagulation abnormalities, cardiac, hepatic, and renal diseases were excluded from the study.

Sixty patients who underwent elective laparoscopic cholecystectomy under general anesthesia were randomized into two groups: group B (modified BRILMA block) and group T (subcostal TAP block) by computer-generated random numbers and concealment done by sealed, opaque envelope method. The monitors like an electrocardiogram, non-invasive blood pressure (NIBP), pulse oximetry, temperature, and capnography were attached and baseline vital parameters were noted. All the patients received general anesthesia with endotracheal intubation which was standardized for both groups. Fentanyl 2 µg/kg iv was administered five minutes before intubation. Patients were induced with Propofol 2mg/kg and the muscle relaxant used was vecuronium 0.1 mg/kg. Anesthesia was maintained with air/oxygen, sevoflurane, and vecuronium.

After induction of anesthesia, the patients received either ultrasound-guided modified BRILMA block (in Group B) or Subcostal TAP block (in Group T). An ultrasound machine (Logic V2, GE Medical Systems, Jiangsu, China) with a (5 to 13 Hz) high-frequency linear probe and 100mm, 22 G stimuplex needle (B Braun) were used to perform the blocks. All the blocks were performed after induction of anesthesia under stringent aseptic precautions. For performing modified BRILMA block, the patient was placed in left lateral decubitus with the probe in the sagittal plane at the mid-axillary line at the level of the eighth rib on the right side. The fascial plane between the serratus anterior muscle and the external intercostal muscle was identified. The needle was introduced by an in-plane technique and after confirmation by hydrodissection, 20 mL of ropivacaine 0.2% was administered into the serratus-intercostal fascial plane under ultrasound guidance to visualize the spread of the LA solution (Figure 1).

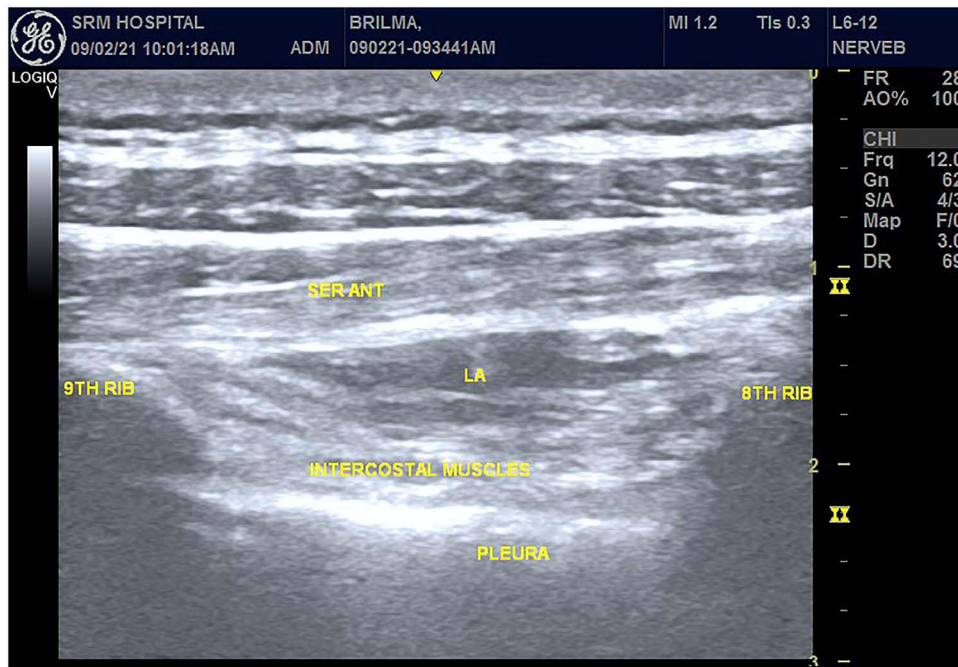


Figure 1 Modified BRILMA Block.
Abbreviations: Ser Ant, Serratus Anterior; LA, Local Anesthetic.

Ultrasound-guided Subcostal TAP block was performed in the supine position with the probe placed below the xiphisternum in the transverse plane and moved laterally parallel to the right costal margin to visualize the muscle layers of the anterior abdominal wall and by in-plane technique. The

subcostal TAP plane (between the posterior sheath of rectus abdominis and transversus abdominis muscles) was confirmed by hydro dissection and 20 mL of ropivacaine 0.2% was administered (Figure 2). All the blocks were done by a single experienced anesthesiologist.

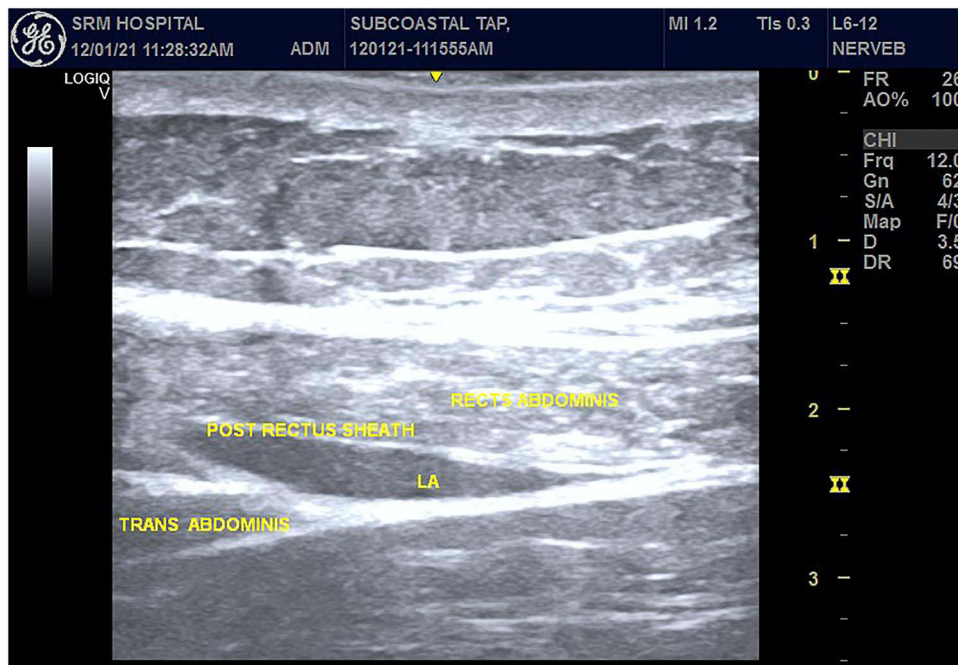


Figure 2 Subcostal Transversus Abdominis Plane Block.
Abbreviation: LA, Local Anesthetic.

Intravenous crystalloid 20mL/kg was administered before pneumoperitoneum was created. End-tidal carbon dioxide was maintained between 35 and 40 mm Hg by adjusting the ventilator settings. A rise in Mean Arterial Pressure (MAP) or heart rate above 20% of the baseline value was treated with an additional dose of fentanyl 1 µg/kg. Hypertension refractory to deepening the plane of anesthesia was treated with nitroglycerine infusion. Hypotension (MAP less than 20% of baseline value) was managed with intravenous fluid boluses and ephedrine. Ondansetron 4 mg and Paracetamol 1 g were administered intravenously during surgical closure in both groups. At the end of the surgery, the patients were extubated and monitored in Post Anesthesia Care Unit (PACU). The duration of surgery (from skin incision to closure) and duration of anaesthesia (time taken from induction to extubation) were recorded. All patients received Paracetamol 1g every 6h intravenously for 24h as part of multimodal analgesia.

The anesthesiologist performing the block took no further part in the study. The patients in PACU were monitored by another anesthesiologist who was blinded to the study groups allotted. VAS scoring was used to assess the pain with a scale of one to ten, which was measured every two hours at rest and every fourth hour during movement (from supine to sitting position). Morphine was administered through patient-controlled analgesia (PCA) pump with a basal infusion rate of 0.1 mg/h, a bolus dose of 1 mg, and 10 min lockout interval. The time to request for first rescue analgesia, which was the time taken from the completion of the block to the first request for postoperative analgesia (when VAS \geq 3) was noted.⁸ The total morphine consumption in the 24h postoperative period was noted and compared between the groups.

Any complications related to subcostal TAP blocks like intraperitoneal or intravascular injection, LA toxicity, or hematoma formation were noted. And also, patients were observed for complications of BRILMA block like pneumothorax, intravascular injection, or LA toxicity. The adverse effects related to morphine infusions like nausea and vomiting, sedation, pruritus, constipation, urinary retention, and respiratory depression were also noted.

We calculated the sample size using the following formula with a 95% confidence interval and 80% power of the study. $N = [Z\alpha/2 + Z\beta] \times 2 \times \sigma^2/d^2$, where $Z\alpha/2$ is

the critical value of the normal distribution at $\alpha/2$ (for a confidence level of 95%, α is 0.05 and the critical value is 1.96), $Z\beta$ is the critical value of the normal distribution at β (power 80%, β is 0.2 and the critical value is 0.84), σ^2 is the population variance, and d is the difference that we would like to detect. Using the aforementioned formula, we arrived at a total sample size of $N=60$ (30 subjects in each group).

The data were entered in Microsoft Excel spreadsheet 2016 and analyzed with a statistical package for social sciences (SPSS version 27). The distribution of data was normal and no skewness was found. The data were described in means and proportions and descriptive statistics were done. Further, the Chi-square test was used to analyze the categorical data (sex, ASA physical status) and an unpaired Student's *t*-test was used to analyze the numerical data (age, weight, duration of analgesia, morphine consumption, VAS scores). A P-value < 0.05 was considered to be statistically significant.

Results

Sixty-six patients were assessed for eligibility and enrolled in the study. After the attrition of six cases, sixty cases were finally analyzed with 30 in each group. The flow of the patients in both groups was depicted in the CONSolidated Standards of Reporting Trials (CONSORT) diagram (Figure 3). Both the groups were similar in terms of demographic data like age, sex, and weight. ASA physical status and duration of surgery were also comparable between the groups. The demographic results are tabulated in Table 1.

The morphine requirement in the postoperative period was similar in both groups. The consumption of Morphine in Group B was 5.67 ± 1.98 mg and Group T was 5.17 ± 1.85 mg, which was found to be statistically insignificant with a p-value of 0.316. The time to request for first rescue analgesia was 759.33 ± 80.29 min in group B which was comparable to 854 ± 93.01 min in group T and statistically insignificant (p-value = 0.295). The results are summarized in Table 2.

The average VAS scores at rest recorded second hourly were comparable in both the groups during the entire 24 h postoperative period (Figure 4). There was also no significant difference in VAS scores at movement, recorded fourth hourly between the groups (Figure 5). There were no block failures or complications (related to block and morphine infusion) in both groups.

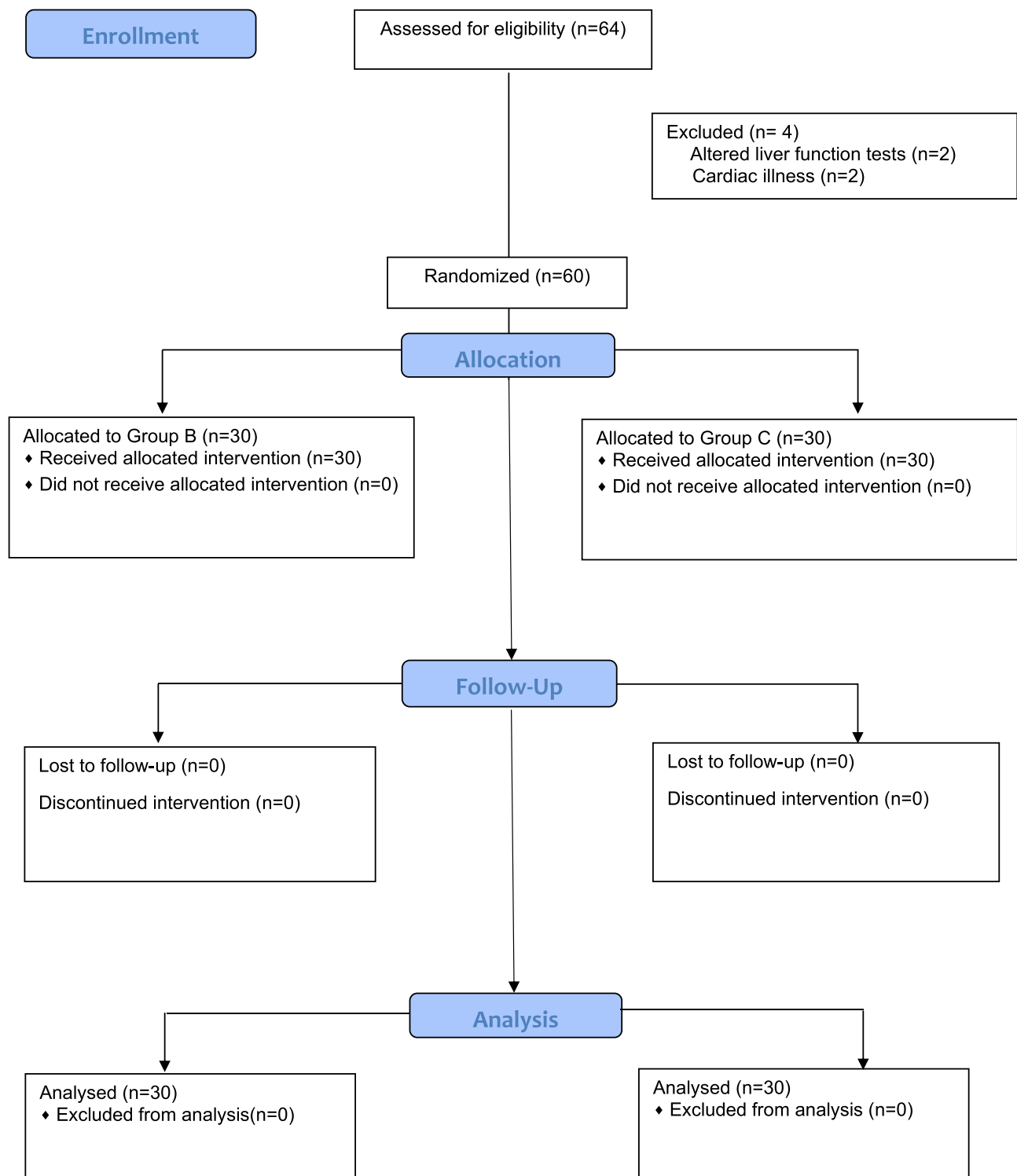


Figure 3 CONSolidated Standards Of Reporting Trials (CONSORT) flow chart.

Discussion

Modified BRILMA block is a less explored regional anesthetic technique and a promising block for postoperative analgesia in the unilateral anterior chest wall and upper abdominal surgeries. This has the advantage that the block can be performed

even after surgical skin closure as well as in the postoperative period, with the sutures or staples in the laparoscopic port site. But, in the subcostal TAP block, the drug is deposited in the plane through which laparoscopic ports were made and hence, need to be performed before the commencement of surgery.

Table 1 Demographic Variables

| Parameters | Group B (n = 30) | Group T (n = 30) | P-value |
|---|---------------------|---------------------|---------|
| Age (years) | 47.8 ± 11.12 | 42.8 ± 11.09 | 0.086* |
| Sex (M/F) | 46.6%/ 53.4% | 40%/ 60% | 0.602* |
| ASA (I/II) | 70%/ 30% | 73.3%/ 26.6% | 0.082* |
| Co-morbidities DM/ HTN/ Liver diseases | 3/ 2/ 4 | 3/ 1/ 4 | 0.275* |
| Body mass index | 23.773 ± 0.955 | 24.103 ± 0.887 | 0.171* |
| Duration of anesthesia (minutes) | 123 ± 51.03 | 119.5 ± 44.88 | 0.779* |
| Duration of surgery (minutes) | 92.37 ± 10.97 | 89.51 ± 9.26 | 0.279* |

Notes: Values are in Mean ± Standard deviation (SD)/percentage of patients. * p-value not significant.

Abbreviations: ASA, American Society of Anesthesiologists; DM, Diabetes mellitus; HTN, Hypertension.

Table 2 Comparison of Analgesic Data

| Parameters | Group B (n = 30) | Group T (n = 30) | P-value |
|---|---------------------|---------------------|---------|
| Morphine consumption (mg) | 5.67 ± 1.98 | 5.17 ± 1.85 | 0.317* |
| Time to first request for rescue analgesia (min) | 759.33 ± 80.29 | 854 ± 93.01 | 0.295* |

Notes: Values are in Mean ± Standard deviation (SD). * p-value not significant.

There was no RCT comparing the efficacy of modified BRILMA with subcostal TAP block in laparoscopic cholecystectomy surgeries. We found that the modified BRILMA block provided effective analgesia compared to the subcostal TAP block in terms of morphine consumption in the postoperative period, duration of analgesia, VAS scores, and complications.

We found no significant difference in analgesic consumption between the groups. Though there were no studies comparing Subcostal TAP with modified BRILMA block, the analgesic consumption was found to be considerably reduced in both the block techniques studied separately. The morphine consumption following subcostal TAP block in laparoscopic cholecystectomy was 4.72 ± 0.94 mg in another study, well matching our results.⁹ Eldawlatly et al observed lesser morphine consumption in laparoscopic cholecystectomy patients who received subcostal TAP block than the control group (22.8 mg vs 10.5 mg).¹⁰ Shin et al demonstrated lesser fentanyl consumption in patients receiving subcostal TAP in laparoscopic cholecystectomies.¹¹

In a similar study on laparoscopic sleeve gastrectomy surgeries, Ibrahim and Shaama observed a reduction of morphine consumption in the subcostal TAP group when compared to the control group (16.76 mg vs 24.76 mg).¹² In a study by Fernandez Martin et al on modified BRILMA block in supraumbilical open surgeries like cholecystectomy and gastrectomy, they found that the intraoperative fentanyl consumption and postoperative morphine consumption were significantly reduced following a preincisional block.⁷ In various other studies, Serratus-Intercostal interfascial plane block effectively reduced the postoperative analgesic consumption in nonreconstructive breast surgeries,^{3,4} open cholecystectomies,⁵ and open gastrectomy.⁶

In our study, we found that Subcostal TAP provided analgesia for a longer duration of 854 ± 93.01 min compared to the modified BRILMA group (759.33 ± 80.29 min) but with no statistically significant difference (p-value = 0.294). Venkatraman et al observed

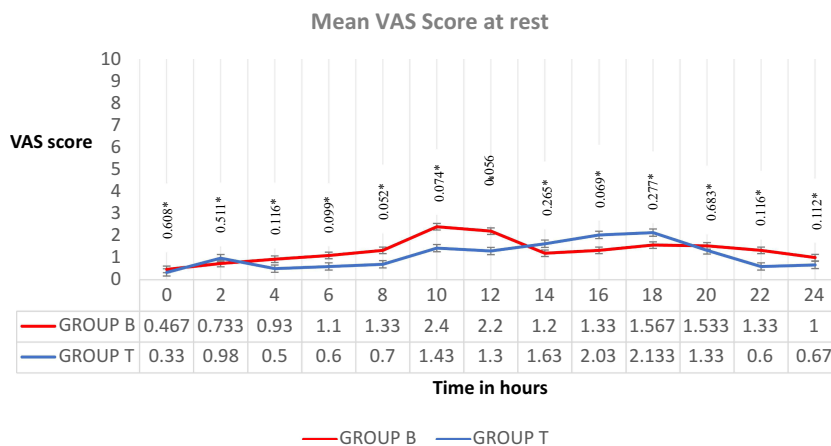


Figure 4 VAS score at rest. Values are in mean with p-value at the top. * p-value (not significant).

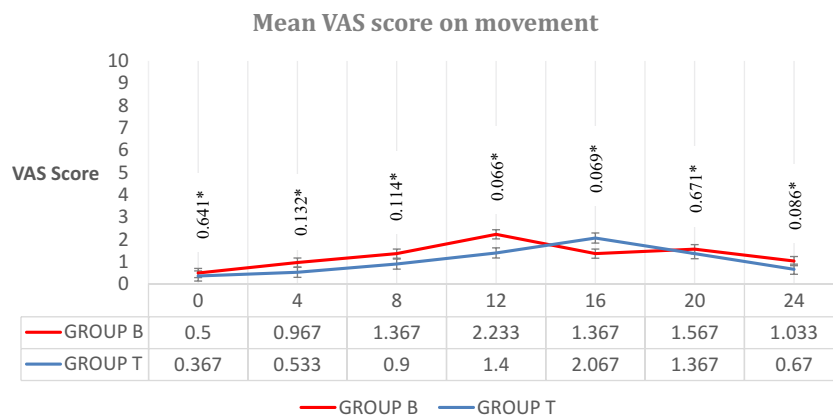


Figure 5 VAS score on movement. Values are in mean with p-value at the top. * p-value (not significant).

a postoperative analgesia duration of 867.24 ± 135.83 min with subcostal TAP block in laparoscopic cholecystectomy, which was similar to our study.⁸ In a study by Suseela et al on laparoscopic cholecystectomies, subcostal TAP provided a longer duration of analgesia for 510 min compared to 292 min in the port site infiltration group.¹³ On comparing with our study, Kamhawy et al demonstrated a lesser duration of analgesia for 248 min in open cholecystectomy surgeries with subcostal TAP, which was quite an invasive procedure compared to laparoscopy.¹⁴

Patients in both groups had a comparable reduction in VAS pain scores in the postoperative period in this study. Vrsajkov et al observed that the mean pain scores by Numerical Rating Scale (NRS) were significantly lesser in patients who received subcostal TAP than the standard analgesia group at every time point following laparoscopic cholecystectomy.¹⁵ In various other studies on laparoscopic cholecystectomy, subcostal TAP reduced VAS pain scores significantly more than port site infiltration¹⁶ and posterior TAP block.¹⁷ Subcostal TAP was also found comparable to paravertebral block in reducing VAS scores after open cholecystectomy.¹⁴ The efficacy of Brilma block has been demonstrated in reducing pain scores after supraumbilical open surgeries⁷ and breast surgeries.^{3,4}

We have not encountered any block failures or block-related complications in both groups, as the blocks were performed by experienced anesthesiologists under ultrasound guidance. There were many studies on the safety of subcostal TAP.^{8–10} BRILMA block was also found to be safe in many studies with no complications.^{3,4} In our study, we found that the modified BRILMA block provided analgesia as effective as subcostal TAP block with no difference in complications. However, modified

BRILMA block has added advantages like the ability to perform even after surgery and also can be repeated in the postoperative period, if warranted.

There are a few limitations to our study. We did not encounter any complications or failures in blocks, as the blocks were performed by experienced anesthesiologists under ultrasound guidance. The anesthesiologist took adequate precautions and advanced only when the tip of the needle is visualized. The ability of the patients to ambulate in the postoperative period and discharge criteria of the patients were not compared in our study. We included only ASA I and II patients in the age group of 18 to 60 years. We did not study the effectiveness of both the blocks in high-risk individuals where it may be more beneficial. But we expect it to be as effective as in others.

Conclusion

Ultrasound-guided modified BRILMA block is as effective as subcostal TAP block with similar morphine consumption, time to first request for rescue analgesia, and VAS scores at rest and movement following laparoscopic cholecystectomies.

Data Sharing Statement

The data used to support the findings of this study are available from the corresponding author upon request.

Disclosure

The authors declare no conflicts of interest in this work.

References

1. Bisgaard HK, Jacob Rose T. Pain and convalescence after laparoscopic cholecystectomy. *Eur J Surg*. 2001;167(2):84–96. doi:10.1080/110241501750070510

2. Hebbard PD, Barrington MJ, Vasey C. Ultrasound-guided continuous oblique subcostal transversus abdominis plane blockade: description of anatomy and clinical technique. *Reg Anesth Pain Med.* 2010;35(5):436–441. doi:10.1097/AAP.0b013e3181e66702
3. Diéguez García P, Fajardo Pérez M, López Álvarez S. Ultrasound-assisted approach to blocking the intercostal nerves in the mid-axillary line for non-reconstructive breast and axilla surgery. *Rev Esp Anesthesiol Reanim.* 2013;60(7):365–370. doi:10.1016/j.redar.2013.04.002
4. González-García J, González-Bada A, López-Ramos JM, Echevarria-Correas MA, Muñecas-Herreras MBG, Aguilera-Celorrio L. Prospective, randomized comparative study of ultrasound-guided blocking of the lateral cutaneous branches of the intercostal nerves versus conventional analgesia in non-reconstructive breast surgery. *Rev Esp Anesthesiol Reanim Engl Ed.* 2019;66(3):137–143. doi:10.1016/j.redar.2018.11.001
5. Fernández Martín MT, López Álvarez S, Mozo Herrera G, Platero Burgos JJ. Ultrasound-guided cutaneous intercostal branches nerves block: a good analgesic alternative for gallbladder open surgery. *Rev Esp Anesthesiol Reanim.* 2015;62(10):580–584. doi:10.1016/j.redar.2015.02.011
6. Fernández-Martin MT, López-álvarez S, Fajardo-López M. Interfascial intercostal nerves block: alternative to epidural analgesia in open gastrectomy? Report on 4 clinical cases. *Colomb J Anesthesiol.* 2018;257–261.
7. Fernández Martín MT, López Álvarez S, Pérez Herrero MA. Serratus-intercostal interfascial block as an opioid-saving strategy in supra-umbilical open surgery. *Rev Esp Anesthesiol Reanim Engl Ed.* 2018;65(8):456–460. doi:10.1016/j.redar.2018.03.007
8. Venkatraman R, Karthik K, Belinda C, Balaji R. A randomized observer-blinded controlled trial to compare pre-emptive with postoperative ultrasound-guided mandibular nerve block for postoperative analgesia in mandibular fracture surgeries. *Local Reg Anesth.* 2021;14:13–20.
9. Venkatraman R, Saravanan R, Dhas M, Pushparani A. Comparison of laparoscopy-guided with ultrasound-guided subcostal transversus abdominis plane block in laparoscopic cholecystectomy - a prospective, randomised study. *Indian J Anaesth.* 2020;64(12):1012–1017. doi:10.4103/ija.IJA_528_20
10. El-Dawlatly AA, Turkistani A, Kettner SC, et al. Ultrasound-guided transversus abdominis plane block: description of a new technique and comparison with conventional systemic analgesia during laparoscopic cholecystectomy. *Br J Anaesth.* 2009;102(6):763–767. doi:10.1093/bja/aep067
11. Shin HJ, Oh AY, Baik JS, Kim JH, Han SH, Hwang JW. Ultrasound-guided oblique subcostal transversus abdominis plane block for analgesia after laparoscopic cholecystectomy: a randomized, controlled, observer-blinded study. *Minerva Anesthesiol.* 2014;80(2):185–193.
12. Ibrahim M, Shamaa HE. Efficacy of ultrasound-guided oblique subcostal transversus abdominis plane block after laparoscopic sleeve gastrectomy: a double blind, randomized, placebo controlled study. *Egypt J Anaesth.* 2014;30(3):285–292. doi:10.1016/j.egja.2014.01.003
13. Suseela I, Anandan K, Aravind A, Kaniyil S. Comparison of ultrasound-guided bilateral subcostal transversus abdominis plane block and port-site infiltration with bupivacaine in laparoscopic cholecystectomy. *Indian J Anaesth.* 2018;62(7):497–501. doi:10.4103/ija.IJA_55_18
14. Kamhawy G, El-Taher E, Abdelrahman M. A comparison of oblique subcostal transversus abdominis plane block versus thoracic paravertebral block for postoperative analgesia after open cholecystectomy. *Egypt J Anaesth.* 2017;33(4):323–329. doi:10.1016/j.egja.2017.08.007
15. Vrsajkov V, Mančić N, Mihajlović D, Miličević ST, Uvelin A, Vrsajkov JP. Subcostal transversus abdominis plane block can improve analgesia after laparoscopic cholecystectomy. *Braz J Anesthesiol Engl Ed.* 2018;68(2):149–153.
16. Tolchard S, Davies R, Martindale S. Efficacy of the subcostal transversus abdominis plane block in laparoscopic cholecystectomy: comparison with conventional port-site infiltration. *J Anaesthesiol Clin Pharmacol.* 2012;28(3):339–343. doi:10.4103/0970-9185.98331
17. Khan KK, Khan RI. Analgesic effect of bilateral subcostal tap block after laparoscopic cholecystectomy. *J Ayub Med Coll Abbottabad.* 2018;30(1):12–15.

Local and Regional Anesthesia

Dovepress

Publish your work in this journal

Local and Regional Anesthesia is an international, peer-reviewed, open access journal publishing on the development, pharmacology, delivery and targeting and clinical use of local and regional anesthetics and analgesics. The journal welcomes submitted papers covering original research, basic science, clinical studies, reviews &

evaluations, guidelines, expert opinion and commentary, case reports and extended reports. The manuscript management system is completely online and includes a very quick and fair peer-review system, which is all easy to use. Visit <http://www.dovepress.com/testimonials.php> to read real quotes from published authors.

Submit your manuscript here: <https://www.dovepress.com/local-and-regional-anesthesia-journal>