


Surgical Treatment of Postoperative Abdominal Metastases of Hepatocellular Carcinoma: 10-Year Experience in a Single Center

Jiong-Ze Fang*
Yong Yang *
Hong-Da Zhu
Jian-Nan Sun
Hong-Chao Mi
Cai-De Lu

Department of Hepatopancreatobiliary Surgery, Ningbo Medical Centre Lihuli Hospital, Ningbo University, Ningbo, Zhejiang, People's Republic of China

*These authors contributed equally to this work

Objective: The significance of surgical treatment was analyzed by retrospectively collecting data on the re-resection of intra-abdominal metastases after hepatocellular carcinoma (HCC) surgery in our center over the past 10 years.

Methods: The clinical and pathological data of 15 patients who developed intra-abdominal metastases after HCC resection and underwent re-resection from January 2010 to January 2020 were collected to analyze the patients' characteristics and prognosis.

Results: Of the 15 cases of abdominal metastasis, the majority (8 cases) had greater omental metastasis. There were 4 cases of mesenteric metastases, 1 case of abdominal wall metastasis, 1 case of mesenteric plus rectal wall metastasis, and 1 case of colon and mesenteric metastasis. The 1-year, 3-year, and 5-year disease-free survival (DFS) rates were 31.1%, 23.3%, and 11.7%, respectively. The 1-year, 3-year, and 5-year overall survival rates were 93.3%, 28.7%, and 19.1%, respectively. Three patients are currently surviving disease-free, with survival times of 130.4 months, 43.3 months, and 9.4 months, respectively.

Conclusion: Although the current guidelines do not recommend surgical resection as the preferred treatment for postoperative abdominal metastases of HCC, surgical resection is recommended for patients with limited or solitary metastasis in the abdominal cavity.

Keywords: hepatocellular carcinoma, postoperative recurrence of HCC, intra-abdominal metastasis, disease-free survival, overall survival

Introduction

Hepatocellular carcinoma (HCC) is a common malignant tumor in China. According to the latest report of the International Agency for Research on Cancer of the World Health Organization, there were 410,000 new cases of HCC in China and 390,000 deaths in 2020, which is a serious threat to public health.¹ Although targeted and immunotherapy for HCC have made great progress in recent years, surgical resection is still the most effective way to treat HCC, and postoperative recurrence is the main factor affecting the overall survival (OS) time of patients. Most postoperative recurrences of HCC are intrahepatic; pulmonary metastases account for the highest proportion of extrahepatic metastases, and intra-abdominal metastases are relatively rare, with an incidence of 2%-16%.² Currently, it is generally believed that intra-abdominal metastasis of HCC indicates end-stage HCC, and the median survival time is generally less than 1 year.³ For these patients, there is currently no unified treatment standard. Staging of HCC with abdominal metastasis, according to the 8th edition of the cancer staging system issued by the International Union for Cancer Control and American

Correspondence: Cai-De Lu
Tel/Fax +86 574- 55835600
Email lucaide@nbu.edu.cn

Received: 4 August 2021
Accepted: 9 November 2021
Published: 20 November 2021



Joint Committee on Cancer (AJCC),⁴ abdominal metastasis belongs to stage IV, or Barcelona stage C,⁵ targeted therapy such as sorafenib is preferred. According to the *Guidelines for the Diagnosis and Treatment of Primary HCC in China* (2019 edition), HCC with abdominal metastasis belongs to stage IIIb,⁶ the first choice for treatment is systemic therapy, transcatheter arterial chemoembolization (TACE), or radiotherapy. However, it has also been reported that the median survival time of patients with abdominal metastasis after resection is as long as 34.5 months. In view of this situation, we retrospectively analyzed the HCC cases with postoperative abdominal metastasis that were surgically resected in our center over the past 10 years. Our treatment experience is summarized below in the hope that it will be helpful in clinical work.

Objects and Method

Case Data

From January 2010 to January 2020, a total of 2178 cases of HCC were resected in the Department of Hepatobiliary and Pancreatic Surgery, Li Huili Hospital of Ningbo Medical Center, China. Of these, 30 cases with intra-abdominal metastases after HCC resection were surgically resected; 12 of these cases were excluded because resection was performed for biopsy, and 3 cases of abdominal lymph node metastasis were excluded. The remaining 15 cases of HCC with intra-abdominal metastasis after resection that underwent re-resection were included in this study (Figure 1). The inclusion criteria were as follows: (1) patients older than 18 years of age; (2) patients with intra-abdominal metastasis of HCC confirmed by pathology and with complete surgical resection of the metastatic lesions; and (3) patients with no severe heart or lung diseases. The exclusion criteria were as follows: (1) patients with abdominal metastases pathologically confirmed as non-HCC, including cholangiocarcinoma or mixed HCC; (2) patients undergoing resection for abdominal metastasis biopsy or palliative resection; and (3) patients with a previous history of other malignant tumors. This study was approved by the Ethics Committee of Ningbo Medical Centre Lihuli Hospital (KY2021PJ062), and informed consent for the review of medical records from patient was waived because of the retrospective nature of the study. All the patients or the immediate family members of liver donors signed informed consent statement for the liver donations. The study protocol also complied with the ethical standards established by the

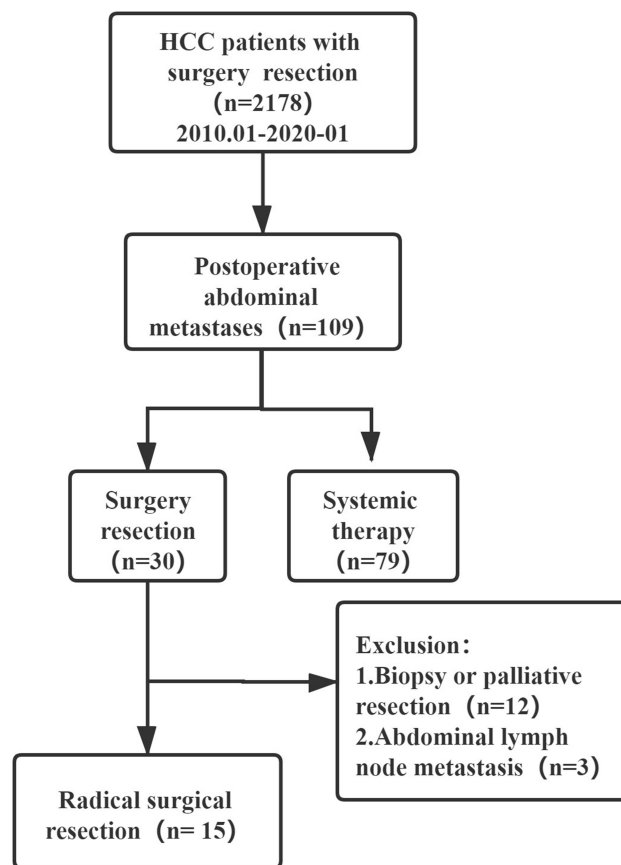


Figure 1 Patient flow diagram.

Declaration of Helsinki in terms of patient data confidentiality. In this study, donor livers were sourced from people who volunteered to donate their organs after death; the organs were distributed through the Chinese human organ distribution and sharing computer system, no organs came from condemned prisoners, and it was conducted in accordance with the Declaration of Istanbul.

Surgical Methods

All 15 patients had undergone radical resection of HCC in the past, including 2 cases of laparoscopic HCC resection, 12 cases of open liver resection, and 1 case of allogeneic liver transplantation. Laparotomy was performed in 14 cases of abdominal metastases, and 1 patient underwent laparoscopic resection of abdominal metastases. All patients who underwent radical resection did not receive systemic therapy.

Postoperative Follow-Up and Treatment

After discharge, the patients were followed up by telephone or at outpatient or inpatient visits to collect information about their general condition, the recurrence and

Table 1 Clinicopathologic Characteristics of the 15 Patients with Resected Peritoneal Dissemination

Case	Operation Time	Age (Years)	Sex	ECOG	Child-Pugh Grade	Site of Recurrence	Tumor Number	Metastatic Tumor Size (cm)	Pathological Type	Intrahepatic Recurrence	Treatment	Blood Loss (mL)	Differentiation
1	2017.06	60	Male	0	A	Mesentery	1	10.0	HCC	No	Resection of implantation	200	Well
2	2017.03	49	Male	1	A	Omentum	1	3.0	HCC	Yes	Liver transplantation + Resection of implantation	1000	Moderate
3	2015.12	55	Male	1	A	Abdominal wall	3	1	HCC	No	Resection of implantation	100	Moderate
4	2012.04	57	Male	0	A	Omentum	1	6	HCC	No	Resection of implantation	100	Moderate
5	2012.02	60	Male	0	A	Mesentery	2	4	HCC	Yes	Liver cancer resection + Resection of implantation	400	Moderate
6	2012.11	68	Male	0	A	Mesentery	1	2.5	HCC	No	Resection of implantation	100	Poor
7	2010.04	27	Male	0	A	Omentum	1	7	HCC	Yes	Liver cancer resection + Resection of implantation	300	Moderate
8	2012.11	47	Male	0	A	Mesentery	2	6.8	HCC	No	Resection of implantation + Segmental resection of jejunum	300	Moderate
9	2010.08	57	Male	0	A	Omentum	1	3.6	HCC	Yes	Liver cancer resection + Resection of implantation	400	Moderate
10	2015.05	51	Male	0	A	Mesentery + rectum	2	1.8	HCC	No	Resection of implantation + Partial rectal resection	100	Moderate
11	2017.03	53	Male	0	A	Omentum	2	5.5	HCC	No	Resection of implantation	20	Poor

(Continued)

Table 1 (Continued).

Case	Operation Time	Age (Years)	Sex	ECOG	Child-Pugh Grade	Site of Recurrence	Tumor Number	Metastatic Tumor Size (cm)	Pathological Type	Intrahepatic Recurrence	Treatment	Blood Loss (mL)	Differentiation
12	2017.04	61	Male	1	A	Omentum	3	3.3	HCC	No	Resection of implantation	100	Poor
13	2017.11	47	Male	1	A	Right colon	2	1	HCC	Yes	Resection of implantation + liver cancer resection+Right colectomy	400	Moderate
14	2020.04	56	Male	0	A	Omentum	1	2.1	HCC	No	Resection of implantation	100	Poor
15	2017.01	46	Male	0	A	Omentum	4	1.2	HCC	Yes	Resection of implantation	1500	Moderate

Abbreviation: ECOG, Eastern Cooperative Oncology Group.

metastasis of HCC, and survival. The methods used to monitor the recurrence and metastasis of HCC included serum α -fetoprotein (AFP) detection (once a month for 6 months after surgery, once every 2 months from 6 months to 1 year after surgery, and once every 3 months after 1 year) and abdominal hepatobiliary B-ultrasound (once a month for 6 months after surgery and once every 3 months after 6 months), chest computed tomography (CT) and abdominal enhanced magnetic resonance imaging (MRI) examinations (once every 3 months for 1 year after surgery and once every 6 months after 1 year). Patients diagnosed with postoperative intrahepatic recurrence or extrahepatic metastasis of HCC were treated with surgical resection, intervention, and targeted treatment according to the specific conditions. The start of the follow-up was the day of the abdominal metastasis resection, and the end was January 31, 2021. The disease-free survival (DFS) time was the time between the start of surgery and tumor recurrence or the last follow-up. The OS time was defined as the time from surgery to death or to the last follow-up. The follow-up time ranged from 8 to 130 months, with an average of 33.2 months.

Statistical Analysis

Data analysis in this study was performed using SPSS software, version 22.0 (IBM Inc., Armonk, NY, USA). The survival analysis was performed using the Kaplan-Meier method. $P < 0.05$ was considered statistically significant.

Result

Patient Demographic Characteristics and General Information

The 15 patients were all males, with a median age of 55 (47, 60) years old. The Eastern Cooperative Oncology Group (ECOG) score was 0 in 11 cases and 1 in 4 cases. The Child-Pugh scores were all grade A. All patients underwent repeat surgery due to recurrence after the first resection of HCC; for 11 cases, the surgery was the first abdominal resection of metastases; for 3 cases, it was the second resection of metastases; and for 1 case, it was the third resection. Regarding the surgical methods, 14 cases underwent laparotomy, and 1 case underwent laparoscopic surgery. There were 8 cases of simple metastasis resection and 5 cases of combined liver metastasis resection; of the combined resections, 1 patient underwent liver transplantation; 1 patient underwent HCC resection, abdominal metastasis resection,

Table 2 Laboratory Data of the 15 Patients with Resected Peritoneal Dissemination

Case	Hb (g/L)	HBsAg	PT (Sec)	Albumin (g/L)	Bil (T) (μmol/L)	ALT (U/L)	AST (U/L)	AFP (μg/L)
1	156	+	11.4	40.0	15.6	11	15	1.6
2	164	+	12.9	51.5	34	31	33	5.2
3	151	+	11.2	46.0	14.7	32	37	268.9
4	162	+	11.4	39.5	11.2	18	13	2.7
5	143	–	12.3	39.3	10.3	24	23	3.4
6	119	+	12.7	38.9	11.0	12	16	136.5
7	143	+	10.7	42.0	8.3	15	13	423.6
8	136	+	11.6	38.9	11.2	42	40	564.3
9	126	+	12.3	39.9	7.9	23	21	615.2
10	137	+	11.4	40.2	6.3	12	16	113.6
11	129	+	11.6	41.9	5.6	22	26	672.7
12	134	–	12.6	38.7	24.8	21	53	37.9
13	151	–	11.1	38.8	6.0	16	17	292.1
14	147	+	11.6	40.0	9.0	14	20	2411.2
15	132	–	12.6	43.5	8.6	31	45	85.9

Abbreviations: Hb, hemoglobin; PT, prothrombin time; Bil, bilirubin; T, total; ALT, alanine aminotransferase; AST, aspartate aminotransferase; AFP, alfa fetoprotein.

and right colectomy; 1 patient underwent abdominal metastasis resection and Segmental resection of jejunum; and 1 patient underwent abdominal metastasis resection and partial rectal resection (Table 1).

Preoperative Laboratory Examination

All 15 patients underwent routine laboratory tests before surgery, including routine blood, biochemical, hepatitis B virus markers, serum AFP, and coagulation function tests. Among them, 11 patients had hepatitis B infection. None of the patients showed significant abnormalities in the blood routine and biochemistry; 11 patients had higher than normal preoperative serum AFP, and the highest AFP level was 2411.2 ug/L (Table 2).

Pathological Characteristics of the First Surgery

Among the 15 patients, 13 underwent laparotomy, and 2 underwent laparoscopic surgery. The resected tumors had a median diameter of 4.5 (2.5, 5.7) cm. The degree of tumor differentiation was as follows: 1 case with high differentiation, 10 cases with moderate differentiation, and 4 cases with poor differentiation. Twelve patients had solitary tumors, and 3 patients had multiple tumors. Regarding the microvascular invasion (MVI) classification, there were 2 cases of grade 0, 8 cases of grade 1, and 5 cases of grade 2. At the time of the first surgery, 3 patients had liver tumors that had broken through the liver capsule, 12 patients had tumor resection margins that

exceeded 1 cm, and 3 patients had resection margins within 1 cm. There were 6 cases of grade 2 liver fibrosis, 6 cases of grade 3 liver fibrosis, and 3 cases of grade 4 liver fibrosis. Two patients had a history of hepatic rupture (Table 3).

Distribution Characteristics of Abdominal Metastatic Tumors

Eight patients were diagnosed with abdominal metastasis after HCC resection based on enhanced CT (Figure 2). Five patients had no abdominal metastasis on MRI (Figure 3) examination; 2 patients had no abdominal metastasis on preoperative MRI and positron emission tomography (PET)-CT examination, but intra-abdominal metastasis of HCC was found during surgery. Greater omental metastasis accounted for the majority of the metastasis sites, with a total of 8 cases. There were 4 cases of mesenteric metastases, 1 case of abdominal wall metastasis, 1 case of mesentery plus rectum metastasis, and 1 case of right colon metastasis. The largest number of metastases was 4. There were 7 cases of solitary metastasis, 5 cases of 2 metastases, 2 cases of 3 metastases, and 1 case of 4 metastases (Figures 1–3).

Survival Prognosis Analysis

For 2178 patients who were treated by resection, the 1-, 3-, and 5-year DFS rates were 79.4%, 54.4%, and 53.8%, respectively, and metastases-free survival rates were 82.9%, 62.9%, and 45.3%, respectively. During the follow-up period, the postoperative 1-, 3-, and 5-year DFS

Table 3 Pathological Characteristics of the First Surgery

Case	Size(cm)	Treatment	Differentiation	Satellite Lesions	MVI	Liver Capsule	Section Margin (cm)	Stage of Hepatic Fibrosis	Rupture
1	6.5	Right lobectomy	Well	+	M1	Complete	>1	S3	No
2	4.8	Left lateral segmentectomy	Moderate	-	M1	Complete	<1	S4	No
3	6.5	Liver transplantation	Moderate	+	M0	Complete	>1	S4	No
4	4.5	Left lobectomy	Moderate	-	M1	Complete	>1	S2	No
5	2.5	Local hepatectomy	Moderate	-	M1	Complete	<1	S2	No
6	1.8	Local hepatectomy	Poor	-	M2	Broken	>1	S3	No
7	3.2	Left lateral segmentectomy	Moderate	-	M1	Complete	>1	S2	No
8	4.5	Right posterior lobectomy	Moderate	-	M2	Broken	>1	S2	Yes
9	3.0	Left lobectomy	Moderate	-	M1	Complete	>1	S2	No
10	2.5	Left lateral segmentectomy	Moderate	-	M2	Complete	>1	S3	No
11	8.5	Liver transplantation	Moderate	-	M2	Complete	>1	S4	No
12	5.5	Liver transplantation	Poor	+	M2	Broken	>1	S3	No
13	5.7	Local hepatectomy	Moderate	-	M1	Complete	>1	S3	Yes
14	2.5	Left caudate lobectomy	Poor	-	M0	Complete	<1	S2	No
15	4.5	Local hepatectomy	Poor	-	M1	Complete	>1	S3	No

Abbreviation: MVI, microvascular invasion.

rates of the 15 patients were 31.1%, 23.3%, and 11.7%, respectively, and the 1-, 3-, and 5-year OS rates were 93.3%, 28.7%, and 19.1%, respectively (Figure 4). At the end of follow-up, 12 patients died, all of HCC recurrence, and 3 patients survived (130.4 months, 43.3 months, and 9.4 months, respectively, Table 4). Currently, there are no cases of intrahepatic recurrence or extrahepatic metastasis.

Discussion

HCC combined with extrahepatic metastasis is commonly encountered in clinical practice. Autopsy examinations of

HCC patients show that the incidence of HCC metastasis is as high as 64%.⁷ Distant metastasis of HCC is mainly blood metastasis but can include lung, bone, adrenal gland, and brain metastasis. Lymphatic system metastasis is relatively rare. Most peritoneal metastases are caused by peritoneal implantation of the tumor after HCC rupture and bleeding or the dissemination of tumor tissues in the peritoneal cavity during the first resection of HCC; in contrast, cases of unruptured tumors combined with peritoneal metastases found for the first time are less common. All 15 patients in this study were found to have intra-

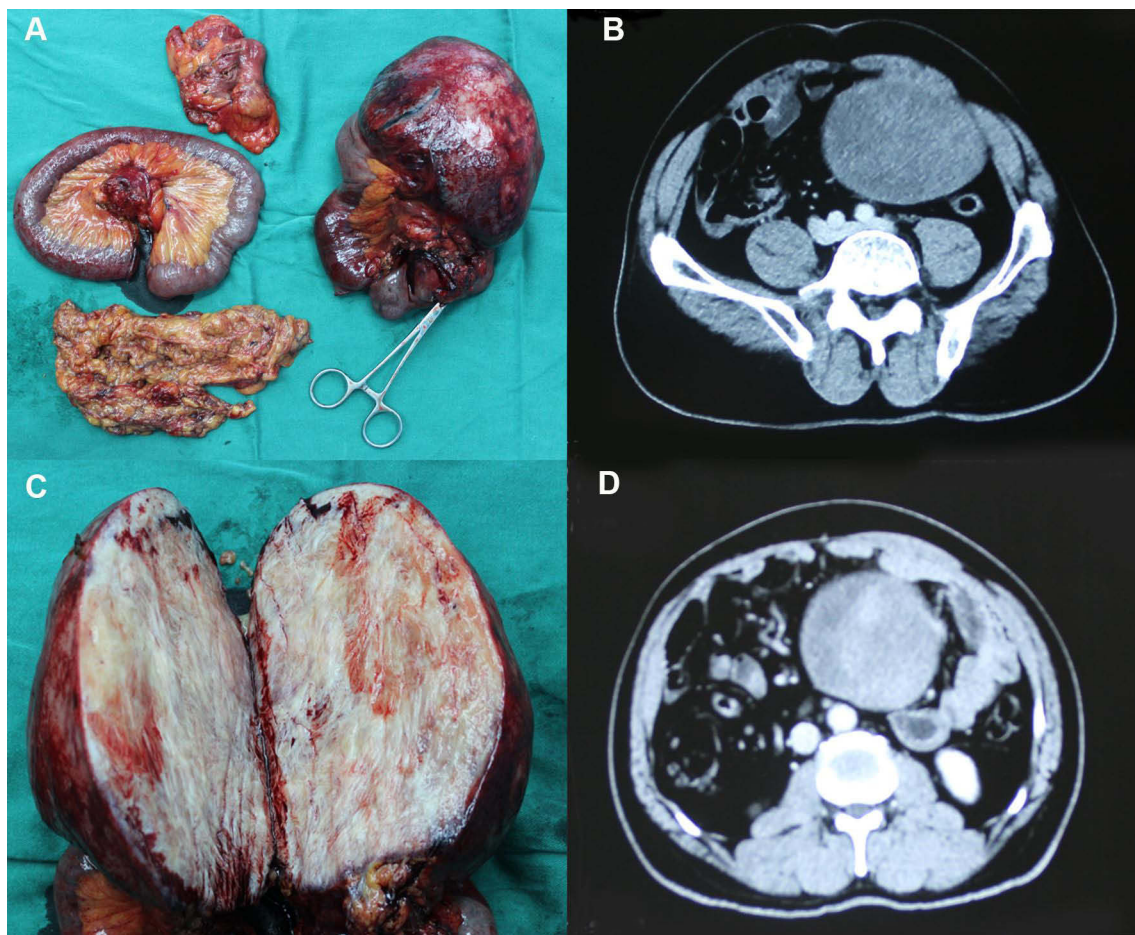


Figure 2 Clinical picture of patient 1. (A) Giant metastatic tumor of mesentery; (B) Computed tomography (CT) images; (C) Tumor section specimen; (D) Arterial dominant phase of CT shows arterial enhancement of nodule measuring 10.0 cm in diameter.

abdominal metastases during follow-up after the first resection of HCC. The main route of intraabdominal metastasis of HCC is still direct tumor invasion or planting metastasis. Sometimes 2 types of metastasis are present at the same time, and the most common site of metastasis is the omentum.^{8,9} There are also different forms of metastasis, including solitary intra-abdominal metastasis, multiple focal intra-abdominal metastasis, and intra-abdominal diffuse metastasis. In the first two cases, surgical resection can generally be performed, while for intra-abdominal diffuse metastasis, it is difficult to achieve complete resection of the tumors visible to the naked eye. Among the 15 patients in this study, 7 had a solitary intra-abdominal metastasis, and 8 had multiple focal metastases. One patient had 4 intra-abdominal metastases. However, complete resection of the metastases was achieved in all cases, including 8 cases of omental resection and 2 cases of combined partial colon or rectal resection. Among the 15 patients with abdominal metastases, 2 had a history of

liver tumor rupture and hemorrhage, which may be a reason for intra-abdominal metastasis of HCC. Tumor rupture and hemorrhage was also observed in metastatic tumors, including 1 case of abdominal metastatic tumor rupture and hemorrhage resulting in hemorrhagic peritonitis, for which emergency surgical treatment was performed.

In terms of staging of HCC with abdominal metastasis, according to the 8th edition of the cancer staging system⁴ issued by the International Union for Cancer Control and American Joint Committee on Cancer (AJCC), abdominal metastasis belongs to stage IV, or Barcelona stage C.⁵ According to the *Guidelines for the Diagnosis and Treatment of Primary HCC in China* (2019 edition),⁶ HCC with abdominal metastasis belongs to stage IIIb. For stage IV HCC, the first choice for treatment is systemic therapy, transcatheter arterial chemoembolization (TACE), or radiotherapy. However, in clinical practice, some surgeons still choose to surgically remove primary and metastatic lesions before starting systemic treatment.¹⁰

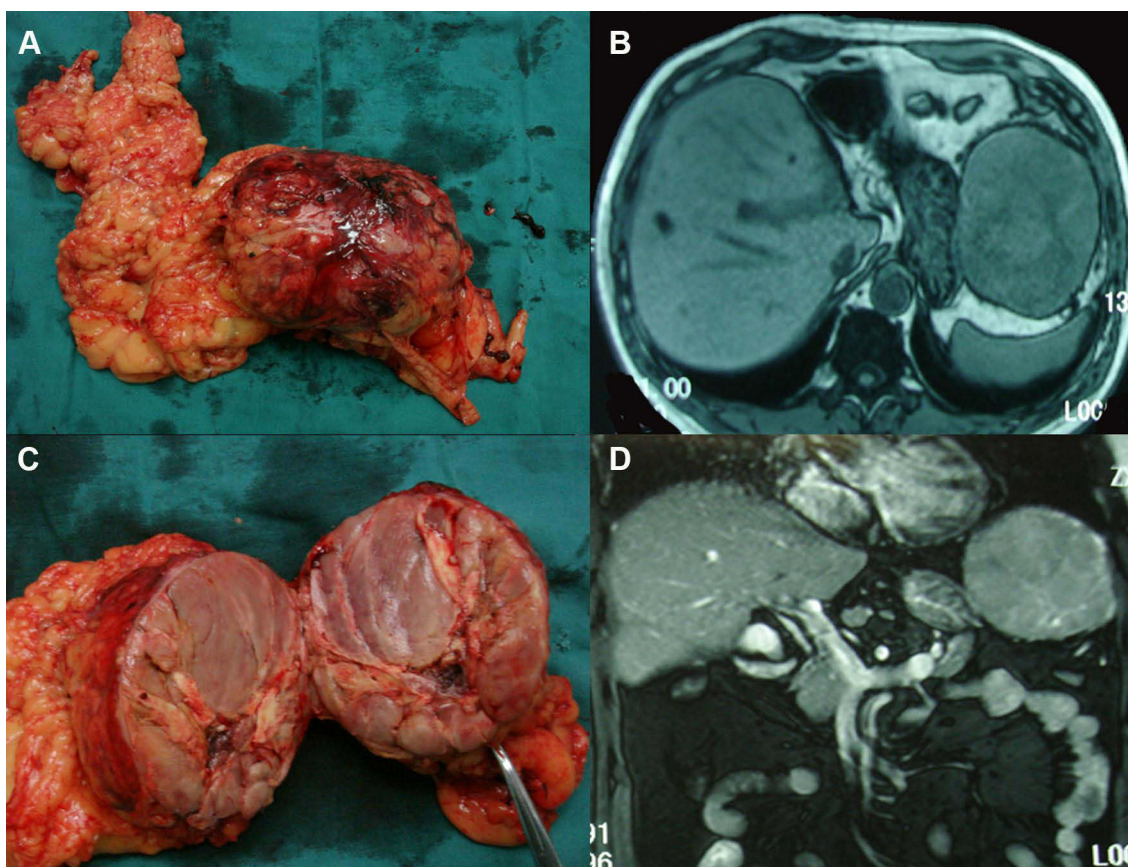


Figure 3 Clinical picture of patient 4. (A) Giant metastatic tumor of omentum; (B) Horizontal plane of magnetic resonance images; (C) Tumor section specimen; (D) Coronal plane of magnetic resonance imaging.

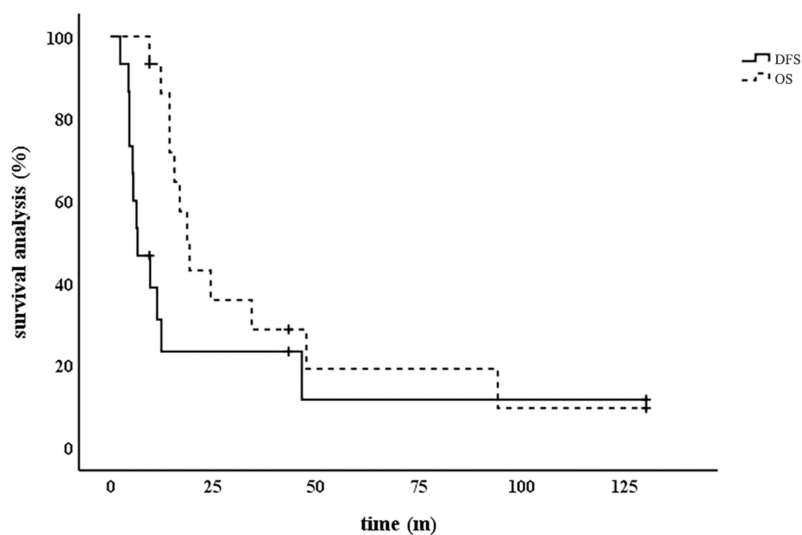


Figure 4 The survival rate after resection of the abdominal metastases. **Abbreviations:** DFS, disease-free survival; OS, overall survival.

Table 4 Postoperative Survival of the Patients

Case	Treatment of Re-Recurrence	DFS (m)	OS (m)	Status
1	–	43.3	43.3	Free of disease
2	Sorafenib+Lenvatinib	9.6	34.3	Dead
3	Sorafenib+Regorafenib	5.5	47.6	Dead
4	Sorafenib	46.5	94.2	Dead
5	Sorafenib	11.3	15.5	Dead
6	Sorafenib	12.3	16.8	Dead
7	–	130.3	130.3	Free of disease
8	Sorafenib	4.5	9.4	Dead
9	None	6.5	14.3	Dead
10	Sorafenib	4.5	18.6	Dead
11	Sorafenib	5.3	14.3	Dead
12	Sorafenib+Regorafenib	4.3	24.3	Dead
13	Sorafenib	2.3	12.2	Dead
14	–	9.4	9.4	Free of disease
15	Sorafenib+Apatinib	6.3	19.2	Dead

Abbreviations: DFS, disease-free survival; OS, overall survival.

Currently, there is no unified standard for the treatment of postoperative abdominal metastasis of HCC. Various guidelines and standards do not specifically describe whether surgical treatment should be performed for resectable intra-abdominal metastases.

At present, most studies on the re-resection of abdominal metastasis after HCC surgery are case reports. There are few serial studies; there were only 5 studies published from 2002 to 2014. The median survival time was from 13.8 months to 34.5 months, and the highest 5-year survival rate was 48% (Table 5). Studies have reported the long-term survival of HCC patients after abdominal metastasis resection.^{11–13} Yeh et al⁹ studied 16 abdominal metastasis patients and found that the OS time of the patients with solitary abdominal metastasis without intrahepatic recurrence was similar to that of patients without recurrence. Some studies have further shown that HCC patients with postoperative abdominal

metastasis but without intrahepatic recurrence or with intrahepatic lesions that can be effectively controlled have a good postoperative prognosis and should be actively treated with surgery; furthermore, the number of abdominal metastases may not be the main prognostic factor.^{15,16} Kow et al¹⁷ conducted a study of 36 patients with abdominal metastases and found that the median survival time of patients who underwent abdominal metastasis resection after HCC surgery was significantly improved compared with that of patients who did not undergo surgical resection (33 vs 14 m), and the prognosis was better for patients with abdominal metastases found more than 6 months after the first surgery and with a solitary or limited abdominal metastasis. A study conducted by the Japanese Society of Hepato-Biliary-Pancreatic Surgery of 99 patients from 44 institutions in Japan showed that the number and size of abdominal metastases affected the prognosis. The 5-year OS rate of patients with an abdominal cancer index (PCI) ≤6 and no residual tumor was 43%, and their prognosis was much better than that of patients who did not meet those criteria.¹⁸

In this study, the median survival time of the 15 patients was 18.6 months, and the median DFS time was 6.5 months. Among these patients, 3 had a DFS of more than 5 years. All 3 patients had intra-abdominal solitary metastasis and no history of intrahepatic tumor rupture. For intra-abdominal metastases, the prognosis is better when the lesion is solitary or localized. In the 2 patients with intestinal wall metastasis, postoperative specimen examinations showed intestinal stenosis. If the abdominal metastases had not been resected, intestinal obstruction symptoms would likely have developed. For these patients, resection of abdominal metastases may be acceptable and may improve their quality of life. The median survival time of our patients with abdominal metastasis after HCC surgery is better than that reported in the literature, especially some patients with isolated or limited metastasis achieve long-term disease-free survival, and obtain a relatively good prognosis.

Table 5 Median Survival of Abdominal Metastases of Hepatocellular Carcinoma in the Literature

No	Author	n	Area	Year	5-Year Os	Median Survival (Months)
1	Yeh et al ⁹	16	Taiwan	2002	-	16.0
2	Lin et al ¹⁴	8	Taiwan	2009	-	13.8
3	Hashimoto et al ¹⁵	9	Japan	2012	42.0%	-
4	Takemura et al ¹⁶	32	Japan	2014	39.0%	34.5
5	Kow et al ¹⁷	13	Singapore	2012	48.0%	33.0

This study was retrospective and had the selection bias inherent to such studies. Because the surgery was exploratory, the total number of surgical resections of abdominal metastases after HCC surgery was small, and therefore, the sample size of the study was small. In the future, some large-scale multicenter prospective studies may be needed to clarify the significance of the resection of abdominal metastases after HCC surgery.

With the application of immunosuppressive agents in HCC and the widespread development of multidisciplinary diagnosis and treatment models, there are an increasing number of systemic treatment methods for advanced HCC. Choosing the best treatment regimen for the individual patient is the biggest problem facing clinicians today. Surgery should still be chosen with caution given that the current major guidelines do not recommend surgery for metastatic tumors.

However, for relatively limited intra-abdominal or solitary metastatic lesions, some patients can attain a good prognosis with the simultaneous resection of metastases. For patients with intestinal wall metastasis, we recommend partial intestinal resection followed by systematic treatment, which can hopefully improve the quality of life of these patients.

Data Sharing Statement

The datasets used and/or analysed in this study are available from the corresponding author on reasonable request.

Ethics Statement

This study was approved by the Ethics Committee of Ningbo Medical Centre Lihuli Hospital (KY2021PJ062), and informed consent for the review of medical records from patient was waived because of the retrospective nature of the study. All the patients or the immediate family members of liver donors signed informed consent statement for the liver donations. The study protocol also complied with the ethical standards established by the Declaration of Helsinki in terms of patient data confidentiality.

Funding

There is no funding to report.

Disclosure

Jiong-Ze Fang and Yong Yang are co-first authors for this study. The authors report no conflicts of interest in this work.

References

1. Wild CP, Weiderpass E, Stewart BW. *World Cancer Report: Cancer Research for Cancer Prevention*. Lyon: International Agency for Research on Cancer; 2020.
2. Kow AW, Kwon CH, Song S, et al. Clinicopathological factors and long-term outcome comparing between lung and peritoneal metastasectomy after hepatectomy for hepatocellular carcinoma in a tertiary institution. *Surgery*. 2015;157(4):645–653. doi:10.1016/j.surg.2014.07.024
3. Uchino K, Tateishi R, Shiina S, et al. Hepatocellular carcinoma with extrahepatic metastasis: clinical features and prognostic factors. *Cancer*. 2011;117(19):4475–4483. doi:10.1002/ncr.25960
4. Chun YS, Pawlik TM, Vauthey JN, et al. 8th Edition of the AJCC cancer staging manual: pancreas and hepatobiliary cancers. *Ann Surg Oncol*. 2018;25(4):845–847. doi:10.1245/s10434-017-6025-x
5. Llovet JM, Bru C, Bruix J. Prognosis of hepatocellular carcinoma: the BCLC staging classification. *Semin Liver Dis*. 1999;19(3):329–338. doi:10.1055/s-2007-1007122
6. Bureau of Medical Administration, National Health Commission of the People's Republic of China. Guidelines for diagnosis and treatment of primary liver cancer (Version 2019). *Chin J Pract Surg*. 2020;40(2):121–138.
7. Nakashima T, Okuda K, Kojiro M, et al. Pathology of hepatocellular carcinoma in Japan. 232 consecutive cases autopsied in ten years. *Cancer*. 1983;51(5):863–877. doi:10.1002/1097-0142(19830301)51:5<863::AID-CNCR2820510520>3.0.CO;2-D
8. Kwak MS, Lee JH, Yoon JH, et al. Risk factors, clinical features, and prognosis of the hepatocellular carcinoma with peritoneal metastasis. *Dig Dis Sci*. 2012;57(3):813–819. doi:10.1007/s10620-011-1995-1
9. Yeh C, Chen M, Jen L. Resection of peritoneal implantation from hepatocellular carcinoma. *Ann Surg Oncol*. 2002;9(9):863–868. doi:10.1007/BF02557522
10. Berger Y, Spivack JH, Heskell M, et al. Extrahepatic metastasectomy for hepatocellular carcinoma: predictors of long-term survival. *J Surg Oncol*. 2016;114(4):469–474. doi:10.1002/jso.24340
11. Eriguchi N, Aoyagi S, Okuda K, et al. Successful surgical treatment for implanted intraperitoneal metastases of hepatocellular carcinoma. *J Hepatobiliary Pancreat Surg*. 2007;7(5):520–523. doi:10.1007/s005340070025
12. Uenishi T, Kubo S, Hirohashi K, et al. Successful surgical control for hepatocellular carcinoma disseminated to the peritoneum: a case report. *Hepato-Gastroenterology*. 2002;49(44):532.
13. Chou H, Lee K, Yeh C, et al. Long-term survival following resection of peritoneal implantation from hepatocellular carcinoma: a case report. *Hepato-Gastroenterology*. 2005;52(64):1221.
14. Lin CC, Liang HP, Lee HS, et al. Clinical manifestations and survival of hepatocellular carcinoma patients with peritoneal metastasis. 2009;24(5):815–820. doi:10.1111/j.1440-1746.2009.05848.x
15. Hashimoto MM, Sasaki KM, Moriyama JM, et al. Resection of peritoneal metastases in patients with hepatocellular carcinoma. *Surgery*. 2013;153(5):727–731. doi:10.1016/j.surg.2012.03.031
16. Takemura N, Hasegawa K, Aoki T, et al. Surgical resection of peritoneal or thoracoabdominal wall implants from hepatocellular carcinoma. *Br J Surg*. 2014;101(8):1017–1022. doi:10.1002/bjs.9489
17. Kow AWC, Kwon CHD, Song S, et al. Risk factors of peritoneal recurrence and outcome of resected peritoneal recurrence after liver resection in hepatocellular carcinoma: review of 1222 cases of hepatectomy in a tertiary institution. *Ann Surg Oncol*. 2012;19(7):2246–2255. doi:10.1245/s10434-012-2260-3
18. Iida H, Tani M, Aihara T, et al. New metastasectomy criteria for peritoneal metastasis of hepatocellular carcinoma: a study of the Japanese Society of Hepato-Biliary-Pancreatic Surgery. *J Hepatobiliary Pancreat Sci*. 2020;27(10):673–681. doi:10.1002/jhbp.796

Cancer Management and Research

Dovepress

Publish your work in this journal

Cancer Management and Research is an international, peer-reviewed open access journal focusing on cancer research and the optimal use of preventative and integrated treatment interventions to achieve improved outcomes, enhanced survival and quality of life for the cancer patient.

The manuscript management system is completely online and includes a very quick and fair peer-review system, which is all easy to use. Visit <http://www.dovepress.com/testimonials.php> to read real quotes from published authors.

Submit your manuscript here: <https://www.dovepress.com/cancer-management-and-research-journal>