




A Case of Acute Myeloid Leukemia Harboring a Rare Three-Way Translocation t(5;7;7) Involving the *PDGFRB* Gene and Successfully Treated with Imatinib

Azra Borogovac ¹Kamal Kant Sahu ²Ganesh Kumar Vishwanathan ³Patricia Minehart Miron⁴Jan Cerny ⁵

¹Hematology-Oncology Section, Department of Medicine, University of Oklahoma Health Sciences Center, Oklahoma City, OK, USA; ²Division of Hematology and Oncology, Department of Internal Medicine, Huntsman Cancer Institute, University of Utah, Salt Lake City, UT, USA; ³Department of Hematology, All India Institute of Medical Sciences (AIIMS), New Delhi, India; ⁴Department of Pathology, University of Massachusetts Memorial Medical Center, Worcester, MA, USA; ⁵Division of Hematology and Oncology, Department of Medicine, University of Massachusetts Memorial Medical Center, Worcester, MA, USA

Abstract: Platelet-derived growth factor-beta (*PDGFRB*) gene maps for the receptor tyrosine kinase PDGFR β . *PDGFRB* gene fusions have been implicated in multiple myeloid and lymphoid neoplasms and have shown exquisite sensitivity to tyrosine kinase inhibitors. We report a case of a 29-year-old male who presented with acute myeloid leukemia who was eventually found to harbor a unique three-way translocation t(5;7;7)(q33.2;q32;q11.2) involving the *PDGFRB* gene. The patient initially achieved a complete response after induction with daunorubicin and cytarabine, but when he returned for consolidation, his white cell count had increased, and he was found to have an underlying myeloproliferative neoplasm. He was given consolidation with high-dose cytarabine and imatinib with excellent response, and ultimately received a matched unrelated donor transplant. The patient remains in remission to this day more than eight years later.

Keywords: AML, eosinophilia, *PDGFRB*, translocation, imatinib, karyotype

Introduction

Platelet-derived growth factor (PDGF) is a dimeric protein composed of two receptor tyrosine kinases, α and β , encoded by the *PDGFRA* (4q12) and *PDGFRB* (5q32) genes.¹ *PDGFRB* gene rearrangements create chimeric proteins that can cause constitutive tyrosine kinase activity, which leads to upregulation of transcription factors affecting cell growth and survival.^{2,3} The first described, and most common *PDGFRB* rearrangement, is the (5;12)(q33;p13) translocation with *ETV6*; however, approximately 30 other different fusion partners of *PDGFRB* have been identified to date.⁴⁻⁸

Myeloid and lymphoid neoplasms with eosinophilia associated with PDGFR or fibroblast growth factor receptor 1 (FGFR-1) rearrangements are grouped into their own clinical entity according to the World Health Organization (WHO) classification, although eosinophilia may be absent in a subset of cases with these rearrangements.⁹ The *PDGFRB* fusion genes have been reported in all major groups of myeloid neoplasms including myelodysplastic syndrome (MDS)/myeloproliferative neoplasms (MPN), acute myeloid leukemia (AML), and in lymphoid neoplasms, such as B-cell and T-cell acute lymphoblastic leukemias (ALL).^{5,6,10-12} Among patients with MPNs, *PDGFRB* rearrangement is seen in approximately 2% of patients and is associated with leukocytosis, eosinophilia and anemia.¹³ The presence of *PDGFRB* rearrangement is associated with excellent response to imatinib, including in patients that have failed standard chemotherapy.^{4,14-18}

Correspondence: Jan Cerny
Division of Hematology and Oncology,
Department of Medicine, University of
Massachusetts Memorial Medical Center,
Worcester, MA, USA
Email jan.cerny@umassmemorial.org



We report a case of a 29-year-old man who initially presented with AML and achieved a complete response (CR) after induction chemotherapy. However, when he was admitted for consolidation chemotherapy, he was found to have an elevated white cell count of 35,000/mm³, for which a repeat bone marrow biopsy with cytogenetic analysis was performed. He was subsequently found to have an MPN harboring a unique three-way translocation t(5;7;7)(q33.2;q32;q11.2) involving the *PDGFRB* gene. The patient achieved a good response with the addition of imatinib to his consolidation chemotherapy and subsequently underwent an allogeneic stem cell transplant (alloSCT).

Case Presentation

Our patient was a 29-year-old male who presented with loss of vision in the right eye. He also reported fatigue, dyspnea, night sweats and left upper quadrant fullness for

approximately one month before presentation. His initial complete blood count revealed a total leukocyte count of 380,000/mm³ with 66% blasts, 5% segmented neutrophils, 8% monocytes, 3% eosinophils, and other immature myeloid cells (Table 1). He was anemic and thrombocytopenic with a hemoglobin of 7.8 gm/dL and a platelet count of 35,000/mm³. A bone marrow biopsy was a diagnostic of AML with monocytic differentiation. There were no *FLT3* nor *NPM1c* terminal mutations. Cytogenetic analysis showed a 3-way translocation involving chromosome 5 and both chromosomes 7 with breakpoints at 5q33.2, 7q32 and 7q11.2 [(46, XY,t(5;7;7)(q33.2;q32;q11.2)] as the only abnormality (Figure 1). Interphase fluorescence in situ hybridization (FISH) was positive for *PDGFRB* rearrangement. Metaphase FISH with *PDGFRB* and with whole chromosome painting probes to chromosomes 5 and 7 confirmed the 3-way translocation and showed that sequences 5' to *PDGFRB* were translocated to the

Table 1 Peripheral Blood and Bone Marrow Trends Throughout Treatment Course

Peripheral Blood	Initial Presentation	Day 14	Day 28 AML-CRI	DAY 37	After Imatinib Therapy
WBC	380,000/mm ³	200/mm ³	2600/mm ³	35,900/mm ³	3300/mm ³
Segmented neutrophils	5%		36%	50%	60.1%
Banded neutrophils	3%		7%	9%	
Metamyelocytes	2%		4%	4%	
Myelocytes			2%	5%	
Promyelocytes	6%		5%	1%	
Lymphocytes	4%	80%	24%	9%	17.4%
Monocytes	8%	20%	22%	21%	12.4%
Eosinophils	3%			1%	9.8%
Blasts	66%				
Hemoglobin	7.8 g/dL	8.4 g/dL	9.6 g/dL	12.1 g/dL	10.0 g/dL
Platelet count	35,000/mm ³	11,000/mm ³	179,000/mm ³	237,000/mm ³	54,000/mm ³
Bone Marrow					
Cellularity	100%	Low	20–30%	95%	80%
Blasts	61%	No blasts	1%	3%	2%
Normoblasts			27%	20%	29%
Promonocytes	9%				
Promyelocytes	3%		9%	3%	2%
Myelocytes, metamyelocytes, neutrophils	12%		50%	65%	53%
Eosinophils	2%		0%	7%	4%
Monocytes	13%		8%	8%	1%
Basophils	0%		3%	0%	0%
Lymphocytes	0%		2%	3%	9%
Plasma Cells	0%		0%	1%	0%

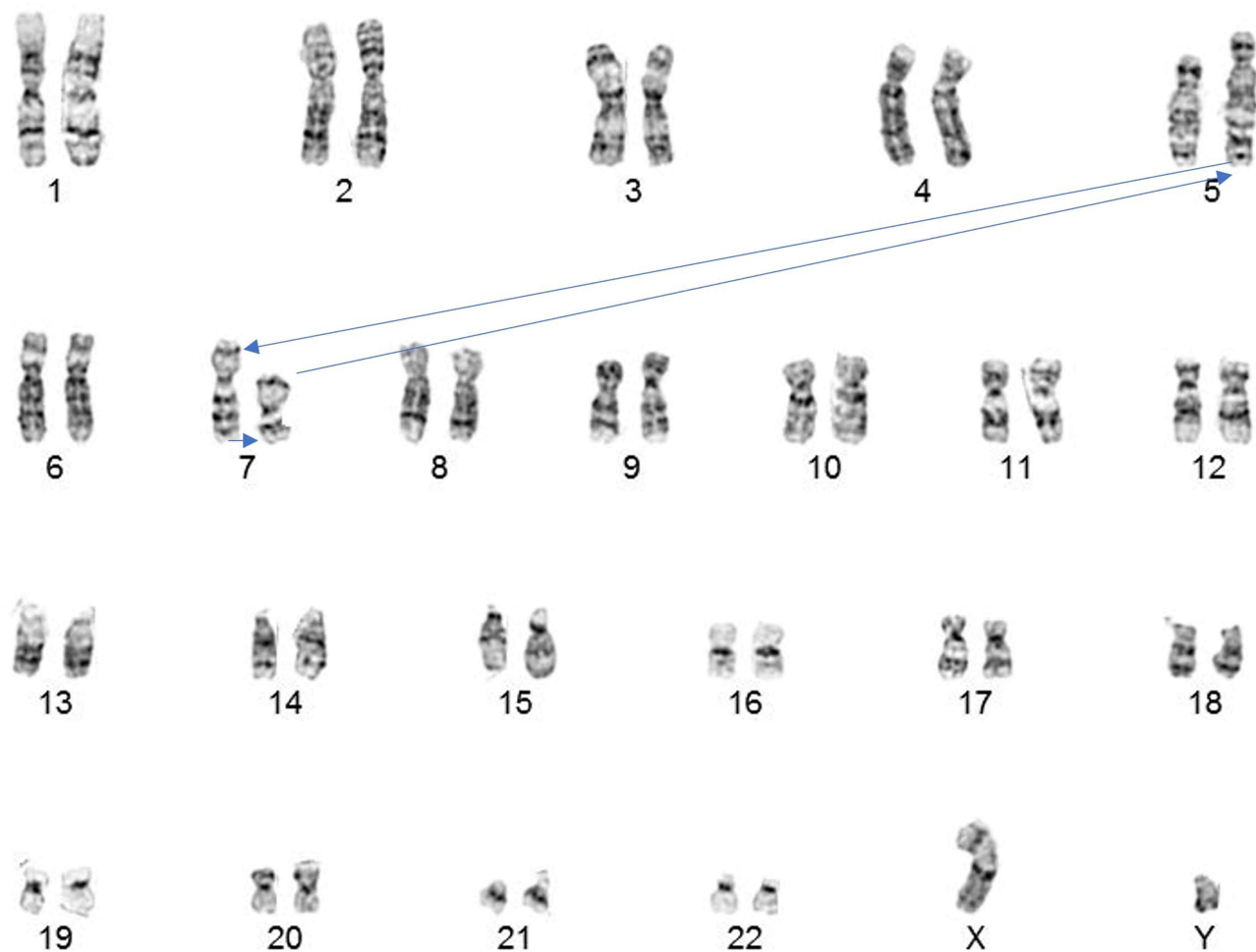


Figure 1 Karyotype. 46,XY,t(5;7)(q33.2;q32;q11.2). Arrows indicate the direction of the transfer of chromosomal material between the derivative chromosomes 5, 7 and 7.

derivative chromosome 7 with the 7q32 breakpoint (Figure 2). For other *PDGFRB* fusions, the critical oncogenic fusion is on the derivative chromosome 5, which retains the 3' portion of *PDGFRB* (Figure 3). Thus, the partner gene for this unidentified *PDGFRB* rearrangement appeared to lie at the 7q11.2 breakpoint (Figure 4). *BCR-ABL1* fusion was not observed. The patient was started on induction chemotherapy with cytarabine and daunorubicin (7+3). Bone marrow biopsies on days 14 and 28 were negative for AML consistent with a successful induction.

When he presented for consolidation chemotherapy, the patient was found to have a total white blood cell count of 35,000/mm³ with 50% segmented neutrophils, 21% monocytes, and no blasts. Due to concern for disease relapse, a repeat bone marrow biopsy was performed which demonstrated 95% hypercellular marrow with granulocytic hyperplasia, monocytosis, eosinophilia, and megakaryocytic hypoplasia. Morphologically, the bone

marrow was consistent with chronic myelomonocytic leukemia (CMML) with eosinophilia of 7%. Eosinophilia was not present in the peripheral blood. The patient had persistence of the same clonal rearrangement. The patient proceeded with high-dose ARA-C (HiDAC) for consolidation. Due to the *PDGFRB* translocation, imatinib 400 mg daily was added to his consolidation regimen.

A repeat bone marrow one month after initiation of imatinib therapy demonstrated continued morphological remission but persistent *PDGFRB* rearrangement. He subsequently underwent a matched unrelated donor alloSCT 3 months after initiation of imatinib with myeloablative conditioning. He has remained in a clinical and pathological CR 8 years later.

Discussion

We report a patient with a rare translocation involving the *PDGFRB* gene, who was initially treated with induction 7

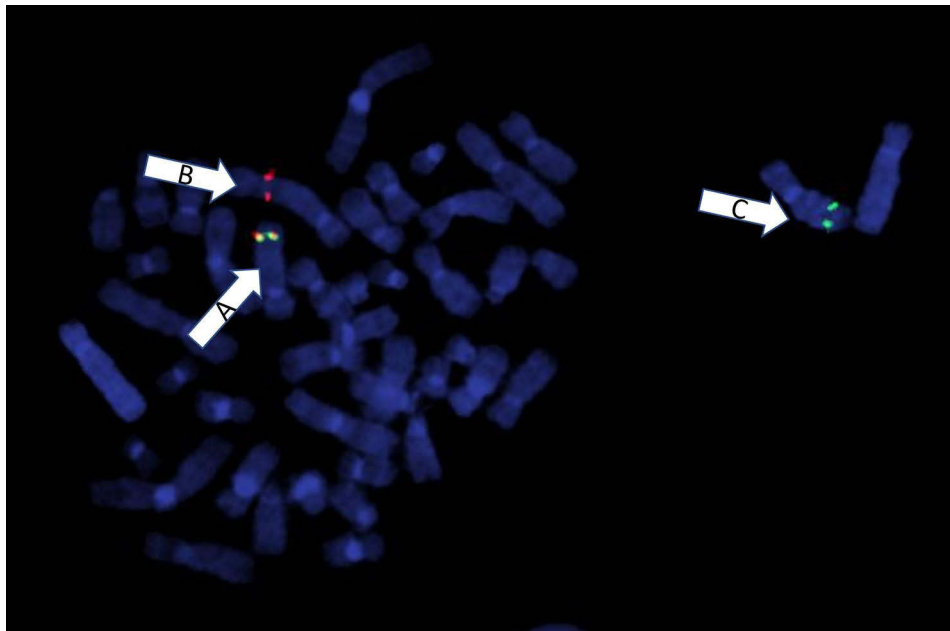


Figure 2 Metaphase FISH using break apart probes for 3'PDGFRB (red signal) and 5'PDGFRB (green signal). Arrow A shows the normal chromosome 5 with an intact PDGFRB fusion signal (yellow). Arrow B shows the derivative chromosome 5 containing only the 3' portion of PDGFRB (red signal). Arrow C shows the derivative chromosome 7 with the translocated 5' portion of PDGFRB (green signal).

+3 chemotherapy for AML and was subsequently found to have an underlying MPN. Metaphase chromosome analysis demonstrated a three-way translocation (5;7;7)(q33.2; q32;q11.2); FISH confirmed the involvement of the

PDGFRB gene. To the best of our knowledge, this is the first such reported case of a PDGFRB translocation with a fusion product that would be equivalent to that generated by a more straight-forward two-way translocation, t(5;7)

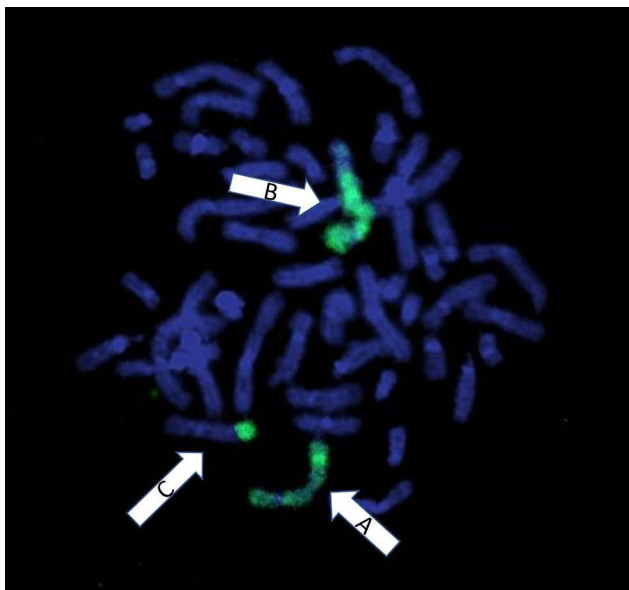


Figure 3 Whole chromosome 5 paint with green fluorescent probes. Arrow A shows the normal chromosome 5 with fluorescence label seen throughout the chromosome indicating intact chromosomal material. Arrow B shows the derivative chromosome 5; the unlabeled end of the long arm indicates the translocated chromosomal material from the derivative chromosome 7. Arrow C shows the derivative chromosome 7 containing translocated material from the der(5).

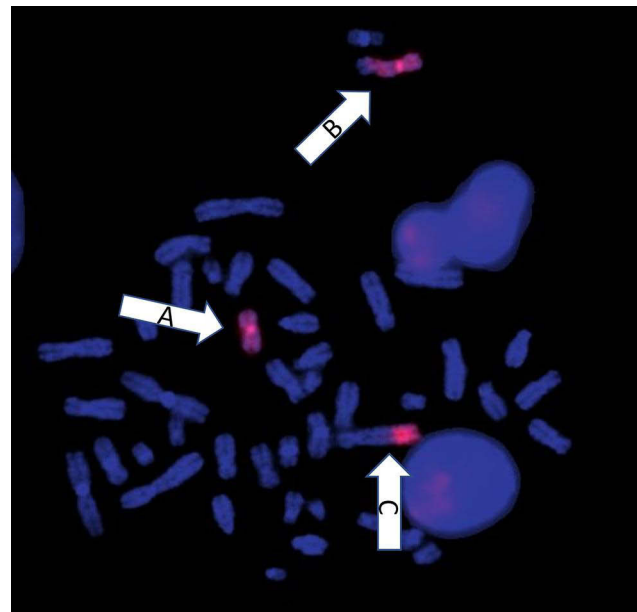


Figure 4 Whole chromosome 7 paint with red fluorescent probes. Arrow A shows the derivative chromosome 7. Arrow B shows the derivative chromosome 7 with the unlabeled part at the end indicating the translocated chromosomal material from the derivative chromosome 5. Arrow C shows the der(5) with translocated chromosomal material from der(7).

(q33.2;q11.2). The patient was treated with HiDAC consolidation chemotherapy for the AML along with targeted therapy with imatinib. He maintained his counts for 3 months until alloSCT and remains in remission to this date. As in our case, the *PDGFRB* translocation in acute leukemia is often not found until the patient experiences relapse.¹⁹ Additionally, the diagnosis may be more difficult if peripheral eosinophilia is not present. In one study, approximately 4 of 19 patients (21%) with hematological malignancies with *PDGFRB* rearrangements did not have eosinophilia and only 11/19 (58%) of cases had eosinophils $\geq 1.5 \times 10^9/L$.⁷

The mechanism by which PDGFR fusion proteins lead to malignant neoplasms is thought to occur through constitutive activation of the PDGFRs. Normally, the PDGF proteins assemble causing dimerization of the PDGFRs, which activate the cell's tyrosine kinase activity. This sequence of events leads to downstream signaling cascades important in cell migration, proliferation and survival through many overlapping signaling pathways.^{2,20} One such pathway activated by the PDGFR is the PI3K/AKT/mTOR pathway, which is frequently dysregulated in many cancers.²¹

Identifying the *PDGFRB* rearrangement in hematological malignancies early in disease has important treatment implications as they have been shown to respond favorably to tyrosine kinase inhibitors (TKIs). In a cohort of 26 patients with hematological malignancies with *PDGFRB* translocations treated with imatinib therapy, Cheah et al demonstrated a 10-year overall survival (OS) of 90% after a median duration of imatinib of 6.6 years, and the 6-year progression-free survival (PFS) of 88%. No patients developed treatment resistance; furthermore, all patients that achieved hematological response did so within 2 months.⁴ Jawhar et al also evaluated 22 patients with *PDGFRB* translocations with myeloid and lymphoid malignancies (17 patients in chronic phase, and 5 patients in blastic phase) and found all the chronic phase patients achieved a CR with imatinib alone. The 5 patients in blastic phase (2 myeloid, and 3 lymphoid) were treated with a combination of intensive chemotherapy and imatinib, consolidated with alloSCT for 3 of the patients. The 5-year OS was 50% in those who presented in blastic phase versus 92% in chronic phase.⁷

It is important to note that only a few cases have been reported with AML involving the *PDGFRB* gene, and the response to TKIs is not as clearly established. In a review

of case reports, Naymagon et al documented 4 cases of AML associated with *PDGFRB* translocations.¹⁹ Three cases resulted from de novo AML, while one had an underlying MPN. All four cases achieved a CR with induction chemotherapy and imatinib, but only 2 of 4 maintained a CR after 12 months or more of follow-up.¹⁹ Tokita et al reported a patient with chronic idiopathic myelofibrosis with *TEL-PDGFRB* fusion that transformed into AML. The patient was similarly treated with induction chemotherapy and imatinib. The patient responded well for three months until his AML relapsed, and he died shortly thereafter.²² Shimomura et al reported the first case of AML with *PDGFRB* rearrangement to be treated with single-agent imatinib for induction therapy and achieved hematological remission; however, his AML shortly relapsed. They hypothesized treatment resistance was due to a point mutation in the *PDGFRB* gene.¹⁶ Several *PDGFRB* rearrangements have also been associated with resistance to imatinib and other TKIs.^{23–25} No studies have reported the role of later generation TKIs in the setting of AML with *PDGFRB* rearrangements after resistance to imatinib.

Conclusion

The *PDGFRB* rearrangement can present as a wide array of hematological malignancies. Our patient's AML responded to induction chemotherapy; however, his MPN surfaced once he achieved remission for AML. He subsequently achieved a hematological response after initiation of imatinib, which he maintained until transplantation; as such, it is unclear how he would have responded with long-term tyrosine kinase inhibition. This case further argues for early cytogenetic analysis of *PDGFR* rearrangements in patients with a diverse presentation of hematological malignancies.

IRB Approval

IRB approval was not required to publish this case report.

Ethical Statement

The article does not contain participation of any human being and animal.

Patient Consent

As an institutional protocol, patient was consented at the beginning of his treatment only that if required his treatment data would be used for publication without revealing his identity. Hence, we confirm that we have taken

appropriate consent from the patient, which allows us to report this case.

Funding

There is no funding to report.

Disclosure

Dr. Jan Cerny has the following disclosures outside the published work: he serves in the advisory board/consultancy for Jazz Pharmaceuticals, Pfizer and Amgen. He is a Data and Safety Monitoring Board Member for AlloVir, and holds stocks from Actinium Pharmaceuticals, Bluebird Bio Inc., Dynavax Pharma, Atyr Pharmac, Gamida Cell, Miragen Therapeutics, Mustang Bio, Novavax, Ovid Therapeutics, Sorrento Therapeutics, TG Therapeutics, Vaxart Inc., and Veru Inc. The authors report no other conflicts of interest in this work.

References

- Demoulin JB, Montano-Almendras CP. Platelet-derived growth factors and their receptors in normal and malignant hematopoiesis. *Am J Blood Res.* 2012;2:44–56.
- Kazlauskas A. PDGFs and their receptors. *Gene.* 2017;614:1–7. doi:10.1016/j.gene.2017.03.003
- Golub TR, Barker GF, Lovett M, Gilliland DG. Fusion of PDGF receptor beta to a novel ets-like gene, tel, in chronic myelomonocytic leukemia with t(5;12) chromosomal translocation. *Cell.* 1994;77:307–316. doi:10.1016/0092-8674(94)90322-0
- Cheah CY, Burbury K, Apperley JF, et al. Patients with myeloid malignancies bearing PDGFRB fusion genes achieve durable long-term remissions with imatinib. *Blood.* 2014;123:3574–3577. doi:10.1182/blood-2014-02-555607
- Vega F, Medeiros LJ, Bueso-Ramos CE, et al. Hematolymphoid neoplasms associated with rearrangements of PDGFRA, PDGFRB, and FGFR1. *Am J Clin Pathol.* 2015;144:377–392. doi:10.1309/AJCPMORR5Z2IKCEM
- Appiah-Kubi K, Lan T, Wang Y, et al. Platelet-derived growth factor receptors (PDGFRs) fusion genes involvement in hematological malignancies. *Crit Rev Oncol Hematol.* 2017;109:20–34. doi:10.1016/j.critrevonc.2016.11.008
- Jawhar M, Naumann N, Schwaab J, et al. Imatinib in myeloid/lymphoid neoplasms with eosinophilia and rearrangement of PDGFRB in chronic or blast phase. *Ann Hematol.* 2017;96:1463–1470. doi:10.1007/s00277-017-3067-x
- Reiter A, Gotlib J. Myeloid neoplasms with eosinophilia. *Blood.* 2017;129:704–714. doi:10.1182/blood-2016-10-695973
- Arber DA, Orazi A, Hasserjian R, et al. The 2016 revision to the World Health Organization classification of myeloid neoplasms and acute leukemia. *Blood.* 2016;127:2391–2405. doi:10.1182/blood-2016-03-643544
- Bain BJ. Myeloid and lymphoid neoplasms with eosinophilia and abnormalities of PDGFRA, PDGFRB or FGFR1. *Haematologica.* 2010;95:696–698. doi:10.3324/haematol.2009.021675
- Morerio C, Aquila M, Rosanda C, et al. HCMOGT-1 is a novel fusion partner to PDGFRB in juvenile myelomonocytic leukemia with t(5;17)(q33;p11.2). *Cancer Res.* 2004;64:2649–2651. doi:10.1158/0008-5472.CAN-03-4026
- Pozdnyakova O, Orazi A, Kelemen K, et al. Myeloid/lymphoid neoplasms associated with eosinophilia and rearrangements of PDGFRA, PDGFRB, or FGFR1 or with PCM1-JAK2. *Am J Clin Pathol.* 2021;155:160–178. doi:10.1093/ajcp/aqaa208
- Arefi M, Garcia JL, Penarrubia MJ, et al. Incidence and clinical characteristics of myeloproliferative neoplasms displaying a PDGFRB rearrangement. *Eur J Haematol.* 2012;89:37–41. doi:10.1111/j.1600-0609.2012.01799.x
- Metzgeroth G, Schwaab J, Gosenca D, et al. Long-term follow-up of treatment with imatinib in eosinophilia-associated myeloid/lymphoid neoplasms with PDGFR rearrangements in blast phase. *Leukemia.* 2013;27:2254–2256. doi:10.1038/leu.2013.129
- David M, Cross NC, Burgstaller S, et al. Durable responses to imatinib in patients with PDGFRB fusion gene-positive and BCR-ABL-negative chronic myeloproliferative disorders. *Blood.* 2007;109:61–64. doi:10.1182/blood-2006-05-024828
- Shimomura Y, Maruoka H, Ishikawa T. Marked response to imatinib mesylate in a patient with platelet-derived growth factor receptor beta-associated acute myeloid leukemia. *Int J Hematol.* 2017;105:697–701. doi:10.1007/s12185-016-2167-z
- Bell GC, Padron E. Detection of a PDGFRB fusion in refractory CMML without eosinophilia: a case for broad spectrum tumor profiling. *Leuk Res Rep.* 2015;4:70–71.
- Wenger TL, Bly RA, Wu N, et al. Activating variants in PDGFRB result in a spectrum of disorders responsive to imatinib monotherapy. *Am J Med Genet A.* 2020;182:1576–1591. doi:10.1002/ajmg.a.61615
- Naymagon L, Marcellino B, Mascarenhas J. Eosinophilia in acute myeloid leukemia: overlooked and underexamined. *Blood Rev.* 2019;36:23–31. doi:10.1016/j.blre.2019.03.007
- Wu E, Palmer N, Tian Z, et al. Comprehensive dissection of PDGF-PDGFR signaling pathways in PDGFR genetically defined cells. *PLoS One.* 2008;3:e3794. doi:10.1371/journal.pone.0003794
- Zhang H, Bajraszewski N, Wu E, et al. PDGFRs are critical for PI3K/Akt activation and negatively regulated by mTOR. *J Clin Invest.* 2007;117:730–738. doi:10.1172/JCI28984
- Tokita K, Maki K, Tadokoro J, et al. Chronic idiopathic myelofibrosis expressing a novel type of TEL-PDGFRB chimera responded to imatinib mesylate therapy. *Leukemia.* 2007;21:190–192. doi:10.1038/sj.leu.2404397
- Byrgazov K, Kastner R, Gorna M, et al. NDEL1-PDGFRB fusion gene in a myeloid malignancy with eosinophilia associated with resistance to tyrosine kinase inhibitors. *Leukemia.* 2017;31:237–240. doi:10.1038/leu.2016.250
- Zhang Y, Gao Y, Zhang H, et al. PDGFRB mutation and tyrosine kinase inhibitor resistance in Ph-like acute lymphoblastic leukemia. *Blood.* 2018;131:2256–2261. doi:10.1182/blood-2017-11-817510
- Tran TH, Nguyen JV, Stecula A, et al. The EBF1-PDGFRB T681I mutation is highly resistant to imatinib and dasatinib in vitro and detectable in clinical samples prior to treatment. *Haematologica.* 2021. doi:10.3324/haematol.2020.261354

Cancer Management and Research

Dovepress

Publish your work in this journal

Cancer Management and Research is an international, peer-reviewed open access journal focusing on cancer research and the optimal use of preventative and integrated treatment interventions to achieve improved outcomes, enhanced survival and quality of life for the cancer patient.

The manuscript management system is completely online and includes a very quick and fair peer-review system, which is all easy to use. Visit <http://www.dovepress.com/testimonials.php> to read real quotes from published authors.

Submit your manuscript here: <https://www.dovepress.com/cancer-management-and-research-journal>