






# Hypertrophic Scar Following Excisional Surgery and Full-Thickness Skin Grafting Due to Rhinophyma Treated with 1064 nm Q-Switched Neodymium:Yttrium Aluminum Garnet Laser

Kartika Ruchiatan <sup>1</sup>  
Reti Hindritiani <sup>1</sup>  
Diah Puspitosari <sup>1</sup>  
Gabriela Reginata <sup>1</sup>  
Rani Seprina <sup>2</sup>

<sup>1</sup>Department of Dermatology and Venereology, Faculty of Medicine, Universitas Padjadjaran-Dr. Hasan Sadikin Hospital, Bandung, Indonesia;

<sup>2</sup>Department of Plastic Surgery and Reconstruction, Faculty of Medicine, Universitas Padjadjaran-Dr. Hasan Sadikin Hospital, Bandung, Indonesia

**Abstract:** Rhinophyma is characterized by progressive enlargement of the nasal skin, which is considered to be an advanced stage of phymatous rosacea. Esthetic disfigurement makes surgical treatment necessary for this condition. Hypertrophic scars are the consequence of alterations in the skin's healing process following surgical interventions. Laser may be the treatment of choice in hypertrophic scars. We reported a case of hypertrophic scars following excisional surgery and full-thickness skin grafting due to rhinophyma in an 18-year-old male who was consulted from the Department of Plastic Surgery and Reconstruction. The 1064 nanometer (nm) Q-switched Neodymium: Yttrium Aluminum Garnet (QS Nd:YAG) with 4 mm spot size, 1.5 J/cm<sup>2</sup> and 1 Hz was applied to the hypertrophic scars for three sessions within one month interval. Clinical improvement was observed as indicated by the patient's Vancouver scar scale score and spectrophotometry result, and no side effects were found. Nd:YAG laser is a non-ablative device that targets hemoglobin, water, and melanin. Any thermal effects on dermal tissue containing blood vessels could result in reduced blood flow through the capillaries in the dermal papillae. QS Nd:YAG-induced selective photothermolysis was responsible for collagen breakdown and reduced collagen production in hypertrophic scars. The 1064 nm QS Nd:YAG laser gave good results in this case although more treatment sessions may be recommended and a longer follow-up is necessary in order to assess the stability of the result.

**Keywords:** hypertrophic scar, rhinophyma, QS Nd:YAG laser

## Introduction

Rhinophyma is a benign condition characterized by a large, bulbous nose with prominent pores. It is commonly associated with untreated cases of rosacea. Surgery is usually required for the management of rhinophyma. However, it often has sequelae in the form of scar formation.<sup>1</sup> Hypertrophic scars result from excessive deposition of collagen at sites of prior dermal injury and wound repair due to an imbalance between collagen biosynthesis and matrix degradation.<sup>2</sup> Hypertrophic scars can carry a substantial psychological impact that causes patients to seek advice on how to improve their cosmetic appearance.<sup>3,4</sup> Because of the complex pathogenesis and variability in clinical response, it is difficult to treat hypertrophic scars. This, in turn, results in a high recurrence rate regardless of therapy.<sup>5</sup> Many therapeutic modalities for hypertrophic scars have been introduced and used with

Correspondence: Kartika Ruchiatan  
Department of Dermatology and Venereology, Faculty of Medicine, Universitas Padjadjaran-Dr. Hasan Sadikin Hospital, Jl. Pasteur 38, Bandung, West Java, 40161, Indonesia  
Tel +6281 1247932  
Email kartika.ruchiatan@unpad.ac.id

variable outcomes including intralesional steroid injections, pressure dressing, silicone gel sheeting, topical silicone gels, radiotherapy, cryotherapy, surgical scar revision, and laser therapies.<sup>2,5</sup>

Lasers are a noninvasive, safe, painless, and well-tolerated modality.<sup>2</sup> Lasers were first used in the treatment of scars in 1978.<sup>3</sup> The 1064 nm Q-switched Neodymium: Yttrium Aluminum Garnet (QS Nd:YAG) laser has been shown to selectively suppress collagen production in fibroblast cultures, and clinical studies on its application towards the treatment of scars have also been promising.<sup>2,3,5</sup> Here, we demonstrate a case of hypertrophic scar following excisional surgery and full-thickness skin grafting due to rhinophyma treated with 1064 nm QS Nd:YAG laser.

## Case

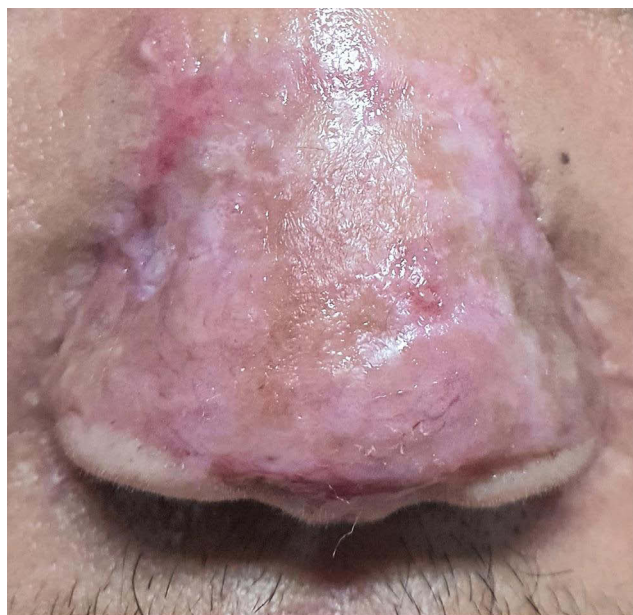
An 18-year-old man was consulted from the Department of Plastic Surgery and Reconstruction with a chief complaint of hypertrophic scars with uneven skin tone on his nose six months after excisional surgery and full-thickness skin grafting due to a history of rhinophyma five years prior (Figure 1). On physical examination, the patient's vital signs and general status were within normal limit, and nutritional status was normal, with normal body weight. The patient's dermatological status showed regional distribution, in the form of hypertrophic scar and skin dyspigmentation of the nose. The patient was treated with 2% alpha arbutin cream twice daily and received three sessions of 1064 nm QS Nd:YAG

laser (4 mm spot, 1.5 J/cm<sup>2</sup>, 1 Hz) at monthly interval. Scar thinning assessed using Vancouver scar scale and skin tone brightness assessed using spectrophotometry showed improvement. There were decrement of hypertrophic scar and improvement of uneven skin tone after the third session (Figure 2). No complications were observed, and the patient was satisfied.

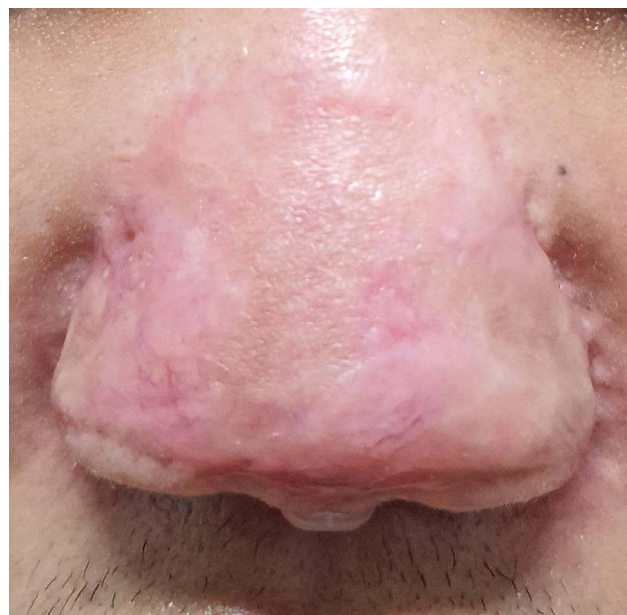## Discussion

Hypertrophic scars are responsible for cosmetic disfigurement, especially if located around the facial area.<sup>6</sup> Lasers can be an option in minimizing the appearance of hypertrophic scars.<sup>2</sup> Treatment with 1064 nm QS Nd:YAG laser, a non-ablative and selective photothermolysis system, is commonly used in many dermatology clinics for various pigmentary disorders and tattoo removal. Therefore, 1064 nm QS Nd:YAG laser with low fluence can be easily applied to patients with hypertrophic scars by simply changing the parameters of laser devices that are usually available in most dermatology clinics.<sup>5</sup>

The mechanism by which laser devices exert therapeutic effects on hypertrophic scars remains to be elucidated.<sup>5</sup> As QS Nd:YAG laser is a non-ablative device that targets hemoglobin, water, and melanin, any thermal effects on dermal tissue containing blood vessels could result in reduced blood flow through the capillaries in the dermal papillae. In addition, previous reports suggested that QS Nd:YAG-induced selective photothermolysis was responsible for collagen breakdown and reduced collagen production in hypertrophic



**Figure 1** Clinical manifestation prior to laser treatment, six months after surgery.



**Figure 2** Clinical manifestation after three sessions of treatment.

scars.<sup>5,7,8</sup> QS Nd:YAG-induced neocollagen production and collagen remodeling through thermal damage might also play a role in the clinical improvement of hypertrophic scars.<sup>2,5</sup>

One rationale for the use of 1064 nm QS Nd:YAG laser was its effect on melanosomes and/or melanocytes in hypertrophic scars.<sup>5,9</sup> A study by Mutalik et al demonstrated clinical improvement of pigmentation in scars, which helped to obscure the distinctive border between the scar and its surrounding skin.<sup>9</sup> It is reasonable to propose that this option becomes one of the primary techniques of choice. Another study by Cho et al<sup>5</sup> also demonstrated clinical improvement of pigmentation in scars, obscuring the border between hypertrophic scar and its surrounding skin.<sup>5</sup>

For a scar-measuring device to provide clinical utility, it should be non-invasive, accurate, reproducible, and easy-to-use to facilitate objective data collection.<sup>10</sup> The Vancouver scar scale is a useful assessment tool for the grading and evaluation of risks of scar development and scar treatment outcomes. Aspects assessed on the Vancouver scar scale include pigmentation, vascularity, pliability, and height or thickness.<sup>11</sup> In this patient, the initial total Vancouver scar scale score was ten, and after three sessions of treatment, the total score was decreased to six, with a decrease observed in all aspects of VSS, indicating an improvement of the Vancouver scar scale score without any side effects.

Evaluating coloration changes using a spectrophotometer is necessary to assess the success of therapy in pigmentation disorders.<sup>12</sup> Three parameters are assessed objectively in spectrophotometer examination, namely L\* (luminance: black and white) to assess the level of skin brightness, a\* (green and red) to assess erythema which will increase if erythema occurs, and b\* (blue and yellow) to assess hyperpigmentation disorders.<sup>12,13</sup> Spectrophotometric examination on this patient revealed brightening of the skin with an increased L\* value and fading redness with a reduced a\* value. The L\* value was increased from 52.33 to 55.45, from 36.68 to 40.81, and from 52.36 to 56.42 on the right side, left side, and middle part of the nose, respectively, whereas the a\* value was decreased from 15.55 to 14.21, from 13.08 to 10.07, and from 16.41 to 13.39 on the right side, left side, and middle part of the nose, respectively. Improvement was observed after three sessions of treatment, without any side effects. However, this case has limitations due to single-subject results and short-term follow-up.

## Conclusion

In conclusion, our results demonstrate that 1064 nm QS Nd:YAG laser may be beneficial for the treatment of hypertrophic scars. Improvement of scars and skin tone was seen in this patient, not only clinically but also objectively, as indicated by decreased Vancouver scar scale score and improvement of spectrophotometric parameters. For optimal result, several sessions of treatment and longer follow-up are necessary.

## Consent for Publication

The patient has signed the consent forms for the use of case details and images for publication and scientific purposes. Institutional approval from The Research Ethic Committee of Dr. Hasan Sadikin General Hospital Bandung, Indonesia, has been obtained to publish the case details (approval number: LB.02.01/X.6.5/362/2021).

## Acknowledgments

The authors would like to thank the staff of the Department of Dermatology and Venereology, Faculty of Medicine, Universitas Padjadjaran, Bandung, West Java, Indonesia.

## Funding

The authors declare that this study has received no financial support.

## Disclosure

The authors report no conflicts of interest in this work.

## References

1. Al Hamzawi NK, Al Baaj SM. Large rhinophyma treated by surgical excision and electrocautery. *Case Rep Surg.* 2019;2019:1–3. doi:10.1155/2019/2395619
2. Mysore V, Mhatre M. Safety and efficacy of long-pulsed Nd:YAG Laser for the treatment of keloids – a prospective study of 39 keloids. *J Laser Health Acad.* 2015;2015:1–6.
3. Al Harithy RA, Pon K. Scar treatment with lasers: a review and update. *Curr Dermatol Rep.* 2012;1(2):69–75. doi:10.1007/s13671-012-0009-7
4. Bimbi C, Brzeziński P. Combined treatment of keloids and scars with Nd:YAG 1064-nm laser and cryotherapy: report of clinical cases. *Dermatol Online.* 2020;11:149. doi:10.7241/ourd.20202.8
5. Cho SB, Lee JH, Lee SH, Lee SJ, Bang D, Oh SH. Efficacy and safety of 1064-nm Q-switched Nd:YAG laser with low fluence for keloids and hypertrophic scars. *J Eur Acad Dermatol Venereol.* 2010;24(9):1070–1074. doi:10.1111/j.1468-3083.2010.03593.x
6. Morosolli AR, De Oliveira Moura Cardoso G, Murilo-Santos L, Niccoli-Filho W. Surgical treatment of earlobe keloid with CO2 laser radiation: case report and clinical standpoints. *J Cosmet Laser Ther.* 2008;10(4):226–230. doi:10.1080/14764170802307957

7. Atiyeh BS. Nonsurgical management of hypertrophic scars: evidence-based therapies, standard practices, and emerging methods. *Aesthetic Plast Surg.* 2007;31(5):468–492. doi:10.1007/s00266-006-0253-y
8. Jin R, Huang X, Li H, et al. Laser therapy for prevention and treatment of pathologic excessive scars. *Plast Reconstr Surg.* 2013;132(6):1747–1758. doi:10.1097/PRS.0b013e3182a97e43
9. Mutalik S. Treatment of keloids and hypertrophic scars. *Indian J Dermatol Venereol Leprol.* 2005;71:3–8. doi:10.4103/0378-6323.13777
10. Fearmonti R, Bond J, Erdmann D, Levinson H. A review of scar scales and scar measuring devices. *Eplasty.* 2010;10:354–363.
11. Thompson CM, Sood RF, Honari S, Carrouger GJ, Gibran NS. What score on the Vancouver Scar Scale constitutes a hypertrophic scar? Results from a survey of North American burn-care providers. *Burns.* 2015;41(7):1442–1448. doi:10.1016/j.burns.2015.04.018
12. Ly BC, Dyer EB, Feig JL, Chien AL, Del-Bino S. Research techniques made simple: cutaneous colorimetry: a reliable technique for objective skin color measurement. *J Invest Dermatol.* 2020;140(1):3–12. doi:10.1016/j.jid.2019.11.003
13. Taylor S, Westerhof W, Im S, Lim J. Non-invasive techniques for the evaluation of skin colour. *J Am Acad Dermatol.* 2006;54:282–290. doi:10.1016/j.jaad.2005.12.041

### International Medical Case Reports Journal

Dovepress

### Publish your work in this journal

The International Medical Case Reports Journal is an international, peer-reviewed open-access journal publishing original case reports from all medical specialties. Previously unpublished medical posters are also accepted relating to any area of clinical or preclinical science. Submissions should not normally exceed 2,000 words or 4

published pages including figures, diagrams and references. The manuscript management system is completely online and includes a very quick and fair peer-review system, which is all easy to use. Visit <http://www.dovepress.com/testimonials.php> to read real quotes from published authors.

Submit your manuscript here: <https://www.dovepress.com/international-medical-case-reports-journal-journal>