

# Efficacy of Triamcinolone Acetonide Injection in a Case of Giant Spiradenoma

Eva Krishna Sutedja , Rafithia Anandita, Endang Sutedja , Inne Arline Diana, Kartika Ruchiatan 

Department of Dermatology and Venereology, Faculty of Medicine, Universitas Padjadjaran - Dr. Hasan Sadikin General Hospital, Bandung, West Java, Indonesia

Correspondence: Eva Krishna Sutedja, Department of Dermatology and Venereology, Faculty of Medicine, Universitas Padjadjaran - Dr. Hasan Sadikin General Hospital, Jl. Pasteur No. 38, Bandung, West Java, 40161, Indonesia, Tel +628122014300, Email evakrishna@yahoo.com

**Abstract:** Spiradenoma is a rare benign adnexal tumor with eccrine differentiation. The clinical manifestations include painful, skin-colored, red, gray, or bluish nodules on the upper half of the body. We report a case of spiradenoma in a 31-year-old man. The diagnosis was established from the patient's history, physical examination, and histopathological examination. In this case, the patient was treated with intralesional injection of triamcinolone acetonide (TA) 10 mg/mL. After the fourth injection, the lesions grew smaller and thinner. TA injection is easy to administer and showed good efficacy in spiradenoma case, although further research with a larger number of patients is needed.

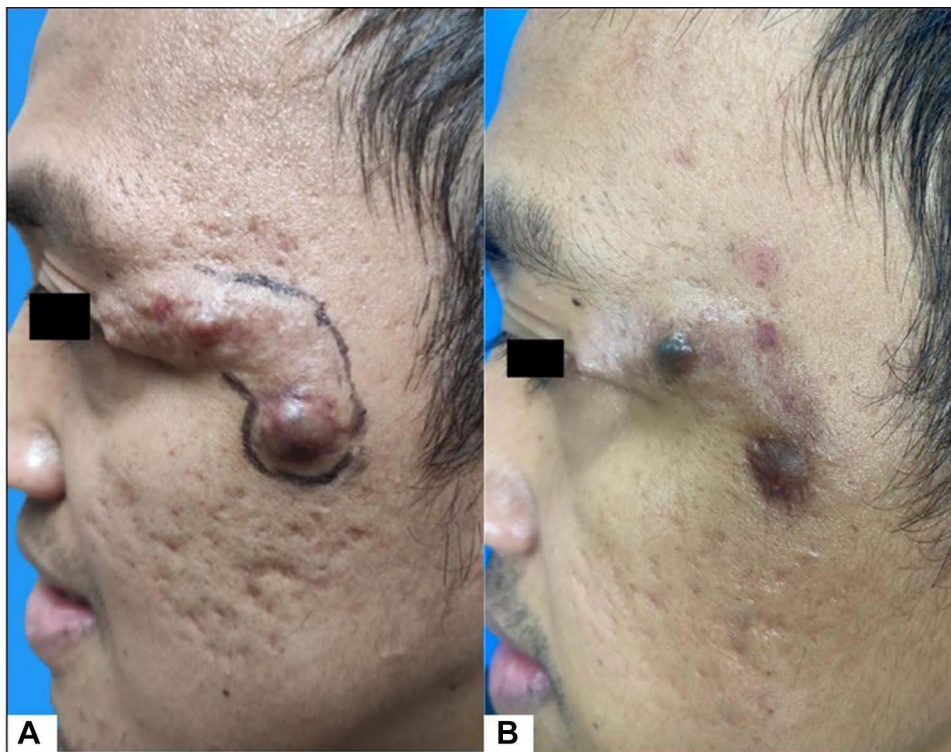**Keywords:** adnexal tumor, eccrine glands, rare case, spiradenoma, triamcinolone acetonide injection

## Introduction

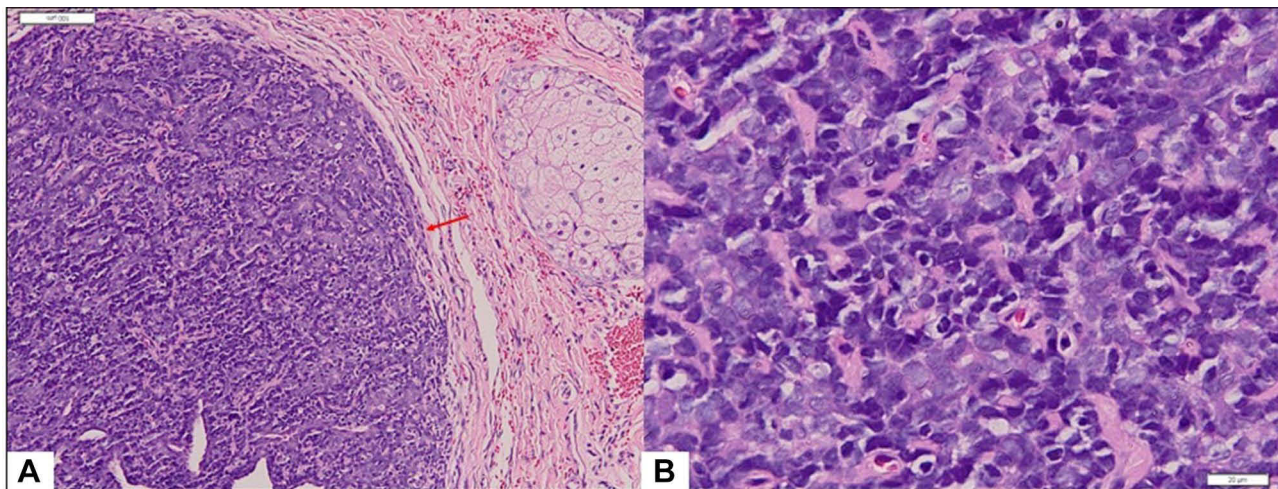
Spiradenoma is a rare type of adnexal tumors originating from the eccrine glands.<sup>1,2</sup> The etiology remains unknown. This condition was first introduced by Kersting and Helwig in 1956.<sup>1</sup> Its clinical features consist of skin-colored, erythematous, gray, or bluish<sup>2</sup> nodules<sup>1</sup> accompanied with pain.<sup>1,2</sup> The lesions of spiradenoma are generally solitary,<sup>1</sup> with the most common predilection being on the ventral part of the body,<sup>3</sup> especially on the upper part of the trunk.<sup>1</sup> Atypical clinical features of spiradenoma may occur as multiple lesions arranged in a linear or zosteriform arrangement.<sup>2,3</sup> Spiradenoma can occur at any age,<sup>1</sup> most commonly between 15 and 35 years old.<sup>2</sup> There is no difference of incidence among genders.<sup>1,2</sup> There are various therapeutic modalities for spiradenoma, including surgical excision, dermabrasion, electrodesiccation, cryosurgery, radiotherapy, and CO<sub>2</sub> laser.<sup>2,4</sup> However, the efficacy of some of these modalities has not been determined.<sup>4</sup> In 2013, Gordon et al<sup>5</sup> in the United States reported a case of spiradenoma treated using injection of triamcinolone acetonide (TA) 10 mg/mL with minimal improvement. Gottschalk et al<sup>6</sup> administered TA 40 mg/mL in one case of adnexal tumor with a 75% reduction in lesion size. This study aims to report a rare case of giant spiradenoma which was treated by 10 mg/mL TA injection.

## Case Presentation

A 31-year-old man presented with giant painful skin-colored and erythematous nodules on his left eyelid and left temple (Figure 1A). The lesion first appeared 15 years prior to consultation as a skin-colored papule on the left eyelid which enlarged into a nodule after 5 years. New nodules appeared on his left temple around 5 years ago and grew larger one year prior. There was no other significant past medical or family history. Dermatological examination revealed firm, skin-colored nodules with smooth surface and well-defined boundaries, painful upon palpation, measuring 1.5×2.8 x 0.3 cm and 1.6×1.7 x 0.4 cm. We performed a punch biopsy on the left temple. The histopathological result revealed a tumor mass consisting of round to oval cells with hyperplastic, compact, and nodular characteristics. Some cells formed a tubular structure, and some appeared paler and larger. The cells had monomorphous nuclei with few inflammatory cells. There were no signs of malignancy (Figure 2A and B). The patient refused surgical therapy. Therefore, we performed intralesional injection of 10 mg/mL TA, consisting of five injections per visit. After four sessions of TA injections with



**Figure 1** (A) Clinical manifestations of spiradenoma in the form of skin-colored and erythematous nodules on the left eyelid and left temple before triamcinolone acetonide injection. (B) Spiradenoma lesions after triamcinolone acetonide injection.



**Figure 2** Histopathological findings. (A) Red arrow shows one tumor mass. (B) Tumor mass consisted of round, oval cells showing hyperplastic, compact, and nodular characteristics. Some formed a tubular structure. Some cells appeared paler and larger.

one month interval, the lesions grew thinner and smaller and the pain disappeared (Figure 1B). There were no side effects reported.

## Discussion

Adnexal tumors are classified based on their differentiation in forming skin adnexal structures into eccrine, apocrine, follicular, and sebaceous gland tumors. They are further divided into benign and malignant types. Benign tumors of the

eccrine glands include cylindroma, hidradenoma, syringoma, poroma, and spiradenoma.<sup>3</sup> There was no report on the prevalence of spiradenoma worldwide. It is considered to be a very rare disease.<sup>1,2</sup>

The exact etiology and pathogenesis of spiradenoma are unknown. It is suspected that a defect in the tumor suppressor gene plays a role in this disease.<sup>2</sup> Several recent hypotheses have been proposed regarding spiradenoma, including abnormal multipotent stem cells in the folliculosebaceous unit and trauma as a triggering factor.<sup>7</sup>

Spiradenoma is characterized by skin-colored, erythematous, gray, or bluish<sup>2,3</sup> nodules<sup>1</sup> accompanied by pain.<sup>1,2</sup> The lesions are generally solitary,<sup>1</sup> and are often found on the ventral part of the body,<sup>3</sup> especially the trunk.<sup>1</sup> Our case of spiradenoma manifested as painful skin-colored and erythematous nodules on the patient's face. This is in accordance with the signs, symptoms, and predilection of spiradenoma.

Some tumors of the skin are difficult to diagnose clinically due to the lack of external characteristics that allow recognition through inspection alone. Several painful subcutaneous tumors which can be considered as differential diagnoses are spiradenoma, neuroma, glomus tumor, leiomyoma, angioliipoma, neurilemmoma, and dermatofibroma.<sup>8</sup> Histopathological examination is therefore necessary to establish the diagnosis of spiradenoma.<sup>9</sup> The histopathological features of spiradenoma include non-capsulated dermal neoplasms with single or multinodular nodules,<sup>10</sup> consisting of basaloid cells, arranged in a tubular structure.<sup>3</sup> There are two types of cells that can be found: small basaloid cells with hyperchromatic nuclei and little cytoplasm located at the edge of the nodules, and large basaloid cells with vesicular nuclei and pale cytoplasm located in the center of the nodules.<sup>3,8,10</sup> Lymphocytes are also scattered throughout the tumor.<sup>3</sup> The histopathological examination result in our case supported the diagnosis of spiradenoma.

Surgical excision is the current gold standard for treating spiradenoma with low recurrence rates. Meanwhile, the efficacy of several other therapeutic modalities has yet to be determined.<sup>4</sup> Several investigators had studied other less invasive therapies for spiradenoma. In 2013, Gordon et al<sup>5</sup> in the United States reported a case of spiradenoma treated using intralesional 10 mg/mL TA injection, but there was minimal improvement. Gottschalk et al<sup>6</sup> treated a skin adnexal tumor with intralesional 40 mg/mL TA injection. A total of 1 mL of 40 mg/mL TA aqueous suspension was injected into a single 4 cm lesion. After one injection, the size of the tumor was reduced by 75%.<sup>6</sup> Steroid use in this case aimed to reduce inflammation that can be associated with pain.<sup>5</sup> Corticosteroids have anti-inflammatory, immunosuppressive, antiproliferative, and vasoconstrictive effects.<sup>11</sup> The intralesional skin injection method was chosen to achieve a localized corticosteroid concentration in the lesion with less systemic absorption, thereby avoiding systemic side effects. The mechanism of how intradermal steroid affects the course of the disease remains unknown.<sup>12</sup> Our patient was treated with intralesional 10 mg/mL TA injections due to refusal to undergo surgery. Improvement was observed after the fourth injection: the skin lesions became thinner and smaller. The pain also diminished.

## Conclusion

Intralesional injection of TA can be a therapeutic option for spiradenoma patients who refuse surgical therapy. TA injection is easy to administer and showed good efficacy in spiradenoma case, although further research with a larger number of patients remains needed.

## Ethical Statement

The publication of case images was included in the patient's consent. Institutional approval to publish case details has been obtained.

## Consent Statement

The authors have obtained all appropriate patient consent forms. The patient signed a consent form for the publication of case details and images.

## Acknowledgments

The authors would like to thank the entire staff of the Dermatology and Venereology Department, Faculty of Medicine, Universitas Padjadjaran – Hasan Sadikin General Hospital Bandung, West Java Indonesia.

## Disclosure

The authors report no conflicts of interest in this work.

## References

1. Kanwaljeet S, Chatterjee T. Eccrine spiradenoma: a rare adnexal tumor. *Indian J Cancer*. 2017;54(4):695. doi:10.4103/ijc.IJC\_301\_17
2. Dhua S, Sekhar DR. A rare case of eccrine spiradenoma—treatment and management. *Eur J Plast Surg*. 2016;39(2):143–146. doi:10.1007/s00238-015-1103-4
3. Foreman RK, Duncan LM. Appendage tumors of the skin. In: Kang S, Amagai M, Bruckner AL, Enk AH, Margolis DJ, McMichael AJ, editors. *Fitzpatrick's Dermatology*. 9th ed. New York: McGraw-Hill; 2019:1820–1853.
4. Nath AK, Kumari R, Thappa DM. Eccrine spiradenoma with chondroid syringoma in Blaschkoid distribution. *Indian J Dermatol Venereol Leprol*. 2009;75(6):600. doi:10.4103/0378-6323.57723
5. Gordon S, Styron BT, Haggstrom A. Pediatric segmental eccrine spiradenomas: a case report and review of the literature. *Pediatr Dermatol*. 2013;30(6):e285–e286. doi:10.1111/j.1525-1470.2012.01777.x
6. Gottschalk HR. Dermatological clinical conference scientific program for the 102nd annual session California medical association. *Arch Dermatol*. 1974;110(3):473–479. doi:10.1001/archderm.1974.01630090095041
7. Englander L, Emer JJ, McClain D, Amin B, Turner RB. A rare case of multiple segmental eccrine spiradenomas. *J Clin Aesthet Dermatol*. 2011;4(4):38.
8. Naversen DN, Trask DM, Watson FH, Burket JM. Painful tumors of the skin: “LEND AN EGG”. *J Am Acad Dermatol*. 1993;28(2):290–300. doi:10.1016/0190-9622(93)70039-V
9. Sharma A, Paricharak DG, Nigam JS, et al. Histopathological study of skin adnexal tumours—institutional study in South India. *J Skin Cancer*. 2014;2014:1–4. doi:10.1155/2014/543756
10. Weedon D. Tumors of cutaneous appendages. In: *Weedon's Skin Pathology*. 3rd ed. Brisbane: Elsevier Inc; 2010:758–807.
11. Kerscher M, Williams S, Lehmann P. Topical treatment with glucocorticoids. In: Ring J, Przybilla B, Ruzicka T, editors. *Handbook of Atopic Eczema*. 2nd ed. New York:Springer-Verlag Berlin Heidelberg; 2006:477–491.
12. Firooz A, Tehranchia-Nia Z, Ahmed AR. Benefits and risks of intralesional corticosteroid injection in the treatment of dermatological diseases. *Clin Exp Dermatol*. 1995;20(5):363–370. doi:10.1111/j.1365-2230.1995.tb01351.x

International Medical Case Reports Journal

Dovepress

### Publish your work in this journal

The International Medical Case Reports Journal is an international, peer-reviewed open-access journal publishing original case reports from all medical specialties. Previously unpublished medical posters are also accepted relating to any area of clinical or preclinical science. Submissions should not normally exceed 2,000 words or 4 published pages including figures, diagrams and references. The manuscript management system is completely online and includes a very quick and fair peer-review system, which is all easy to use. Visit <http://www.dovepress.com/testimonials.php> to read real quotes from published authors.

Submit your manuscript here: <https://www.dovepress.com/international-medical-case-reports-journal-journal>