


# Iatrogenic Ureteral and Colonic Injuries During Emergency Cesarean Section: A Lesson Learned from a Surgical Catastrophe – A Case Report

Faisal Ahmed <sup>1</sup>, Saleh Al-Wageeh <sup>2</sup>, Mohamed Badheeb<sup>3</sup>, Abdulfattah Altam<sup>4</sup>, Afaf Alsharif<sup>5</sup>

<sup>1</sup>Department of Urology, School of Medicine, Ibb University of Medical Sciences, Ibb, Yemen; <sup>2</sup>Department of General Surgery, School of Medicine, Ibb University of Medical Sciences, Ibb, Yemen; <sup>3</sup>Department of Internal Medicine, Faculty of Medicine, Hadhramout University, Hadhramout, Yemen; <sup>4</sup>Department of General Surgery, School of Medicine, 21 September University, Sana'a, Yemen; <sup>5</sup>Department of Gynecology, School of Medicine, Jebelah University for Medical and Health Sciences, Ibb, Yemen

Correspondence: Faisal Ahmed, Department of Urology, School of Medicine, Ibb University of Medical Sciences, Ibb, Yemen, Tel/Fax +967 4428950, Email fmaaa2006@yahoo.com

**Introduction:** Iatrogenic concomitant ureteral and colonic injury in emergency cesarean section (C-section) is an exceedingly rare, yet, catastrophic complication and has not been reported to our knowledge.

**Case Report:** A 30-year-old woman presented with decreased urination for 2 days after a C-section. Ultrasonography showed severe left hydronephrosis and moderate abdominal free fluid. A ureteroscopy revealed a total occlusion of the left ureter, and subsequently, a ureteroneocystostomy was performed. Two days later, the patient was complicated with abdominal distension that necessitated re-exploration. The exploration revealed colonic injury (rectosigmoid), peritonitis, endometritis, and ureteral anastomosis disruption. A colostomy, repair of colonic injury, hysterectomy, and ureterocutaneous diversion were performed. The patient's hospital stay was complicated, with stomal retraction requiring operative revision and wound dehiscence, which was treated conservatively. After 6 months, the colostomy was closed, and the ureter was anastomosed via the Boari-flap procedure.

**Conclusion:** Injuries to the urinary and gastrointestinal tracts are serious complications of a cesarean section; concurrent involvement is exceedingly rare; however, delayed recognition and intervention can worsen the prognosis.

**Keywords:** case report, cesarean section, colon injury, iatrogenic, ureteral injury

## Plain Language Summary

Iatrogenic concomitant ureteral and colonic injury in a cesarean section is exceedingly rare and may be associated with catastrophic complications if not treated promptly. We report a 30-year-old woman presented with decreased urination for 2 days after a C-section. While the ureteral injury was diagnosed, the colonic injury was initially missed, leading to severe consequences such as peritonitis, endometritis, and disruption of the ureteral anastomosis, which required a colostomy, repair of the colonic injury, hysterectomy, and ureterocutaneous diversion. However, the colostomy stoma was initially placed in an improper position, which required operative revision. Finally, after 6 months, the colostomy was closed, and the ureter was anastomosed using the Boari-flap procedure. Our report highlights the rare but serious nature of such injuries, which can result in catastrophic complications after emergency C-sections, possibly due to improper management. We believe that a multidisciplinary approach with high attention to detail can help prevent such sequelae.

## Introduction

Ureteral injuries during gynecologic surgeries are uncommon, given the proximity of urologic and gynecologic structures within the pelvis. Nevertheless, the intra-operative identification of such injuries can be challenging, especially during emergent gynecological operations when the fetus is also in danger.<sup>1</sup> Recently, cesarean sections (C-sections) have been performed more frequently in low-income countries, with increased complication rates, especially in regional hospitals

where many complications can be missed or under-reported.<sup>2</sup> However, the incidence of ureteral and bowel injuries in C-sections remains low and was reported at about 0.4% and 0.54%, respectively.<sup>2-4</sup>

Iatrogenic concomitant ureteral and colonic injury in emergency C-sections is an exceedingly rare yet catastrophic complication that has not been reported in the literature to our knowledge. Report of such cases sheds light on the nature of this problem and gives insight for surgeons to avoid catastrophic subsequences if this complication is not promptly treated. Herein, we present a case of an iatrogenic concomitant ureteral and colonic injury due to an emergency C-section in a 30-year-old female who experienced several unforeseen complications in a resource-limited setting.

## Case Report

A 30-year-old gravida 3, para 3 woman presented with decreased urination, left flank pain, and fever for 2 days after an emergency C-section for the first time, indicated due to fetal and maternal distress secondary to prolonged labor and prolonged vaginal bleeding in Al-Thora hospital, Ibb, Yemen. Despite resuscitative efforts, her newborn expired after 45 minutes. During the C-section, severe uterine adhesions were identified (As there were lesions of endometriosis, and adhesions between the posterior wall of the uterus and the sigmoid colon), and an estimated blood loss of 1500 cc, according to the gynecologist report. The patient did not receive any prenatal care during her pregnancy. She is a nonsmoker and denied chronic medical conditions, drug abuse, accidental poisoning, or previous surgical history.

On physical examination, the patient appeared pale, ill, and febrile during the initial evaluation, with an oral temperature of 38 °C, pulse rate of 80 beats per minute, and blood pressure of 95/70 mm Hg. The patient's abdomen was mildly distended, with moderate tenderness, primarily in the left lower quadrant.

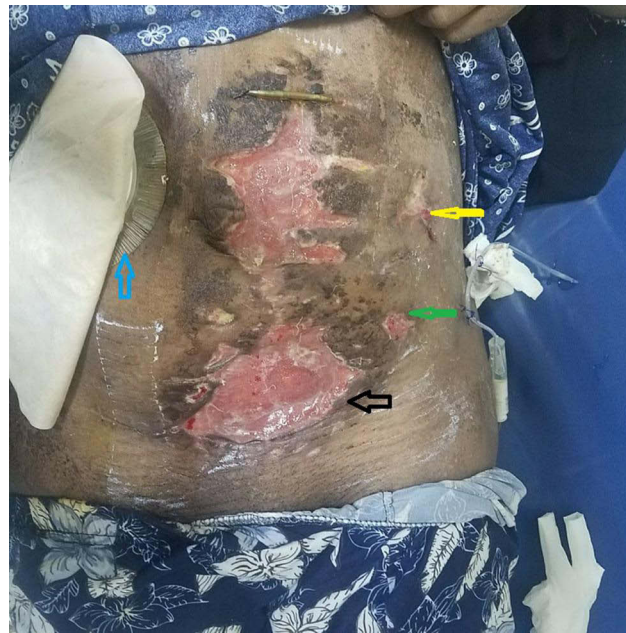
The laboratory data were as follows: White blood cell (WBC) count was  $15.3 \times 10^3/\text{mL}$ , with 90% polymorph neutrophils (Leukocytosis with neutrophilic predominance), hemoglobin was 7.5 g/dL, platelets count was  $200 \times 10^3/\mu\text{L}$ , blood urea nitrogen (BUN) was 23 mg/dl, and creatinine was 3.8 mg/dl. Other blood tests, such as liver function and coagulation tests, were within normal ranges. Ultrasonography (US) showed severe left hydronephrosis and moderate free fluid in the abdominal cavity. The abdominal tap aspiration was performed, and the spot creatinine was 52 mg/dL indicating that the fluid was urine.

The patient was resuscitated with packed red blood cells and broad antibiotic coverage. Thereafter, she urgently underwent a ureteroscopy that showed a total occlusion of the left ureter. Subsequently, a decision to surgical exploration was made, given the hemodynamic instability, lack of percutaneous nephrostomy equipment, and the evidence of intra-abdominal contamination. Intra-operatively, we found moderate free fluid in the abdominal cavity. The left ureter was crushed and ligated with a Vicryl suture (5 sticks) at around 5 cm of its distal part. After fluid evacuation, the injured segment of the ureter was excised and ureteroneocystostomy in a refluxing manner was performed after bladder distention with saline through the catheter. Additionally, we dissected the ureter, carefully, from the surrounding tissues in the cephalad direction, spatulated the distal ureteral end, and inserted a double j stent. The ureter was implanted in the posterior dome of the urinary bladder with tension-free anastomosis and sutured with 4-0 Vicryl through the full-thickness ureter, then the bladder mucosal and detrusor layer. A Jackson-Pratt (JP) drain near the anastomosis was inserted, and the abdominal wall was closed after evaluating the intraperitoneal content.

## Follow-Up and Outcome

Clear fluids were started on the second postoperative day. The patient had mild abdominal distension, pain, and nausea. On the third postoperative day, she had increasing abdominal distension and stopped passing flatus. The abdominal US showed a large amount of collection in the peritoneal cavity. The blood laboratory data showed a leukocytosis (WBC of  $22 \times 10^3/\text{mL}$  with a left shift).

A computed tomography (CT) scan of the abdomen and pelvis with contrast revealed a significant amount of free air and fluid throughout the abdomen and pelvis adjacent to the anterior abdominal wall. Multiple free gas locules were also seen in the mesentery, with contrast enhancement of multiple small bowel loops, with no evidence of contrast extravasation. The findings suggested a perforated viscus. After consulting the general surgery team, the patient was immediately taken to the operating room for an exploratory laparotomy, which revealed a small perforation in the rectosigmoid part with some spillage, peritonitis with bowel loop edema, and ureteral anastomosis disruption. The



**Figure 1** Postoperative photo of the patient showing wound dehiscence (green arrow: site of previous colostomy, yellow arrow: site of skin ureterostomy, blue arrow: site of new colostomy, black arrow: site of the infected wound).

complexity of this case forced us to perform multi-staged interventions in a multidisciplinary fashion. Firstly, the gynecologist performed a hysterectomy due to endometritis (confirmed histopathologically), severe oozing, and suture disruption of the uterus. Secondly, the ureterocutaneous diversion of the left ureter was performed by a urologist, and the ureterostomy was created on the left side. Lastly, the general surgeon performed the colostomy procedure after the repair of the colonic injury, and the colostomy was created on the left side. On the fifth postoperative day, colostomy retraction occurred with wound infection, and communication between colostomy and ureterostomy was observed. Re-exploration was decided to relocate the sigmoid colostomy, and a transverse right-side end colostomy was done (Figure 1). One week postoperatively, the patient experienced a superficial skin abdominal wall infection complicated with wound dehiscence and hypoalbuminemia (albumin: 2 g/dL) that required treatment with several debridement, wound irrigation, antibiotics, and supportive therapy. The recommended antibiotics were linezolid (600 mg IV every 12 hours for 7 days), then changed to ceftriaxone (1g IV every 12 hours for 5 days) plus metronidazole (500 mg IV every 12 hours for 5 days) and changed to oral ciprofloxacin (500mg every 12 hours orally for 7 days). She gradually resumed her normal diet and was discharged 30 days later in stable condition. She required home care to assist with her colostomy, ureterostomy, and ambulation.

Six months later, the colostomy was closed, and the ureter was anastomosed via the Boari tabularized bladder flap procedure (the bladder was opened on its anterior surface, and a full-thickness bladder flap was flipped caudally and tabularized for anastomosis to the proximal ureteral segment after double j stent insertion). After an uneventful postoperative recovery, the patient was discharged on the seventh postoperative day. One-month follow-up by US and voiding cystourethrography showed a normal appearance of the bladder with adequate bladder capacity and normal upper urinary tract system. Three months later, retrograde ureteroscopy showed an adequate caliber of the ureter. The patient was regularly followed up with the US for 3 months for a year. The patient had no irritative or gastrointestinal symptoms within 2 years of follow-up.

## Discussion

The rate of C-sections in developing countries has increased in recent years, subsequently increasing its complications. In addition, compared to tertiary centers, C-sections performed at rural hospitals with limited resources are linked to higher rates of complications.<sup>2</sup> We reported a rare complication of ureteral ligation and colonic injury in a complicated

emergency C-section that experienced severe catastrophic subsequences and was treated with several surgical interventions. Such a case is rare and has not been reported in the literature.

Women with a history of endometriosis have an increased risk of obstetric complications, and adhesions caused by endometriosis are difficult to predict preoperatively.<sup>5</sup> In our patient, there was no history of previous surgery; however, incidental lesions of endometriosis were discovered during C-section that may cause severe adhesion.<sup>5</sup>

Following cesarean delivery, our patient experienced four unfortunate complications, including accidental ureteral ligation, missed colonic injury, wound dehiscence following several surgical procedures, and a grievous stillbirth. Each of which had a dreadful physical and mental impact.

Iatrogenic ureteral ligation in the C-section procedure is uncommon, with an incidence of 0.10–0.27%.<sup>6</sup> Although surgical treatment of ureteral injuries is simple and effective once identified intra-operatively, these injuries are typically missed in 67–89% of all cases.<sup>6</sup> The majority of ureteral injuries during C-sections are a result of the hemostatic sutures that are used to control bleeding. Less frequently, ureters can be directly injured by extending a uterine incision, resulting in partial or complete ureter transection. Ustunsoz et al reported a 13 of 24 ureteral injuries had complete obstruction due to hemostatic sutures.<sup>6</sup> Similarly, in our case, the cause of complete obstruction is due to hemostatic sutures. Our case was consistent with recent literature, which reports a shift from transection to obstructive ureter injuries in recent years.<sup>7</sup> This is likely due to global surgical teams' enhanced technique and experience. Interestingly, we observed that most of the gynecologists in our center sutured the uterus with long needle lengths (Vicryl 1/0, needle length: 22mm) to avoid bleeding and longer operative time.<sup>8</sup> However, such long needles have increased the risk of ureteral ligation, as was seen in our case. Direct pressure, sharp dissection, and exposure of the bleeding vessels, followed by accurate and precise suturing, should be used to treat sudden hemorrhage.<sup>9</sup>

A delayed diagnosis is the single controllable factor that adversely affects the outcome, so recognizing the ureteral injury as soon as possible is critical.<sup>10</sup> The impact of delayed recognition of such a complication has direful physical, mental, and legal consequences.<sup>2</sup> The diagnosis of ureter injury necessitates a high level of suspicion, and it is generally difficult to make unless there is a leak. A total ureteral occlusion may be silent until a secondary urinary infection or pain develops. The reported time from diagnosis to treatment was  $21 \pm 50.1$  days (range: 1 day–8 months).<sup>6</sup> In our case, the diagnosis of ureteral injury was made 2 days after the C-section, and the patient had signs of peritonitis.

Early repair is debatable, but it may be possible if the injury is discovered within the first 72 hours after surgery. To avoid the inflammatory phase, urinary diversion with a ureteral stent, percutaneous nephrostomy, or both is recommended after 6 weeks, followed by a delayed repair.<sup>11</sup> In our case, the decision to surgical exploration was made, given the hemodynamic instability, lack of percutaneous nephrostomy equipment, and the evidence of intra-abdominal contamination.

If the ureteric injury is suspected postoperatively, radiologic investigations such as abdominal US and CT scans help recognize the site and the nature of the injuries.<sup>2</sup> If the contrast CT scan cannot be performed due to high creatinine, unavailability, or emergencies, ureteroscopy and retrograde urethrography may be helpful in ureteral injury detection.<sup>2</sup> In our case, the creatinine level was high (possibly a result of its absorption from the peritoneal cavity due to ureteral injury), and the ureteroscopy showed a total occlusion of the distal part of the ureter, indicating a total occlusion of the ureter. The patient US showed hydronephrosis and free fluid in the abdominal cavity. In addition, urine peritonitis was documented by high creatinine levels of the aspirated abdominal fluid.

Regarding rectosigmoid injury during C-section, the frequency of small bowel injury during peritoneal entry was reported to be 0.0003/10.000 C-section. The incidence of bowel injuries in C-sections is low and ranges from 0.08% to 0.54%.<sup>3,4</sup> Intestinal injuries can cause harm in a variety of ways. Bowel loops may be adherent to the anterior abdominal wall, especially if surgery through a midline incision has occurred, and may be damaged during peritoneal entry or if extensive adhesion division is required before delivery. In addition, it may be damaged during the closure after delivery. It is possible to include bowel loops within the sutures posterior to the uterus while closing the uterus, especially if angle extensions are present.<sup>12</sup> Bowel injury that is not recognized intraoperatively usually manifests as signs and symptoms of intra-abdominal sepsis. In the case of diathermy-induced perforation, this could take several days. The early recognition of bowel injuries can be challenging, even with imaging, as extraluminal air and fluid may be seen on CT imaging are frequently seen in the immediate postoperative period. Other radiological findings that may aid in the diagnosis include protruding intestinal loops,

inflammation/abscess formation, and oral contrast material leakage, all signs of gastrointestinal perforation. Signs of peritonitis may not allow performing primary repair and diversion with colostomy procedures highly recommended.<sup>5,12</sup> Some factors such as the complexity of the operative phase, use of electrosurgical energy, surgeon's experience, the presence of adhesions between the rectum and uterus, omitted observation of the gastrointestinal contents, and absence of typical symptoms of bowel injury may contribute to increasing the risk for bowel injuries misdiagnosis and subsequently increases the rates of morbidity and mortality.<sup>5,12</sup> We recommended careful abdominal examination, gentle dissection of the tissues, and high suspicion of high-risk patients with previous abdominal operations.

In our case, unfortunately, the colonic injury was not recognized at the time of operation nor in the second operation (ureteral reimplantation) and subsequently led to ureteral anastomosis disruption and severe peritonitis and the need for ureterostomy and colostomy procedures. The doubt that sigmoid injury may occur during the ureteroneocystostomy procedure is possible. However, in this case, the ureter was implanted in the posterior dome of the urinary bladder which is far away from the sigmoid wall. Additionally, the colostomy procedure was implanted at the ureterostomy site, leading to wound infection and osteoma retraction. This issue was repaired with osteoma relocation to the right side. In our case, the main cause of this complication was that a beginner surgeon with little experience in this field performed the osteoma.

Regarding post-C-section surgical site infection and wound dehiscence, its overall rate is 9.6%, and this risk increased in endometritis and emergency cases.<sup>12</sup> Diabetes, infection, suture methodology, a hematoma on the uterine incision line, and retrovesical hematoma are all risk factors.<sup>13</sup> Most of these cases may be successfully managed with proper antibiotics and conservative treatment; as was performed in our case.<sup>13</sup>

Urologists have long struggled to repair ureteral long-segmented defects. Psoas bladder hitch, ureter replacement, renal auto-transplantation, Boari flap, and nephrectomy are all suggested surgical procedures.<sup>14</sup> Boari flap procedure is usually used in affected distal or mid ureter without needing bowel segment resection or bladder augmentation. However, it may reduce bladder capacity and is ineffective for longer ureteral defects (more than 15 cm).<sup>14</sup> In our case, the defect was in the med ureter, the procedure was successful, and postoperative bladder capacity and ureteral caliber were acceptable.

In terms of stillbirth, lack of access to antenatal care contributes to rising stillbirth rates in low-income countries. Most stillbirths in the developing world are caused by prolonged and difficult labor, preeclampsia, and infections. Furthermore, providing elementary newborn care training to birth attendants in developing countries reduces stillbirths.<sup>15</sup> In our case, instead of no regular perinatal care, our patient had vaginal bleeding, fetal distress, and basic newborn care training not optimal as we lack the person and equipment in a resource-limited setting which unfortunately leads to the baby's death.

Our report highlights the rare serious injuries of several catastrophic complications after emergency C-section, which may be secondary to improper management. We think treatment with a multidisciplinary team with high tension may prevent such sequels.

## Conclusion

Ureteral injury and colonic injury are serious complications of a cesarean section; concurrent involvement is exceedingly rare; however, delayed recognition and intervention can worsen the prognosis. The surgeons should consider the possibility of unusual findings and be familiar with delayed presentations of visceral and urologic injuries, particularly in low-resource settings. Multidisciplinary team management is highly recommended to investigate and treat these complications promptly.

## Consent

Written informed consent was obtained from the patient to publish this case report and any accompanying images. No institutional approval was required to publish the case report.

## Acknowledgment

The authors would like to thank the General Manager of Althora General Hospital, Ibb, Yemen, Dr Abdulghani Ghabisha, for editorial assistance.



## Disclosure

The authors declare that they have no conflicts of interest in this work.

## References

1. Raassen T, Ngongo CJ, Mahendeka MM. Diagnosis and management of 365 ureteric injuries following obstetric and gynecologic surgery in resource-limited settings. *Int Urogynecol J*. 2018;29(9):1303–1309. doi:10.1007/s00192-017-3483-4
2. Field A, Haloob R. Complications of caesarean section. *Obstet Gynaecol*. 2016;18(4):265–272. doi:10.1111/tog.12280
3. Bhattee GA, Rahman J, Rahman MS. Bowel injury in gynecologic operations: analysis of 110 cases. *Int Surg*. 2006;91(6):336–340.
4. Jones OH. Cesarean section in present-day obstetrics. Presidential address. *Am J Obstet Gynecol*. 1976;126(5):521–530. doi:10.1016/0002-9378(76)90742-0
5. Suzuki N, Wakaki Y, Watanabe K, et al. Difficulty in predicting intra-abdominal adhesion before cesarean section: a case report. *Clin Case Rep*. 2022;10(3):e05643. doi:10.1002/ccr3.5643
6. Ustunsoz B, Ugurel S, Duru NK, et al. Percutaneous management of ureteral injuries that are diagnosed late after cesarean section. *Korean J Radiol*. 2008;9(4):348–353. doi:10.3348/kjr.2008.9.4.348
7. Rajasekar D, Hall M. Urinary tract injuries during obstetric intervention. *Br J Obstet Gynaecol*. 1997;104(6):731–734. doi:10.1111/j.1471-0528.1997.tb11986.x
8. Benkirane S, Saadi H, Serji B, et al. Uterine necrosis following a combination of uterine compression sutures and vascular ligation during a postpartum hemorrhage: a case report. *Int J Surg Case Rep*. 2017;38:5–7. doi:10.1016/j.ijscr.2017.07.005
9. Pal DK, Wats V, Ghosh B. Urologic complications following obstetrics and gynecological surgery: our experience in a tertiary care hospital. *Urol Ann*. 2016;8(1):26–30. doi:10.4103/0974-7796.158502
10. Antoniou E, Orovou E, Iliadou M, et al. Factors associated with the type of cesarean section in Greece and their correlation with international guidelines. *Acta Inform Med*. 2021;29(1):38–44. doi:10.5455/aim.2021.29.38-44
11. Smith AP, Bazinet A, Liberman D. Iatrogenic ureteral injury after gynecological surgery. *Can Urol Assoc J*. 2019;13(6Suppl4):S51–s55. doi:10.5489/cuaj.5936
12. Visconti F, Quaresima P, Rania E, et al. Difficult caesarean section: a literature review. *Eur J Obstet Gynecol Reprod Biol*. 2020;246:72–78. doi:10.1016/j.ejogrb.2019.12.026
13. Yu L, Kronen RJ, Simon LE, et al. Prophylactic negative-pressure wound therapy after cesarean is associated with reduced risk of surgical site infection: a systematic review and meta-analysis. *Am J Obstet Gynecol*. 2018;218(2):200–210.e201. doi:10.1016/j.ajog.2017.09.017
14. Bai Y, Wei H, Ji A, et al. Reconstruction of full-length ureter defects by laparoscopic bladder flap forming. *Sci Rep*. 2021;11(1):3970. doi:10.1038/s41598-021-83518-0
15. McClure EM, Nalubamba-Phiri M, Goldenberg RL. Stillbirth in developing countries. *Int J Gynaecol Obstet*. 2006;94(2):82–90. doi:10.1016/j.ijgo.2006.03.023

International Medical Case Reports Journal

Dovepress

Publish your work in this journal

The International Medical Case Reports Journal is an international, peer-reviewed open-access journal publishing original case reports from all medical specialties. Previously unpublished medical posters are also accepted relating to any area of clinical or preclinical science. Submissions should not normally exceed 2,000 words or 4 published pages including figures, diagrams and references. The manuscript management system is completely online and includes a very quick and fair peer-review system, which is all easy to use. Visit <http://www.dovepress.com/testimonials.php> to read real quotes from published authors.

Submit your manuscript here: <https://www.dovepress.com/international-medical-case-reports-journal-journal>