

Co-Occurring EGFR S645C and EGFR L858R in a Patient with Lung Adenocarcinoma Induced Primary Resistance to Osimertinib

Li Wang^{1,*}, Fei Quan^{2,*}, Zhen Guo³, Zhongyu Lu², Duoxia Yang², Meiqi Shi¹

¹Department of Medical Oncology, Jiangsu Cancer Hospital & Jiangsu Institute of Cancer Research & The Affiliated Cancer Hospital of Nanjing Medical University, Nanjing, People's Republic of China; ²The Medical Department, Nanjing Sincere Medical Laboratory Science Co., Ltd, Nanjing, People's Republic of China; ³Radiology Department, Jiangsu Cancer Hospital & Jiangsu Institute of Cancer Research & The Affiliated Cancer Hospital of Nanjing Medical University, Nanjing, People's Republic of China

*These authors contributed equally to this work

Correspondence: Meiqi Shi, Department of Medical Oncology, Jiangsu Cancer Hospital & Jiangsu Institute of Cancer Research & The Affiliated Cancer Hospital of Nanjing Medical University, No. 42, Baiziting, Xuanwu District, Nanjing, Jiangsu, 210009, People's Republic of China, Tel/Fax +86 25 83283568, Email shimeiqi1963@163.com

Abstract: Approximately 10–20% of patients demonstrate primary resistance to EGFR-TKIs, and different EGFR mutations vary in sensitivity to EGFR-TKIs. We report a case of a 78-year-old male with lung adenocarcinoma that EGFR L858R (AF = 1.32%) coexisting with EGFR S645C (AF = 7.13%) in his diagnosed tissues analyzed by NGS. The patient was primarily resistant to first-line osimertinib and rapidly progressed after pembrolizumab in combination with pemetrexed and bevacizumab, as demonstrated by persistently elevated CEA levels during treatment. ctDNA-based NGS analysis revealed loss of EGFR L858R while persistence of highly abundant EGFR S645C in the pleural fluid and plasma after treatment, suggesting that EGFR L858R may be a subclone. We provide the first clinical evidence of the primary resistance of EGFR S645C to osimertinib and emphasize the importance of identifying clones and subclones. Our patient did not respond to immunotherapy either, and preclinical studies have shown that EGFR S645C activates the MEK signaling pathway, the combination of EGFR-TKIs and MEK inhibitors may be effective.

Keywords: EGFR S645C, osimertinib, primary resistance, NSCLC, subclone

Introduction

EGFR mutations occur in 51.4% of Asian patients with lung adenocarcinomas,¹ multiple co-mutations have been proven to be associated with primary resistance to EGFR tyrosine kinase inhibitors (EGFR-TKIs), among these, rare EGFR mutations that coexisted with EGFR exon 19 deletion (19DEL)/L858R are easily overlooked due to lack of function identification and clinical medication, Nevertheless, statistical analysis of mutation profiles of ~60,000 tumors found that, same-gene double mutations are extremely rare in pan-cancer mutation profiles but are characteristic of lung cancer, double mutations in EGFR predominantly exist in lung cancer, especially in lung adenocarcinoma.² On the one hand, when rare EGFR mutations and 19DEL/L858R are on the same allele (ie, in cis), it may directly alter the protein conformations and result in steric hindrance of the EGFR-TKIs.³ On the other hand, previous study reported that 1.7% non-small-cell lung cancer (NSCLC) had more than one driver gene mutation,⁴ which revealed that lung cancer is a very heterogeneous disease. When rare EGFR mutations and 19DEL/L858R are in trans, the rare EGFR mutations maybe a strong driver mutation, whose potential oncogenic capacity poses a challenge for targeted therapy. Here, we report a case of double EGFR-mutant lung adenocarcinoma in which despite the presence of the common EGFR-TKIs sensitive mutation EGFR L858R, the coexisting high-frequency rare mutation EGFR S645C made the patient resistant to osimertinib.

Case Report

In June 2021, a 78-year-old male was admitted to our hospital because of sternal pain, chest computed tomography (CT) indicated a right upper lobe mass (27 × 18 mm) (Figure 1) and pathology showed moderately differentiated lung adenocarcinoma. Multiple mixed or pure ground-glass nodules were observed in the upper lobes of both lungs, suggesting multifocal adenocarcinoma. CT revealed mediastinal lymph node enlargement and bone destruction in parts of the thoracic spine and ribs, which were considered to be bone metastases. The serum tumor biomarker carcinoembryonic antigen (CEA) was 397 ng/mL. The final diagnosis was a clinical stage IV (cT2N2M1) lung adenocarcinoma.

We identified EGFR p.L858R (c.2573T>G, allele frequency (AF)=1.32%) and EGFR p.S645C (c.1934C>G, AF=7.13%) by DNA-based next-generation sequencing (NGS) 551-gene panel (Simceredx) based on the punctured lung tissue (Table 1). Considering that EGFR p.L858R is a common therapeutic target for lung adenocarcinoma and that there are multiple approved drugs, the patient received osimertinib (80 mg once daily) as the first-line therapy in July 2021 (Figure 2).

Unfortunately, a month later, he reported worsening bone pain, respiratory symptoms of cough, and aggravated chest tightness (August 2021). CT re-examination revealed a slowly enlarging lung mass (27 × 18 mm). Furthermore, the serum CEA was markedly elevated (397 ng/mL→518.77 ng/mL). A comprehensive clinical assessment revealed that the patient's disease had progressed and was primarily resistant to osimertinib.

The patient was physically unfit for biopsy and strongly refused chemotherapy or injectable drugs. Considering that anlotinib has been widely used in EGFR-mutant patients previously treated with EGFR-TKIs, crosstalk between EGFR and vascular endothelial growth factor (VEGF) and its receptor (VEGFR) has been reported, and that targeting the two pathways simultaneously has a synergistic effect,⁵ we tried to combine osimertinib with anlotinib. The patient experienced slow progressive disease (PD) with analogous lung neoplasms (24 × 18 mm), mediastinal lymph nodes, and bone metastasis, and CEA was elevated again (518.77 ng/mL→744 ng/mL) in October 2021.

For previously treated EGFR-mutant NSCLC, immune checkpoint inhibitors in combination with chemotherapy and anti-angiogenesis drugs effectively prolonged progression-free survival (PFS) according to IMpower150⁶ and ORIENT-31.⁷ A retrospective clinical study also showed that pembrolizumab in combination with chemotherapy or anti-angiogenesis drugs significantly prolonged the overall survival (OS) of EGFR-mutant NSCLC patients compared with

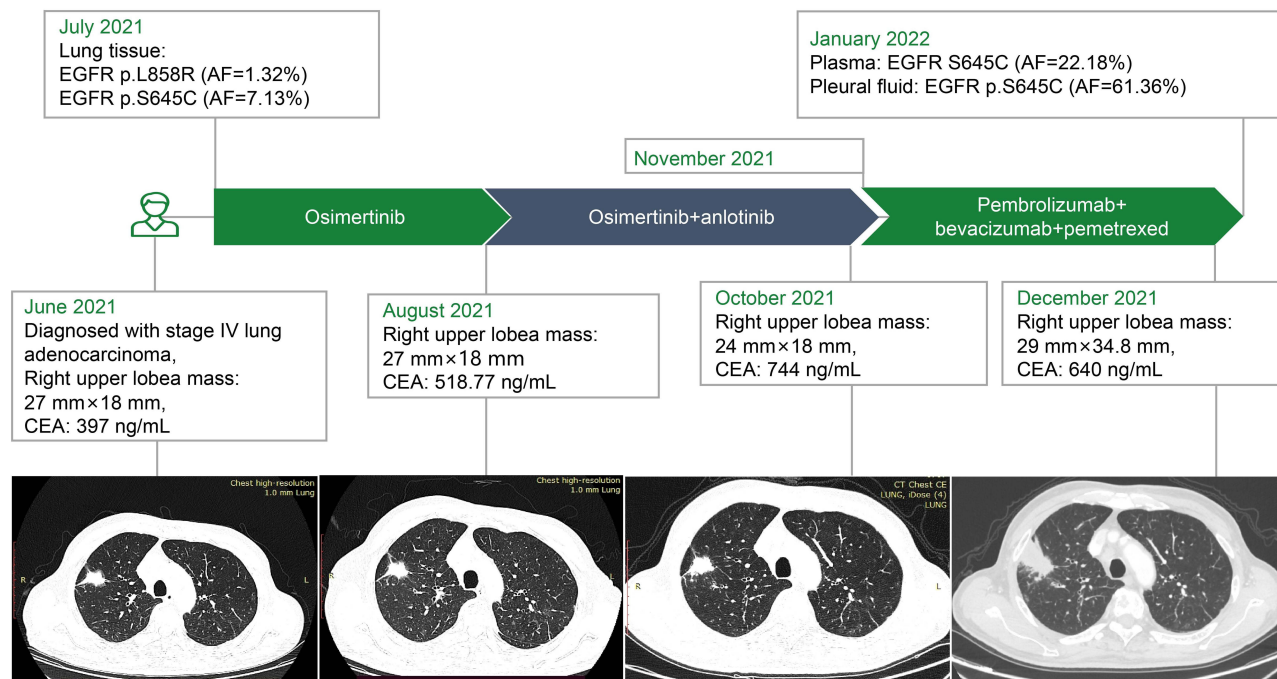


Figure 1 Radiologic images, timeline and changes in the CEA level during the patient's clinical course.

Table 1 All Detected Variants in the Patient's Punctured Lung Tissue (July 2021)

Gene	NM.	Exon/Intron	HGVS_c.	HGVS_p.	AF/CNVs
EGFR	NM_005228.3	exon21	c. 2573T>G	p. L858R	1.32%
EGFR	NM_005228.3	exon17	c. 1934C>G	p. S645C	7.13%
ARAF	NM_001256196.1	exon7	c. 660C>A	p. N220K	13.17%
ERBB4	NM_005235.2	exon3	c. 259G>A	p. V87M	11.49%
DNMT3A	NM_175629.2	exon4	c. 327dup	p. Q110Afs*14	8.55%
PIGR	NM_002644.3	exon4	c. 651G>T	p. Q217H	8.14%
STAT5B	NM_012448.3	intron1	c. -10-10_-10-7del		3.53%
CDK8	NM_001260.2	exon13	c. 1271G>A	p. R424H	2.50%
BTG2					3.53
BTG1					3.49
RARA					3.14

pembrolizumab alone.⁸ So we adopted a dosage regimen of two cycles of pembrolizumab and pemetrexed from November 2021, platinum was removed because of its toxicity and side effects.

However, CT indicated a markedly enlarged lesion (29 × 34.8 mm) in December 2021, and CEA levels remained stubbornly high (640 ng/mL). The patient sent pleural fluid sample and blood sample for NGS testing in January 2022, which revealed EGFR S645C (AF 61.36%) in the pleural fluid sample and EGFR S645C (AF 22.18%) in the plasma, notably,

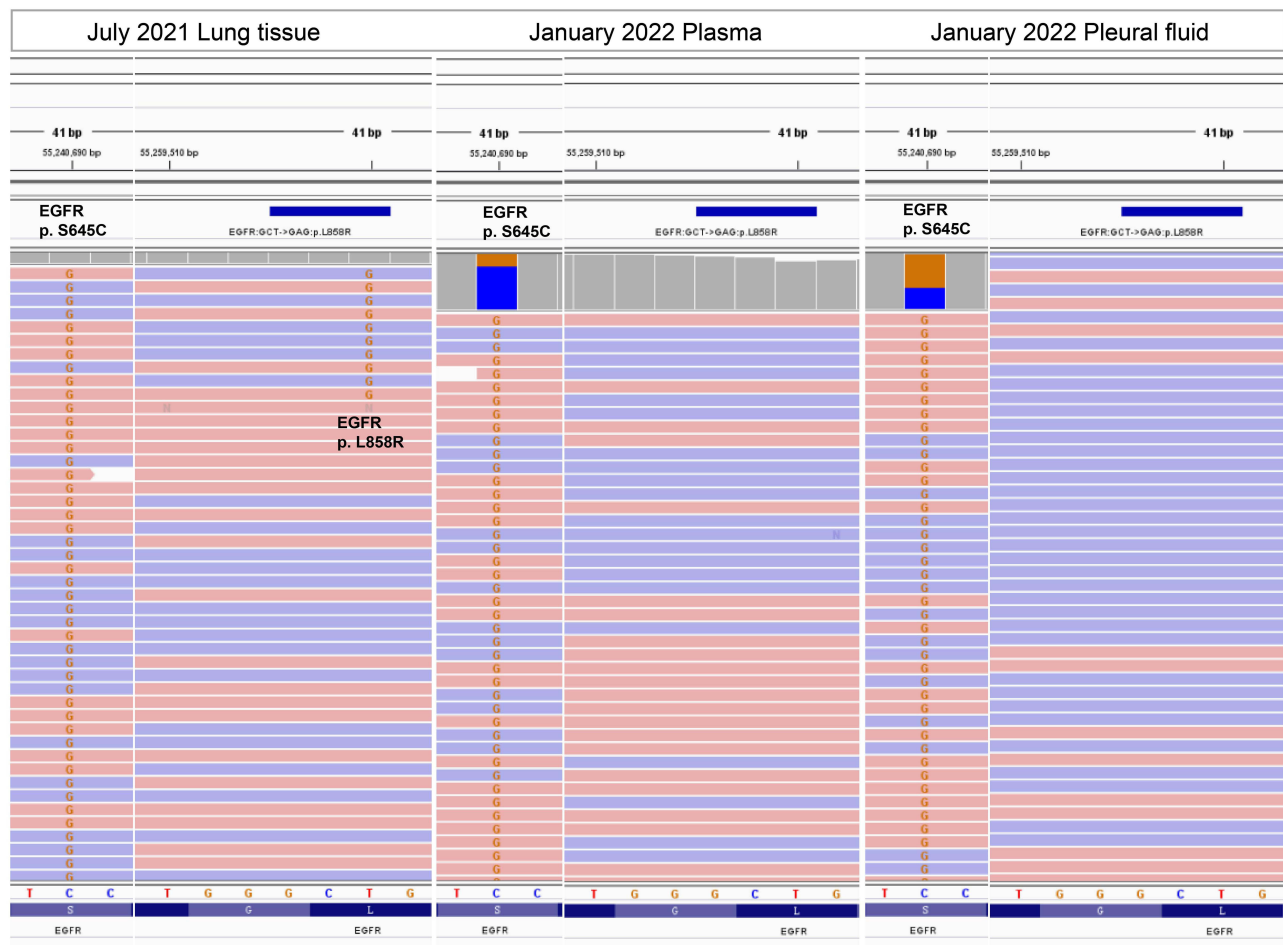


Figure 2 EGFR S645C and EGFR L858R detected in lung tissue (July 2021), plasma (January 2022) and pleural fluid (January 2022).

EGFR L858R was not detected in either sample. We realized that EGFR p.S645C may be the main factor driving disease progression. We intended to discuss the next treatment plan; however, the patient was lost to follow-up after discharge.

Discussion

In the patient's initial diagnosed lung tissue, the abundance of EGFR S645C (AF = 7.13%) was higher than that of EGFR L858R (AF = 1.32%), after failure of osimertinib treatment, only EGFR S645C but not EGFR L858R was detected in plasma and pleural fluid, which imply that EGFR L858R was likely to be the subclone. It is reported that a patient with lung adenocarcinoma with EGFR/BRAF co-mutations in both primary and metastatic sites had limited efficacy with first-line afatinib, but switched to a BRAF/MEK inhibitor with significant efficacy due to the higher frequency of the BRAF V600E mutation allele compared with EGFR L858R.⁹ Furthermore, studies using circulating tumor DNA to monitor minimal residual disease in lung cancer have shown that clonal mutations are more predictive to predict the risk of recurrence than subclonal mutations.¹⁰ The studies above indicated the importance of identifying clone and subclones.

The presence of multiple subclones within the tumour is a challenge in the targeted therapy for patients with cancer. Single-cell analysis confirmed the intratumoral heterogeneity of EGFR-activating mutations in advanced NSCLC, in patients with lung adenocarcinoma treated with gefitinib, the rate of L858R mutation was significantly higher in the long PFS group than in the short PFS group.¹¹ Compared with 19 deletion, patients with L858R tend to carry more co-mutations, studies have shown that patients with L858R benefit more from EGFR-TKIs plus chemotherapy than those with 19DEL.¹² NEJ009 also confirmed that first-line EGFR-TKIs combined chemotherapy significantly prolonged PFS compared with gefitinib-alone.¹³ It is worth discussing whether the combination of target drug and chemotherapy is needed for tumors with high internal heterogeneity, clonal evolution analysis may be able to more accurately screen out the first-line population suitable for EGFR-TKIs combined chemotherapy.

We hypothesized that L858R cells were eliminated and S645C cells outgrew after osimertinib treatment, thus, only EGFR S645C was detected in the plasma and pleural fluid, which implies that osimertinib can suppress the subclone L858R, but the activating S645C clone showed resistance to the treatment. Unfortunately, our patient's first-line treatment was limited by the absence of approved drugs for EGFR S645C.

It is reported that EGFR S645C is present in 0.02% of the American Association for Cancer Research (AACR) Project Genomics Evidence Neoplasia Information Exchange (GENIE) cases, with the highest prevalence of conventional glioblastoma multiforme, glioblastoma, and lung adenocarcinoma.¹⁴ In the local database (Simceredx), the detection rate of EGFR S645C in lung cancer was 0.028% (14/49255). Therefore, the rare mutation deserves our attention. In 2016, researchers identified EGFR S645C as a gain-of-function mutation by expression-based variant impact phenotyping (eVIP) method, which could promote tumor formation in vivo and is less sensitive to erlotinib than wild-type EGFR in vitro.¹⁵ In 2022, EGFR S645C was shown to be osimertinib-resistant in vivo.¹⁶ Functional analysis revealed a highly correlated expression profile of EGFR S645C with KRAS G12C, suggesting that the activity of EGFR S645C is dependent on MEK reactivation, combination with mTOR inhibitors such as trametinib can overcome EGFR-TKI resistance.¹⁵ It is reported that two EGFR-mutant patients with acquired BRAF fusion experienced tumor shrinkage after combination of erlotinib and trametinib.¹⁷ Selumetinib (a MEK1/2 inhibitor) combined with osimertinib has been proven to overcome EGFR-TKIs resistance caused by NRAS mutations both in vitro and in vivo,¹⁸ in addition, the MEK inhibitors selumetinib or trametinib in combination with EGFR-TKIs have been shown to overcome or delay osimertinib resistance. EGFR-TKIs in combination with MEK inhibitors are limited but effective option for EGFR-mutant patients with reactivated MAPK signaling pathways.

Conclusion

This is the first clinical evidence that EGFR S645C is primarily resistant to osimertinib, and the powerful oncogenic capacity of EGFR S645C when it as the clonal mutation deserves our attention.

Abbreviations

TKIs, tyrosine kinase inhibitors; NSCLC, non-small-cell lung cancer; NGS, next-generation sequencing; CT, computed tomography; CEA, carcinoembryonic antigen; AF, allele frequency; PFS, progression-free survival; OS, overall survival; VEGF, vascular endothelial growth factor; VEGFR, vascular endothelial growth factor receptor; PD, progressive disease;

ctDNA, circulating tumor DNA; eVIP, expression-based variant impact phenotyping; AACR, American Association for Cancer Research; GENIE, Project Genomics Evidence Neoplasia Information Exchange.

Data Sharing Statement

The original contributions presented in this study are included in the article and further inquiries can be directed to the corresponding author.

Ethics Approval and Consent to Participate

The authors declare that written informed consent was obtained from the patient's and institutional approval for the publication of data and images. The research gene analysis was with ethics approval (HREC ID 4814).

Consent for Publication

All claims expressed in this article are solely those of the authors and do not necessarily represent those of their affiliated organizations, or those of the publisher, the editors and the reviewers. Any product that may be evaluated in this article, or claim that may be made by its manufacturer, is not guaranteed or endorsed by the publisher.

Acknowledgments

We thank Dr. Ran Ding, Dr. Wanglong Deng and Dr. Dongsheng Chen from Jiangsu Simcere Diagnostics for their assistance with this study.

Author Contributions

All authors made a significant contribution to the work reported, whether that is in the conception, study design, execution, acquisition of data, analysis and interpretation, or in all these areas; took part in drafting, revising or critically reviewing the article; gave final approval of the version to be published; have agreed on the journal to which the article has been submitted; and agree to be accountable for all aspects of the work.

Disclosure

Fei Quan, Zhongyu Lu and Duoxia Yang were employed by Jiangsu Simcere Diagnostics Co., Ltd. The remaining authors declare that the research was conducted in the absence of any commercial or financial relationships that could be construed as a potential conflict of interest.

References

1. Shi Y, Au JS, Thongprasert S, et al. A prospective, molecular epidemiology study of EGFR mutations in Asian patients with advanced non-small-cell lung cancer of adenocarcinoma histology (PIONEER). *J Thorac Oncol*. 2014;9(2):154–162. doi:10.1097/JTO.000000000000033
2. Yavuz BR, Tsai CJ, Nussinov R, Tuncbag N. Pan-cancer clinical impact of latent drivers from double mutations. *Commun Biol*. 2023;6(1):202. doi:10.1038/s42003-023-04519-5
3. Li M, Zhou CZ, Yang JJ, et al. The in cis compound EGFR mutations in Chinese advanced non-small cell lung cancer patients. *Cancer Biol Ther*. 2019;20(8):1097–1104. doi:10.1080/15384047.2019.1595280
4. Zhuang X, Zhao C, Li J, et al. Clinical features and therapeutic options in non-small cell lung cancer patients with concomitant mutations of EGFR, ALK, ROS1, KRAS or BRAF. *Cancer Med*. 2019;8(6):2858–2866. doi:10.1002/cam4.2183
5. Larsen AK, Ouaret D, El OK, Petitprez A. Targeting EGFR and VEGF(R) pathway cross-talk in tumor survival and angiogenesis. *Pharmacol Ther*. 2011;131(1):80–90. doi:10.1016/j.pharmthera.2011.03.012
6. Socinski MA, Nishio M, Jotte RM, et al. IMpower150 final overall survival analyses for atezolizumab plus bevacizumab and chemotherapy in first-line metastatic nonsquamous NSCLC. *J Thorac Oncol*. 2021;16(11):1909–1924. doi:10.1016/j.jtho.2021.07.009
7. Lu S, Wu L, Jian H, et al. Sintilimab plus bevacizumab biosimilar IBI305 and chemotherapy for patients with EGFR-mutated non-squamous non-small-cell lung cancer who progressed on EGFR tyrosine-kinase inhibitor therapy (ORIENT-31): first interim results from a randomised, double-blind, multicentre, Phase 3 trial. *Lancet Oncol*. 2022;23(9):1167–1179. doi:10.1016/S1470-2045(22)00382-5
8. Chen Y, Yang Z, Wang Y, et al. Pembrolizumab plus chemotherapy or anlotinib vs. pembrolizumab alone in patients with previously treated EGFR-mutant NSCLC. *Front Oncol*. 2021;11:671228. doi:10.3389/fonc.2021.671228
9. Morikawa K, Iinuma M, Shinozaki Y, Nishine H, Inoue T, Mineshita M. A case of advanced adenocarcinoma genetically confirmed with EGFR/BRAF co-mutation in both primary and metastatic lesions. *Ther Adv Med Oncol*. 2021;13:17588359211053420. doi:10.1177/17588359211053420
10. Wang S, Li M, Zhang J, et al. Circulating tumor DNA integrating tissue clonality detects minimal residual disease in resectable non-small-cell lung cancer. *J Hematol Oncol*. 2022;15(1):137. doi:10.1186/s13045-022-01355-8

11. Guo L, Chen Z, Xu C, et al. Intratumoral heterogeneity of EGFR-activating mutations in advanced NSCLC patients at the single-cell level. *BMC Cancer*. 2019;19(1):369. doi:10.1186/s12885-019-5555-y
12. Wu Q, Luo W, Li W, Wang T, Huang L, Xu F. First-generation EGFR-TKI plus chemotherapy versus EGFR-TKI alone as first-line treatment in advanced NSCLC with EGFR activating mutation: a systematic review and meta-analysis of randomized controlled trials. *Front Oncol*. 2021;11:598265. doi:10.3389/fonc.2021.598265
13. Miyauchi E, Morita S, Nakamura A, et al. Updated analysis of NEJ009: gefitinib-alone versus gefitinib plus chemotherapy for non-small-cell lung cancer with mutated EGFR. *J Clin Oncol*. 2022;40(31):3587–3592. doi:10.1200/JCO.21.02911
14. André F, Arnedos M, Baras AS; AACR Project GENIE Consortium. AACR Project GENIE: powering Precision Medicine through an International Consortium. *Cancer Discov*. 2017;7(8):818–831. doi:10.1158/2159-8290.CD-17-0151
15. Berger AH, Brooks AN, Wu X, et al. High-throughput phenotyping of lung cancer somatic mutations. *Cancer Cell*. 2016;30(2):214–228. doi:10.1016/j.ccell.2016.06.022
16. Ikeuchi H, Hirose T, Ikegami M, et al. Preclinical assessment of combination therapy of EGFR tyrosine kinase inhibitors in a highly heterogeneous tumor model. *Oncogene*. 2022;41(17):2470–2479. doi:10.1038/s41388-022-02263-4
17. Luo J, Makhnin A, Tobi Y, et al. Erlotinib and trametinib in patients with EGFR-mutant lung adenocarcinoma and acquired resistance to a prior tyrosine kinase inhibitor. *JCO Precis Oncol*. 2021;5:55–64.
18. Eberlein CA, Stetson D, Markovets AA, et al. Acquired resistance to the mutant-selective EGFR inhibitor AZD9291 is associated with increased dependence on RAS signaling in preclinical models. *Cancer Res*. 2015;75(12):2489–2500. doi:10.1158/0008-5472.CAN-14-3167

Lung Cancer: Targets and Therapy

Dovepress

Publish your work in this journal

Lung Cancer: Targets and Therapy is an international, peer-reviewed, open access journal focusing on lung cancer research, identification of therapeutic targets and the optimal use of preventative and integrated treatment interventions to achieve improved outcomes, enhanced survival and quality of life for the cancer patient. Specific topics covered in the journal include: Epidemiology, detection and screening; Cellular research and biomarkers; Identification of biotargets and agents with novel mechanisms of action; Optimal clinical use of existing anticancer agents, including combination therapies; Radiation and surgery; Palliative care; Patient adherence, quality of life, satisfaction; Health economic evaluations.

Submit your manuscript here: <http://www.dovepress.com/lung-cancer-targets-therapy-journal>