

Combined Electromagnetic and Electrohydraulic Focused ESWT and EMTT for Delayed Calcaneal Union in an Adolescent Parkour Athlete - A Case Report

Karsten Knobloch¹, Amol Saxena², Wolfgang Schaden³

¹SportPraxis Professor Knobloch, Hannover, Germany; ²Department of Sports Medicine, Sutter-Palo Alto, Palo Alto, CA, USA; ³Ludwig Boltzmann Institute for Experimental and Clinical Traumatology, AUVA Research Center, Vienna, Austria

Correspondence: Karsten Knobloch, SportPraxis Professor Knobloch, Heiligerstrasse 3, Hannover, 30159, Germany, Email knobloch@sportpraxis-knobloch.de

Abstract: This case report describes a novel and unique combination of both electromagnetic and electrohydraulic focused extracorporeal shockwave therapy (ESWT) and extracorporeal magnetotransduction therapy (EMTT) for accelerated healing in a calcaneus epiphyseal fracture with delayed healing in an adolescent Parkour athlete. After a 2.5m jump, the 14-year-old experienced significant heel pain, however avoided telling his parents. After eight weeks, the initial imaging using ultra low dose weight-bearing cone beam CT (WBCT) revealed a calcaneus non-union situation adjacent to the open calcaneal physis. To improve and accelerate bony healing substantially, we chose to apply both combined focused electromagnetic (Storz Ultra, Storz Medical AG, Tägerwillen, CH) and focused electrohydraulic (MTS, Konstanz, Germany) ESWT in a fractioned fashion plus EMTT (Storz Magnetolith, Tägerwillen, CH) in five consecutive weekly sessions while allowing the patient to fully weight bear. The follow-up WBCT after six weeks revealed a near to total healing of the delayed union and being pain-free. Notably, combination therapy with focused ESWT and EMTT did not result in early closure of the calcaneal epiphysis. We conclude that combined focused electromagnetic and electrohydraulic ESWT and EMTT facilitate bony healing in adolescent calcaneal apophyseal fractures without any adverse effects on the open physis. Evidence level IV (case report).

Keywords: ESWT, shockwave therapy, EMTT, epiphysis, non, union

Introduction

Parkour is an “art of movement” where obstacles of daily ambient life are playfully encountered which is also known as free running, urban-running or obstacle coursing.¹ Traceurs (parkour participants) consider the city as a playground and as an outlet for their creativity. Parkour consists of finding new and potentially dangerous ways to traverse the city landscape.²

In a retrospective large study with 266 traceurs, an average of 1.9 injuries per sport career/year or 5.5 injuries per 1000h training were reported. Landing incorrectly was the movement element resulting in most of the injuries (61%). Overestimation (23%) as well as misjudging the situation (20%) were the next most common causes. A cross-sectional report from the United States underscores that more than half of all reported injuries (58%) affected patients’ extremities with even children of 8 years presenting with Parkour injuries.³

Significant bone fractures have been reported in case reports with multiple foot fractures with dislocations in one case⁴ and a tarsal navicular fracture in a 17-year-old Portuguese Parkour athlete,⁵ who was operated on after a 3.5m fall in a two stage approach first with external fixation and two weeks later with open reduction and internal fixation. After six weeks of non-weight bearing, fracture healing was achieved after 15 weeks in the latter patient.

The following case highlights a complete non-invasive approach in a 14-year-old traceur combining two different focused extracorporeal shockwave generators (electromagnetic and electrohydraulic) with novel extracorporeal magnetotransduction therapy (EMTT) for accelerated calcaneal bone healing after a failed parkour landing.

Case Report

A 14-year-old Parkour athlete (BMI 20,2kg/m²) suffered immediate heel pain when landing after a 2.5m high jump. However, he wanted to hide the injury from his parents. He and his father sought medical help 8 weeks after the injury due to significant heel pain. The athlete did not mention the previous fall.

Ultrasound examination using an 18MHz Matrix linear probe (Canon Medical Systems, Aplio i800) revealed a slightly enlarged plantar fascia (anterior posterior diameter 4mm vs 3.2mm, [Figure 1](#)) with suspected plantar fasciitis. However, there was no history of overuse like running or ball sports. In light of the following cone beam imaging with a calcaneal nonunion, the plantar fascia thickening is most likely due to intra-fascial bleeding following the fracture.

Weight-bearing cone beam CT (WBCT, [Figure 2](#)) was performed using a SCS MedSeries H22 system with ultra-low dosage (748mGy x cm²) to rule out any bony pathology. It revealed a calcaneal fracture, which was still evident eight weeks after the trauma, which he then admitted to his parents and care providers.

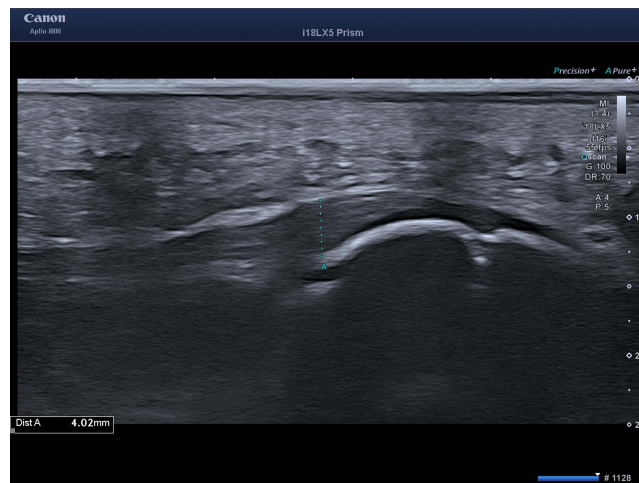


Figure 1 Plantar fascia on the right symptomatic side with a 4mm anterior-posterior diameter as slightly enlarged anterior posterior diameter is usually associated with plantar fasciitis, in this case intra-fascial bleeding (18MHz Matrix linear probe, Canon Medical Systems).

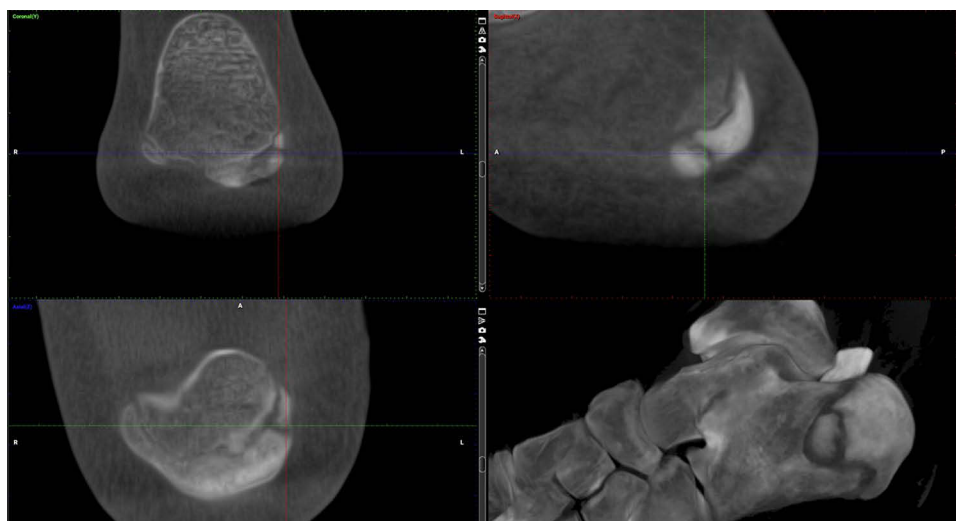


Figure 2 Weight-bearing cone beam CT (WBCT, SCS Med Series H22, 748mGy x cm²) showing a non-healed epiphyseal fracture of the calcaneus eight weeks after a landing in Parkour.

Therapy

Since the calcaneal fracture was a delayed union situation eight weeks after the Parkour landing and the patient was fully weight-bearing the entire eight weeks prior, we offered a comprehensive stimulation of bone healing using a combination of two types of focused ESWT and novel ion inducing therapy EMTT (Storz Magnetolith).

Electromagnetic transduction therapy (EMTT) is a promising new technology of treatment based on PEMF with magnetic field strengths between 10 and 80 mTesla and very fast oscillating frequencies with 100–300kHz. EMTT is characterized by high frequency oscillating magnetic fields with an effective transduction performance of >60 kiloTesla/second (kT/s). This is in contrast to known pulsed electromagnetic field (PEMF) therapy, where effective transduction performance is <60kT/s with the commercially available PEMF devices. Impulses are emitted by a high-speed generator that is released in nanoseconds and an impulse release frequency of up to 8 Hz. The very short duration of each impulse from EMTT ensures full electrophysical reaction without any temperature increase in the tissue including electroporation and piezoelectric effects. To increase the likelihood of bone healing we combined, for the first time, two different focused shockwave generators and principles with EMTT: the electromagnetic principle and the electrohydraulic principle. The rationale was to improve the effect of focused ESWT by two different shockwave principles as a combined shockwave therapy. Overall, electrohydraulic ESWT in non-union situations achieve a 55–80% success rate. Usually, one to three treatments of electrohydraulic focused ESWT are applied. As far as the number of shots is concerned, in small bones usually 2000 shots are applied with an electrohydraulic device.

Previous research has shown 80% chance of achieving bone healing in similar situations. In order to improve this rate, we performed a sequential shockwave treatment using three different technologies. These were performed at the same setting, within a 10 minute time interval, which has been shown to have superior effects on soft tissue microcirculation³ (Figure 3).

Following the idea of sequential, repetitive focused ESWT, a single session in this case consisted of:

1. Focused electromagnetic ESWT (Storz Ultra 4000 shots, 0.03–0.12mJ/mm²)
2. Extracorporeal magnetotransduction therapy (Storz Magnetolith, 8/8, 6000 shots)
3. Focused electrohydraulic ESWT (MTS 2000 shots, 0.03–0.11mJ/mm²)

The energy flux densities were adjusted to the individual patient's visual analog scale <5/10 for each visit. Overall, five combined bone stimulation sessions were offered on a weekly basis. While for the first two visits, the energy flux density was rather low-level (nano-energetic) 0.03–0.05mJ/mm² with both focused devices, the following sessions allowed slightly higher low to medium energetic energy flux densities based on the patient's visual analog scale <5/10. The patient was advised to use maximally cushioned running shoes in his daily activities, but was not allowed to perform sport nor Parkour, which he complied with.

Follow-up WBCT was performed six weeks after the first bone stimulation session, which was two weeks after the 5th bone stimulation session. The fracture line at this early point in time, only two weeks after the last bone stimulation session, was substantially consolidated. Clinically, the patient was pain free. He was counseled to slightly increase loading over the next four weeks with slow running, but no Parkour, to allow complete bone consolidation (Figures 4 and 5).

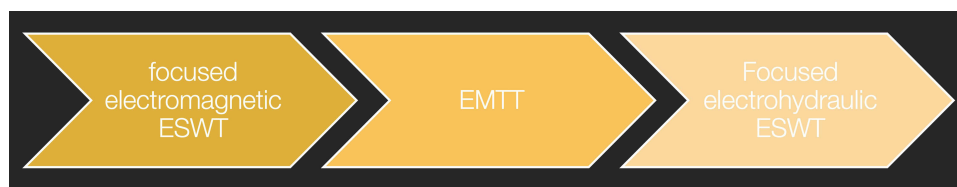


Figure 3 A single bone stimulation session started with focused electromagnetic ESWT, followed by EMTT, leading to focused electrohydraulic ESWT.

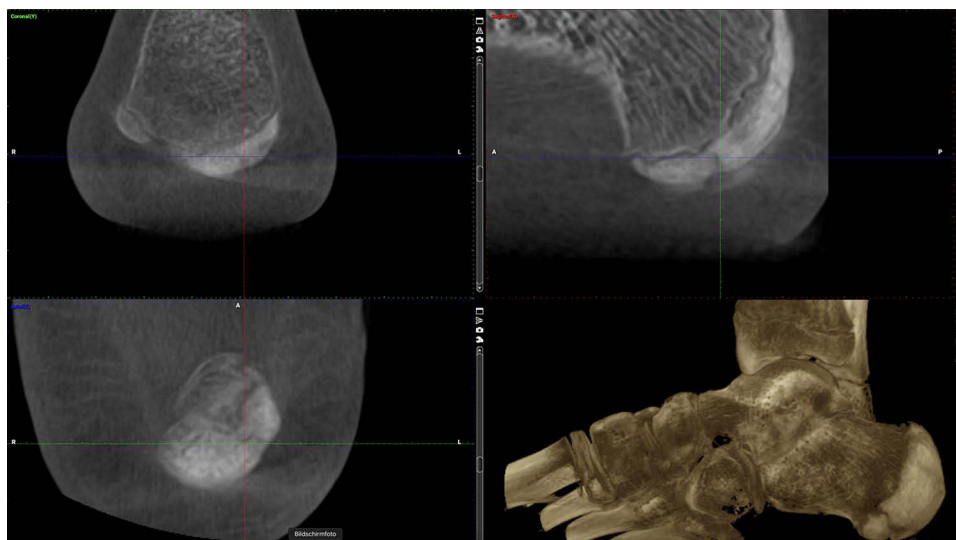


Figure 4 Follow-up weight-bearing CT (WBCT) six weeks after the first combined bone stimulation treatment, which was two weeks after the last session with substantial improvement of the delayed union situation at that early point in time.

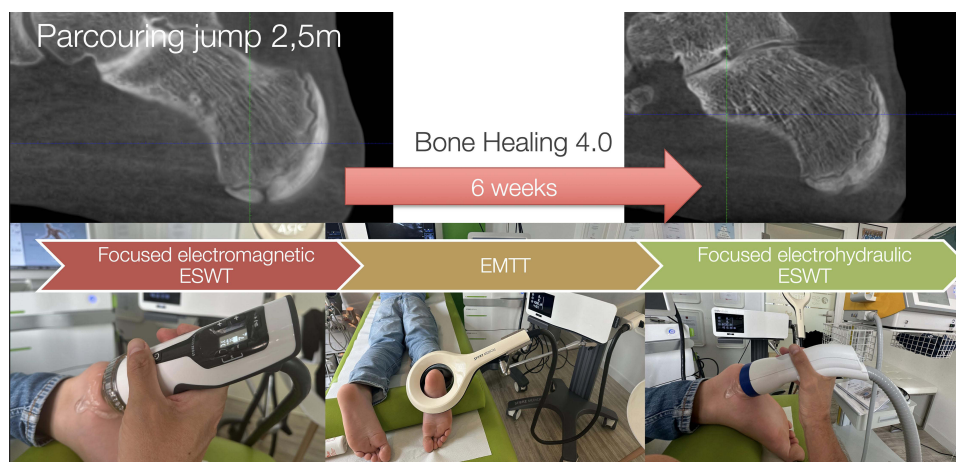


Figure 5 Scheme of a fractionated, repetitive bone stimulation program starting with focused electromagnetic ESWT, followed by EMTT, then thirdly, electrohydraulic focused ESWT in a single session five times in adolescent delayed calcaneus union. Notably, focused ESWT and EMTT did not result in early closure of the calcaneal epiphysis.

Discussion

This case report highlights, for the first time, the combination of fast oscillating magnetic field therapy, also called extracorporeal magnetotransduction therapy (EMTT) with two types of focused ESWT in an adolescent with a delayed calcaneal union situation. Bone healing in non-union situations with focused ESWT has previously been shown with different generators alone with efficacies of 55–80%^{6,7} mediated by mechanotransduction⁸ and usually with high-energetic energy flux densities of $0.25\text{mJ}/\text{mm}^2$ or higher. Intracellular communication is enhanced by ESWT via exosome stimulation.⁹

Focused ESWT can be derived from three different generator types: electrohydraulic, electromagnetic and piezo-electric. Usually, only one type of generator is used clinical-wise. We considered that the combination of focused electrohydraulic and electromagnetic ESWT might yield even better bony healing in an adolescent with open epiphysis, where high-energetic focused ESWT might do harm. In an experimental study we reported that fractionated repetitive focused electromagnetic ESWT (3 boots of 1000 impulses with $0.3\text{mJ}/\text{mm}^2$ in 10 min intervals) could enhance

microcirculatory blood flow in rats.¹⁰ Stimulated by these observations we sought to combine low energetic focused ESWT with two different generators with EMTT.

In this case, calcaneal bony healing was induced within 6 weeks with the combination of EMTT and combined focused low energetic ESWT with no adverse effects and pain free in an adolescent. Neither EMTT nor dual focused ESWT resulted in early closure of the calcaneal epiphysis in the 14-year-old boy. This is of note since, for more than two decades, open physis were regarded as a contraindication for focused ESWT. Experimental studies in rabbits led to varying effects on the open epiphysis with 0.32mJ/mm² 800 shots with no damage on rabbit epiphysis,¹¹ while 14kV with 3000 shots increased the epiphyseal plaque thickness.¹² A more recent clinical study¹³ found no premature closure in Osgood Schlatter and Sever's adolescents receiving focused ESWT with 0.1mJ/mm². In line with this, we did not find a premature closure of the calcaneal epiphysis when using combined focused ESWT (<0.12mJ/mm²) and EMTT.

In rotator cuff tendinopathy, an RCT demonstrated superior clinical results when combining focused high-energetic electromagnetic ESWT and EMTT.¹⁴ For bone stimulation, the combination of focused electromagnetic ESWT and novel EMTT has been reported in case series for scaphoid non-unions,¹⁵ metacarpal non-unions,¹⁶ and humerus non-unions.¹⁷ Isolated EMTT has recently been studied in a clavicle fracture in a triathlete.¹⁸ Suggested modes of action of EMTT are electroporation and a piezoelectric effect. In combination, mechanotransduction by ESWT and magnetotransduction by EMTT may leverage the beneficial effect on bone healing.

We conclude that combined focused electromagnetic and electrohydraulic ESWT and EMTT facilitate bony healing in adolescent calcaneal apophyseal fractures without any adverse effects on the open physis.

Abbreviations

EMTT, electromagnetic transduction therapy; ESWT, extracorporeal shockwave therapy; WBCT weight-bearing computer tomography; Hz, Hertz.

Ethics Approval and Informed Consent

The patient and his parents were informed that data from the case would be submitted for publication, and the parents gave consent. IRB approval was not required to publish this case report.

Funding

There is no funding to report.

Disclosure

KK is a lecturer for Storz Medical and reports non-financial support from MTS for providing test machine. AS has nothing to disclose. WS is a consultant for MTS and reports personal fees from SoftWave TRT, outside the submitted work.

References

1. Wanke EM, Thiel N, Groneberg DA, Fischer A. Parkour-art of movement and its injury risk. *Sportverletz Sportschaden*. 2013;27(3):169–176. doi:10.1055/s-0033-1350183
2. McLean CR, Houshian S, Pike J. Paediatric fractures sustained in Parkour (free running). *Injury*. 2006;37(8):795–797. doi:10.1016/j.injury.2006.04.119
3. Rossheim ME, Stephenson CJ. Parkour injuries presenting to United States emergency departments, 2009–2015. *Am J Emerg Med*. 2017;35(10):1503–1505. doi:10.1016/j.ajem.2017.04.040
4. Miller JR, Demoiny SG. Parkour: a new extreme sport and case study. *J Foot Ankle Surg*. 2008;47(1):63–65. doi:10.1053/j.jfas.2007.10.011
5. Karmali S, Ramos JT, Almeida J, Barros A, Campos P, da Costa DS. Tarsal navicular fracture in a Parkour Practitioner, a rare injury - case report and literature review. *Rev Bras Ortop*. 2019;54(6):739–745. doi:10.1016/j.rboe.2017.12.009
6. Beutler S, Regel G, Pape HC, et al. Extracorporeal shock wave therapy for delayed union of long bone fractures - preliminary results of a prospective cohort study. *Unfallchirurg*. 1999;102(11):839–847. doi:10.1007/s001130050492
7. Willems A, van der Jagt OP, Meuffels DE. Extracorporeal shockwave treatment for delayed union and nonunion fractures: a systematic review. *J Orthop Trauma*. 2019;33(2):97–103. doi:10.1097/BOT.0000000000001361
8. D'Agostino MC, Craig K, Tibalt E, Respizzi S. Shockwave as biological therapeutic tool: from mechanical stimulation to recovery and healing, through mechanotransduction. *Int J Surg*. 2015;24(Pt B):147–153. doi:10.1016/j.ijsu.2015.11.030

9. Gollmann-Tepeköylü C, Pözl L, Graber M, et al. miR-19a-3p containing exosomes improve function of ischaemic myocardium upon shock wave therapy. *Cardiovasc Res.* 2020;116(6):1226–1236. doi:10.1093/cvr/cvz209
10. Kisch T, Wuerfel W, Forstmaier V, et al. Repetitive shock wave therapy improves muscular microcirculation. *J Surg Res.* 2016;201(2):440–445. doi:10.1016/j.jss.2015.11.049
11. Nassenstein K, Nassenstein I, Schleberger R. Effects of high-energy shock waves on the structure of the immature epiphysis - a histomorphological study. *Z Orthop Ihre Grenzgeb.* 2005;143(6):652–655. doi:10.1055/s-2005-836903
12. Ozturk H, Bulut O, Oztemur Z, Kaloglu C, Kol IO. Effect of high-energy extracorporeal shock waves on the immature epiphysis in a rabbit model. *Arch Orthop Trauma Surg.* 2008;128(6):627–631. doi:10.1007/s00402-007-0388-6
13. Shafshak T, Amer MA. Focused ESWT for youth sports-related apophyseal injuries: case series. *J Orthop Surg Res.* 2023;18(1):616. doi:10.1186/s13018-023-04065-0
14. Klüter T, Krath A, Stukenberg M, et al. Electromagnetic transduction therapy and shockwave therapy in 86 patients with rotator cuff tendinopathy: a prospective randomized controlled trial. *Electromagn Biol Med.* 2018;37(4):175–183. doi:10.1080/15368378.2018.1499030
15. Knobloch K. Novel extracorporeal magnetotransduction therapy with Magnetolith and high-energy focused electromagnetic extracorporeal shockwave therapy as bone stimulation therapy for scaphoid nonunion - a case report. *Med: Case Rep Study Protoc.* 2020;2:1.
16. Knobloch K. Extracorporeal magnetotransduction therapy (EMTT) and high-energetic focused ESWT as bone stimulation therapy for metacarpal non-union - a case report. *Handchir Mikrochir Plast Chir.* 2021;53(1):82–86. doi:10.1055/a-1344-8126
17. Knobloch K. Bone stimulation 4.0 - combination of EMTT & EMTT in humerus nonunion. *Unfallchirurg.* 2021;125:323–326. doi:10.1007/s00113-021-01025-3
18. Gerdesmeyer L, Burgkart R, Saxena A. Clavicle fracture and triathlon performance: a case report. *J Med Case Rep.* 2024;18(1):197. doi:10.1186/s13256-024-04482-7

Open Access Journal of Sports Medicine

Dovepress

Publish your work in this journal

Open Access Journal of Sports Medicine is an international, peer-reviewed, open access journal publishing original research, reports, reviews and commentaries on all areas of sports medicine. The manuscript management system is completely online and includes a very quick and fair peer-review system. Visit <http://www.dovepress.com/testimonials.php> to read real quotes from published authors.

Submit your manuscript here: <http://www.dovepress.com/open-access-journal-of-sports-medicine-journal>