

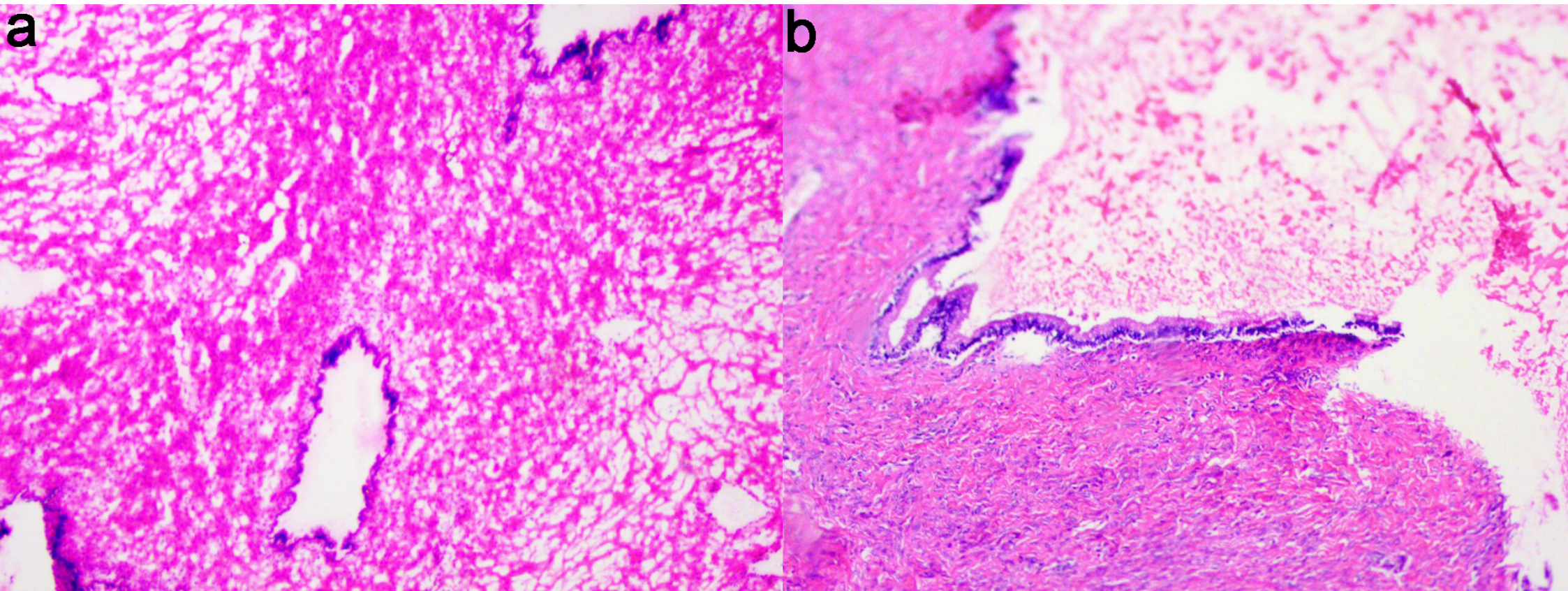Figure S1: (a) FS showed only areas of mucinous cystadenoma; (b) after extensive sampling, a small focal borderline tumor was identified on PS.



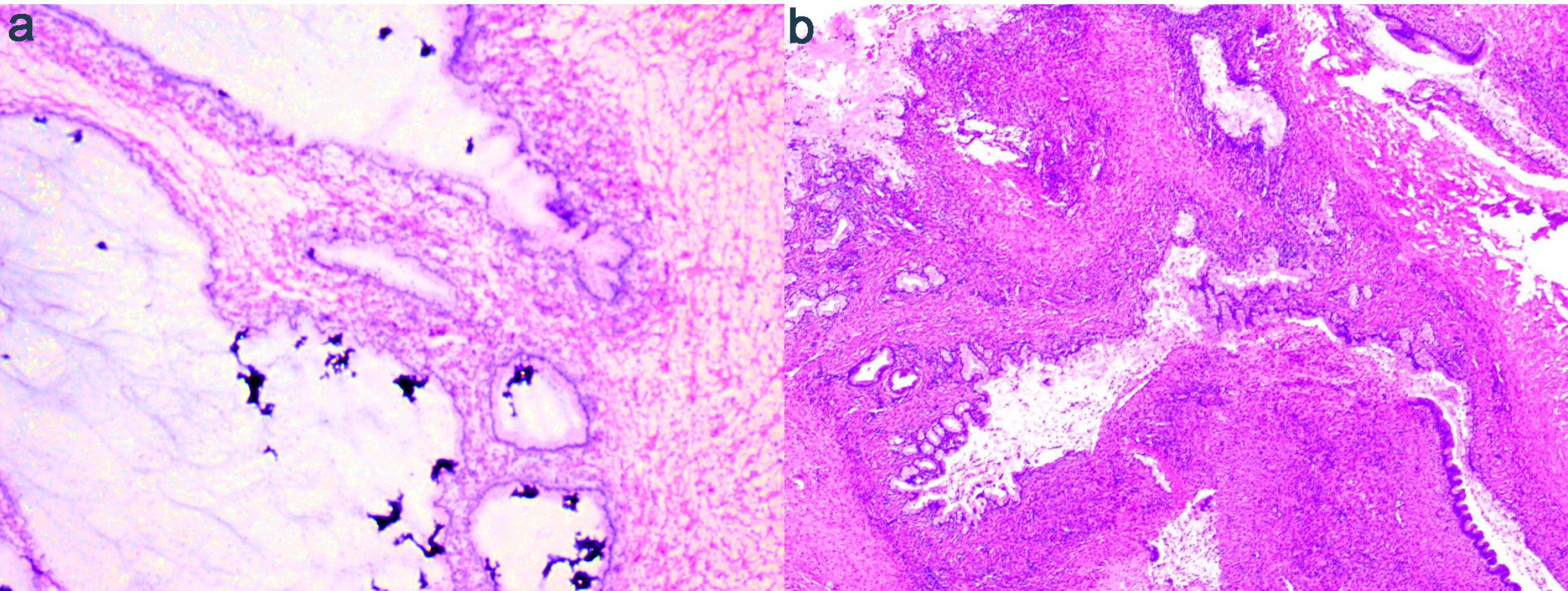


Figure S2: (a) benign ovarian tumor featuring the presence of mucus in the cystic lumen was impressed on FS slide; (b) areas of focal borderline tumor were identified on PS.



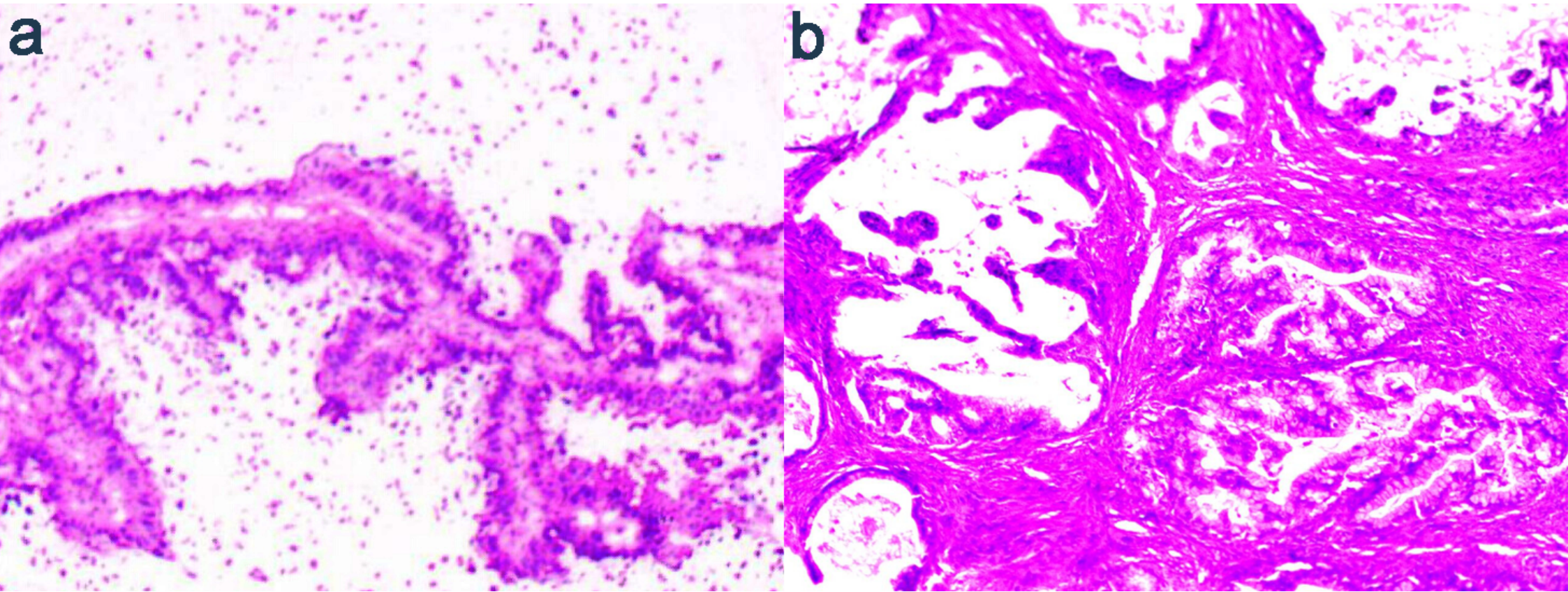


Figure S3: (a) FS showed areas consistent with borderline mucinous tumor; (b) additional sections showed foci of expansile invasion in a background of borderline tumor.



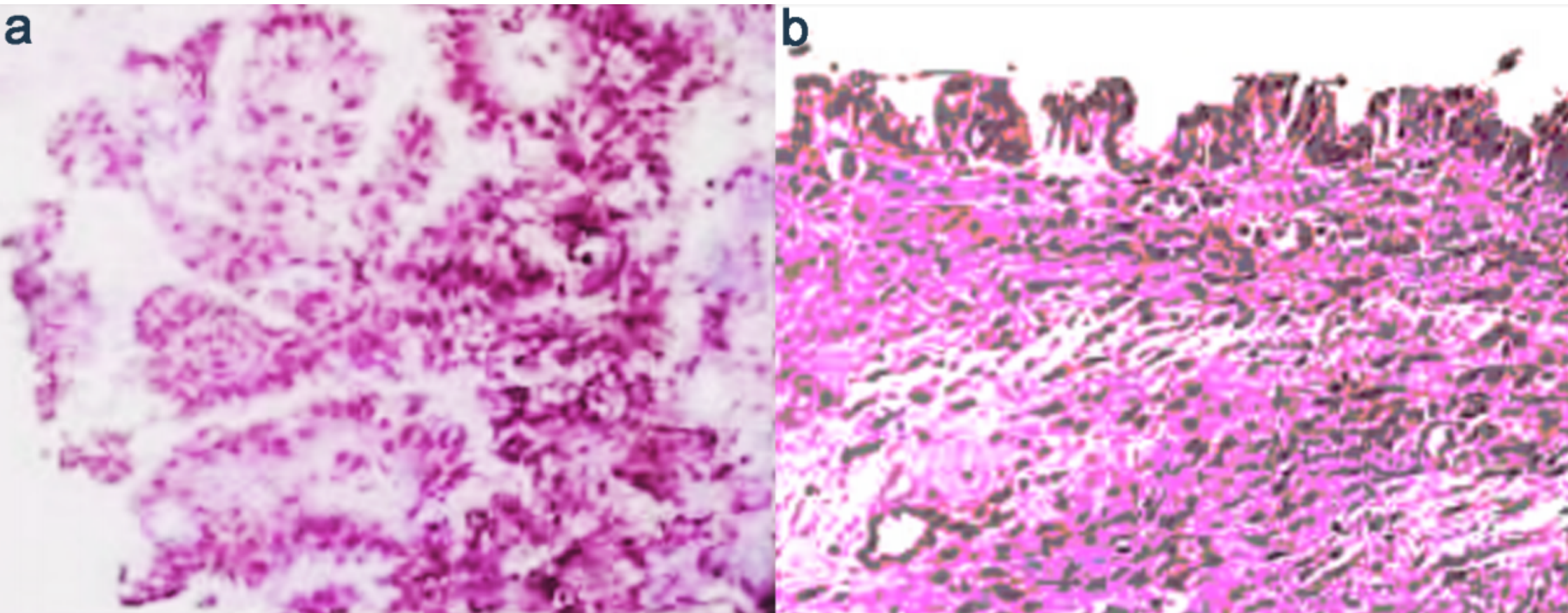


Figure S4: (a) papillary projections on FS lead to diagnostic suspicion of focal borderline changes; (b) mixed serous and mucinous ovarian cystadenoma was classified on PS.