

A pregnant Japanese woman returning from Africa with recurrent fevers

Akihiro Tsukadaira¹
Tomohiro Sekiguchi¹
Takashi Ashida²
Chinatsu Murashita³
Nobuo Itoh³
Mikiko Kobayashi⁴
Takashi Kagoshima⁴
Yoshitaka Yamazaki⁴

¹Department of Internal Medicine,

²Department of Obstetrics and Gynecology, ³Division of Clinical Pathology, Iida Municipal Hospital, Yawatacho 438, Iida, Japan;

⁴Department of Internal Medicine, Suzaka Prefectural Hospital, Suzaka 1332, Suzaka, Japan

Abstract: Certain clinical aspects of vivax malaria are no longer defined as benign. We present a case of vivax malaria with three relapses in a pregnant Japanese woman who had returned to Japan from the Comoros Islands in East Africa. Data on the successful delivery, examination of Duffy-blood group antigen, and microscopic findings of growing stages of *Plasmodium vivax* are thought to be of considerable interest.

Keywords: vivax malaria, Duffy-blood group, pregnancy

Introduction

There is growing evidence that the impact of *Plasmodium vivax* has been underestimated in developing and poor countries.^{1,2} The difficulty of differential diagnosis and lack of proper treatment of both blood-stage and latent parasites are two of the reasons for the prevalence of vivax malaria.

Case report

A 28-year-old Japanese woman who had been married to an African man and lived in the Comoros Islands for 1 year was admitted to our hospital in Japan because of chills and severe headache. She was 30 weeks pregnant and had taken medication against malaria 2 months previously when she was in Africa.

Laboratory findings showed leukocyte (6,600/ μ L) and platelet (6.6×10^4 / μ L) counts, as well as hemoglobin (9.7 g/dL), C-reactive protein (CRP; 19.2 mg/dL), fibrin/fibrinogen degradation products (FDP) (35.1 μ g/mL), and FDP D-dimer (38.5 μ g/mL) levels. Giemsa staining of peripheral blood using pH 7.4 buffer showed that 1.8% of the erythrocytes were infected by *Plasmodium*. After the ring form, schizont, and gametocyte of this parasite were determined (Figure 1), the results of the subsequent rapid diagnostic test and DNA assay led to a diagnosis of vivax malaria.

Seven-day medication (quinine 1500 mg/day) against malaria, administered under strict observation and with the patient's agreement, led to remission. However, vivax malaria relapsed in the 34th week of pregnancy. The presence of latent parasites was suspected to be the cause of the fevers. The next quinine administration resulted in another remission. To exterminate the latent parasites, we assessed mother and child blood glucose-6-phosphate dehydrogenase (G6PD) activities after 39th week spontaneous vaginal delivery, after which she was treated again with primaquine (15 mg/day; 14 days). The new born baby's weight was 2850 g. There were no

Correspondence: Akihiro Tsukadaira
Department of Internal Medicine,
Iida Municipal Hospital,
Yawatacho 438, Iida 395-8502,
Japan
Tel +81 265 21 1255
Fax +81 265 21 1266
Email 0375@imh.jp

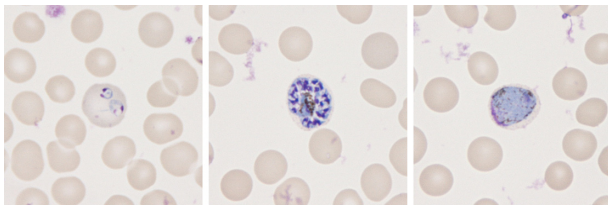


Figure 1 Microscopic findings of the growing stages of *Plasmodium* species in erythrocytes, which are known to be the merozoite, trophozoite, schizont, and gametocyte stages. Ring forms of two early trophozoites can be observed in an enlarged erythrocyte (left). The presence of more than 16 merozoites in a mature schizont suggests *P. vivax* infection (center). The presence of a round gametocyte in an enlarged erythrocyte also suggests *P. vivax* infection (right).

Note: Giemsa stainings, original magnification $\times 1000$.

abnormalities in either the baby or the placenta. There was no mother-to-child transmission. Mother and child are healthy after 6 months of anti-relapse therapy.

Discussion

Four distinct *Plasmodium* species are known to regularly infect humans: *P. falciparum*, *P. vivax*, *P. malariae*, and *P. ovale*. Certain clinical aspects of vivax malaria are not defined as benign anymore because relapse, severe clinical cases, and drug resistance have been reported for *P. vivax*.¹⁻³ Relapse of *P. vivax* and *P. ovale* is known to be triggered by dormant hypnozoites in the liver.²

Plasmodium falciparum malaria is defined as malignant and is a major public health problem in Africa, including the Comoros Islands,⁴ while vivax malaria is the major cause of malaria outside Africa, mainly afflicting Asia and the Americas.² Why would vivax malaria be less prevalent in Africa? It is known that Africans with Duffy-blood group antigen negative erythrocytes cannot be infected by *P. vivax*,⁵ because it requires the Duffy-blood group antigen as an obligate receptor for invasion,⁶ and the Duffy-blood group antigen negative phenotype Fy(a- b-) frequently occurs in the native African.^{7,8}

On the other hand, treatment of symptomatic vivax malaria during pregnancy is very difficult. It may lead to preterm delivery and fetal loss, and neonates of non-immune mothers may be at a particular risk of congenital malaria resulting from transplacental passage of parasites.⁹ Quinine as well as chloroquine are the drugs of choice for the treatment of vivax malaria. Primaquine, the only therapeutic option for these dormant tissue forms, is contraindicated during pregnancy because of the risk of fetal hemolysis.¹⁰ Even more noteworthy, low-birth weight associated with vivax malaria has also been reported during second and subsequent pregnancies.¹¹

We reported here repeated recurrences of vivax malaria in a Japanese primigravida from the Comoros Islands. Since the Duffy-blood group antigen of our patient was Fy(a+ b-), our findings support the notion that we should pay careful attention to the occurrence of *P. vivax* even in Africa,¹² in addition to the numerous local Duffy-blood group antigen-negative populations.

Acknowledgments

We thank Dr S Kano, Department of Tropical Medicine and Malaria, Research Institute, National Center for Global Health and Medicine in Japan, for evaluating examinations of using the Binax NOW Malaria Rapid Diagnostic Test (Binax Inc, USA) and RT-PCR using QIAGEN – QIAamp DNA Mini Kit for *Plasmodium* species. We also thank the Japanese Red Cross Society Saitama Blood Center, for their Duffy-blood group antigen evaluations.

Disclosure

The authors report no conflicts of interest in this work.

References

- Price RN, Tjitra E, Guerra CA, et al. Vivax malaria: neglected and not benign. *Am J Trop Med Hyg.* 2007;77(Suppl 6):79–87.
- Carlton JM, Adams JH, Silva JC, et al. Comparative genomics of the neglected human malaria parasite *Plasmodium vivax*. *Nature.* 2008;455(7214):757–763.
- Argawal R, Nath A, Gupta G. Noninvasive ventilation in *Plasmodium vivax* related ALI/ARDS. *Intern Med.* 2007;46:2007–2011.
- Rebaudet S, Bogreau H, Silai R, et al. Genetic structure of *Plasmodium falciparum* and elimination of malaria, Comoros archipelago. *Emerg Infect Dis.* 2010;16(11):1686–1694.
- Chaudhuri A, Polyakova J, Zbrzezna V, et al. Cloning of glycoprotein D cDNA, which encodes the major subunit of the Duffy blood group system and the receptor for the *Plasmodium vivax* malaria parasite. *Proc Natl Acad Sci U S A.* 1993;90(22):10793–10797.
- Michon P, Fraser T, Adams JH. Naturally acquired and vaccine-elicited antibodies block erythrocyte cytoadherence of the *Plasmodium vivax* Duffy binding protein. *Infect Immun.* 2000;(6896):3164–3171.
- Matsuoka H, Hasegawa M, Ishii A, et al. A survey of malaria, glucose-6-phosphate dehydrogenase deficiency and Duffy blood group in six localities in Guatemala. *J J Trop Med Hyg.* 1988;16:1–9.
- Howes RE, Patil AP, Piel FB, et al. The global distribution of the Duffy blood group. *Nat Commun.* 2011;2:266.
- ter Kuile FO, Rogerson SJ. *Plasmodium vivax* infection during pregnancy: an important problem in need of new solutions. *Clin Infect Dis.* 2008;46:1382–1384.
- Baird JK. Neglect of *Plasmodium vivax* malaria. *Trends Parasitol.* 2007;23(11):533–539.
- Nosten F, McGready R, Simpson JA, et al. Effects of *Plasmodium vivax* malaria in pregnancy. *Lancet.* 1999;354(9178):546–549.
- Mizuno Y, Kudo K, Kano S. Difficulty of proper diagnosis for an imported vivax malaria patient from Africa. *Kansenshogaku Zasshi.* 2007;81(5):597–599. Japanese.

International Medical Case Reports Journal

Dovepress

Publish your work in this journal

The International Medical Case Reports Journal is an international, peer-reviewed open-access journal publishing original case reports from all medical specialties. Previously unpublished medical posters are also accepted relating to any area of clinical or preclinical science. Submissions should not normally exceed 2,000 words or

4 published pages including figures, diagrams and references. The manuscript management system is completely online and includes a very quick and fair peer-review system, which is all easy to use. Visit <http://www.dovepress.com/testimonials.php> to read real quotes from published authors.

Submit your manuscript here: <http://www.dovepress.com/international-medical-case-reports-journal-journal>