

Evaluation of tensile strength of tissue adhesives and sutures for clear corneal incisions using porcine and bovine eyes, with a novel standardized testing platform

Simon Kaja
Daryl L Goad
Fatima Ali
Ashley Abraham
R Luke Rebenitsch
Savak Teymoorian
Rohit Krishna
Peter Koulen

Vision Research Center and
Department of Ophthalmology,
University of Missouri-Kansas City,
School of Medicine, Kansas City, MO,
USA

Background: Tissue adhesives for ophthalmologic applications were proposed almost 50 years ago, yet to date no adequate tissue glues have been identified that combine strong sealing properties with adequate safety and absence of postsurgical side effects. In recent years, cataract surgeries and Descemet's stripping with endothelial keratoplasty procedures have significantly increased the number of clear corneal incisions performed. One of the obstacles to discovery and development of novel tissue adhesives has been the result of nonstandardized testing of potential tissue glues.

Methods: We developed an instrument capable of controlling intraocular pressure in explanted porcine and bovine eyes in order to evaluate sealants, adhesives, and surgical closure methods used in ophthalmic surgery in a controlled, repeatable, and validated fashion. We herein developed and validated our instrument by testing the adhesive properties of cyanoacrylate glue in both porcine and bovine explant eyes.

Results: The instrument applied and maintained intraocular pressure through a broad range of physiological intraocular pressures. Cyanoacrylate-based glues showed significantly enhanced sealing properties of clear corneal incisions compared with sutured wounds.

Conclusion: This study shows the feasibility of our instrument for reliable and standardized testing of tissue adhesive for ophthalmological surgery.

Keywords: manometer, intraocular pressure, applanation tonometry, clear corneal incision, tissue adhesive, ocular surgery

Introduction

Cataract surgery utilizes clear corneal incisions, and the increasing frequency of Descemet's stripping with endothelial keratoplasty (DSEK) has led to an increase in the number of clear corneal incisions performed.^{1,2} Because traditional suturing methods are time-intensive and increase the risk of surgical complications, such as leaks around the incision and stability of the chamber,³ sutureless clear corneal incisions have gained popularity, and 92% of surgeons prefer sutureless closure techniques.^{1,2}

Several studies have documented an increased risk of postoperative endophthalmitis following sutureless clear corneal incisions when compared with sutured corneal incisions.^{1,4-6} The intrinsic self-healing properties of the cornea are affected by changes in intraocular pressure and/or exogenously applied pressure.⁷ Failure of wound closure, resulting in prolapse of the chamber, increases the risk of endophthalmitis and

Correspondence: Peter Koulen
University of Missouri-Kansas City,
School of Medicine, Vision Research
Center, 2411 Holmes St,
Kansas City, MO 64108, USA
Tel +1 816 404 1834
Fax +1 816 404 1825
Email koulenp@umkc.edu

astigmatism,⁸ which is observed much more frequently in patients with sutureless wound closures.⁹

DESK incisions are frequently closed with sutures given their larger diameter (4.5–6.0 mm), increasing the risk of wound dehiscence, astigmatism, or even neovascularization.^{4–6} The use of tissue adhesives can provide a suitable and safe alternative to sutures.¹⁰ Of particular benefit, adhesives provide fast wound closure, minimal corneal cytotoxicity, as well as an additional bacteriostatic effect that reduces the risk of endophthalmitis.^{1,10,11} Tissue adhesives have been proposed for clear corneal incisions for almost half a century. Most efforts have focused on fibrin-based and cyanoacrylate-based compounds,^{10,12,13} as well as photodynamic biologic tissue glues.^{14–16} However, to date, no adequate tissue glues have been identified that combine strong sealing properties with adequate safety and absence of postsurgical side effects.^{1,10}

Nonstandardized testing of potential tissue glues is one major obstacle to the discovery and development of novel clinically useful tissue adhesives. We therefore developed an instrument capable of controlling intraocular pressure in explanted porcine and bovine eyes in order to evaluate sealants, adhesives, and surgical closure methods used in ophthalmic surgery in a controlled, repeatable, and validated fashion. Our instrument allows both destructive and nondestructive preclinical testing of these surgical adjuncts to establish their operational parameters.

We herein validated our instrument by testing the adhesive properties of cyanoacrylate glue as compared with a traditional suturing method in both porcine and bovine explant eyes. The instrument applied and maintained intraocular pressure through a broad range of physiological intraocular pressures. Cyanoacrylate-based glues showed significantly enhanced sealing properties for clear corneal incisions compared with sutured wounds. This study shows the feasibility of our instrument for reliable and standardized testing of tissue adhesive for ophthalmological surgery.

Materials and methods

Instrument design

The design of the instrument was based on two hydrostatic pressure reservoirs (Nalgene, Rochester, NY), a relieving pressure regulator, and a digital manometer (both from Omega Engineering Inc, Stamford, CT). A two-meter high support rod was used to adjust the first reservoir to provide a static pressure up to 120 mmHg, while the second lower reservoir allowed for testing lower pressures up to 40 mmHg. For the instrument design, we assumed that a one meter high

column of phosphate-buffered saline at 4°C has a specific gravity of 1.02 g/cm³, resulting in a pressure of 75 mmHg.

Tubing, valves, and manifolds were obtained from Cole-Parmer (Vernon Hills, IL) and used to build the device as shown in Figure 1. Manifolds allow the operator to select the supply pressure reservoir and to isolate the eye and manometer from the reservoir depending on the requirements of the experiment.

Cadaver eyes were attached to the device through a 30 gauge needle (BD Biosciences, Bedford, MA) inserted through the optic nerve into the chamber. For validation, the intraocular pressure applied by our instrument was compared with measurements of intraocular pressure obtained using applanation tonometry (Tono-Pen XL, Reichert Ophthalmic Instruments, Depew, NY).

Cadaver eyes and experimental design

All experiments were in accordance with the Association for Research in Vision and Ophthalmology Statement for the Use of Animals in Ophthalmic and Visual Research and institutional guidelines. Freshly isolated bovine and porcine cadaver eyes were obtained from a local abattoir (Paradise Meats, Trimble, MO). A limbal clear corneal incision (2.5 mm), identical to those used in phacoemulsification procedures, was performed on each eye, using a 2.5 mm crescent-angled blade knife. The incisions were closed either using a 10-0 nylon suture (Ethilon, Ethicon, San Angelo, TX) or by application of 2 µL of *n*-butyl cyanoacrylate tissue adhesive (Liquivet Rapid, Oasis Medical, Metawa, IL, Figure 3A).

Wound integrity was measured using stepwise increases in hydrostatic elevation of intraocular pressure, paired with optical monitoring of wound closure and fluid leakage. Eyes were initially pressurized to 20 mmHg and the intraocular pressure was then increased by 10 mmHg every 3 minutes to a pressure at which significant loss of tissue integrity was observed. The maximal pressures were 120 mmHg and 140 mmHg for bovine and porcine eyes, respectively. Once maximal intraocular pressure was achieved, the eyes were held at this pressure for an additional 15 minutes. Visual observation of fluid leakage was considered failure of wound closure.

Results

Testing and validation of the instrument

Based on the theoretical design, the system was built as shown in Figure 1 utilizing two hydrostatic pressure reservoirs combined with a relieving pressure regulator providing fine control of the applied intraocular pressure.

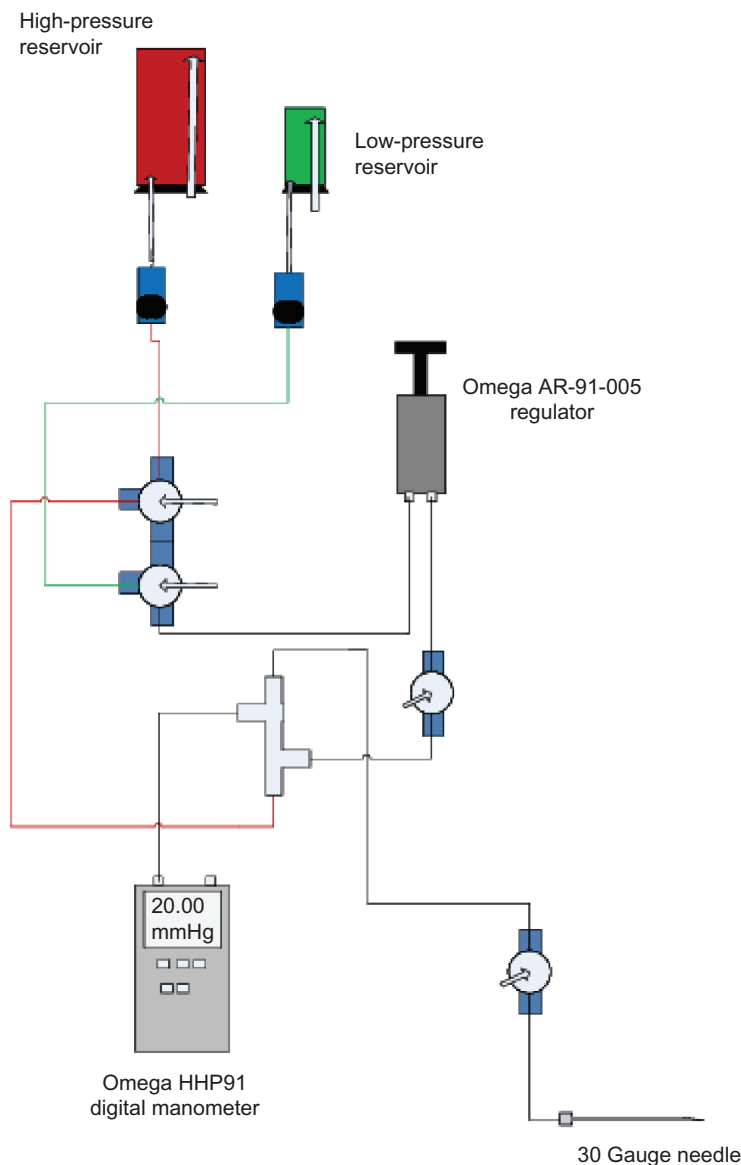


Figure 1 Schematic diagram of our instrument to evaluate tensile strength. Two hydrostatic pressure reservoirs, filled with phosphate-buffered saline, serve to apply low (up to 40 mmHg) or high intraocular pressures (up to 140 mmHg). Manual switches allow selection of the appropriate pressure reservoir. A manifold feeds the solution into a relieving bypass pressure regulator allowing fine adjustment of intraocular pressure applied to the explant eyes. A digital intraocular pressure readout is achieved through a digital manometer attached via a Y connector and mounted in the same horizontal plane as the eyeball to ensure an accurate readout.

The pressure applied could be read on a digital manometer placed at the same height as the eyeball.

In order to calibrate and validate our system, we applied three different intraocular pressures (10, 30, and 60 mmHg) to both porcine and bovine eyes. After equilibration for one minute at the chosen pressure using the manometer readout, intraocular pressure was measured using applanation tonometry. Across the range of physiological intraocular pressures, our instrument accurately applied the desired intraocular pressure, with less than 2% difference from the intraocular pressure measured using a Tono-Pen-XL in both bovine ($n = 5$; Figure 2A) and porcine ($n = 5$; Figure 2B) eyes.

Evaluation of tensile strength of tissue adhesives and sutures

We next used our instrument to compare the tensile strength after closure of limbal clear corneal incisions with either a 10-0 nylon suture or application of cyanoacrylate-based tissue adhesive (Figure 3A).

In bovine eyes, wounds sealed with tissue adhesive withstood intraocular pressures up to 120 mmHg without exception (120 ± 0 mmHg; $n = 13$), whereas leakage was observed in wounds closed with a suture at 84 ± 2 mmHg ($n = 13$; Figure 3B). Similarly in porcine eyes, clear corneal incisions closed with tissue adhesive did not leak or burst

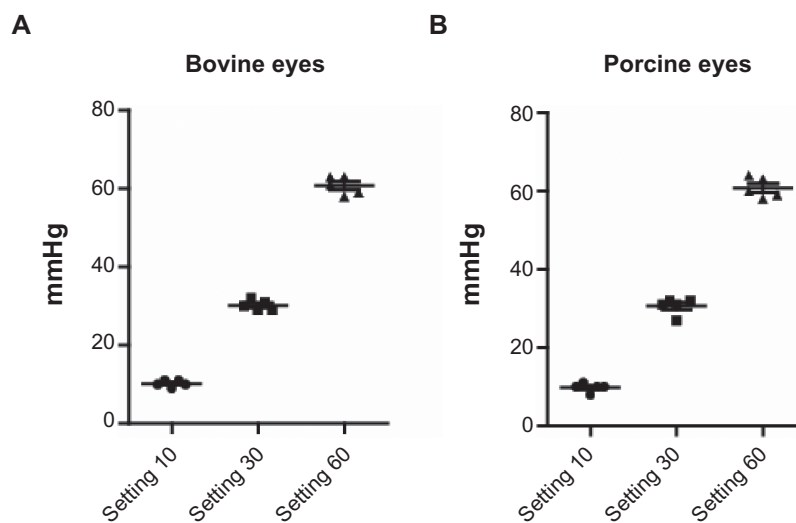


Figure 2 Validation of the instrument. Digital readout and correct application of intraocular pressure in bovine (A) and porcine (B) eyes was validated by applanation tonometry. Intraocular pressures across a range of 10–60 mmHg were accurately applied, with less than 2% variation in tonometry readings.

up to intraocular pressures of 140 mmHg (140 ± 0 mmHg; $n = 9$), whereas sutured wounds showed leakage of fluids at 76 ± 4 mmHg ($n = 7$; Figure 3C).

In some eyes, we observed small visible tears in the sclera, indicating that the adhesive bond was stronger than the structural integrity of the eye tissue.

Discussion

We developed an instrument that provides a reliable platform for both nondestructive and destructive testing of tissue adhesives and suture techniques for ophthalmological applications. Our instrument has several advantages; most importantly, it is based on two hydrostatic pressure reservoirs coupled with

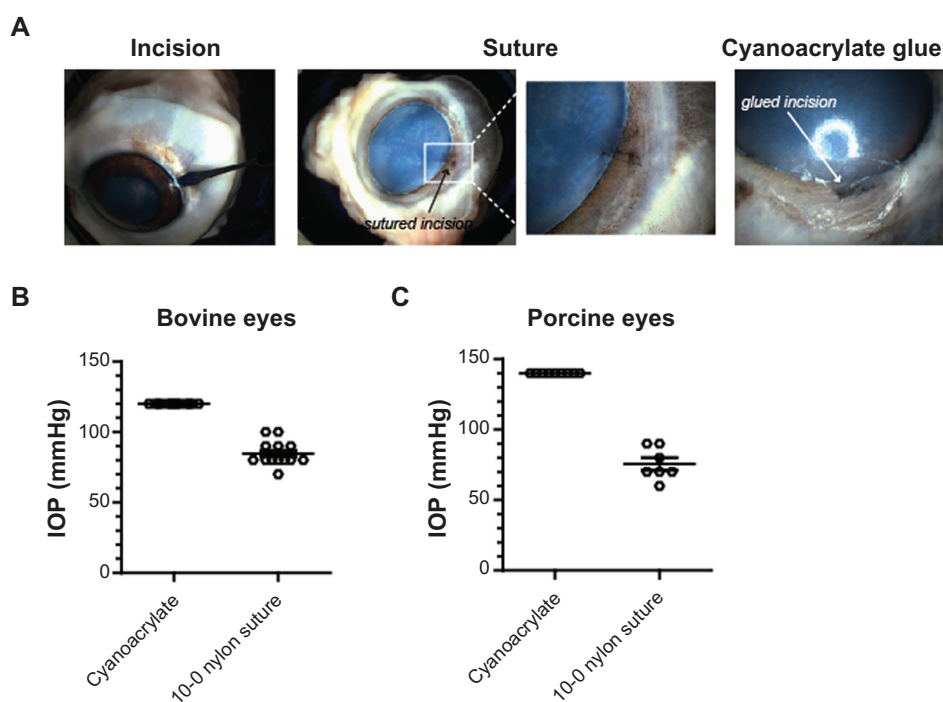


Figure 3 Comparison of tensile strength using tissue adhesive or sutures. (A) Representative images of porcine cadaver eyes with clear corneal incisions using a 2.5 mm crescent-angled knife, incision closed by suture, or using cyanoacrylate-based tissue adhesive. (B) Clear corneal incisions did not show leakage at sustained intraocular pressure of 120 mmHg in bovine eyes, whereas leakage and compromised wound integrity were observed in sutured eyes at 84 ± 2 mmHg ($n = 13$). (C) Porcine eyes showed a similar tensile strength after suturing 76 ± 4 mmHg ($n = 7$), while wounds closed with glue withstood 140 mmHg pressure.

a relieving pressure regulator providing accurate, constant pressure, and eliminating the need for manual repositioning of saline reservoirs during the experiments to maintain the desired pressure. A previous report described a system for control of static pressure using a manually operated syringe to generate static pressure on explanted eyes.¹ The uses of a syringe to establish, increase, and maintain intraocular pressure in explanted eyes adds to the variability of experiments. Our device allows for more consistent and precise control of intraocular pressure, and limits testing to a physiologic range of pressures, up to and including failure of scleral tissues.

In order to validate our system, we used a Tono-Pen XL applanation tonometer. Given the similar corneal thickness of porcine, bovine, and human eyes, the Tono-Pen yields accurate measurements of intraocular pressure, as shown previously.^{17,18}

We have shown that cyanoacrylate glues may provide a suitable alternative to sutures for closure of clear corneal incisions. Specifically, *n*-butyl cyanoacrylate may prove useful for ophthalmic applications. As such, we confirm previous data from a variety of other experimental systems testing 2-octyl cyanoacrylate (Dermabond®),^{19–21} and *n*-butyl cyanoacrylate^{1,22} using our novel standardized testing platform. Furthermore, to our knowledge, this is the first report comparing the tensile strength of tissue adhesives and sutures for clear corneal incisions in both porcine and bovine eyes, as well as validating intraocular pressures with applanation tonometry.

Our novel instrument overcomes the obstacles previously encountered when testing tissue adhesives for ophthalmological use by providing a validated, standardized, and reliable testing platform.

Acknowledgments

This study was supported by the Felix and Carmen Sabates Missouri Endowed Chair in Vision Research and the Vision Research Foundation of Kansas City. We thank Dr Larry and Betsy Piebenga, Margaret, Richard, and Sara Koulen for their generous support and encouragement.

Disclosure

The authors report no conflicts of interest in this work.

References

1. Banitt M, Malta JB, Soong HK, Musch DC, Mian SI. Wound integrity of clear corneal incisions closed with fibrin and N-butyl-2-cyanoacrylate adhesives. *Curr Eye Res.* 2009;34(8):706–710.
2. Leaming DV. Practice styles and preferences of ASCRS members – 2003 survey. *J Cataract Refract Surg.* 2004;30(4):892–900.
3. Ashwin PT, Shah S, Wolffsohn JS. Advances in cataract surgery. *Clin Exp Optom.* 2009;92(4):333–342.
4. Terry MA, Shamie N, Chen ES, Hoar KL, Friend DJ. Endothelial keratoplasty a simplified technique to minimize graft dislocation, iatrogenic graft failure, and pupillary block. *Ophthalmology.* 2008;115(7):1179–1186.
5. Koenig SB, Covert DJ. Early results of small-incision Descemet's stripping and automated endothelial keratoplasty. *Ophthalmology.* 2007;114(2):221–226.
6. Gorovoy MS. Descemet-stripping automated endothelial keratoplasty. *Cornea.* 2006;25(8):886–889.
7. Sarayba MA, Taban M, Ignacio TS, Behrens A, McDonnell PJ. Inflow of ocular surface fluid through clear corneal cataract incisions: a laboratory model. *Am J Ophthalmol.* 2004;138(2):206–210.
8. Gogate PM. Small incision cataract surgery: Complications and mini-review. *Indian J Ophthalmol.* 2009;57(1):45–49.
9. Thoms SS, Musch DC, Soong HK. Postoperative endophthalmitis associated with sutured versus unsutured clear corneal cataract incisions. *Br J Ophthalmol.* 2007;91(6):728–730.
10. Chan SM, Boisjoly H. Advances in the use of adhesives in ophthalmology. *Curr Opin Ophthalmol.* 2004;15(4):305–310.
11. Chen WL, Lin CT, Hsieh CY, Tu IH, Chen WY, Hu FR. Comparison of the bacteriostatic effects, corneal cytotoxicity, and the ability to seal corneal incisions among three different tissue adhesives. *Cornea.* 2007;26(10):1228–1234.
12. Henrick A, Gaster RN, Silverstone PJ. Organic tissue glue in the closure of cataract incisions. *J Cataract Refract Surg.* 1987;13(5):551–553.
13. Webster RG Jr, Slansky HH, Refojo MF, Boruchoff SA, Dohlman CH. The use of adhesive for the closure of corneal perforations. Report of two cases. *Arch Ophthalmol.* 1968;80(6):705–709.
14. Goins KM, Khadem J, Majmudar PA. Relative strength of photodynamic biologic tissue glue in penetrating keratoplasty in cadaver eyes. *J Cataract Refract Surg.* 1998;24(12):1566–1570.
15. Goins KM, Khadem J, Majmudar PA, Ernest JT. Photodynamic biologic tissue glue to enhance corneal wound healing after radial keratotomy. *J Cataract Refract Surg.* 1997;23(9):1331–1338.
16. Khadem J, Truong T, Ernest JT. Photodynamic biologic tissue glue. *Cornea.* 1994;13(5):406–410.
17. Ruiz-Ederra J, Garcia M, Hernandez M, et al. The pig eye as a novel model of glaucoma. *Exp Eye Res.* 2005;81(5):561–569.
18. Passaglia CL, Guo X, Chen J, Troy JB. Tono-Pen XL calibration curves for cats, cows and sheep. *Vet Ophthalmol.* 2004;7(4):261–264.
19. Leung GY, Peponis V, Varnell ED, Lam DS, Kaufman HE. Preliminary in vitro evaluation of 2-octyl cyanoacrylate (Dermabond) to seal corneal incisions. *Cornea.* 2005;24(8):998–999.
20. Ritterband DC, Meskin SW, Shapiro DE, Kusmierczyk J, Seedor JA, Koplin RS. Laboratory model of tissue adhesive (2-octyl cyanoacrylate) in sealing clear corneal cataract wounds. *Am J Ophthalmol.* 2005;140(6):1039–1043.
21. Straatsma BR. Experimental ophthalmic surgery employing cyanoacrylate adhesives. *Trans Am Ophthalmol Soc.* 1968;66:986–1021.
22. Sharma A, Kaur R, Kumar S, et al. Fibrin glue versus N-butyl-2-cyanoacrylate in corneal perforations. *Ophthalmology.* 2003;110(2):291–298.

Clinical Ophthalmology

Publish your work in this journal

Clinical Ophthalmology is an international, peer-reviewed journal covering all subspecialties within ophthalmology. Key topics include: Optometry; Visual science; Pharmacology and drug therapy in eye diseases; Basic Sciences; Primary and Secondary eye care; Patient Safety and Quality of Care Improvements. This journal is indexed on

Submit your manuscript here: <http://www.dovepress.com/clinical-ophthalmology-journal>

Dovepress

PubMed Central and CAS, and is the official journal of The Society of Clinical Ophthalmology (SCO). The manuscript management system is completely online and includes a very quick and fair peer-review system, which is all easy to use. Visit <http://www.dovepress.com/testimonials.php> to read real quotes from published authors.