

# Optimal management of equine keratomycosis

Paula D Galera<sup>1</sup>  
Dennis E Brooks<sup>2</sup>

<sup>1</sup>College of Veterinary Medicine,  
University of Brasilia, DF, Brazil;

<sup>2</sup>Departments of Large and Small  
Animal Clinical Sciences, College of  
Veterinary Medicine, University of  
Florida, Gainesville, FL, USA

**Abstract:** Keratomycosis in the horse exists in several unique clinical forms. This paper discusses the diagnosis and clinical management of keratomycosis in the horse associated with tear film instability, epithelial keratopathy, subepithelial infiltrates, superficial and deep ulcers, plaques, melting ulcers, descemetocoeles, iris prolapse, and stromal abscesses. Prompt diagnosis and aggressive treatment of equine keratomycosis can make a major difference in the maintenance of a cosmetic and visual eye.

**Keywords:** fungal keratitis, keratomycosis, horse, cornea, melting, keratoplasty

## Introduction

Keratomycosis in the horse is associated with significant ocular morbidity, is considered a common vision-threatening disease of the horse, and remains a diagnostic and therapeutic challenge to the ophthalmologist, equine veterinarian, and horse owner.<sup>1-12</sup> Once considered mainly a posttraumatic eye problem,<sup>4</sup> keratomycosis in horses is now also being diagnosed more frequently in temperate geographical regions,<sup>5,6</sup> although warm, humid, and subtropical environments are still important risk factors for the various forms of equine keratomycosis.<sup>1-3</sup>

Fungi are normal inhabitants of the equine environment and corneal/conjunctival microflora, and exist in symbiosis with ocular surface bacteria on the horse.<sup>1,4,6,13</sup> Some of these fungal species may be innately pathogenic, while others can become pathogenic following corneal injury and/or alterations in the microenvironment of the ocular surface.<sup>4,14,15</sup> A lack of integrity and stability of the precorneal tear film, and corneal epithelial cell injury predispose and encourage fungal adhesion, invasion, and infection of the horse cornea.<sup>9,14,16</sup> It may be that unique characteristics of the horse tear film, low resting temperature of the horse cornea, a large corneal surface, and/or interspecies alterations in corneal immunoprotection make the horse more susceptible than other animal species to keratomycosis.<sup>14,15</sup>

The most often proposed pathogenesis of ulcerative fungal keratitis in horses begins with slight to severe corneal trauma, resulting in an epithelial defect.<sup>8,16</sup> Corneal epithelial cell loss allows the ocular surface or environmental fungal organisms to adhere, invade, and infect the cornea.<sup>3,14</sup> Seeding of fungi from a foreign body of plant origin is also possible.<sup>8,9,16</sup> A concurrent viral or bacterial corneal infection may be present to weaken the corneal defense mechanisms of the ocular surface.<sup>16,17</sup> Fungal infection may be suspected when there is a history of corneal trauma,<sup>8</sup> or when a corneal ulcer has been treated with antibiotic therapy for a long

Correspondence: Dennis E Brooks  
2015 SW 16 Ave, Gainesville,  
FL 32608, USA  
Tel +1 352 294 4455  
Fax +1 352 392 6125  
Email brooksd@ufl.edu

period, or if corticosteroids were previously used topically to treat ocular surface disease.<sup>2,14,17,18</sup> We suspect other factors may also play a role in the development of equine keratomycosis.

## General management of equine keratomycosis

Keratomycosis of the horse is found as a continuum of lesions, and in ulcerative and nonulcerative forms. Fungal keratitis in the horse can be grouped into three basic categories, ie, superficial keratomycoses (including tear film alterations and microerosions, superficial ulceration, and plaque formation), stromal ulcerative keratomycosis (including deep ulcers with corneal furrowing, melting ulcers, and corneal perforation with iris prolapse), and stromal abscesses.<sup>3</sup> Slight to severe corneal haze, varying amounts and depths of white to yellow cellular infiltration, no to intense corneal vascularization, and varying degrees of painful iridocyclitis can be present in the several forms of equine keratomycosis. *Aspergillus*, *Fusarium*, *Cylindrocarpon*, *Curvularia*, *Penicillium*, *Cystodendron*, yeasts, and molds are known causes of ulcerative and nonulcerative keratomycosis in horses,<sup>16</sup> and *Mortierella wolfii* was also recently described.<sup>19</sup> Clinical signs like microerosion, nonulcerative or ulcerative lesions with whitish to yellow opacification, corneal vascularization, plaque formation, melting, and perforation, as well as secondary uveitis and signs of ocular pain are common in equine keratomycosis.<sup>3</sup>

Diagnostic tests in horses with corneal diseases should include fluorescein and rose Bengal staining,<sup>8</sup> tear film breakup time, superficial and deep corneal cytology, superficial and deep corneal cultures with attempted growth on both fungal and aerobic plates, and corneal biopsy if surgery is performed.<sup>16,20</sup> Rose Bengal retention indicates instability of the tear film and may be associated with a poor prognosis for rapid healing.<sup>8,14</sup> The presence of fungal microorganisms on cytological scrapings from a corneal lesion is a significant finding indicating advanced fungal disease.<sup>21</sup> Even in cases where culturing or histopathology cannot identify a fungal agent, fungal DNA can be present and identified by polymerase chain reaction.<sup>2,22</sup> Laser scanning confocal microscopy is a new emerging technology useful as an in vivo, noninvasive diagnostic test for ocular surface diseases that can aid in the diagnosis of equine fungal keratitis and confirm the presence of fungi in deep corneal stromal lesions in horses.<sup>23–26</sup>

Differential diagnoses for equine keratomycosis depend on the type of fungal infection but generally include

keratoconjunctivitis sicca,<sup>16</sup> bacterial keratitis, eosinophilic keratoconjunctivitis, immune-mediated keratitis, herpes virus keratitis, traumatic keratopathy, corneal degeneration, calcific band keratopathy, and corneal neoplasia.<sup>3</sup>

Regardless of the clinical manifestation (epithelial keratitis, ulcerative keratitis, stromal abscess, melting ulcers, iris prolapse), some of the same treatment steps are utilized in all forms of equine keratomycosis, and others are used primarily in the more severe forms of equine keratomycosis. Medical therapy, even with adjunctive surgical procedures, remains the major source of disease control for equine keratomycosis. Subpalpebral lavage systems aid medication instillations in horses with keratomycosis because frequent topical instillations over prolonged periods of time are generally required.<sup>14</sup>

Selection of specific and efficacious therapeutic topical and systemic medication regimen for equine keratomycosis requires recognition of the presence or absence of fungal and bacterial infection, the degree of stromal destruction, the level of tear film proteinase activity, the presence and severity of intraocular inflammation, and the degree of ocular pain.<sup>3</sup> Treatment must be directed against the fungi as well as against the iridocyclitis that occurs following fungal replication and death.<sup>3,16</sup> The role of antiprotease therapy in corneal destruction caused by equine keratomycosis may ultimately be of greater importance than the fungal infection itself, and inability to control hyperproteinase activity is often the major reason for treatment failure.<sup>2,14</sup> Therapy is often quite prolonged, scarring of the cornea can be prominent,<sup>16</sup> and surgical therapy for equine keratomycosis may be necessary depending on the clinical manifestation of the disease.<sup>22,27–30</sup> It is important to consider that horses with keratomycosis usually receive four or more topical medications, and that rarely the possible conflicting effects of one drug on another are considered. It is thus prudent to allow a minimum of 5 minutes between each medication using subpalpebral lavage tubes.<sup>31</sup> Despite the increased awareness of owners and veterinarians, and despite aggressive therapy, some forms of equine keratomycosis still retain a guarded prognosis for sight.<sup>32</sup>

## Medical therapy

In addition to in vitro susceptibility data, selection of an ophthalmic antifungal should include consideration of drug toxicity, tissue penetration, ease of administration, and availability.<sup>13</sup> Three major classes of antimycotic drugs are available, ie, polyenes (natamycin and amphotericin B), azoles, and nucleoside analogs.<sup>33</sup> In clinical practice, equine

keratomycosis is most effectively treated with the azoles and/or natamycin.<sup>15</sup> Polyenes have an excellent spectrum of activity, but penetrate the intact cornea poorly,<sup>15,31</sup> whereas azoles have a good corneal penetration but vary in their fungal susceptibility.<sup>34</sup> Amphotericin B is more effective against yeasts, in particular *Candida* spp<sup>12,33</sup> and *Aspergillus* spp, but has a limited effect on *Fusarium*.<sup>12</sup> The combination of topical amphotericin B with subconjunctival injection of fluconazole in humans was more effective than the use of amphotericin B alone, suggesting that combination antifungal therapy can be a good choice.<sup>12</sup>

Natamycin is generally effective against filamentous fungi,<sup>14,33,35</sup> although frequent administration is necessary to achieve therapeutic levels in the cornea<sup>33</sup> because of its reported poor penetration in this tissue.<sup>2,11,15</sup> We would argue that natamycin is highly active in deep stromal abscess and penetrates corneas debrided of epithelium quite easily when normal permeability function is diminished,<sup>36</sup> and thus remains a very important drug to use in equine keratomycosis.

Miconazole, natamycin, fluconazole, econazole, voriconazole, clotrimazole, and itraconazole have been successfully used topically to treat fungal ulcers in horses but their effects can vary according to geographic region and can change over time.<sup>14</sup> In Florida in 1998, fungi such as *Aspergillus* and *Fusarium* were equally susceptible to natamycin and miconazole,<sup>6,9</sup> but presently miconazole is most effective against *Aspergillus* and natamycin against *Fusarium*. Miconazole and ketoconazole were effective against *Fusarium* spp<sup>14</sup> and itraconazole was particularly effective against *Aspergillus* spp.<sup>33</sup> Recently, in vitro testing of the effects of itraconazole, miconazole, and natamycin at different concentrations on cellular morphology and cellular proliferation of equine keratocytes were evaluated. Itraconazole showed markedly fewer cytopathologic effects, and natamycin produced the most severe morphological changes in keratocytes at all concentrations and time points.<sup>10</sup> The use of irritating drugs is often necessary to eliminate specific fungal species, but clinicians should exercise some caution in using drugs such as natamycin when fungi are not present.

In a recent in vitro study, voriconazole penetrated the intact horse cornea<sup>14</sup> and appeared to be the most effective antifungal drug for initial treatment of equine keratomycosis.<sup>9,14</sup> It is now our first choice for antifungal therapy because common equine fungal pathogens, including *Fusarium*, *Aspergillus*, and *Candida* are susceptible to it.<sup>37</sup> Voriconazole concentrations were also established at therapeutic levels in horse aqueous humor after oral

and topical administration, and were also detected in the plasma following topical administration.<sup>38</sup> Subconjunctival voriconazole has also been used to treat equine keratomycosis cases, although its efficacy by this method has not been verified.<sup>39</sup> Although reported as being less frequent than other fungi, *Candida* spp can also be treated with amphotericin B,<sup>12,13,33</sup> natamycin,<sup>37</sup> or flucytosine, a nucleoside analog.<sup>14</sup> The 1% flucytosine parenteral solution is well tolerated for topical ophthalmic use.<sup>33</sup>

Silver sulfadiazine<sup>14,35</sup> and dilute (1:50) povidine iodine can also be used for equine keratomycosis. Silver sulfadiazine has both antibacterial and antifungal properties, and povidine iodine is effective against bacteria, fungi, viruses, and protozoa.<sup>14</sup> Although the antifungal activity of silver sulfadiazine was not evaluated in vivo, the results of one in vitro study and many clinical anecdotes show that it could be useful in clinical cases of equine keratomycosis.<sup>35</sup> We do not recommend silver sulfadiazine in equine keratomycosis in Florida because it does not appear to work well. We use dilute povidine iodine twice daily in our lavage tubing treatments. Chlorhexidine gluconate 0.2% has been used effectively to treat fungal keratitis resistant to antifungal drugs in humans and needs to be evaluated in horses.<sup>40</sup>

Antifungal drug resistance is well recognized, and its prevention depends on maximizing the pharmacodynamic properties of the particular drug class, use of local rather than systemic treatment, and practicing good hygiene.<sup>15</sup> We have noted resistance to miconazole to *Fusarium*, and natamycin resistance by *Aspergillus* in Florida in the past decade.

Prophylactic topical antibacterial drugs include triple antibiotic preparations (neomycin, polymyxin B, gramicidin, or bacitracin), tetracyclines, macrolides, and aminoglycosides.<sup>31</sup> Gentamicin, ciprofloxacin, and tobramycin ophthalmic solutions may be used topically to treat Gram-negative bacteria.<sup>5,14</sup> Amikacin 10 mg/L is another choice. Chloramphenicol may be useful,<sup>5</sup> although it is bacteriostatic. Cefazolin 55 mg/mL is the best treatment for Gram-positive infections such as *Streptococcus*.<sup>14</sup>

Iridocyclitis is present to some degree with the different forms of equine keratomycosis, and varies according to progression of the disease. Ocular pain and uveitis may increase for a time after starting antifungal medications due to fungus death.<sup>14,19</sup> Uveitis must be controlled to prevent blindness, and is treated in horses by both the topical and systemic routes. Nonsteroidal anti-inflammatory agents such as flunixin meglumine (1 mg/kg orally, intravenously, or intramuscularly twice daily) and phenylbutazone (2 mg/kg orally twice daily) can be used. Both are effective in reducing

uveal exudation and relieving ocular discomfort, but flunixin meglumine is the most frequently used and efficacious nonsteroidal anti-inflammatory agent for systemic treatment of iridocyclitis in horses.<sup>14</sup> Flunixin and all other systemically administered nonsteroidal anti-inflammatory agents should be used at the lowest dosage to control pain, because they appear to reduce the speed of corneal vascularization at higher doses.<sup>14</sup> Atropine 1% solution is effective in causing pupillary dilatation and stabilizing the blood-aqueous barrier. It also minimizes synechiae formation and reduces ciliary muscle spasm, a factor contributing to ocular discomfort. Horses on atropine should be monitored carefully for signs of reduced intestinal motility and episodes of colic.<sup>41</sup> Despite their potential to prevent rejection and minimize inflammation, corticosteroids are contraindicated in horses because of a high incidence of infectious and collagenolytic keratitis.<sup>2,42</sup> Resolution of the corneal condition results in a gradual resolution of the signs of uveitis.<sup>42</sup>

After corneal damage, elevated levels of matrix metalloproteinases from inflammatory cells, epithelial cells, and keratocytes can be detected in the tears, relative to that of the contralateral healthy eye.<sup>43</sup> The metalloproteinases play a role in the degradation of matrix components, such as collagen.<sup>32,44</sup> As levels of matrix metalloproteinases and serine proteases (like neutrophil elastase) become elevated in the tears of horses, prevention and control of collagenolysis is extremely important to speed corneal healing and reduce scarring. Metalloproteinases are inhibited by tissue inhibitor of metalloproteinase, serum and disodium ethylenediamine tetra-acetic acid, tetracyclines, and acetylcysteine. Serine proteases are inhibited by prealbumin inhibitor. Serum contains growth factors, fibronectin, and vitamins (especially vitamin A) that stimulate epithelial cell growth, migration, and differentiation.<sup>32,33,43</sup> Serum was compared with fresh frozen plasma with regard to corneal epithelium healing in vitro and differences were found. Serum contains more concentrated levels of epithelial growth factor, platelet-derived growth factor, and vitamin A compared with plasma, which probably makes serum significantly superior with regard to stimulation of corneal healing.<sup>45</sup> Serum or plasma can be administered topically as often as necessary, and is replaced by new serum every 8 days.<sup>14</sup> Ten percent acetylcysteine or 0.17% ethylenediamine tetra-acetic acid and tetracyclines (oxytetracyclines, doxycycline) can also be administered until stromal liquefaction diminishes. In some eyes, both ethylenediamine tetra-acetic acid and serum are needed and used simultaneously to stop melting.<sup>14,44,46</sup>

## Surgical treatment

Fungal keratitis in horses has been described and grouped into three basic categories, ie, superficial keratomycoses (including tear film alterations and microerosions, superficial ulceration, and plaque formation), stromal ulcerative keratomycosis (including deep ulcers with corneal furrowing, melting ulcers, and corneal perforation with iris prolapse), and stromal abscesses.<sup>3</sup> Aggressive medical treatment for all forms of equine keratomycosis may need to be combined with surgical therapy in eyes where there is a poor response to topical antifungal therapy, epithelial and fungal debris is pronounced, collagenolytic activity is extreme,<sup>9</sup> stromal loss is greater than one third corneal thickness (including deep ulcers and descemetocoeles), corneal perforation occurs, and/or if the anterior uveitis cannot be controlled.<sup>3,9,14</sup> The surgical procedure chosen depends on the depth and location of the offending lesion.<sup>22</sup>

## Epithelial debridement/superficial keratectomy

We have observed that dead fungi are difficult to remove by phagocytosis and enzymatic dissolution due to their large size, and their physical presence may inhibit corneal healing, and thus need to be removed surgically. Epithelial debridement with topical anesthetics and a blade or cotton swab removes devitalized corneal tissue and dead hyphae in superficial forms of equine keratomycosis,<sup>16</sup> and can accompany medical therapy or precede more invasive surgeries to improve antifungal drug penetration. This modification of a superficial keratectomy can be realized with a cotton-tipped applicator, spatulas, scalpels, forceps,<sup>29</sup> and/or a diamond burr.<sup>47</sup> Debridement should be continued until only firmly adhered epithelium at the edge of the fungal lesion remains.<sup>29</sup> Fungal removal by debridement speeds healing, minimizes scarring, and decreases the stimulus for iridocyclitis.<sup>16</sup> Debridement is not suitable for deeper lesions.

## Amniotic membrane transplantation

Amniotic membrane can be used successfully to preserve globe structure and vision in horses with equine keratomycosis and mild or severe keratomalacia,<sup>48</sup> and has replaced the use of large diameter 180 degree or 360 degree conjunctival flaps.<sup>27</sup> The amnion tissue is harvested from normal equine placenta but is not yet available commercially.<sup>41</sup> This biomaterial acts as a self-sacrificing dressing because it attracts proteases and microbes that could attack the cornea, and allows the cornea to heal. It is believed that the amnion provides proteins like lumican and dermatopontin to speed corneal healing

**Table 1** Clinical signs from equine keratomycosis and their respective treatment

Clinical appearance	Treatment
Tear film instability/ microlesions	Topical antibiotics, serum, atropine, antifungals; systemic flunixin meglumine; fly masks
Epithelial keratopathy	Topical antibiotics, serum, atropine, antifungals; systemic flunixin meglumine; fly masks
Subepithelial infiltrates	Topical antibiotics, serum, atropine, antifungals; systemic flunixin meglumine; fly masks
Superficial ulcers	Topical antifungals, antibiotics, serum and/or ethylenediamine tetra-acetic acid, atropine; systemic flunixin meglumine; protective hood
Deep ulcers	Conjunctival pedicle graft after debridement or use of grafts; partial temporary tarsorrhaphy; clinical treatment as described; protective hood
Plaques	Excision of the plaque and underlying superficial stroma; keratoplasty (corneal conjunctival or amnion graft); partial temporary tarsorrhaphy clinical treatment as described; protective hood
Melting ulcers	Keratotomy and deep anterior lamellar keratoplasty; partial temporary tarsorrhaphy; clinical treatment as described; protective hood
Descemetocoeles	Keratotomy and replacement with cornea (deep anterior lamellar keratoplasty) or Biosist™ in combination with amnion or conjunctival graft; partial temporary tarsorrhaphy; clinical treatment as described; protective hood
Iris prolapse	Excision of iris tissue necrotic or contaminated; penetrating keratoplasty with conjunctival graft; partial temporary tarsorrhaphy; clinical treatment as described
Stromal abscess	Posterior lamellar keratoplasty for deep stromal abscess in the axial cornea or deep endothelial lamellar keratoplasty for limbal deep stromal abscess; partial temporary tarsorrhaphy; clinical treatment as described; protective hood
Failure of treatment	Enucleation

**Note:** The clinical therapy is generally similar, but the interval between instillations is reduced when the clinical manifestation becomes worse.

in the horse.<sup>49</sup> Lumican modulates cellular behavior like proliferation and migration,<sup>50</sup> and dermatopontin induces fibroblast cell adhesion.<sup>51</sup> We have utilized amnion grafts at the University of Florida combined with penetrating and lamellar keratoplasty in horses with encouraging results. Amniotic membrane can also be used alone, in single or multiple layers, and in combination with conjunctival grafts.<sup>16,27</sup>

Placed over deep melting ulcers or over penetrating keratoplasty sites, amniotic membrane can reduce vascularization and preserve corneal or graft transparency.<sup>16</sup>

However, amniotic membrane does not supply the cornea with important vascular-derived factors that are helpful in corneal healing as does the conjunctival graft.<sup>42</sup>

## Conjunctival grafts

Pedicle conjunctival grafts are frequently used for treatment of deep, melting, and large diameter corneal ulcers, descemetoceles, and perforated corneal ulcers with iris prolapse.<sup>14,27</sup> They contain blood vessels and lymphatics thus offering antibacterial, antifungal, antiviral, antiprotease, and anticollagenase effects.<sup>14,42</sup> When harvested from the limbal area, the transplanted conjunctival epithelium contains stem cells capable of producing corneal epithelium.<sup>41</sup> Conjunctival grafts also provide mechanical support for a thin or weakened cornea,<sup>27</sup> and a route for systemic antibiotic to be delivered to the corneal ulcer.<sup>52</sup> Conjunctival grafts are used in conjunction with primary repair or penetrating keratoplasty in cases of iris prolapse or large diameter full thickness stromal abscesses.<sup>29,42</sup> Three to 8 weeks after placement of the graft, the blood supply should be interrupted, cutting its base from the limbus.<sup>29</sup>

## Penetrating and lamellar keratoplasties

Corneal transplantation for treatment of severe inflammatory keratopathies in horses with corneal fungal infection and melting has been used successfully at the University of Florida since 1993.<sup>28</sup> Penetrating keratoplasty is a full thickness microsurgical transplantation of the corneal epithelium, stroma, and Descemet's membrane/endothelium.<sup>28,53,54</sup> Penetrating keratoplasty is performed in horses for therapeutic and tectonic reasons in melting and fungal ulcers with extensive stromal loss, iris prolapse/descemetoceles, and full thickness stromal abscesses. It is a viable, routine surgical technique in horses with severe fungal keratitis,<sup>28</sup> and has a very good visual outcome,<sup>27,28,53</sup> although the penetrating keratoplasty site remains opaque to some degree due to graft rejection.<sup>53</sup> Frozen donor cornea up to 13 mm in diameter can be sutured in place with 7-0 to 8-0 sutures to replace diseased or missing cornea.

Lamellar keratoplasties, such as deep endothelial lamellar keratoplasty and posterior lamellar keratoplasty, remove only the diseased portion of the cornea leaving the healthy corneal layers of the cornea intact. However, they are now the preferred method for focal corneal fungal disease such as deep stromal abscesses in horses, because they offer improved

visual outcomes and more rapid healing when compared with penetrating keratoplasty.<sup>22,27,30,53,55,56</sup> The deep anterior lamellar keratoplasty is another type of lamellar keratoplasty to replace the epithelium and stroma in melting ulcers when Descemet's membrane is intact in the horse.

Posterior lamellar keratoplasty is indicated for deep stromal abscesses with a clear or slightly vascular overlying anterior stroma in the axial cornea.<sup>28,30,53</sup> A deep lamellar endothelial keratoplasty has been used for limbal deep stromal abscesses in horses where the superficial cornea may be vascularized but is otherwise normal.<sup>28,53</sup> Exposure of the abscess is accomplished by dissection of the cornea to the depth of the lesion, removal of the abscess with a corneal trephine, replacement and suturing of the split thickness donor corneal graft into the surgical site, and then surgical replacement of the overlying remaining normal corneal layers. The anterior chamber can be reformed with sodium hyaluronate, air, or lactate Ringer's solution.

Deep anterior lamellar keratoplasty is a surgical technique to remove the entire corneal stroma down to bare normal Descemet's membrane and endothelium,<sup>57</sup> and is indicated in horses with rapidly progressive, large diameter, catastrophic, and melting corneal ulcers with and without exposure of Descemet's membrane.<sup>53</sup> Dissection and removal of superficial to deep layers of necrotic cornea is followed by suturing of donor corneal epithelium and anterior stroma over the surgical lesion.

Surgical lamellar and penetrating keratoplasties can also be used with biologic membranes like amniotic membrane and small intestinal porcine submucosa. The small intestinal submucosa graft provides a scaffold for corneal healing as well as additional strength to the overlying bulbar conjunctival graft. Grafts can be used to replace the missing stromal and epithelial cells.<sup>41</sup>

### Third eyelid flaps and tarsorrhaphy

A temporary tarsorrhaphy is recommended after most equine corneal surgery, such as amnion and conjunctival grafts, penetrating keratoplasty, deep endothelial lamellar keratoplasty, deep anterior lamellar keratoplasty, and posterior lamellar keratoplasty. It minimizes to the cornea surface<sup>27,28</sup> and improves graft adherence.<sup>42</sup> Third eyelid flaps can provide physical support to weakened corneas but are not indicated in most cases of deep equine keratomycosis.<sup>20</sup> In the postoperative period, use of a protective hood with a plastic eyecup is important to minimize rubbing of the eye. Horses with surgical treatment of equine keratomycosis should be evaluated daily to confirm that there are no complications.<sup>42</sup>

## Therapeutic management of keratomycotic lesions (Table 1)

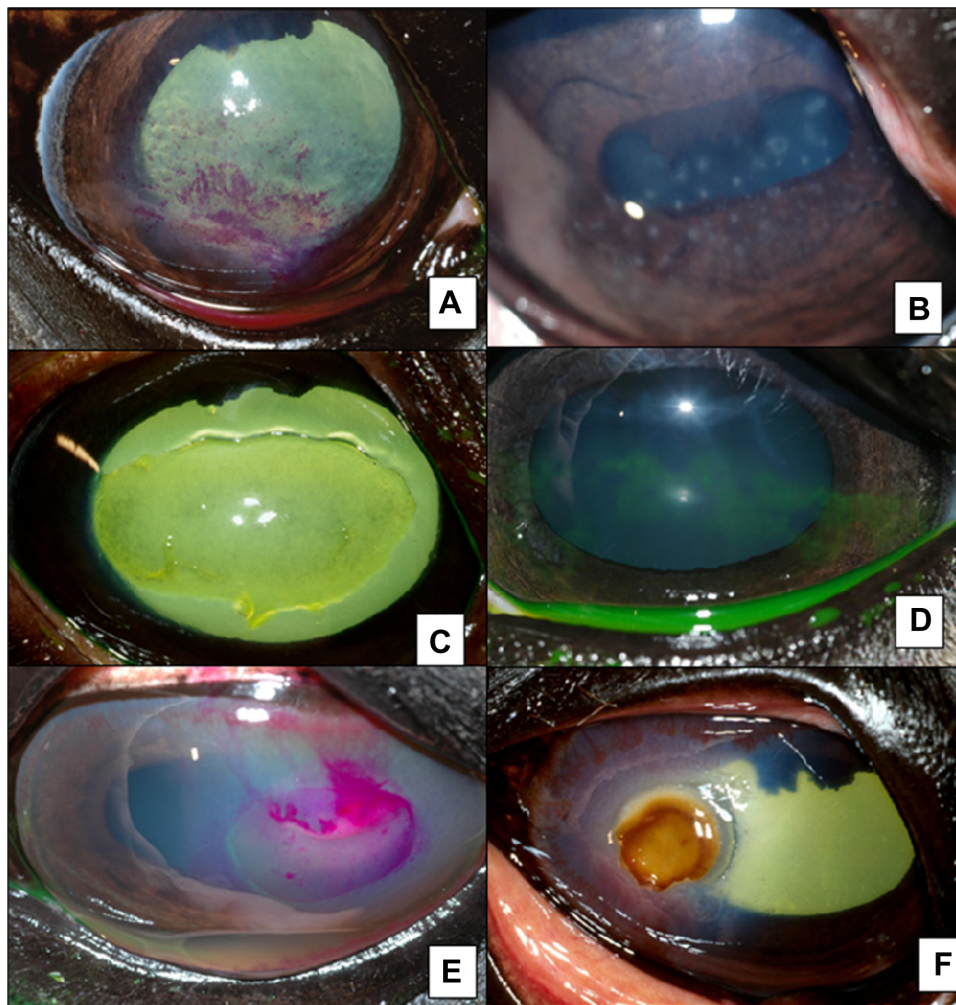
### Tear film instability with and without microlesions

Horses with fungal-induced tear film instability display generalized and/or punctate haziness of the cornea. The lesions are rose Bengal-positive (Figure 1A) and may represent a form of qualitative keratoconjunctivitis sicca. Rose Bengal retention is also found with quantitative keratoconjunctivitis sicca, viral keratitis, corneal edema, and severe corneal scarring in the horse.<sup>16</sup> *Aspergillus* is the most common cause of this in our experience.

Horses with ocular pain, a dry or hazy appearance to the cornea in a multifocal, punctate, or generalized pattern, and no uveitis, should be stained with rose Bengal and fluorescein stains. Keratomycosis, viral keratitis, keratoconjunctivitis sicca, immune-mediated keratitis, and conditions caused by environmental air pollution should be considered in the differential diagnosis. Superficial epithelial lesions of the cornea can be divided into microerosions, microcysts, and keratopathies. Epithelial and subepithelial lesions require a biomicroscopic lamp for differentiation. Punctate epithelial microerosions are fine lesions that stain with rose Bengal and stain faintly with fluorescein.<sup>8</sup> They appear in areas of cornea in which there has been partial thickness loss of normal surface epithelial cells with exposure of underlying immature corneal epithelial cells, appearance of punctate microcysts in areas of epithelial healing with recurrent erosions, and cystic spaces in edematous corneal epithelium.<sup>2,8</sup> Rose Bengal is able to stain epithelial cells and keratin, exposed stroma, and degenerative epithelial cells only when there is a generalized deficiency of the mucin layer of the precorneal tear film.<sup>8,14</sup> Hyphae can be obtained from corneal scrapings and fungi cultured from the scraping site in fungal-induced microerosions.<sup>16</sup> Medical therapy should include topical antibiotics, serum, atropine, and antifungals, and systemic flunixin meglumine.<sup>8,14</sup> Fly masks are recommended to reduce tear film evaporation. This form of keratomycosis can progress to the ulcerative form of keratomycosis, but generally has a favorable prognosis.<sup>58</sup>

### Epithelial keratopathy

Fungi can invade the epithelium to cause a very fine punctate or generalized haze. The diagnosis of epithelial keratomycosis is made with negative rose Bengal staining, negative or weak fluorescein staining, epithelial opacities from slit-lamp examination, and cytologic evidence of hyphae,



**Figure 1** Clinical appearance of different forms of equine keratomycosis. (A) Rose Bengal-positive epithelial microerosions. (B) Subepithelial keratomycosis with microerosions. (C) Superficial ulcerative keratitis fluorescein stained. (D) Superficial keratomycosis fluorescein weakly positive. (E) Superficial ulcerative keratitis rose Bengal-positive showing tear film instability. (F) Superficial fungal plaque; note the brownish color, corneal edema, and neovascularization.

fungal culture, and positive resolution of the condition with antifungal medication. Medical therapy should include topical antibiotics, serum, and antifungals, and systemic flunixin meglumine. Fly masks are recommended to reduce tear film evaporation. This form of keratomycosis can progress to the subepithelial form of keratomycosis, and generally has a favorable prognosis once diagnosed and treated.<sup>8</sup> We suspect that this type and the subepithelial form of eosinophilic keratoconjunctivitis are common to horses in any geographic region. Horses with epithelial keratomycosis and subepithelial infiltrates have been reported anecdotally in the US, UK, Japan, France, Germany, Canada, Denmark, and Finland.

### Subepithelial infiltrates

Subepithelial infiltrates can be caused by fungi, lymphocytes, neutrophils, or fibroblasts. Diagnosis of this condition requires the slit-lamp biomicroscope for localization.<sup>8</sup>

Fungi have been identified from subepithelial punctate opacities (Figure 1B) which retain neither fluorescein nor rose Bengal stains prior to scraping for cytology.<sup>2,16</sup> Treatment is the same as described for epithelial form. We feel that equine subepithelial infiltrates represent a quite common and distinct keratopathy in the horse, and that many horses with equine subepithelial keratomycosis are able to resolve the condition spontaneously. Equine subepithelial keratomycosis may be more prevalent in temperate climates than the ulcerative forms noted in subtropical environments. We also suggest that equine subepithelial keratomycosis may be a preliminary event in the formation of corneal ulcers in some horses, and deep stromal abscesses in other horses.

### Superficial ulcers

Superficial fungal ulcers arise from loss of the cornea epithelium and stain positively for fluorescein (Figure 1C–E).<sup>16</sup>

Due to the lack of epithelium, the cornea becomes more susceptible to opportunistic infections. Ulcers also result in increased tear film matrix metalloproteinase activity, and there is some degree of iridocyclitis.<sup>14,16,43</sup> Medical therapy for a superficial fungal ulcer should include systemic flunixin meglumine, and topical antifungals, antibiotics, serum and/or ethylenediamine tetra-acetic acid, and atropine.<sup>7</sup> The frequency is determined by the severity of the condition.<sup>52</sup>

## Deep ulcers

The loss of more than the initial third of the stroma is considered a deep ulcer.<sup>14</sup> Some deep ulcers can heal with medical therapy alone, but deep ulcers and descemetocelles that are rapidly progressive with increasing signs of uveitis, and areas of marked stromal melting, stromal loss or marked cellular infiltrate are considered complicated, likely infected, and require surgical intervention.<sup>52</sup> Rupture may be imminent.<sup>42</sup> Surgical therapy for a deep fungal ulcer could be a conjunctival pedicle graft after debridement of the corneal lesion, penetrating keratoplasty, deep anterior lamellar keratoplasty, or use of biomaterial grafts such as amnion or Biosist™ to help the weakened cornea and prevent its rupture.<sup>41</sup> Medical therapy for deep ulcers remains aggressive, and should include systemic flunixin meglumine, as well as topical therapy of antifungals, antibiotics, serum and ethylenediamine tetra-acetic acid, and atropine.<sup>8</sup> The frequency should be increased to every hour in complicated and progressive cases.

## Plaques

A dense, dark-colored plaque elevated off the corneal surface can be caused by fungal invasion of the cornea epithelium and stroma. The plaques appear film-like and/or fluffy in the early stages, and are typically discolored (Figures 1F and 2A). The lesions begin as a small opacity, but can enlarge rapidly and occupy more than half of the corneal surface. The specific reason for this fungal plaque and abscess formation is unknown. The presence of a deep stromal excavation (furrow) bordering the plaque is considered a serious development.<sup>2,59</sup> The furrow precedes corneal vascularization, can progress rapidly over 24–48 hours, causes pain, and can lead to corneal rupture; like other forms of ulcerative keratomycosis in horses, corneas with fungal plaques heal very slowly.<sup>2</sup> In most cases of fungal plaques, removal by keratectomy speeds healing time.<sup>2,16</sup> Fungal plaques can benefit from excision of the plaque and underlying superficial stroma, and a keratoplasty with placement of a corneal conjunctival or amnion graft.<sup>42</sup> Medical therapy should include systemic flunixin meglumine,

as well as topical antifungals, antibiotics, serum and ethylenediamine tetra-acetic acid, and atropine.<sup>8</sup>

## Melting ulcers

Stromal malacia or melting occurs as a result of collagenolysis due to protease liberation from invading neutrophils, microorganisms, and corneal epithelial cells or keratocytes (Figure 2B and C). The result is loss of rigidity and structure of the corneal collagen with development of a deep ulcer or descemetocoele.<sup>52</sup> Standard treatment for melting fungal ulcers includes topical antifungals and antibiotics, serum and ethylenediamine tetra-acetic acid, atropine, as well as systemic flunixin meglumine.<sup>21</sup> It is imperative and often difficult to control collagenolysis medically.

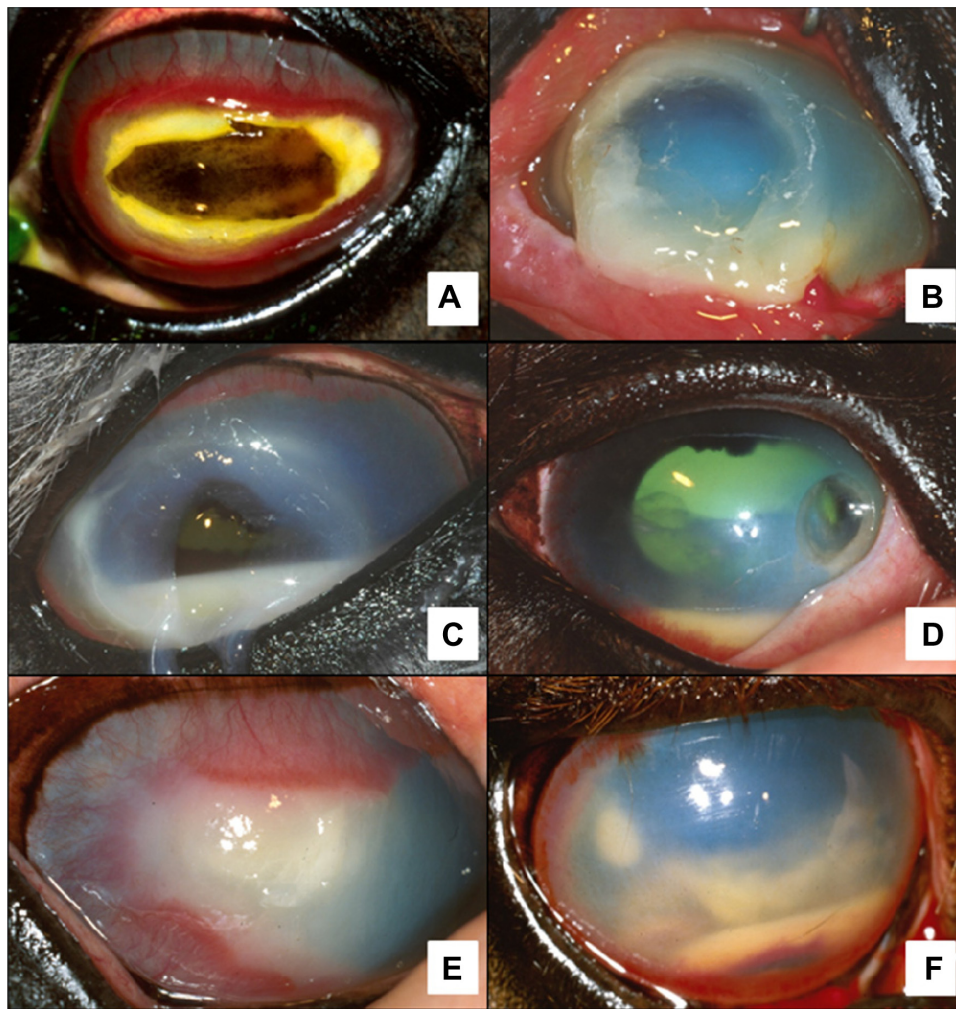
Keratectomy and deep anterior lamellar keratoplasty may be indicated to speed healing by removing infected and necrotic tissue, encouraging vascularization, minimizing scarring, and decreasing the stimulus for anterior uveitis.<sup>41</sup> A conjunctival or amnion graft can restore the anterior cornea,<sup>14</sup> and a temporary partial tarsorrhaphy avoids additional trauma to the cornea.<sup>41</sup> In melting ulcers, tear film protease/collagenase activity can digest absorbable sutures or the graft itself, resulting in possible corneal perforation such that antiprotease therapy should be rigorously maintained postoperatively.<sup>42</sup>

## Descemetocoeles

A descemetocoele is a deep corneal lesion in which the corneal epithelium and stroma are completely destroyed, leaving a corneal lesion lined only by Descemet's membrane and corneal endothelium (Figure 2D). Once this barrier is breached, a full thickness corneal perforation occurs, the aqueous humor is lost, and the iris can prolapse.<sup>29</sup> Descemetocoele and iris prolapse can be a result of keratomalacia,<sup>52</sup> in which collagenolysis is not controlled.<sup>42</sup> It is not uncommon for stromal melting to progress rapidly to full-thickness corneal perforation within 48 hours in the most severe cases.<sup>2</sup> Because of the fragile nature of descemetocoeles, as well as the potential for intraocular inflammatory damage with perforation, descemetocoele repairs should be considered as an emergency. Vision should always be assessed or attempted to determine the likely visual outcome. Evaluation of the consensual pupillary light reflex (if possible) and dazzle reflex may provide some information on visual capability, and ocular ultrasonography can also be used to assess the posterior segment.<sup>29</sup>

Medical therapy should include systemic flunixin meglumine, and topical antifungals, antibiotics, serum and ethylenediamine tetra-acetic acid, and atropine.<sup>8</sup> Surgical





**Figure 2** Clinical appearance of equine keratomycosis. (A) Necrotic fungal plaque and intense corneal perlimbal vascularization. (B) Corneal melting and cellular infiltration. (C) Corneal melting and hypopyon into the anterior chamber. (D) Descemetocoele, perlimbal neovascularization, hypopyon, and fibrin into the anterior chamber. (E) Deep stromal abscess in the axial cornea and intense corneal edema and vascularization. (F) Deep stromal abscess at 10 o'clock with intense perlimbal vascularization and hypopyon, fibrin, and hyphema in the anterior chamber.

treatment of descemetocoeles consists of keratectomy to remove the necrotic and infected tissue,<sup>16</sup> and replacement of the missing cornea with cornea (deep anterior lamellar keratoplasty), or replacement with collagen from Biosist or Acell™ in combination with an amnion or conjunctival graft<sup>16,28</sup> and partial temporary tarsorrhaphy.<sup>46</sup> Sometimes, conjunctival grafts alone result in continuing leakage of aqueous humor through a corneal perforation, and the use of cornea or another tissue can provide the best results.<sup>29</sup>

### Iris prolapse

In keratomycosis, an iris prolapse can result from progression of ulcerative keratitis, or rupture from a stromal abscess.<sup>1</sup> The prognosis is guarded for ocular survival and vision if surgery is not attempted. Surgical management requires corneal repair and stabilization. Prolapsed iris

tissue that appears desiccated, necrotic or contaminated, or that has been prolapsed from more than 24 hours, should be excised rather than replaced in the anterior chamber. It is important to perform a keratectomy on the margins of the corneal defect to debride the devitalized and infected tissue. A penetrating keratoplasty with conjunctival graft can then be placed.<sup>42</sup> Vision can be achieved in up to 68% of eyes with iris prolapse using a technique of penetrating keratoplasty/conjunctival flap.<sup>60</sup> Medical therapy should include systemic flunixin meglumine, and topical antifungals, antibiotics, serum and ethylenediamine tetra-acetic acid, and atropine.<sup>8</sup>

### Stromal abscess

Fungal tropism for glycosaminoglycans has been suggested, based on the fact that hyphae are often found sequestered

in the posterior stroma near and/or infiltrating Descemet's membrane where glycosaminoglycans exist in abundance. Stromal abscesses vary widely in size, location in the cornea, border clarity, and stromal depth. Superficial stromal abscesses can be bacterial or fungal in origin, whereas deep stromal abscesses (Figure 2E and F) are thought to be more likely fungal in origin, and are thus often refractory to medical treatment compared with more superficial abscesses. The corneal epithelium may or may not be defective in the presence of a stromal abscess.<sup>2</sup>

Deep stromal abscesses are generally refractory to medical management due to poor penetration of medications, and the inability of the cornea to remove dead fungal hyphae.<sup>2,42</sup> Penetrating keratoplasty is the treatment of choice for a full thickness corneal stromal abscess. The most effective surgical treatment for a deep stromal abscess is penetrating keratoplasty or deep endothelial lamellar keratoplasty because it removes infectious organisms, necrotic stroma, and metabolites of degenerating leukocytes, while preserving the overlying stroma and epithelium.<sup>42</sup> Penetrating keratoplasty is indicated for deep stromal abscess in the axial cornea and deep endothelial lamellar keratoplasty has been used for limbal deep stromal abscess.<sup>28,53</sup> Our success rate using these procedures approaches 90%.<sup>28</sup> If the donor button exceeds 8 mm in diameter, a pedicle conjunctival graft is also indicated over the surgical site because it provides physical support, reduces formation of microleaks, and accelerates healing.<sup>42</sup>

## Disclosure

The authors report no conflicts of interest in this work.

## References

- Andrew SE, Nguyen A, Jones GL, Brooks DE. Seasonal effects on the aerobic bacterial and fungal conjunctival flora of normal thoroughbred brood mares in Florida. *Vet Ophthalmol*. 2003;6:45–50.
- Scotty NC. Equine keratomycosis. *Clin Tech Equine Pract*. 2005;4:29–36.
- Clode AB. Diseases and surgery of the cornea. In: Gilger BC, editor. *Equine Ophthalmology*. 2nd ed. Maryland Heights, MO: Elsevier Saunders; 2011.
- Johns IC, Baxter K, Booter H, Hicks C, Menzies-Gow N. Conjunctival bacterial and fungal flora in healthy horses in UK. *Vet Ophthalmol*. 2011;14:195–199.
- Galán A, Martín-Suárez EM, Gallardo JM, Molleda M. Clinical findings and progression of 10 cases of equine ulcerative keratomycosis (2004–2007). *Equine Vet Educ*. 2009;21(5):236–242.
- Brooks DE, Andrew SE, Dillavou CL, Ellis G, Kubilis PS. Antimicrobial susceptibility patterns of fungi isolated from horses with ulcerative keratomycosis. *Am J Vet Res*. 1998;59:138–142.
- Andrew SE, Brooks DE, Smith PJ, Gelatt KN, Chmielewski NT, Whittaker CJ. Equine ulcerative keratomycosis: visual outcome and ocular survival in 39 cases (1987–1996). *Equine Vet J*. 1998;30:109–116.
- Brooks DE, Andrew SE, Denis HM, et al. Rose Bengal positive epithelial microerosions as a manifestation of equine keratomycosis. *Vet Ophthalmol*. 2000;3:83–86.
- Pearce JW, Giuliano EA, Moore CP. In vitro susceptibility patterns of *Aspergillus* and *Fusarium* species isolated from equine ulcerative keratomycosis cases in the midwestern and southern United States with inclusion of the new antifungal agent voriconazole. *Vet Ophthalmol*. 2009;12:318–324.
- Mathes RL, Reber AJ, Hurley DJ, Dietrich UM. Effects of antifungal drugs and delivery vehicles on morphology and proliferation of equine corneal keratocytes in vitro. *Am J Vet Res*. 2010;71:953–959.
- Mann SS, Singh J, Kalra D, Parihar JKS, Gupta N, Kumar P. Medical and surgical management of keratomycosis. *Armed Forces Med J India*. 2008;64:40–42.
- Mahdy RA, Nada WM, Wageh MM. Topical amphotericin B and subconjunctival injection of fluconazole (combination therapy) versus topical amphotericin B (monotherapy) in treatment of keratomycosis. *J Ocul Pharmacol Ther*. 2010;26:281–285.
- Ledbetter EC, Patten VH, Scarlett JM, Vermeylen FM. In vitro susceptibility patterns of fungi associated with keratomycosis in horses of the northeastern United States: 68 cases (1987–2006). *J Am Vet Med Assoc*. 2007;231:1086–1091.
- Brooks DE, Matthews AG. Equine ophthalmology. In: Gelatt KN, editor. *Vet Ophthalmol*. 4th ed. Ames, IA: Blackwell Publishing; 2007.
- Ford MM. Antifungals and their use in veterinary ophthalmology. *Vet Clin North Am Small Anim Pract*. 2004;34:669–691.
- Brooks DE, editor. *Ophthalmology for the Equine Practitioner*. 2nd ed. Jackson, WY: Teton Newmedia; 2008.
- Blomme E, Del-Piero F, La-Perle KMD, Wilkins PA. Aspergillosis in horses: a review. *Equine Vet Educ*. 1998;10(2):86–93.
- Wu TG, Wilhelmus KR, Mitchell BM. Experimental keratomycosis in a mouse model. *Invest Ophthalmol Vis Sci*. 2003;44:210–216.
- Wada S, Ode H, Hobo S, Niwa H, Katayama Y, Takatori K. *Mortierella wolffii* keratomycosis in a horse. *Vet Ophthalmol*. 2011;14:267–270.
- Brooks DE. Equine ophthalmology. In: Gelatt KN, editor. *Veterinary Ophthalmology*. 3rd ed. Philadelphia, PA: Lippincott Williams & Wilkins; 1999.
- Utter ME, Wotman KL. Nonulcerative bullous keratitis associated with *Pseudomonas alcaligenes* infection in a thoroughbred mare. *Equine Vet Educ*. 2009;21:590–595.
- Plummer CE, Kallberg ME, Ollivier FJ, Barrie KP, Brooks DE. Deep lamellar endothelial keratoplasty in 10 horses. *Vet Ophthalmol*. 2008; 11 Suppl 1:35–43.
- Matsumoto Y, Dogru M, Sato EA, et al. The application of in vivo confocal scanning laser microscopy in the management of *Acanthamoeba* keratitis. *Mol Vis*. 2007;13:1319–1326.
- Ledbetter EC, Irby NL, Kim SG. In vivo confocal microscopy of equine fungal keratitis. *Vet Ophthalmol*. 2011;14:1–9.
- Kojima T, Matsumoto Y, Dogru M, Tsubota K. The application of in vivo laser scanning confocal microscopy as a tool of conjunctival in vivo cytology in the diagnosis of dry eye ocular surface disease. *Mol Vis*. 2010;16:2457–2464.
- Hau SC, Dart JKG, Vesaluoma M, et al. Diagnostic accuracy of microbial keratitis with in vivo scanning laser confocal microscopy. *Br J Ophthalmol*. 2010;94:982–987.
- Brooks DE. Complications of ophthalmic surgery in the horse. *Vet Clin Equine*. 2009;24:697–734.
- Brooks DE, Plummer CE, Kalberg ME, et al. Corneal transplantation for inflammatory keratopathies in the horse: Visual outcome in 206 cases (1993–2007). *Vet Ophthalmol*. 2008;11:123–133.
- Gilger BC. Diseases and surgery of the canine cornea and sclera. In: Gelatt KN, editor. *Veterinary Ophthalmology*. Ames, IA: Blackwell Publishing; 2007.
- Brooks DE. Targeted lamellar keratoplasty in the horse: a paradigm shift in equine corneal transplantation. *Equine Vet J*. 2010;Suppl 37: 24–30.

31. Clode AB. Therapy of equine infectious keratitis: a review. *Equine Vet J*. 2010;Suppl 37:19–23.
32. Boveland SD, Moore PA, Mysore J, et al. Immunohistochemical study of matrix metalloproteinases-2 and -9, macrophage inflammatory protein-2 and tissue inhibitors of matrix metalloproteinases-1 and -2 in normal, purulonecrotic and fungal infected equine corneas. *Vet Ophthalmol*. 2010;13:81–90.
33. Matthews AG. Ophthalmic antimicrobial therapy in the horse. *Equine Vet Educ*. 2009;21(5):271–280.
34. Clode A, Davis J, Davidson G, Salmon J, Lafevers H, Gilger B. Aqueous humor and plasma concentrations of a compounded 0.2% solution of terbinafine following topical ocular administration to normal equine eyes. *Vet Ophthalmol*. 2011;14:41–47.
35. Betbeze CM, Wu CC, Khron SG, Stiles J. In vitro fungistatic and fungicidal activities of silver sulfadiazine and natamycin on pathogenic fungi isolated from horses with keratomycosis. *Am J Vet Res*. 2006;67:1788–1793.
36. O'Day DM, Ray WA, Head WS, Robinson RD. Influence of the corneal epithelium on the efficacy of topical antifungal agents. *Invest Ophthalmol Vis Sci*. 1984;25:855–859.
37. Utter ME, Wotman KL, Armour M, Bagel J. Clinical findings and outcomes of ulcerative keratomycosis in 30 horses in the mid-Atlantic United States (2006–2007). *Equine Vet Educ*. 2010;22(1):31–39.
38. Clode AB, Davis JL, Salmon J, Michau TM, Gilger BC. Evaluation of concentration of voriconazole in aqueous humor after topical and oral administration in horses. *Am J Vet Res*. 2006;67:296–301.
39. Gilmour MA. Subconjunctival voriconazole for the treatment of mycotic keratitis in a horse. *Equine Vet Educ*. 2011. [Epub ahead of print.]
40. Andrew SE. Corneal fungal disease in small animals. *Clin Tech Small Anim Pract*. 2003;18:186–192.
41. Gelatt KN, Brooks DE. Surgery of the cornea and sclera. In: Gelatt KN, Gelatt JP, editors. *Veterinary Ophthalmic Surgery*. Maryland Heights, MO: Saunders Elsevier; 2011.
42. Denis HM. Equine corneal surgery and transplantation. *Vet Clin North Am Equine Pract*. 2004;20:361–380.
43. Ollivier FJ, Brooks DE, Van-Setten GB, et al. Profiles of matrix metalloproteinase activity in equine tear fluid during corneal healing in 10 horses with ulcerative keratitis. *Vet Ophthalmol*. 2004;7:397–405.
44. Ollivier FJ, Gilger BC, Barrie KP, et al. Proteinases of the cornea and preocular tear film. *Vet Ophthalmol*. 2007;10:199–206.
45. Hartwig D, Herminghaus P, Wedel T, et al. Topical treatment of ocular surface defects: comparison of the epitheliotropic capacity of fresh frozen plasma and serum on corneal epithelial cells in an in vitro cell culture model. *Transfus Med*. 2005;15:107–113.
46. Ollivier FJ, Brooks DE, Kallberg ME, et al. Evaluation of various compounds to inhibit activity of matrix metalloproteinases in the tear film of horses with ulcerative keratitis. *Am J Vet Res*. 2003;64:1081–1087.
47. Silva EG, Powell CC, Gionfriddo JR, Ehrhart EJ, Hill AE. Histologic evaluation of the immediate effects of diamond burr debridement in experimental superficial corneal wounds in dogs. *Vet Ophthalmol*. 2011;14:285–291.
48. Lassaline ME, Brooks DE, Ollivier FJ, Komaromy AM, Kallberg ME, Gelatt KN. Equine amniotic membrane transplantation for corneal ulceration and keratomalacia in three horses. *Vet Ophthalmol*. 2005;8(5): 311–317.
49. Galera PD, Coleman J, Sapp H, Plummer C, Brooks DE. Proteome from frozen equine amnion. *Vet Ophthalmol*. 2011;15(1):1.
50. Iozzo RV. The biology of the small leucine-rich proteoglycans: functional network of interactive proteins. *J Biol Chem*. 1999;274: 18843–18846.
51. Takeda U, Utani A, Wu J, et al. Targeted disruption of dermatopontin causes abnormal collagen fibrillogenesis. *J Invest Dermatol*. 2002;119:678–683.
52. Maggs DJ. Cornea and sclera. In: Maggs DJ, Miller PE, Ofri R, editors. *Slatter's Fundamentals of Veterinary Ophthalmology*. St Louis, MO: Saunders Elsevier; 2008.
53. Brooks DE. Equine keratomycosis: An international problem. *Equine Vet Educ*. 2010;21:243–246.
54. Brooks DE. Penetrating keratoplasty, deep lamellar endothelial keratoplasty, and posterior lamellar keratoplasty in the horse. *Clinical Techniques in Equine Practice*. 2005;4(1):37–49.
55. Andrew SE, Brooks DE, Biros DJ, Denis HM, Cutler TJ, Gelatt KN. Posterior lamellar keratoplasty for treatment of deep stromal abscesses in nine horses. *Vet Ophthalmol*. 2000;3:99–103.
56. Tan DT, Metha JS. Future directions in lamellar corneal transplantation. *Cornea*. 2007;26(9 Suppl 1):S21–S28.
57. Martins BC, Laus JL, Barrie KP, Plummer CE, Brooks DE. Ex-vivo DALK in porcine eyes. *Vet Ophthalmol*. 2011;14:406–422.
58. Sansom J, Featherstone H, Barnett KC. Keratomycosis in six horses in the United Kingdom. *Vet Rec*. 2005;156:13–17.
59. Gaarder JE, Rebhun WC, Ball MA, et al. Clinical appearances, healing patterns, risk factors, and outcomes of horses with fungal keratitis: 53 cases (1978–1996). *J Am Vet Med Assoc*. 1998;213:105–112.
60. Henriksen MM, Barrie KP, Plummer CE, Ben-Shlomo G, Tsujita H, Brooks DE. Visual outcome utilizing corneal transplantation for iris prolapse in the horse: 1998–2010. *Vet Ophthalmol*. 2010;13:407–423.

## Veterinary Medicine: Research and Reports

### Publish your work in this journal

Veterinary Medicine: Research and Reports is an international, peer-reviewed, open access journal publishing original research, case reports, editorials, reviews and commentaries on all areas of veterinary medicine. The manuscript management system is completely online and includes a very quick and fair peer-review system.

Submit your manuscript here: <http://www.dovepress.com/veterinary-medicine-research-and-reports-journal>

Dovepress

Visit <http://www.dovepress.com/testimonials.php> to read real quotes from published authors.