

Medial blepharosynechioplasty: a new surgical concept for severe dry eye

Tsugihisa Sasaki^{1,2}

Taeko Ota³

Youko Ookura⁴

Kazuhisa Sugiyama¹

¹Department of Ophthalmology, Kanazawa University School of Medicine, Kanazawa, Ishikawa;

²Department of Ophthalmology, Fukui Prefectural Hospital, Fukui;

³Department of Ophthalmology, Tonami General Hospital, Tonami-city, Toyama; ⁴Department of Ophthalmology, Saiseikai Kanazawa Hospital, Kanazawa, Ishikawa, Japan

Background: The purpose of this work was to report on the performance of medial blepharosynechioplasty (MBSP), a newly devised technique for treating severe dry eye.

Methods: In this retrospective, nonrandomized clinical trial, three cases with severe dry eye (Sjögren's syndrome) associated with repeated punctal plug loss were treated using MBSP to create a synechia between the upper and lower lid medial borders of the puncta to suppress the lacrimal pump.

Results: Postoperative follow-up showed improvement in the corneal condition in all three cases that persisted for 12–35 months. None of the patients had visual impairment.

Conclusion: MBSP is a promising treatment for severe dry eye and merits further study.

Keywords: dry eye, lacrimal pump suppression, medial blepharosynechioplasty

Introduction

Although punctal plug and occlusion of the lacrimal puncta is an established treatment for dry eye,^{1–3} the risk of complications, including epiphora, intrusion or extrusion of punctal plugs, canalicular stenosis,^{1,4} and inadequate results in cases of monopunctal closure, have frustrated surgeons when performing surgery involving permanent closure of the puncta. Development of alternative surgical methods to suppress the lacrimal pump and tear evaporation with fewer complications would represent a valuable advance in producing a milder effect than upper and lower punctal plugging.

We encountered three patients after dacryocystorhinostomy, who developed blepharosynechia bordering the punctum characterized by epiphora, although the lacrimal ducts remained patent. Epiphora improved after excision of their blepharosynechia. These observations suggested that blepharosynechia-induced epiphora was caused by suppression of the lacrimal pump, which in turn led to us devising medial blepharosynechioplasty (MBSP) as a novel treatment for dry eye.

Methods

The study protocol and data collection methods were approved by the institutional review board of Fukui Prefectural Hospital. This study reports on three patients suffering from repeated punctal plug loss.

Surgical procedure

The infratrochlear nerve was anesthetized using an injection of a mixture of 0.01% epinephrine and 2% lidocaine. Two strips of tissue from the palpebral conjunctiva,

Correspondence: Tsugihisa Sasaki
Sasaki Eye Clinic, 5-2-6 Mikuni-higashi,
Mikuni, Sakai, 913-0016, Japan
Tel +817 7688 0033
Fax +817 7688 0233
Email sasatsug@gmail.com

each measuring $2 \times 3 \times 0.5$ mm, were excised from the medial side of the upper and lower puncta to facilitate formation of a synechia (Figure 1). Eyelid tissues in the immediate vicinity of the puncta were sewn together with 7-0 nylon in conjunction with insertion of a lacrimal probe into the canaliculus to

prevent damage to it. Antibiotic ophthalmic drops and 0.1% fluorometholone were applied postoperatively for 2–4 weeks. The area of the uncovered ocular surface was calculated using Navis (Nidek, Gamagori, Japan) and Photoshop CS (Adobe Systems, San Jose, CA) software from slit-lamp images.

Patient 1

Patient 1 was a 73-year-old woman who had a 20-year history of Sjögren's syndrome and keratoconjunctivitis sicca. Schirmer's test was 0 mm in each eye preoperatively. Slit-lamp examination revealed a bilateral shortened tear film break-up time (2 seconds, R = L) and moderate superficial punctate keratoconjunctivitis. She underwent MBSP in her left eye. A postoperative Schirmer's test was still 0 mm in both eyes. Slit lamp examination showed improvement of superficial punctate keratoconjunctivitis in the left eye and an increase in tear meniscus height from 0.1 mm to 0.2 mm (Figure 2). The area of the uncovered ocular surface was reduced 78.3% postoperatively from the preoperative value. Postoperative follow-up for 35 months showed no recurrence of severe superficial punctate keratoconjunctivitis.

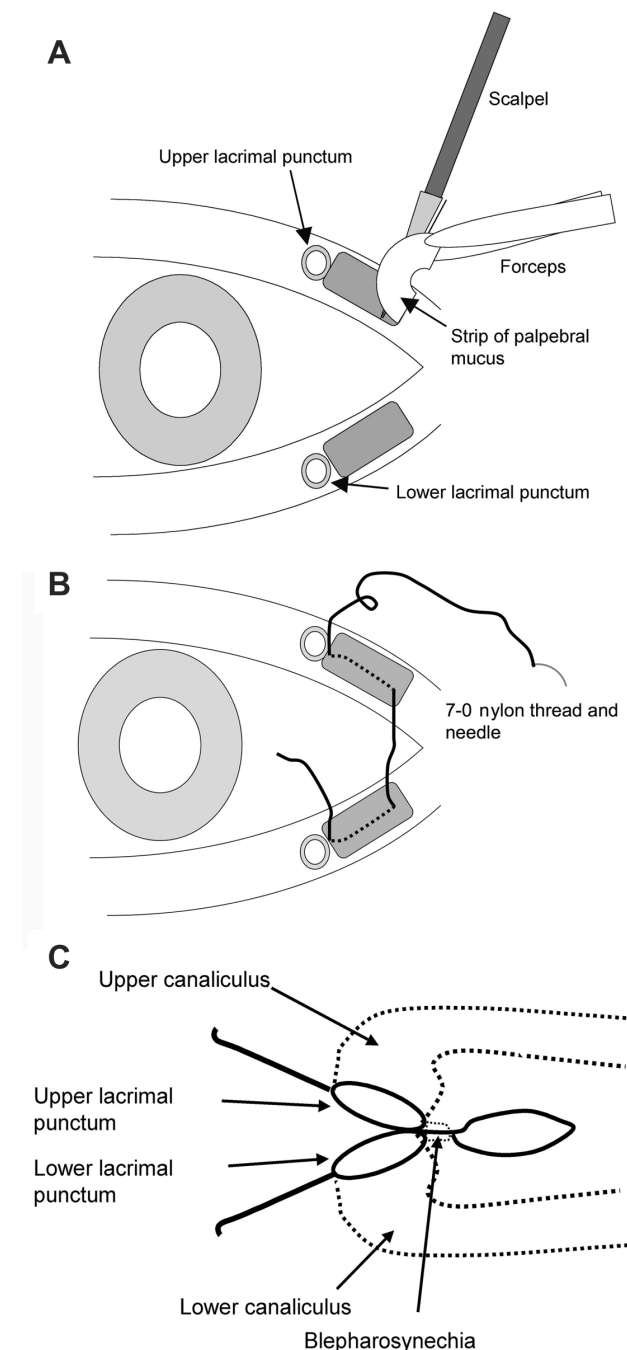


Figure 1 Schematic view of medial blepharosynechioplasty (MBSP) in the right eye. (A) Excision of two strips of palpebral conjunctiva, each measuring $2 \times 3 \times 0.5$ mm (width \times length \times thickness), from the medial side of the upper and lower puncta to facilitate formation of a synechia. (B) The incised eyelids were sewn together in the immediate vicinity of the puncta with 7-0 nylon in conjunction with insertion of a lacrimal probe into the canaliculus to prevent damage to it. (C) Enlarged view near the lacrimal puncta after MBSP.

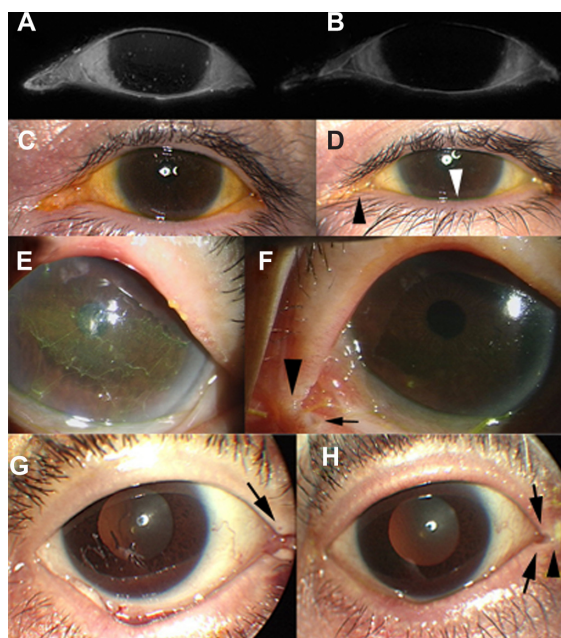


Figure 2 Preoperative and postoperative photographs of patients 1–3. (A) Preoperative photograph of fluorescent dye-stained ocular surface in patient 1. White spots imply superficial punctate keratitis. (B) Postoperative photograph of fluorescent dye-stained ocular surface in patient 1. Superficial punctate keratitis improved. (C) Preoperative photograph of patient 2. Severe dry eye is observed. (D) Postoperative photograph of same patient as in Figure 2A. Tear meniscus height elevation (white arrow head) is identified in patient 1. Synechia near the puncta are identified (arrow). (E) Preoperative photograph of patient 3. Corneal filamentosa is observed. (F) In patient 2, improvements in corneal condition and blepharosynechia (black arrow head) are observed following MBSP. Puncta (arrow) near synechia are still open. (G) Preoperative photograph of patient 3. Corneal filamentosa is observed. (H) In patient 3, improvements in corneal filamentosa and blepharosynechia (black arrow head) are observed postoperatively. Puncta (arrow) near synechia are still open.

Patient 2

Patient 2 was a 79-year-old woman who had a long history of Sjögren's syndrome, dry eye, and bilateral persistent filamentary keratopathy (Figure 2). Schirmer's test was 0 mm in both eyes. She underwent MBSP in her left eye. Filamentary keratopathy improved dramatically after the operation (Figure 2). These improvements persisted post-operatively for 30 months.

Patient 3

Patient 3 was a 76-year-old woman who had a long history of Sjögren's syndrome and chronic dacryocystitis on the left side. Dacryocystitis was treated with dacryocystorhinostomy. She subsequently showed severe superficial punctate keratoconjunctivitis in each eye, at which time Schirmer's test was 1 mm in each eye. She underwent MBSP in her right eye one year after her dacryocystorhinostomy (Figure 2). Her superficial punctate keratoconjunctivitis improved. The postoperative Schirmer's test was 5 mm in the right eye and 2 mm in the left eye. Improvement in filamentary keratopathy was observed at her 12-month postoperative follow-up visit.

Discussion

MBSP increased the quantity of tear fluid in the treated eyes. Punctal plug, punctal closure, and punctal tarsorrhaphy are surgical treatments for severe dry eye.³ MBSP resembles punctal tarsorrhaphy, but there is a difference in the patency of the lacrimal passage in MBSP. Conventional punctal tarsorrhaphy was devised for complete blockage of lacrimal drainage. However, MBSP aims to reverse the pump mechanism partially. The mechanism of action for MBSP is obscure. We hypothesize that MBSP blocks movement of the puncta and canaliculi during blinking and reduces evaporation of tears from the ocular surface through the minitarsorrhaphy. However, reducing evaporation is not thought to cause a major effect because MBSP improves

the condition of the cornea, even in the uncovered area of the cornea. Moreover, tarsorrhaphy-induced ocular coverage reduced tear evaporation by 22% in patient 1. It has also been postulated that apposition of the puncta during blinking is an important component of the valve mechanism in the lacrimal pump.⁵ By creating misalignment of the puncta during blinking, MBSP may interfere with this valve mechanism.

Periorbital injection of botulinum toxin has been reported to improve dry eye^{6,7} by mechanisms involving paralysis of the orbicularis oculi muscle around the canaliculi. MBSP may operate by a mechanism similar to that of botulinum toxin injection. Treatments involving pump suppression may well become a treatment of choice in the future. In all cases, the lacrimal ducts remained patent with no visual impairment and no punctal displacement. Further studies, including a clinical trial of MBSP utilizing a control group, are necessary.

Disclosure

The authors did not receive financial or material support from the manufacturer of any commercial product discussed in this paper.

References

1. Willis RM, Folberg R, Krachmer JH, Holland EJ. The treatment of aqueous-deficient dry eye with removable punctal plugs. A clinical and impression – cytologic study. *Ophthalmology*. 1987;94(5):514–518.
2. Kaido M, Goto E, Dogru M, Tsubota K. Punctal occlusion in the management of chronic Stevens-Johnson syndrome. *Ophthalmology*. 2004;111(5):895–900.
3. Murube J, Murube E. Treatment of dry eye by blocking the lacrimal canaliculi. *Surv Ophthalmol*. 1996;40(6):463–480.
4. Balaram M, Schaumberg DA, Dana MR. Efficacy and tolerability outcomes after punctal occlusion with silicone plugs in dry eye syndrome. *Am J Ophthalmol*. 2001;131(1):30–36.
5. Doane MG. Blinking and the mechanics of the lacrimal drainage system. *Ophthalmology*. 1981;88(8):844–851.
6. Spiera H, Asbell PA, Simpson DM. Botulinum toxin increases tearing in patients with Sjögren's syndrome: a preliminary report. *J Rheumatol*. 1997;24(9):1842–1843.
7. Sahlin S, Chen E, Kaugesaar T, Almqvist H, Kjellberg K, Lennerstrand G. Effect of eyelid botulinum toxin injection on lacrimal drainage. *Am J Ophthalmol*. 2000;129(4):481–486.

Clinical Ophthalmology

Publish your work in this journal

Clinical Ophthalmology is an international, peer-reviewed journal covering all subspecialties within ophthalmology. Key topics include: Optometry; Visual science; Pharmacology and drug therapy in eye diseases; Basic Sciences; Primary and Secondary eye care; Patient Safety and Quality of Care Improvements. This journal is indexed on

Submit your manuscript here: <http://www.dovepress.com/clinical-ophthalmology-journal>

Dovepress

PubMed Central and CAS, and is the official journal of The Society of Clinical Ophthalmology (SCO). The manuscript management system is completely online and includes a very quick and fair peer-review system, which is all easy to use. Visit <http://www.dovepress.com/testimonials.php> to read real quotes from published authors.