

Retrospective study of cattle poisonings in California: recognition, diagnosis, and treatment

Anita Varga¹
Birgit Puschner²

¹William R Pritchard Veterinary Medical Teaching Hospital, Large Animal Clinic, School of Veterinary Medicine, University of California, Davis, CA, USA; ²Department of Molecular Biosciences and the California Animal Health and Food Safety Laboratory System, School of Veterinary Medicine, University of California, Davis, CA, USA

Abstract: In this retrospective study all suspect bovine intoxications submitted to the California Animal Health and Food Safety Laboratory between January 1, 2000 and December 31, 2011 were reviewed. A total of 1199 cases were submitted, but a diagnosis of intoxication was only established in 13.5% of cases. In these cases, overexposures to minerals, metals, and poisonous plants were determined as the most commonly diagnosed poisonings in cattle in California. Nitrate/nitrite poisoning was the most commonly diagnosed plant-associated intoxication, followed by gossypol and oleander. This study details the diagnostic challenges and treatment options for the most commonly diagnosed intoxications. To ensure proper treatment and prevention of new cases, accurate diagnosis is necessary, and therefore this review provides an essential tool for the food animal practitioner. Available toxicological analyses are offered at select laboratories, which can be time consuming and expensive, yet the potential for residues in consumed animal products and implications for human health necessitate testing and consultation. Any potential exposure to a toxicant in cattle should be reviewed to determine whether a residue hazard exists. Therapy focuses on immediate removal of the toxicant from the environment and from the gastrointestinal tract. With few antidotes available, most are cost prohibitive to treat numerous affected cattle. In addition, most antidotes will require extra-label drug use and establishment of meat and milk withdrawal times.

Keywords: toxins, toxicology, poisonous plants, bovine

Introduction

Although infrequent in practice, food animal intoxications require extensive diagnostic and rapid therapeutic measures. The diagnostic approach is key for adequate treatment and prevention of further cases. Unfortunately, no single procedure will test for all toxicants, and these cases require a multifaceted approach to assemble and solve a diagnostic puzzle. A complete case history, clinical and clinicopathological data, postmortem findings, chemical analyses, and occasionally bioassay findings all provide pieces of this puzzle.¹

Toxic residues in food animals may pose a public health risk in edible products. In addition and have to diagnosis and treatment, practitioners often face publicity and medico-legal issues consult closely with regulatory agencies on food safety and public health. Crucial in complex cases, referral veterinary toxicology laboratories can help the bovine practitioner establish an accurate diagnosis and provide advice regarding food safety. In this report, we review and organize existing data from cattle poisonings in California, identify the most common toxicants, and aim to provide a tool for bovine practitioners to enable early recognition, rapid diagnosis and confident treatment.

Correspondence: Birgit Puschner
Department of Molecular Biosciences
and the California Animal Health
and Food Safety Laboratory System,
School of Veterinary Medicine,
University of California,
1120 Haring Hall, Davis,
CA 95616, USA
Tel +1 530 752 6285
Email bpuschner@ucdavis.edu

The purpose of this study was to characterize the most commonly diagnosed intoxications of cattle in California, and to provide details on diagnostic work-up and treatment in view of public health risks.

Materials and methods

Source of case material and categorization

The cases were collected from submissions to the California Animal Health and Food Safety Laboratory System (CAHFS) between January 1, 2000 and December 31, 2011. The terms “poison,” “poisoning,” “toxic,” or “toxicosis” were used to search the laboratory information database. Data obtained from the case reports included production class, location, clinical history, pathological findings, toxicological results, other diagnostic testing, and diagnosis. Cattle were subdivided into two production classes: beef and dairy. Cases were categorized as “intoxication” when toxicological testing was confirmatory and consistent with clinical history, or when pathological findings combined with exposure history, clinical and clinicopathological information were consistent with “intoxication.” For example, a positive finding of oleandrin in rumen content after an unexpected death of a cow was considered diagnostic for oleander intoxication, without detailed pathological or histopathological evaluation. In contrast, hepatic lesions suggestive of amanitin poisoning would be categorized as “hepatotoxicity” rather than amanitin intoxication, unless collected samples tested positive for amanitin.

Data analysis

This is retrospective study and data are presented descriptively.

Results

A total of 1199 bovine cases matched the search terms. Ninety percent of these cases occurred in California; 55% in dairy cattle, 41% in beef cattle, and the remainder was unspecified as to production class. A diagnosis of intoxication was established in 13.5% (162) cases (Figure 1). Ingestion of toxic plants, plant-associated toxins, and copper overexposure comprised the majority of diagnosed cases (Figure 1). Nitrate/nitrite poisoning, followed by gossypol, oleander, and pyrrolizidine alkaloids (Figure 2), comprised the majority of plant-associated intoxications in this dataset.

Discussion

While presented data reflects overall trends in California, the annual incidence of cattle intoxications remains uncertain due to challenges and cost for both the practitioner and producer to pursue in-depth analytical toxicology testing of suspect poisoning cases. Depending upon the state, regulatory agencies may assist in the work-up of suspect intoxications of food-producing animals in order to guarantee a safe food supply. The California Department of Food and Agriculture (CDFA) requires reporting of a suspect intoxication within 24 hours.² While the CAHFS toxicology laboratory provides extensive testing, specific analytical tests have been developed for many but not all toxicants. Our data enhances the

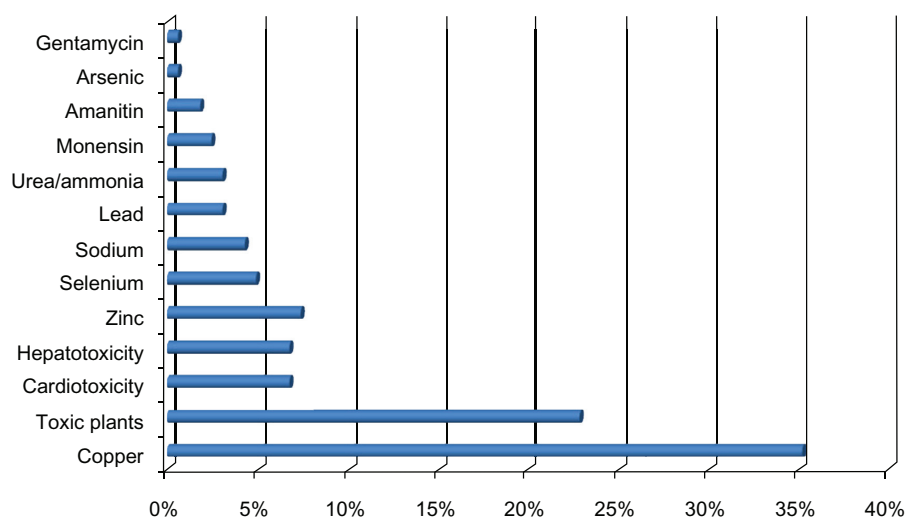


Figure 1 Estimated incidents of poisonings and identified causes diagnosed in cattle by the California Animal Health and Food Safety Laboratory System.

Notes: Incidents are reported as % of total intoxication cases (n = 162) between January 1, 2000 and December 31, 2011. Please refer to the text for further details on presented categories.

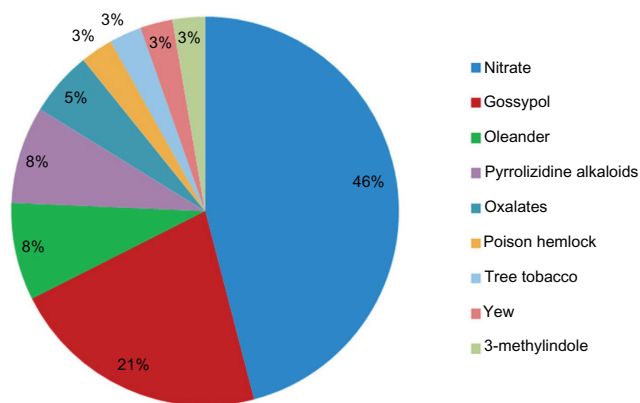


Figure 2 Break-down of the most common poisonous plant-related intoxications in cattle diagnosed by the California Animal Health and Food Safety Laboratory System.

Note: Incidents are reported as % of total plant intoxications (n = 37) between January 1, 2000 and December 31, 2011.

understanding of frequency and etiology of cattle poisoning in California. But intoxications are likely under-reported because of lack of submission to the laboratory and because of lack of identification of all toxicants. One limitation of this retrospective study is that regional differences regarding toxic poisonous plants can occur, and therefore the presented data may not reflect the same incidence of cattle in other geographical areas of the country. A larger retrospective evaluation of cattle in multiple or even all states would give more information about the common intoxications country-wide and their geographical distribution. California is also one of the leading states in the dairy industry. This could have possibly influenced the number of submissions from dairy versus beef cattle operations. However, no central poisoning reporting center for cattle exists, and the gathering of the information is difficult and problematic if attempted in multiple states. The authors therefore concentrated on the common cattle poisoning in the state of California.

Diagnostic approach

Accurate and rapid diagnosis of intoxication is challenging, as no single test detects all possible toxicants. Nonspecific clinical signs (eg, diarrhea or weakness) along with absent post-mortem lesions often confound the diagnosis. A systematic approach to collecting all evidence, proper sampling techniques, and good communication between clinician, technicians, client, and laboratory are critical for successful toxicology investigations (Table 1). A consultation with a veterinary toxicologist can facilitate and enhance the work-up of a poisoning case and ensure proper sample collection. Prior to ante-mortem examination and/or necropsy, the legal

status of the case should be determined to ensure proper documentation (chain-of-custody) and sampling.

Along with crucial history, information on age, sex, reproductive status, morbidity and mortality, and progression of clinical signs, additional questions regarding the following must be asked: recent changes in feed or water, movements of animals, administration of medications or supplements, changes in weather conditions, nearby pesticide applications or industries, changes in personnel, and potential for deliberate poisoning.^{3,4}

Toxicosis should be considered when there is a sudden onset of clinical signs in a number of cattle. Individual animals must be assessed in addition to the herd. A complete physical examination may suggest a specific toxicant, yet many poisonings have nonspecific clinical signs and rate of onset and progression of signs may prove useful to an astute diagnostician. Response to treatment can also provide important information about the possible toxicant.

Suitable samples for toxicology testing from affected, live animals include gastrointestinal (GI) contents (rumen lavage fluid, fecal material), urine, whole blood, serum, and milk. For most analyses performed on serum, blood, urine, or milk, a 1 mL volume of sample is sufficient. If excessive testing is expected, volumes of 5 mL are desired (Table 1). Tissue biopsies, such as liver collection for copper analysis, or fat collection for persistent organic pollutant analysis, can be useful for certain investigations.^{5,6} Samples should be stored in separate containers and frozen.³ Whole blood can be refrigerated at 4°C. Serum must be separated from the clot as soon as possible before freezing. Some analytes, such as potassium, magnesium, phosphorus, and zinc, may be altered by time spent in contact with the clot, because red cells continue to metabolize them or release additional material.⁷ Special care has to be taken to avoid contact with rubber products that can be a source of zinc.⁸ The best choice for trace metal, including zinc testing, is a royal-blue top tube, or equivalent, designed for trace element analysis to avoid an artificial increase.⁹

Often a complete postmortem examination of an animal is necessary to obtain information regarding the cause of an unexpected death or a suspected toxicosis. While practitioners can perform postmortem examinations, a referral veterinary diagnostic laboratory should be considered for thorough diagnostic workup. Necropsy samples can be used for histological, toxicological, and microbiological examination. Samples of major organs should be placed in 10% buffered formalin for histopathological examination. The formalin to tissue

Table 1 Specimens for analytical toxicology testing: preferred amount, container, storage condition, and extensive list of possible analytes

Sample type	Amount	Condition	Select possible tests
Whole blood	2–3 mL	EDTA anticoagulant, refrigerated	Lead, cholinesterase activity, selenium, arsenic, mercury, cyanide, some organic chemicals, anticoagulant rodenticides
Serum	1–3 mL	Spin and remove clot, avoid rubber contact for zinc testing, frozen	Copper, zinc, iron, magnesium, calcium, sodium, potassium, nitrate/nitrite, alkaloids, oleandrin, drugs, gossypol, anticoagulant rodenticides, amanitins, some pesticides, perchlorate
Urine	10 mL	Plastic vial, frozen	Alkaloids, drugs, some metals, cantharidin (blister beetle), fluoride, paraquat, oleandrin, amanitins, some pesticides
Milk	50–100 mL	Plastic vial, frozen	Antibiotic residues, plant toxins, aflatoxin M1, organochlorine insecticides, some pesticides, PCBs, iodide, perchlorate
Ingesta (live animal, feces; postmortem, stomach, small intestine, and large intestine contents; keep separated)	500 g (each)	Whirlpack bags, frozen, do not pool samples	Plant identification, seed identification, cardiac glycosides, grayanotoxins, alkaloids, tannins, insecticides, drugs, cyanide, ammonia, cantharidin, avitrol, petroleum hydrocarbons, heavy metals, ionophores, microcystins, anatoxin-a, ethylene glycol, 4-aminopyridine, anticoagulant rodenticides, herbicides, nitrate/nitrite, urea
Liver	5–10 g	Whirlpack bag, frozen	Heavy metals, minerals, oleandrin, insecticides, organic chemicals, some pesticides, cyanide, aflatoxin B1, anticoagulant rodenticides, amanitins
Kidney (cortex)	5–10 g	Whirlpack bag, frozen	Heavy metals, some plant toxins, ethylene glycol, oxalates, amanitins, sodium fluoroacetate
Brain	Half of brain	Sagittal section (for ChE activity), otherwise 5–10 g, whirlpack bag, frozen	Cholinesterase activity, sodium, macrolide endectocides, organochlorine insecticides
Ocular fluid	1 eye	Whirlpack bag, frozen	Nitrate, calcium, magnesium, potassium
Fat	30 g	Whirlpack bag, frozen	Organochlorine insecticides, PCBs
Lung	10 g	Whirlpack bag, frozen	Paraquat
Injection site	10 g	Whirlpack bag, frozen	Some drugs, other injectables
Liver biopsy	0.2 g	Whirlpack bag, frozen	Pyrrrolizidine alkaloids, metals
Muscle	10 g	Whirlpack bag, frozen	Cyanide, selenium
Hair	5 g	Tie mane/tail hair so origin is noted	Selenium (chronic exposure)
Miscellaneous for special testing	Variable	Usually frozen	Special tests, eg, spleen (barbiturates)

Abbreviations: EDTA, ethylenediaminetetraacetic acid; PCB, polychlorinated biphenyl.

sample ratio should be 9:1, and the thickness of the collected specimen should not exceed 0.5 cm. Fresh frozen samples, not formalin fixed samples, must be collected for toxicology testing.¹⁰ To avoid any dilution effect, samples should not be pooled and should be packed separately in whirlpak bags. Thorough assessment and sampling of rumen and intestinal contents is critical for sudden deaths, because unusual material (chemicals) or toxic plant parts may be identified. Generally, the most useful postmortem specimens for toxicology testing include GI contents, liver, kidney, urine, brain, and ocular fluid (Table 1).⁴ For most tissue analysis, 5 g of specimen is sufficient for toxicology testing. With regards to samples from the GI tract, it is of great use to collect contents from the rumen, small intestine, and large intestine. With regards

to brain, special care must be considered when analysis for cholinesterase activity is desired. Reference ranges are typically based on the analysis of half-brain (sagittal section). It is best to collect as many samples as possible for toxicology testing at the time of necropsy. Samples can be held frozen (tissues, serum, urine, and milk) or refrigerated (blood) until results of other tests (eg, histopathology, bacteriology, and virology) are completed before proceeding to specific toxicological analyses.

Etiologies

The incidents identified in this study allowed us to focus on the most commonly reported intoxications. In addition, we included tetracycline and sulfur as feed additive and

metal toxicants. Although our search criteria did not reveal tetracycline or sulfur intoxications, such intoxications can occur in cattle and might be underdiagnosed or a regional problem. Analysis of feeds and water for total sulfur is routinely recommended in cases of polioencephalomalacia (PEM) diagnosis. A common clinical or postmortem diagnosis in cattle, the etiology of PEM is rarely identified, and pathological lesions and/or response to thiamine treatment often provide sufficient diagnostic criteria. Documentation of tetracycline overexposures in our records does not exist because of lack of routine assays for these antimicrobials in biological specimens.

Toxic plants

Poisonous plants cause significant losses of cattle each year. However, cattle usually only eat poisonous plants when forced by environmental circumstances such as drought or when toxic plants are distributed in the ration or embedded in pellets or cubes. Poisonings can be prevented by providing ample forage and rations free of poisonous plants. Areas infested with poisonous plants should be avoided when trailing, holding, or unloading animals. Supplemental feed may help protect animals if poisonous plants are unavoidable; however, changes in palatability (possibly due to herbicides or drying) or increased toxicity of some plants (due to pesticide residues or high toxin concentrations during certain growth stages) can complicate this approach.

During the investigation of suspect plant intoxications, mixed feed from bunks or stalls as fed, unusual pasture plants, all feed ingredients going into a ration, feed supplements, tags, and labels should be collected. In addition, information on recent feed changes (with dates), feed quality (visual), preparation of mixed feed, feeding practices, feed supplements (recent changes, lot numbers, use level), lot numbers, storage facilities and conditions, pasture changes, and weather changes must be obtained. Diagnosing a plant poisoning can be difficult. In many cases, clinical signs are nonspecific (such as diarrhea), and postmortem lesions are not characteristic. Specialized veterinary toxicology laboratories may provide testing for plant toxins, but the assays do not cover the wide variety of plant toxins. In many cases, the best way to support a diagnosis of a plant poisoning is to confirm the presence of a toxic plant in the animal's environment (this will require positive identification of the suspect plant), to confirm that the plant has been ingested (noting that the candidate plants have been chewed and/or finding plant fragments in vomitus or GI tract samples), and to correlate clinical findings, where possible, with those known to

be associated with the suspect plant. If diagnostic tests are available, the diagnosis can be confirmed. This is especially important in insurance or legal investigations.

Plant intoxications may result from a single ingestion of a large amount of a poisonous plant, but small amounts of acutely toxic plants may also result in severe disease or death. In our retrospective study, acute plant-related intoxications were caused, in descending order, by nitrate-containing plants, gossypol, oleander (*Nerium oleander*), oxalates, poison hemlock (*Conium maculatum*), tree tobacco (*Nicotiana* spp.), Yew (*Taxus* spp.), and 3-methylindole. Chronic poisoning typically results in clinical signs long after exposure to the toxic plant material, and treatment may no longer be possible. Plants that resulted in chronic intoxications of cattle in our study included pyrrolizidine alkaloid-containing plants such as common groundsel (*Senecio vulgaris*), tansy ragwort (*Senecio jacobaea*), and fiddleneck (*Amsinckia intermedia*). In this article, we highlight the most commonly identified toxic plants.

Nitrate containing plants

Nitrate accumulates in vegetative tissue, particularly in the lowest 15 cm of stems.¹¹ The most common nitrate accumulating weeds, pigweed (*Amaranthus retroflexus*) and lamb's quarters (*Chenopodium* spp.), regularly contaminate alfalfa hay, but crop plants, especially oat hay, corn, ryegrass, and sorghum (*Sorghum* spp.) have been incriminated in nitrate toxicosis.^{12,13} Fertilization, herbicide treatment, drought, cloudy weather, and decreased temperatures all may increase the nitrate concentrations in plants. Water contaminated with nitrate from manure or fertilizer runoff can also result in acute intoxications.

Nitrate is reduced to nitrite by rumen microbes. In healthy ruminants, nitrite is further reduced and converted to ammonia by propionate-producing bacteria.¹⁴ Sudden ingestion of toxic amounts of nitrate results in rapid absorption of nitrite. Nitrite oxidizes Fe²⁺ to Fe³⁺, converting hemoglobin to methemoglobin and resulting in tissue anoxia.¹⁵ Clinical signs begin between 30 minutes and 2 hours after exposure, with death possible within 6–24 hours. Acute nitrate poisoning results in depression, respiratory distress, tremors, ataxia, tachycardia, and terminal convulsions. While chocolate-brown discoloration of tissues and blood has been described as a specific diagnostic marker for nitrate/nitrite intoxication, it is not routinely observed. Postmortem, analysis of aqueous humor for nitrate and nitrite concentration proves reliable if eyeballs are collected immediately or several hours after death and refrigerated.¹⁶ A rapid, yet presumptive field

diagnosis can be made using a standard nitrate dipstick to test ocular fluid. Testing of suspect source material (forage, ration, water) for confirmation and quantitation must be done if ocular fluid is consistent with intoxication, to prevent additional exposures. The established laboratory method for nitrate and nitrite quantitation is ion chromatography with a conductivity detector.¹⁷

An emergency situation, acute nitrate/nitrite poisoning must be treated as soon as possible after exposure, with minimal possible stress to cattle at risk of tissue hypoxia and acute death. While methylene blue provides the antidote to methemoglobinemia (8.8 mg/kg of a 1% solution intravenous),¹⁸ it has a 180-day withdrawal time in milk and meat. Although not approved for use in food animals, the United States Food and Drug Administration (FDA) exercises enforcement discretion in cases where treatment is needed, to prevent animal suffering.¹⁹ Chronic exposure to elevated nitrate may lead to fetal anoxia, abortions and stillbirths, and progesterone alterations.²⁰ In addition, long-term exposure to elevated nitrate concentrations in feed or water can lead to decreased production and vitamin deficiencies.

With acute poisoning likely if the feed nitrate concentrations exceed 1% (dry weight), forage management techniques should reduce nitrate concentrations to below 0.3% (dry weight). Careful use of nitrogen fertilizers, harvest under appropriate conditions, supplementation of ration with corn, ensiling, and testing hay and forage for nitrate content will help minimize intoxication risk. Hay with nitrate accumulating plants should be tested prior to feeding. If unavoidable, slow introduction of such feed is recommended to allow the rumen microbial environment to acclimatize to higher nitrate concentrations. A bacterial feed additive (propionibacterium acidipropionic strain P5) may be supplemented when exposure to high concentrations of nitrate in feed or water cannot be avoided. Water should be tested if nitrate contamination is suspected due to manure or fertilizer runoff. Water nitrate concentrations should be below 440 mg/L, but acute toxicosis is unlikely to occur until water nitrate concentrations exceed 1300 mg/L.

Oleander

A drought-tolerant, ornamental evergreen shrub found year round in the United States, especially California, Arizona, and Texas, oleander (*Nerium oleander*) grows along roads, pastures, and fence lines and can invade pastures and contaminate hay. California Animal Health and Food Safety (University of California, Davis, CA) diagnoses 50–100 cases annually in numerous species including cattle, usually from

ingestion of plant clippings, contaminated hay, or silage (Figure 3). Its cardiac glycosides (predominantly oleandrin) inhibit Na⁺-K⁺-ATPase,²¹ resulting in increased intracellular Na⁺, subsequent increased intracellular Ca²⁺, and positive inotropic effects. Cardiac glycosides also may increase vagal tone and lead to direct atrioventricular (AV) nodal depression and bradycardia.²²

Between five and ten leaves of oleander can be lethal to an adult bovine. The entire plant, including seeds, fruit, and root, fresh or dried is toxic. Clinical signs include diarrhea, salivation, cardiac arrhythmias, and death within 2–8 hours. Cardiac abnormalities include bradycardia, AV blocks, ectopic beats, and gallop rhythms.²³ Usually rapidly progressing and with many cattle found dead, rare cases present with clinical signs delayed by 12 hours or more. Postmortem findings depend on the time course and may be minimal in cases that rapidly progress to death. Reddening of the GI mucosa, pulmonary congestion, pale myocardium, or subepicardial and subendocardial hemorrhages may be noticed.²⁴ Histopathological cardiac lesions may include myocardial necrosis, interstitial edema, hemorrhage, and an inflammatory response.

One of the authors has observed transfer of oleandrin into milk of dairy cattle and into edible tissues of poisoned cows. Therefore, specific toxicology work-up of suspect oleander poisonings must address the public health risk. With zero tolerance for oleandrin in edible tissue, any detection is considered unsafe and the product adulterated. Oleandrin has been detected in milk samples for several days after exposure, while muscle tissues may remain positive for up to 10 days, albeit at low ng/g concentrations. Consultation with a toxicologist and confirmatory testing are imperative



Figure 3 Oat hay contaminated with oleander (*Nerium oleander*). Oleander leaves (▲). Oleander stems (+).

Notes: Oleander contamination was estimated to be 1% (w/w). Contamination resulted in a 15% mortality of beef cattle located in California's Central Valley.

to protect the food supply. Highly specific and sensitive liquid chromatography/mass spectrometry methods detect oleandrin in suspect plant material and specimens from animals, including GI contents, liver, serum, urine, milk, and muscle.²⁵ In live animals, serum is the sample of choice for oleandrin detection because it contains higher concentrations than urine. Postmortem, rumen contents are of greatest diagnostic use in acute deaths, while colon contents, liver, and heart are useful specimens.

There is no antidote for cardiac glycosides approved for use in cattle, and due to the acute nature, treatment may not be beneficial. Symptomatic and supportive treatment should include administration of intravenous fluids and antiarrhythmics. Activated charcoal should be administered multiple times over several days to prevent further absorption through enterohepatic circulation of the toxins.²⁶ Cardiac evaluation may warrant the use of atropine and propranolol. Digoxin-specific Fab antibody fragments cross-react with cardiac glycosides in oleander,²⁷ but dosages are empirical and potentially cost-prohibitive.

Pyrrrolizidine alkaloid containing plants

Pyrrrolizidine alkaloids (PAs) naturally occur in many plant species, including *Senecio vulgaris* (common groundsel), *S. jacobea* (tansy ragwort), and *Amsinckia* sp. (fiddleneck). Unpalatable in pastures, these plants present a major concern if incorporated into hay. Common groundsel is commonly found in spring-cut alfalfa hay in California. Flowering, growing PA plants are most toxic, while PA concentrations remain stable in hay and decrease by 90% with ensiling.²⁸ Silage still poses a risk for PA residues.

Chronic PA exposure for 2–6 months results in clinical signs of weight loss, depression, icterus, and anorexia.²⁹ Hepatogenous photosensitization can develop. In contrast to very susceptible cattle and horses, small ruminants and herbivores remain unaffected. Cows ingesting more than 5% of their bodyweight of fresh *S. jacobaea* over 1–3 months can develop severe poisoning and death. Alkaloid concentrations vary considerably in plants; thus, no comparative toxicity data exist for individual PAs or related plants. Other liver-damaging agents (copper, aflatoxins, endotoxins, or viruses) can act synergistically to increase PA susceptibility.^{30–32}

Bioactivated to highly reactive pyrroles in the liver, PAs result in crosslinking of DNA, RNA, and proteins and subsequent cytotoxicity, antimetabolic, and megalocytic activity.³³ Histopathologically, hepatomegalocytes, bile duct hyperplasia, and fibrosis can be seen. Liver enzymes (aspartate aminotransferase, sorbitol dehydrogenase, alkaline phosphatase,

and gamma-glutamyltransferase) only present alteration in early stages of disease. Quickly eliminated from blood, PA analysis is only available at select diagnostic laboratories and only meaningful in very recent exposures. With development of signs months after plant exposure, testing of feed for PAs becomes difficult or impossible because the animals are often on different, non-PA-contaminated feed. However, a thorough feed inspection and testing for PAs remains the best approach to reaching a diagnosis.³⁴ Along with the nonspecific pathological lesions, PA poisoning in cattle is mostly a presumptive diagnosis.

No specific treatment exists, and affected cattle are not expected to recover. With dilution of minute concentrations in milk processing and extremely low concentrations present in meat, this route of exposure is not considered to be of great concern to humans, with greater risk through contaminated salad mixtures, honey, grains, or herbal preparations.³⁵

Gossypol

A polyphenolic aldehyde found in cottonseed pigment glands, the bark of plant roots, leaves, seed hulls, and flowers, gossypol concentration varies among the species of cotton plant. Its free toxic form presents great concern in cottonseed and cottonseed meal commonly used as protein supplement for cattle.³⁶ Especially toxic for monogastric animals³⁷ and young calves,³⁸ adult ruminants are more resistant due to protein complex formation within the rumen.³⁹ Exceeding a dose of 24 g of free gossypol per day can lead to toxicosis because of inability of the animal to detoxify more than this amount.⁴⁰ Gossypol impairs spermatogenesis, increases the number of abnormal spermatozoa, and reduces the sperm motility in bulls fed with cottonseed products.⁴¹

Gossypol intoxication can lead to acute death in calves. Clinical signs are dyspnea, abdominal pain, diarrhea, and congestive heart failure if illness is prolonged.⁴² Chronic exposure to low concentrations of gossypol can result in poor growth and ill thrift in affected calves, enhanced by stress, such as change of feed, group housing, or other environmental factors. Gross necropsy of acute gossypol-poisoned cattle can be unremarkable. Chronic cases show evidence of pulmonary and subcutaneous edema, straw-colored effusions in body cavities, and pale streaking of myocardium indicative of cardiac necrosis.⁴³ Histopathology of the liver reveals periacinar necrosis, and clinical chemistry indicates hepatic failure in terminal cases.⁴³ Diagnosis results from history of exposure, clinical signs, necropsy findings, and analysis of feed samples. Bull semen evaluation with increased number of midpiece defects suggests gossypol overexposure.⁴⁴ Testing

for gossypol can be done in serum or plasma of animals suspected to be exposed to excessive amounts, or in feed. Laboratories use high-performance liquid chromatography.⁴⁵

With no specific treatment available, it is important to remove the feed source and offer feed without cottonseed byproducts. Supportive therapy may help in individual cases. Bulls can return to normal spermatogenesis within 2–3 months after removal of the cottonseed products from the diet.

Feed-related toxicants

Monensin

By-products of *Streptomyces spp*, ionophores of veterinary clinical significance in beef and dairy cattle include monensin, salinomycin, and lasalocid. They all lead to similar clinical presentations when overdosed. Lipid soluble antimicrobials, commonly used as feed additives for ruminants, ionophores target the rumen microbial organism, alter the ruminal ecosystem, result in increased nitrogen and carbon retention by the animal, and lead to increased production efficiency of nutrients.⁴⁶

A carboxylic polyether ionophore widely used as a feed additive in beef cattle, monensin functions as described above in addition to its use for prevention and control of coccidiosis in cattle.⁴⁷ In 2004, the FDA approved use of monensin in total mixed rations for increased milk production efficiency in dairy cattle; the following year, ionophores were widely approved for use in dairy cattle.⁴⁸

Intoxications occur as a result of error in the amount of ionophore added to the diet,⁴⁹ inaccurate on-farm feeding,⁵⁰ administration to the wrong cohort, or exposure of cattle not acclimated to the ionophore-containing ration.⁵¹ With no established LD₅₀ for cattle, toxic monensin concentrations range between 21.9 mg/kg and 80 mg/kg of bodyweight.⁵² Clinical signs of a monensin overdose include anorexia, rumen atony, lethargy, diarrhea, dehydration, muscle fasciculations, weakness, decreased milk production, and sudden death.^{48,53} Tachycardia, tachypnea, and cardiac arrhythmias can develop as signs of cardiac dysfunction. In general, monensin has been shown to have an enhanced toxicity when fed repeatedly at lower doses, compared with one single oral overdose.⁵¹

Cardiac function of cattle with monensin intoxication is impaired due to myocardial necrosis. Echocardiography of cattle with an acute monensin overdose show left ventricular systolic dysfunction and reduced chamber size.⁵³ Echocardiographic interpretation requires expertise and

special equipment, neither practical nor economic for the evaluation of a large number of cattle. A sensitive myocardial biomarker released from damaged myocardium, cardiac troponin I (cTnI) provides a noninvasive, and easy-to-perform ante-mortem diagnostic tool.⁵³ However, cTnI only confirms myocardial damage, not necessarily monensin intoxication.

Gross necropsy of cattle with monensin toxicosis shows cardiac dilatation, epicardial hemorrhages, and pale streaking of the myocardial muscle (indicating necrosis).^{53,54} In cases of prolonged ingestion of sublethal doses of monensin or survival of an acute monensin toxicosis, signs of congestive heart failure such as subcutaneous edema, hydrothorax, ascites, pulmonary edema, and liver congestion can be observed.⁵⁵ Histopathological evaluation reveals myocardial necrosis, vacuolar degeneration, swelling and eosinophilic staining of myocardial fibers, and vacuolation and swelling of mitochondria.^{52,53} Diagnosis relies upon history of exposure, quantitation of monensin concentration of the feed, and necropsy findings. Recently, detection of monensin in myocardial tissue in suspect cases has been used successfully to confirm exposure. However, analysis of feed for monensin concentration is of greatest diagnostic value and relies on liquid chromatography/mass spectrometry.⁵⁶

With no specific antidote, treatment focuses on supportive care and immediate removal of contaminated feed material. Administration of mineral oil in early cases may help sequester lipid soluble ionophore antibiotics still present in the GI system.⁵⁷ In general, the use of mineral oil in cases of intoxication is not advised.

Tetracyclines

The bacteriostatic tetracyclines, including chlortetracycline and oxytetracycline, which are equally effective against gram-positive and -negative bacteria, are used as feed additives in cattle for improved growth rate, increased feed efficiency, prevention and treatment of bacterial enteritis, and bovine respiratory disease complex. High oral dosages of dietary tetracyclines can lead to decreased activity of ruminal flora and ruminoreticular stasis.⁵⁸ Diagnosis is made by evaluation of the feed and exclusion of other toxicants leading to anorexia and rumen atony. Testing for tetracyclines is not routinely offered by veterinary diagnostic laboratories. Treatment focuses on restoration of normal rumen flora by offering good quality hay and correcting the tetracycline concentration in the diet.

Metals and minerals

Copper

An essential micronutrient, copper plays an important role in neutrophil function and triggers appropriate response of peripheral-blood lymphocytes. Below-normal serum copper concentrations significantly impact cytokine production in cattle.⁵⁹ Copper overexposure is hepatotoxic and nephrotoxic and can result in high mortality. Chronic copper poisoning can result from low dietary intake of molybdenum. With decreased intake of dietary molybdenum, GI uptake of copper increases and even normal copper feed concentrations can become toxic to cattle.

Oral or parenteral administration of an acutely toxic dose of copper frequently results from supplementation without nutritional consultation or assessment of herd copper status. Aside from the risk of acute intoxication, this type of supplementation is often not cost effective. Previously, injectable copper preparations, eg, Cu-EDTA, were commonly given to cattle raised on copper-deficient pasture or on molybdenum-rich soil. Slow release, orally administered copper boluses, can result in chronic copper intoxications in suckling calves, particularly if multiples sources of copper exist.⁶⁰ Occasionally, acute hepatotoxicosis due to soluble forms of injectable copper occurs even within the recommended dose; other mineral deficiencies (eg, selenium) may result in increased sensitivity.⁶¹

Acute clinical signs include GI (eg, diarrhea), and central nervous system disturbances, such as circling, head pressing, and ataxia. Some cattle exhibit dyspnea and depression.⁶¹ Others are just found dead. Death usually occurs 12–72 hours post-injection. Acute copper poisoning cases lack icterus or hemoglobinuria as seen in chronic cases with hemolytic anemia.⁶²

Gross necropsy shows peritoneal hemorrhage in some cases.⁶³ Acute copper toxicosis does not necessarily cause the triad of liver damage, hemolysis, and renal damage as seen in chronic toxicoses.⁶⁴ Severe acute generalized centrilobular to panlobular liver necrosis and vacuolar degeneration in the renal tubular epithelial cells can be observed.⁶¹ Nonspecific hepatic degeneration and necrosis require additional testing for aflatoxins, PAs, or gossypol ingestion. Specific copper histochemical stains can confirm diagnosis.

Chronic copper poisoning occurs when the amount of copper absorbed from the diet exceeds the nutritional requirement and the animal's capacity to excrete the excess. The abundant copper accumulates within the liver over a variable period of time.⁶⁵ Clinical signs manifest acutely when the liver's

copper storage is saturated, and the rupture of intracellular lysosomes results in hepatocellular necrosis and liberation of a large amount of copper into the bloodstream. This can lead to acute intravascular hemolysis (hemoglobinuria, icterus, and anemia).^{65,66} However the majority of cattle with chronic copper intoxication show unspecific signs, such as dull mentation and anorexia. Kidney failure in some cases of hemolytic crisis can occur due to hemoglobinuric and tubular nephrosis; death of the animal can occur within hours of first clinical signs. Chronic copper ingestion can also manifest in poor hair coat, weight loss, diarrhea, decreased appetite, milk production, and susceptibility to mastitis, metritis, and retained placenta.^{67,68}

The unspecific clinical signs render diagnosis of chronic copper toxicosis challenging, and other differential diagnoses for liver failure should be considered. Postmortem observations in cattle with an acute hemolytic crisis include generalized icterus, dark swollen kidneys, and pigmenturia, while animals with silent chronic copper exposure usually show no prominent features on gross examination of the carcass. Serum/plasma copper concentrations correlate poorly with liver copper concentrations.⁶⁹ However, in acute hemolytic crisis, serum copper concentration increases from the massive release of copper stores from the hepatocytes. Hepatic enzyme activity also increases. The measurements are unlikely to be elevated prior to hemolytic crisis.⁶⁹ Thus, serum copper analysis can provide useful diagnostic data during the acute phase of the disease. Analysis is done routinely in laboratories using inductively coupled plasma emission spectrometry.⁷⁰ Both, liver and kidney copper concentrations must be evaluated in suspect intoxications. Analysis for copper is typically done by inductively coupled plasma emission spectrometry. Generally between 25 and 100 mg/kg wet weight, copper wet weight varies with age and production class. While liver copper concentrations of greater than 250 mg/kg wet weight are consistent with overexposure, pathological or additional toxicological results must also be considered.⁷¹ In acute clinical cases, kidney copper concentrations typically exceed 10 mg/kg wet weight.⁶³

Lead

Lead poisoning results from cattle's natural curiosity and their habit of licking and indiscriminate eating.⁷² This presents a human food safety concern due to potential exposure to meat or milk products of affected animals⁷³ and results in considerable economic loss in beef and dairy herds.⁷⁴ Asymptomatic animals may have substantial amounts of lead in tissues and

milk; thus, a thorough investigation is required to adequately protect human health.^{75,76} Single ingestion of large quantities of lead-containing material, licking of lead-containing paint chips in old barns or discarded paint cans, consuming water from lead-containing water pipes, lubricants, and lead accumulator batteries result in acute intoxication.⁷⁴ Chronic exposure occurs from grazing on polluted pastures in the vicinity of lead mines or ingestion of forages harvested from such areas.⁷⁷

Only 2%–10% of the ingested lead is absorbed through the GI tract and rapidly distributed to kidney and liver.⁷⁴ Kidney tissue concentrations often reflect accurately the environmental level.⁷⁴ Harmful for unborn calves, lead can accumulate in the central nervous system of the neonate due to immaturity of the blood–brain barrier.⁷⁸ Secretion into milk and redistribution into bone (storage site) may also be significant.⁷⁴ Milk-based diets fed to young cattle enhance the absorption of lead from the GI tract. In addition, lead-contaminated milk from dams can result in exposure and risk.⁷⁹ More commonly, young cattle ingest a single material with high bioavailability (lead oxide, carbonate, or acetate).⁷² Death usually occurs within 12–24 hours without previous clinical signs.⁸⁰

Neurological signs include cortical blindness, delayed menace, head pressing, delayed withdrawal reflex, reduced tongue tone, champing of the jaws with ptyalism and frothing at the mouth, rapid and difficult breathing, tachycardia, ataxia, and tremors.⁸¹ Some animals may wander aimlessly, circle, or walk through objects such as fences or brush.⁸² More common in adults, subacute lead poisoning can lead to depression, anorexia, and GI disturbances such as constipation followed by diarrhea, signs of colic, bruxism and rumen atony. Central nervous system signs also occur.⁸² Hematological evaluation can include basophilic stippling of erythrocytes and increased nucleated red blood cells, but may not be present in acute cases.⁸³ In less common chronic exposures, cattle develop weakness, incoordination and muscle wasting, abortion, and sterility,⁸² and develop normocytic, normochromic anemia, and basophilic stippling of red blood cells.⁸⁰

Gross necropsy can reveal metallic fragments in the reticulum, suggestive of lead poisoning.⁸⁴ However, many lead sources would not be noticeable during necropsy. While all forms of lead are toxic, organic lead is considered most bioavailable, followed by inorganic lead salts (eg, lead acetate, lead sulfide) and metallic lead. Although different lead species are absorbed to varying degrees, all are capable of causing adverse health effects. Histopathology of the

brain will show evidence of polioencephalomalacia, such as cerebral laminar cortical necrosis, severe congestion of cerebrocortical tissue and meninges, edema, and endothelial swelling.^{85,86} Severe liver necrosis and lipid accumulation,⁸¹ and renal tubular degeneration,⁸² may occur. Ante-mortem diagnosis of acute intoxication relies on history of exposure, clinical signs, and blood lead concentration greater than 0.35 µg/mL.⁸⁵ It is critical to analyze a whole blood sample for lead. Serum and plasma samples are not appropriate for lead analysis because lead associated with red blood cells. Furthermore, clinically asymptomatic animals which could have been exposed should be tested for lead. Lead analyses are widely available through diagnostic laboratories, and most laboratories use atomic absorption analysis. Clinical signs correlate poorly with blood concentrations.⁷⁴ Postmortem diagnosis is made based on history and liver and kidney lead concentrations. It is best to determine the lead concentrations in both tissues, as concentrations vary based on the timeframe between exposure and death. Analysis of tissues for lead is typically done by inductively coupled plasma emission spectrometry.

Sulfur

Necessary for cellular function and growth of ruminal microorganisms, sulfur is an important component for rumen synthesis of the sulfur-containing amino acids, and for production of B-vitamins. A minimal 0.15% sulfur is recommended in beef cattle diets and maximum dietary sulfur concentration has been estimated at 0.4%.⁸⁷ Since sulfur content of feedstuffs relates directly to protein concentration and can vary greatly, sulfur-containing additives are often added but can lead to toxic levels.^{88,89} Water can be a significant source of sulfur, and increased water intake with rising ambient temperatures can influence total sulfur consumption. Furthermore, sulfur-containing plants can contribute to a large amount of sulfur.⁹⁰ Cattle exposed to manure gas with a high H₂S content developed PEM, making inhalation of gas a potential source for sulfur intoxication.⁹¹

In beef calves, experimental diets containing more than 4000 ppm sulfur produce neurologic disease due to PEM, and subclinical brain lesions have been observed in a few calves with consumption of sulfur lower than 4000 ppm. Dietary sulfates are reduced to sulfides within the rumen and form hydrogen sulfide gas, increasing risk of PEM.⁹² A concentration of 2000 mg/L hydrogen sulfide typically precedes clinical cases of PEM in cattle.⁹³ Analysis for sulfur in feeds and tissues can be accomplished by inductively coupled plasma emission spectrometry, while analysis for hydrogen sulfide

is done by a H₂S-detector tube. Sulfate concentrations in water are determined by sulfate anion chromatography with conductivity detection.

Acute sulfur intoxication leads to neurologic manifestation, including cortical blindness, staggering, muscle fasciculations, recumbency, opisthotonus, uncontrolled paddling,⁸⁹ coma, or death in the absence of preceding clinical signs.⁸⁸ Exhaled breath may smell of hydrogen sulfide. Sulfates are less toxic than H₂S, but can lead to an osmotic diarrhea due to poor absorption. Histopathology of the brain reveals signs of PEM, such as laminar and cortical spongiosis and neuronal necrosis within the cerebral cortex.⁹⁰

Differential diagnoses for neurologic disorders in cattle include lead poisoning, sodium poisoning, thiamine deficiency-induced PEM, hypovitaminosis A, and *Histophilus somni* meningoencephalitis. Sulfur-induced PEM does not cause a decrease in rumen or blood thiamine concentrations. Diagnosis of sulfur PEM is made by estimation of the total sulfur intake from feed and water. Impractical in the field, sampling of rumen gas for hydrogen sulfide concentration can help assess clinical cases. Treatment of cattle with sulfur-induced PEM consists of thiamine administration, removal of the sulfur containing diet or water, and administration of dexamethasone, if cerebral edema is suspected. Often nonresponsive to thiamine, this treatment may just hold a diagnostic and prognostic value.

Zinc

An essential trace element involved in protein synthesis, carbohydrate metabolism, and enzyme function,⁹⁴ zinc is relatively nontoxic to ruminants. Bioavailability of zinc complexes, amount of dietary fiber, amount and period of zinc feeding, along with age and concurrent disease, influence the susceptibility from environmental contamination or increased amounts in diet or water.⁹⁵ Acute clinical signs include anorexia, drastic decrease in milk production, light-green colored diarrhea, and weakness, while chronic exposure leads to diarrhea, followed by constipation, weight loss, or decreased weight gain in young animals. In live cows, serum and plasma samples are considered suitable for zinc determination. Special care must be taken to avoid contact with rubber products that can be a source of zinc (eg, rubber-topped tubes) and hemolysis, which may also increase zinc concentration. Necropsy of acute cases reveals pulmonary emphysema, pale myocardium, renal hemorrhages, and hepatic degeneration. Chronic exposure leads to pancreatic and renal damage. Histopathology reveals acinar cell degeneration and necrosis and renal cortical fibrosis in calves.⁹⁵

Diagnosis includes feed or water mineral analysis and measurement of tissue zinc concentrations. Liver zinc determination is of greatest diagnostic value in postmortem evaluations. Analysis for zinc is typically done by inductively coupled plasma emission spectrometry

Zinc muscle concentrations are similar to those in the liver, and, in clinical cases, a muscle sample is easy to obtain.⁹⁶ Treatment of zinc poisoning involves removal of feed material high in zinc and increased dietary roughage content.⁹⁷

Environmental toxicants and conditions

Microcystins

Increasing global water temperatures, nutrient and pollutant enrichment lead to eutrophication of fresh and coastal water bodies and can result in toxicogenic cyanobacterial (blue-green algae) blooms. Produced by multiple cyanobacteria, microcystins have been detected worldwide, resulting in numerous animal intoxications. These algal toxins present a constant threat to pastured animals because of their persistence in ponds and streams (Figure 4). Cattle drink contaminated water readily, even consuming algal mats, and poisonings appear to be on the rise. The number of structural variants frequently present in surface water blooms makes estimating toxicity difficult. Cyclic heptapeptides causing acute liver damage through potent inhibition of protein phosphatases 1 and 2A,⁹⁸ microcystins result in diarrhea, weakness, pale mucous membranes, and shock within 30 minutes to several hours.^{99,100} Many die within hours to days, but individual cattle may survive and develop hepatogenous photosensitization (Figure 5). The rapid onset of acute hepatotoxicosis renders



Figure 4 Pond with *Microcystis* bloom in California's Central Valley.

Note: Pond water contained microcystin-LR and resulted in acute deaths of 15 Holstein heifers.

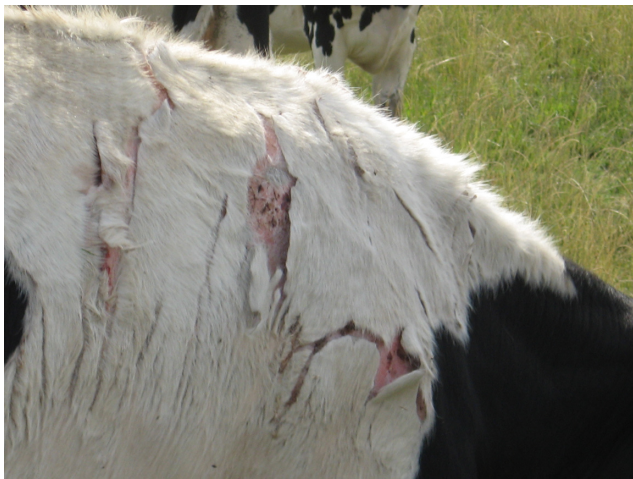

Figure 5 Photosensitization resulting from microcystin exposure.
Notes: Microcystin toxicoses resulted in acute deaths in 15/200 Holstein heifers in California's Central Valley. Approximately 10% of the cattle developed hepatogenous photosensitization. Microcystin-LR was identified in pond water contaminated with *Microcystis* sp.

therapeutic intervention quite difficult, and high mortality rates results. No specific therapy has proven effective in laboratory animals, including decontamination with activated charcoal and no data exists for adsorptive capacity in other animals.¹⁰¹ Symptomatic and supportive care to treat hypovolemia and electrolyte imbalances, and antioxidants such as vitamin E and selenium should be included in the therapeutic regimen for cattle poisoned with microcystins. Cattle with photosensitization must be protected from sun exposure.

A diagnosis of microcystin poisoning is confirmed by liquid chromatography/mass spectrometry analysis of stomach contents, suspect water source, and algal material. As the toxicity of cyanobacteria is strain-specific, morphological identification of the algal genus alone cannot predict the hazard level of a given water source. Detection methods for microcystins in liver or other tissues remain to be developed. Acute hepatic damage results in an enlarged and friable liver resulting from intrahepatic hemorrhage and, histopathologically, in hepatocyte dissociation, degeneration, and necrosis. Pathological findings should quickly lead to an environmental assessment for possible microcystin contaminated water.

Consumption of milk, meat, or liver is unlikely to pose a significant health risk to humans.^{102,103} However, as a tumor promoter, microcystins may pose a cumulative health risk as they become more ubiquitous. Steps must be taken to reduce fertilizer runoff and applications in fields surrounding ponds used for drinking water. Treatment of water sources with algicides releases intracellular toxins, and prevention of blooms is key to protect animal and human health.

Amanitins

More frequently reported in humans, based on clinical presentation and mushroom identification, mushroom poisonings now can be diagnosed by testing of specimens of animals for specific toxins.¹⁰⁴ Amanitins are found in a number of mushroom genera including *Amanita*, *Galerina*, *Lepiota*, *Cortinarius*, and *Conocybe* spp. *Amanita phalloides* (death cap) and *Amanita ocreata* (Western North American destroying angel) are the most common amanitin-containing mushrooms associated with lethality in the United States.¹⁰⁵ A single mushroom can result in the death of a dog or human; while the exact toxicity to cattle is unknown, amanita intoxications may be more common than originally thought.¹⁰⁶

Amanitins decrease transcription and protein synthesis through inhibition of RNA polymerase II,¹⁰⁷ resulting in toxic effects on hepatocytes, crypt cells, and proximal convoluted tubules of the kidneys. Poisoning leads to severe GI duress (colic and diarrhea) approximately 8–12 hours after exposure. The animal may appear to recover for several hours before developing acute liver, renal, and possible multi-organ failure.¹⁰⁸ Elevated serum liver enzyme activities, hypoglycemia, and prolonged clotting times result. Cattle may just be found dead in pasture.

With treatment reliant on symptomatic and supportive care, prognosis is poor. Once acute hepatotoxicosis occurs, effective therapeutic intervention is no longer possible. If acute liver or multi-organ failure has not developed, treatment involves activated charcoal (two to three doses within 24 hours) and supportive care. Silibinin, milk thistle extract (*Silybum marianum*), has been successfully used in Europe to reduce the uptake of amanitins into hepatocytes in humans. No safety or efficacy data exist for use in cattle.

At necropsy, the liver is typically friable with an enhanced reticular pattern. Histopathological lesions indicate a diffuse, centrilobular to panlobular hepatic necrosis. Microcystins, copper, anemia, heart failure, or cocklebur (*Xanthium* spp.) present differential diagnoses, so further confirmation is needed. Analysis of serum, urine, gastric contents, liver, or kidney for amanitin can be performed at select veterinary toxicology laboratories. In live, symptomatic animals, urine is preferable for diagnosis. Postmortem, depending on time since exposure, kidney may contain higher concentrations than liver. Identification of mushroom pieces in the GI contents also may aid in diagnosis in addition to mushrooms collected from the environment. Accurate mushroom identification requires an experienced mycologist. The availability of diagnostic assays will help determine the frequency of mushroom poisonings in cattle.

Water deprivation/sodium ion intoxication

In cattle, sodium toxicosis or water deprivation can result in acute disease with high morbidity and mortality. Intoxications usually occur with ingestion of salt blocks or loose salts following limited exposure to salts for a prolonged period of time. Concurrent decreased water consumption increases clinical severity. A defective water trough system, no access to water,¹⁰⁹ or in cold weather due to freezing of the water source, can lead to hypertonic dehydration with hypernatremia. Hot weather, high milk production, or transportation contribute to toxicity through increased total body-water losses.¹¹⁰ Nursing or diarrheic calves with limited or no access to water become intoxicated when offered milk replacer or electrolytes solution which is improperly formulated or has manufacturer errors.¹¹¹

Cattle become depressed and refuse to eat. Acute cases result in central nervous system disturbances, including excitability, blindness, incoordination, hyperesthesia, opisthotonus, nystagmus, muscle twitching, and convulsions, followed by death, due to osmotic differences and resulting water losses from the brain.^{109,112} Signs of dehydration, especially with prolonged water deprivation, include dry feces and mucus membranes, increased eye ball recession, and skin tent duration. Some animals experience GI disturbances, such as colic and diarrhea, and frequent urination. Although gross necropsy findings are nonspecific, histopathological evaluation of the central nervous system may reveal cerebral edema and lesions consistent with PEM.¹¹³

Suspicion of diet-related intoxication is made based on the history of feed and water changes; however, definitive diagnosis of sodium poisoning is made by toxicological and pathological evidence. Toxic sodium concentrations can be measured in serum, aqueous humor, cerebrospinal fluid, and in rumen content and will be severely elevated in clinical cases. Ocular fluids present a useful and reliable specimen for measuring sodium concentrations. Sodium concentration within the aqueous or vitreous humor does not change

significantly during postmortem autolysis and reflects the sodium concentration at the time of death. The ocular sodium concentration is approximately 95% of the serum sodium concentration. The sodium ion concentration within the brain can also be utilized.

Pesticides and baits

Although the database search did not confirm poisonings in cattle with pesticides or baits, this must be considered.^{114,115} The toxicants of greatest concern in this category are carbamate and organophosphorus insecticides.¹¹⁵ In 1998, 167 lactating dairy cows died within a 24-hour period in the Central Valley of California after ingesting phorate (Puschner, personal communication). The organophosphorus insecticide was mistaken for a mineral supplement and added to the total mixed ration. Phorate poisoning was confirmed by the determination of depressed cholinesterase activity in brains, and phorate detection in liver, rumen contents, and feed. Other commonly used pesticides around cattle include strychnine, anticoagulant rodenticides, zinc phosphide, and pyrethrins/pyrethroids. While most of those toxicants have resulted in malicious or accidental intoxications in small animals, they present a risk to cattle as well.

General therapeutic approach to intoxications of cattle

Treatment begins with removal of the causative agent. If feed-mixing errors have occurred, the feed should be withheld and good quality of roughage should be provided to the animals. The ingestion of toxic materials should be immediately followed with decontamination (Table 2). Ideally, the toxic compound is removed from the rumen and GI tract. Rumen lavage may be attempted with a large diameter bore tube (eg, the Kingman tube), but the large rumen volume and fibrous contents capable of plugging the tube present a challenge. Aspiration pneumonia might be a risk. Surgical ruminal evacuation (rumenotomy) can be performed if the

Table 2 The dos and don'ts when dealing with a poisoning case in cattle

	The dos	The don'ts
Diagnostic approach	<ul style="list-style-type: none"> • Obtain a complete history. • Evaluate feed, water, and environment. • Perform physical examination. • Perform necropsy if deaths have occurred. • Collect samples for pathological, toxicological, and microbiological evaluation. • Consult with a food animal veterinarian and toxicologist. 	<ul style="list-style-type: none"> • Miss sample collection for testing. • Combine samples in one container. • Store samples at room temperature. • Rely on toxicological analysis for a diagnosis. • Disregard residue concerns.
Therapeutic approach	<ul style="list-style-type: none"> • Administration of activated charcoal. • Administration of a cathartic. • Stay within the legal guidelines when using extra-label therapeutics. 	<ul style="list-style-type: none"> • Administration of mineral oil. • Use of prohibited drugs.

patient is stable and without cardiovascular compromise. All contaminated feed material can be removed, and further absorption of the toxic compound eliminated if rumenotomy is performed shortly after ingestion and before the substance is completely absorbed or transitioned into the intestine. Rumenotomy is recommended in individual cattle, with a high genetic, economic, or sentimental value. However, the procedure is time consuming and not practical or economic if numerous cattle are affected.

For herd outbreaks, activated charcoal (AC) has been successfully used as an orally administered adsorbent of toxicants.^{116–118} In suspected intoxications AC should be administered as soon as possible, prior to absorption of toxicants from the GI tract. AC binds toxicants, preventing or reducing the absorption. The dosage for cattle is 1–3 g per kg of bodyweight, mixed with 5 mL water per gram AC.¹¹⁹ The water-AC mix is administered per orogastric tube twice a day and can be given for multiple days without any concern for adverse effects. The Food Animal Residue Avoidance Database has listed a zero day meat and milk withdrawal for the use of AC in ruminants. It is contraindicated to administer AC with mineral oil, as the adsorptive properties of charcoal diminish. Dairy calves should be fed at least 3 hours apart from charcoal administration as feeding interferes with adsorptive properties.

Administration of a purgative agent will decrease the GI transit time and subsequently time for absorption. Commonly used parenteral cathartics in cattle include magnesium sulfate (Epsom salt) and sodium sulfate (Glauber's salt). Their cathartic action results from osmotically mediated water retention, stimulating GI peristalsis. Magnesium also may stimulate release of cholecystokinin, leading to accumulation of intraluminal electrolytes and fluid and increasing intestinal motility.¹²⁰ Epsom salt can be administered from 250 to 500 mg/kg body mass in the AC slurry. Magnesium sulfate should be used with caution in animals with cardiac abnormalities or myocardial injury. If affected cattle already have diarrhea, there is no need to administer a cathartic agent. Mineral oil is a lubricant laxative, commonly used in large animals for the treatment of GI constipation and fecal impaction. Its use is discouraged in intoxications because of questionable efficiency as adsorbent for toxicants and adverse effect on AC (Table 2).

Intoxicated cattle often need supportive therapy irrespective of specific toxin. Depending on electrolyte and hydration status of the animal, intravenous fluid therapy may be warranted. On farm, fluid therapy is possible and should be encouraged by the livestock veterinarian. Thiamine (vitamin B1) should

be administered to anorexic cattle and those with neurologic deficits, for prevention or treatment of PEM.

If a specific diagnosis has been made, possible antidotes should be administered as soon as possible. The food animal veterinarian should keep in mind that most of the antidotes are not approved for the use in cattle, and extra-label drug use will be required in addition to establishment of milk and meat withdrawal times. Veterinarians are encouraged to familiarize themselves with regulations and laws applicable in their practicing region. In the United States, the Food Animal Residue Avoidance Databank provides a useful resource.

Conclusion

The present study demonstrated that in cattle, overexposures to minerals, metals, and poisonous plants are the predominant causes of intoxications in California. While poisonings were only confirmed in 13.5% of the 1199 cases submitted as suspect intoxications, all cases of unexplained deaths or high morbidity events should be investigated as to a possible toxic etiology. Proper sample collection from the animal and environment is crucial for a diagnostic work-up. Information regarding exposure, chronology of events and types of clinical signs, blood and chemistry changes, treatment initiated, and response to treatment should be recorded and sent to the veterinary diagnostic laboratory to narrow necessary testing. While newer analytical methodologies allow broad-based screening of appropriate samples in cases in which exposure to a specific toxicant has not been identified, no single comprehensive test for all possible toxicants exists.

Treatment of suspect poisonings is initially symptomatic and supportive but becomes more targeted with diagnosis. Decontamination of the GI tract using activated charcoal is common practice for managing acute poisonings in cattle, even though few data exist on the adsorptive capacity. While decontamination is commonly initiated prior to a confirmed laboratory diagnosis, it is important to consider that some toxicants, such as metals, are not adsorbed by activated charcoal. Food animal practitioners and veterinary toxicologists can provide consultation about toxic rule-outs for a case, diagnostic testing, treatment of affected animals, and prevention of additional cases. In addition, the possibility of residues in food animal products must be considered when dealing with a poisoning case in cattle, which may require consultation with appropriate regulatory agencies.

Acknowledgments

We thank all pathologists, diagnosticians, and technicians of the California Animal Health and Food Safety Laboratory

for their expertise and valuable contributions to the diagnostic investigations of cases.

Disclosure

The authors report no conflicts of interest in this work.

References

- Galey FD. Diagnostic toxicology for the small animal veterinarian. *Calif Vet*. Sept–Oct 1994:7–10.
- California Department of Food and Agriculture. Reporting animal diseases. http://www.cdffa.ca.gov/ahfss/animal_health/Disease.html. Accessed June 26, 2012.
- Giorgi M, Naso B. Laboratory diagnostic examinations in veterinary toxicology. *Vet Res Commun*. 2004;28 Suppl 1:103–106.
- Galey FD. Diagnostic toxicology. In: Plumlee KH, editor. *Clinical Veterinary Toxicology*. St Louis, MO: Mosby; 2004:22–23.
- Osheim DL, Ross PF, Nelson HA. PCB residues in feedlot steers. II. Tissue levels. *Bull Environ Contam Toxicol*. 1982;28(6):716–717.
- Rogers GM, Capucille DJ, Poore MH, Mass J, Smallwood JE. Growth performance of cattle following percutaneous liver biopsy utilizing a Schackelford–Courtney biopsy instrument. *Bovine Pract*. 2001;35:177–184.
- Zhang DBJ, Elswick RK, Miller WG, Bailey JL. Effect of serum-clot contact time on clinical chemistry laboratory results. *Clin Chem*. 1998;44(6):1325–1333.
- Minnick PD, Braselton WE, Meerdink GL, Slanker MR. Altered serum element concentrations due to laboratory usage of Vacutainer tubes. *Vet Hum Toxicol*. 1982;24(6):413–414.
- Frank EL, Hughes MP, Bankson DD, Roberts WL. Effects of anticoagulants and contemporary blood collection containers on aluminum, copper, and zinc results. *Clin Chem*. 2001;47(6):1109–1112.
- Sato I, Sera K, Suzuki T, Kobayashi H, Tsuda S. Effects of formalin-preservation on element concentrations in animal tissues. *J Toxicol Sci*. 2006;31(3):191–195.
- Bedwell CL, Hamar DW, Hoesterey ML, Sonderman JP, Odde KG. Comparison of 4 Methods for Forage Nitrate Analysis. *J Vet Diagn Invest*. 1995;7(4):527–530.
- Casteel SW, Johnson GC, Miller MA, et al. Amaranthus retroflexus (Redroot Pigweed) poisoning in cattle. *J Am Vet Med Assoc*. 1994;204(7):1068–1070.
- Ozmen O, Mor F, Unsal A. Nitrate poisoning in cattle fed Chenopodium album hay. *Vet Hum Toxicol*. 2003;45(2):83–84.
- Muirhead D. Propionibacterium appears capable of reducing nitrate, nitrite toxicities. *Feedstuffs*. 1992;64(40):12–13.
- Kemp A, Geurink JH, Haalstra RT, Malestein A. Nitrate poisoning in cattle. 2. Changes in nitrite in rumen fluid and methemoglobin formation in blood after high nitrate intake. *Neth J Agr Sci*. 1977;25(1):51–62.
- Edwards G, Foster A, Livesey C. Use of ocular fluids to aid postmortem diagnosis in cattle and sheep. *In Pract*. 2009;31(1):22–25.
- Boermans HJ. Diagnosis of nitrate toxicosis in cattle, using biological fluids and a rapid ion chromatographic method. *Am J Vet Res*. 1990;51(3):491–495.
- Bright SJ, Post LO. Veterinary antidotes and availability: an update. 2008. Available from: <http://www.abvt.org/public/docs/antidoteupdate08.pdf>. Accessed June 27, 2012.
- Bright SJ, Murphy MJ, Steinschneider JC, Lovell RA, Post LO. Treatment of animal toxicoses: a regulatory perspective. *Vet Clin North Am Food Anim Pract*. 2011;27(2):481–512, x.
- Inoue T, Kaibara M, Sakurai-Yamashita Y, Kawano M, Ishimaru T, Tanigawa K. Increases in serum nitrite and nitrate of a few-fold adversely affect the outcome of pregnancy in rats. *J Pharmacol Sci*. 2004;95(2):228–233.
- Jortani SA, Helm RA, Valdes R. Inhibition of Na,K-ATPase by oleandrin and oleandrinogenin, and their detection by digoxin immunoassays. *Clin Chem*. 1996;42(10):1654–1658.
- McLain PL. Effects of cardiac glycosides on spontaneous efferent activity in vagus and sympathetic nerves of cats. *Int J Neuropharmacol*. 1969;8(4):379–387.
- Galey FD, Holstege DM, Plumlee KH, et al. Diagnosis of oleander poisoning in livestock. *J Vet Diagn Invest*. 1996;8(3):358–364.
- Galey FD, Holstege DM, Johnson BJ, Siemens L. Toxicity and diagnosis of oleander (Nerium oleander) poisoning in livestock. In: Garland T, Barr AC, editors. *Toxic plants and other natural toxicants*. New York, NY: CAB International; 1998:215–219.
- Tor ER, Filigenzi MS, Puschner B. Determination of oleandrin in tissues and biological fluids by liquid chromatography-electrospray tandem mass spectrometry. *J Agric Food Chem*. 2005;53(11):4322–4325.
- Tiwary AK, Poppenga RH, Puschner B. In vitro study of the effectiveness of three commercial adsorbents for binding oleander toxins. *Clin Toxicol*. 2009;47(3):213–218.
- Camphausen C, Haas NA, Mattke AC. Successful treatment of oleander intoxication (cardiac glycosides) with digoxin-specific Fab antibody fragments in a 7-year-old child: case report and review of literature. *Z Kardiol*. 2005;94(12):817–823.
- Wiedenfeld H. Plants containing pyrrolizidine alkaloids: toxicity and problems. *Food Addit Contam Part A Chem Anal Control Expo Risk Assess*. 2011;28(3):282–292.
- Stegelmeyer B, Gardner D, Davis TZ. Livestock poisoning with pyrrolizidine-alkaloid-containing plants (Senecio, Crotalaria, Cynoglossum, Amsinckia, Heliotropium, and Echium spp.). *Rangelands*. 2009;31(1):35–37.
- Yee SB, Kinser S, Hill DA, et al. Synergistic hepatotoxicity from coexposure to bacterial endotoxin and the pyrrolizidine alkaloid monocrotaline. *Toxicol Appl Pharmacol*. 2000;166(3):173–185.
- Morris P, O'Neill D, Tanner S. Synergistic liver toxicity of copper and retrorsine in the rat. *J Hepatol*. 1994;21(5):735–742.
- Newberne PM, Chan WC, Rogers AE. Influence of light, riboflavin, and carotene on the response of rats to the acute toxicity of aflatoxin and monocrotaline. *Toxicol Appl Pharmacol*. 1974;28(2):200–208.
- Hincks JR, Kim HY, Segall HJ, Molyneux RJ, Stermitz FR, Coulombe RA Jr. DNA cross-linking in mammalian cells by pyrrolizidine alkaloids: structure-activity relationships. *Toxicol Appl Pharmacol*. 1991;111(1):90–98.
- Holstege DM, Seiber JN, Galey FD. Rapid multiresidue screen for alkaloids in plant-material and biological samples. *J Agric Food Chem*. 1995;43(3):691–699.
- Edgar JA, Colegate SM, Boppre M, Molyneux RJ. Pyrrolizidine alkaloids in food: a spectrum of potential health consequences. *Food Addit Contam Part A Chem Anal Control Expo Risk Assess*. 2011;28(3):308–324.
- Wang X, Howell CP, Chen F, Yin J, Jiang Y. Gossypol – a polyphenolic compound from cotton plant. *Adv Food Nutr Res*. 2009;58:215–263.
- Smith HA. The pathology of gossypol poisoning. *Am J Pathol*. 1957;33(2):353–365.
- Hudson LM, Kerr LA, Maslin WR. Gossypol toxicosis in a herd of beef calves. *J Am Vet Med Assoc*. 1988;192(9):1303–1305.
- Reiser R, Fu HC. The mechanism of gossypol detoxification by ruminant animals. *J Nutr*. 1962;76:215–218.
- Lindsey TO, Hawkins GE, Guthrie LD. Physiological responses of lactating cows to gossypol from cottonseed meal rations. *J Dairy Sci*. 1980;63(4):562–573.
- Hassan ME, Smith GW, Ott RS, et al. Reversibility of the reproductive toxicity of gossypol in periparturient bulls. *Theriogenology*. 2004;61(6):1171–1179.
- Zelski RZ, Rothwell JT, Moore RE, Kennedy DJ. Gossypol toxicity in preruminant calves. *Aust Vet J*. 1995;72(10):394–398.
- Risco CA, Holmberg CA, Kutches A. Effect of graded concentrations of gossypol on calf performance: toxicological and pathological considerations. *J Dairy Sci*. 1992;75(10):2787–2798.
- Risco CA, Chenoweth PJ, Larsen RE, et al. The effect of gossypol in cottonseed meal on performance and on hematological and semen traits in postpubertal Brahman bulls. *Theriogenology*. 1993;40(3):629–642.

45. Hron RJ, Kim HL, Calhoun MC, Fisher GS. Determination of (+)-, (-)-, and total gossypol in cottonseed by high-performance liquid chromatography. *J Am Oil Chem Soc.* 1999;76(11):1351–1355.
46. Callaway TR, Edrington TS, Rychlik JL, et al. Ionophores: their use as ruminant growth promotants and impact on food safety. *Curr Issues Intest Microbiol.* 2003;4(2):43–51.
47. Erickson GE, Milton CT, Fanning KC, et al. Interaction between bunk management and monensin concentration on finishing performance, feeding behavior, and ruminal metabolism during an acidosis challenge with feedlot cattle. *J Anim Sci.* 2003;81(11):2869–2879.
48. Duffield TF, Bagg RN. Use of ionophores in lactating dairy cattle: a review. *Can Vet J.* 2000;41(5):388–394.
49. Wentink GH, Vente JP. Monensin poisoning in dairy cattle. Report of a case (author's transl). *Tijdschr Diergeneeskde.* 1981;106(12):623–625. Dutch.
50. Wardrope DD, Macleod NS, Sloan JR. Outbreak of monensin poisoning in cattle. *Vet Rec.* 1983;112(24):560–561.
51. Potter EL, VanDuyne RL, Cooley CO. Monensin toxicity in cattle. *J Anim Sci.* 1984;58(6):1499–1511.
52. Van Vleet JF, Amstutz HE, Weirich WE, Rebar AH, Ferrans VJ. Clinical, clinicopathologic, and pathologic alterations in acute monensin toxicosis in cattle. *Am J Vet Res.* 1983;44(11):2133–2144.
53. Varga A, Schober KE, Holloman CH, Stromberg PC, Lakritz J, Rings DM. Correlation of serum cardiac troponin I and myocardial damage in cattle with monensin toxicosis. *J Vet Intern Med.* 2009;23(5):1108–1116.
54. Litwak KN, McMahan A, Lott KA, Lott LE, Koenig SC. Monensin toxicosis in the domestic bovine calf: a large animal model of cardiac dysfunction. *Contemp Top Lab Anim Sci.* 2005;44(3):45–49.
55. Hosie BD, Rollo DG. Nutritional myopathy in cattle associated with monensin toxicosis. *Vet Rec.* 1985;116(5):132–133.
56. Huang M, Rumbelha WK, Braselton WE, Johnson M. Rapid quantification of ionophores in feeds by liquid chromatography-tandem mass spectrometry. *J Vet Diagn Invest.* 2011;23(5):956–961.
57. Langston VC, Galey FD, Lovell RA, Buck WB. Toxicity and therapeutics of monensin: a review. *Vet Med.* 1985;80(10):75–84.
58. Plumb DC. Tetracycline HCL. In: Plumb DC, editor. *Plumb's Veterinary Drug Handbook.* 5th ed. Ames, IO: Wiley-Blackwell Publishing; 2005:741–745.
59. Spears JW. Micronutrients and immune function in cattle. *Proc Nutr Soc.* 2000;59(4):587–594.
60. Steffen DJ, Carlson MP, Casper HH. Copper toxicosis in suckling beef calves associated with improper administration of copper oxide boluses. *J Vet Diagn Invest.* 1997;9(4):443–446.
61. Galey FD, Maas J, Tronstad RJ, et al. Copper toxicosis in two herds of beef calves following injection with copper disodium edetate. *J Vet Diagn Invest.* 1991;3(3):260–263.
62. Blakley BR, Berezowski JA, Schiefer HB, Armstrong KR. Chronic copper toxicity in a dairy cow. *Can Vet J.* 1982;23(6):190–192.
63. Sullivan JM, Janovitz EB, Robinson FR. Copper toxicosis in veal calves. *J Vet Diagn Invest.* 1991;3(2):161–164.
64. Bohman VR, Poole SC, Kvasnicka WG, Tronstad RJ, Collinson RW. The toxicology and composition of bovine tissues after parenteral administration of high levels of copper salts. *Vet Hum Toxicol.* 1987;29(4):307–312.
65. Bidewell CA, Drew JR, Payne JH, Sayers AR, Higgins RJ, Livesey CT. Case study of copper poisoning in a British dairy herd. *Vet Rec.* 2012;170(18):464.
66. Bradley CH. Copper poisoning in a dairy herd fed a mineral supplement. *Can Vet J.* 1993;34(5):287–292.
67. Minervino AH, Barrêto Júnior RA, Ferreira RN, et al. Clinical observations of cattle and buffalos with experimentally induced chronic copper poisoning. *Res Vet Sci.* 2009;87(3):473–478.
68. Perrin DJ, Schiefer HB, Blakley BR. Chronic copper toxicity in a dairy herd. *Can Vet J.* 1990;31(9):629–632.
69. Lopez-Alonso M, Crespo A, Miranda M, Castillo C, Hernandez J, Benedito JL. Assessment of some blood parameters as potential markers of hepatic copper accumulation in cattle. *J Vet Diagn Invest.* 2006;18(1):71–75.
70. Melton LA, Tracy ML, Moller G. Screening trace elements and electrolytes in serum by inductively-coupled plasma emission spectrometry. *Clin Chem.* 1990;36:247–250.
71. Puschner B, Thurmond MC, Choi YK. Influence of age and production type on liver copper concentrations in calves. *J Vet Diagn Invest.* 2004;16(5):382–387.
72. Sharpe RT, Livesey CT. Lead poisoning in cattle and its implications for food safety. *Vet Rec.* 2006;159(3):71–74.
73. Baars AJ, van Beek H, Visser IJ, et al. Lead intoxication in cattle: a case report. *Food Addit Contam.* 1992;9(4):357–364.
74. Waldner C, Checkley S, Blakley B, Pollock C, Mitchell B. Managing lead exposure and toxicity in cow-calf herds to minimize the potential for food residues. *J Vet Diagn Invest.* 2002;14(6):481–486.
75. Dwivedi SK, Dey S, Swarup D. Lead in blood and milk from urban Indian cattle and buffalo. *Vet Hum Toxicol.* 1995;37(5):471–472.
76. Oskarsson A, Jorhem L, Sundberg J, Nilsson NG, Albanus L. Lead poisoning in cattle – transfer of lead to milk. *Sci Total Environ.* 1992;111(2–3):83–94.
77. Yabe J, Nakayama SM, Ikenaka Y, Muzandu K, Ishizuka M, Umemura T. Uptake of lead, cadmium, and other metals in the liver and kidneys of cattle near a lead-zinc mine in Kabwe, Zambia. *Environ Toxicol Chem.* 2011;30(8):1892–1897.
78. Oskarsson A, Jorhem L, Sundberg J, Nilsson NG, Albanus L. Lead poisoning in cattle – transfer of lead to milk. *Sci Total Environ.* 1992;111(2–3):83–94.
79. Mavangira V, Evans TJ, Villamil JA, Hahn AW, Chigerwe M, Tyler JW. Relationships between demographic variables and lead toxicosis in cattle evaluated at North American veterinary teaching hospitals. *J Am Vet Med Assoc.* 2008;233(6):955–959.
80. Krametter-Froetscher R, Tataruch F, Hauser S, Leschnik M, Url A, Baumgartner W. Toxic effects seen in a herd of beef cattle following exposure to ash residues contaminated by lead and mercury. *Vet J.* 2007;174(1):99–105.
81. Ozmen O, Mor F. Acute lead intoxication in cattle housed in an old battery factory. *Vet Hum Toxicol.* 2004;46(5):255–256.
82. Baker JC. Lead poisoning in cattle. *Vet Clin North Am Food Anim Pract.* 1987;3(1):137–147.
83. Miranda M, Lopez-Alonso M, Garcia-Partida P, Velasco J, Benedito JL. Long-term follow-up of blood lead levels and haematological and biochemical parameters in heifers that survived an accidental lead poisoning episode. *J Vet Med A Physiol Pathol Clin Med.* 2006;53(6):305–310.
84. Lead poisoning in cattle associated with car batteries and sump oil. *Vet Rec.* 2011;169(7):173–176.
85. O'Hara TM, Bennett L, McCoy CP, Jack SW, Fleming S. Lead poisoning and toxicokinetics in a heifer and fetus treated with CaNa₂ EDTA and thiamine. *J Vet Diagn Invest.* 1995;7(4):531–537.
86. Little PB, Sorensen DK. Bovine polioencephalomalacia, infectious embolic meningoencephalitis, and acute lead poisoning in feedlot cattle. *J Am Vet Med Assoc.* 1969;155(12):1892–1903.
87. Spears JW, Lloyd KE, Fry RS. Tolerance of cattle to increased dietary sulfur and effect of dietary cation-anion balance. *J Anim Sci.* 2011;89(8):2502–2509.
88. Haydock D. Sulfur-induced polioencephalomalacia in a herd of rotationally grazed beef cattle. *Can Vet J.* 2003;44(10):828–829.
89. Beke GJ, Hironaka R. Toxicity to beef cattle of sulfur in saline well water: a case study. *Sci Total Environ.* 1991;101(3):281–290.
90. McKenzie RA, Carmichael AM, Schibrowski ML, Duigan SA, Gibson JA, Taylor JD. Sulfur-associated polioencephalomalacia in cattle grazing plants in the Family Brassicaceae. *Aust Vet J.* 2009;87(1):27–32.
91. Dahme E, Bilzer T, Dirksen G. Neuropathology of manure gas poisoning (H₂S poisoning) in cattle. *Dtsch Tierarztl Wochenschr.* 1983;90(8):316–320. German.

92. Felix TL, Weiss WP, Fluharty FL, Loerch SC. Effects of copper supplementation on feedlot performance, carcass characteristics, and rumen sulfur metabolism of growing cattle fed diets containing 60% dried distillers grains. *J Anim Sci.* 2012;90(8):2710–2716.
93. Gould DH. Polioencephalomalacia. *J Anim Sci.* 1998;76(1):309–314.
94. Miller WJ. Zinc nutrition of cattle: a review. *J Dairy Sci.* 1970;53(8):1123–1135.
95. Graham TW, Thurmond MC, Clegg MS, et al. An epidemiologic study of mortality in veal calves subsequent to an episode of zinc toxicosis on a California veal calf operation using zinc sulfate-supplemented milk replacer. *J Am Vet Med Assoc.* 1987;190(10):1296–1301.
96. Lopez Alonso M, Benedito JL, Miranda M, Castillo C, Hernandez J, Shore RF. Arsenic, cadmium, lead, copper and zinc in cattle from Galicia, NW Spain. *Sci Total Environ.* 2000;246(2–3):237–248.
97. Graham TW, Goodger WJ, Christiansen V, Thurmond MC. Economic losses from an episode of zinc toxicosis on a California veal calf operation using a zinc sulfate-supplemented milk replacer. *J Am Vet Med Assoc.* 1987;190(6):668–671.
98. Runnegar MT, Kong S, Berndt N. Protein phosphatase inhibition and in vivo hepatotoxicity of microcystins. *Am J Physiol.* 1993;265(2 Pt 1):G224–G230.
99. Puschner B, Galey FD, Johnson B, et al. Blue-green algae toxicosis in cattle. *J Am Vet Med Assoc.* 1998;213(11):1605–1607, 1571.
100. Galey FD, Beasley VR, Carmichael WW, Kleppe G, Hooser SB, Haschek WM. Blue-green algae (*Microcystis aeruginosa*) hepatotoxicosis in dairy cows. *Am J Vet Res.* 1987;48(9):1415–1420.
101. Mereish KA, Solow R. Effect of antihepatotoxic agents against microcystin-LR toxicity in cultured rat hepatocytes. *Pharm Res.* 1990;7(3):256–259.
102. Orr PT, Jones GJ, Hunter RA, Berger K. Exposure of beef cattle to sub-clinical doses of *Microcystis aeruginosa*: toxin bioaccumulation, physiological effects and human health risk assessment. *Toxicol.* 2003;41(5):613–620.
103. Orr PT, Jones GJ, Hunter RA, Berger K, De Paoli DA, Orr CLA. Ingestion of toxic *Microcystis aeruginosa* by dairy cattle and the implications for microcystin contamination of milk. *Toxicol.* 2001;39(12):1847–1854.
104. Filigenzi MS, Poppenga RH, Tiwary AK, Puschner B. Determination of alpha-amanitin in serum and liver by multistage linear ion trap mass spectrometry. *J Agric Food Chem.* 2007;55(8):2784–2790.
105. Puschner B, Wegenast C. Mushroom poisoning cases in dogs and cats: diagnosis and treatment of hepatotoxic, neurotoxic, gastroenterotoxic, nephrotoxic, and muscarinic mushrooms. *Vet Clin North Am Small Anim Pract.* 2012;42(2):375–387, viii.
106. Yee MM, Woods LW, Poppenga RH, Puschner B. Amanitin intoxication in two beef calves in California. *J Vet Diagn Invest.* 2012;24(1):241–244.
107. Lindell TJ, Weinberg F, Morris PW, Roeder RG, Rutter WJ. Specific inhibition of nuclear RNA polymerase II by alpha-amanitin. *Science.* 1970;170(3956):447–449.
108. Puschner B, Rose HH, Filigenzi MS. Diagnosis of Amanita toxicosis in a dog with acute hepatic necrosis. *J Vet Diagn Invest.* 2007;19(3):312–317.
109. Riffkin GG, Hucker DA, McLoed IK. Water deprivation in agisted cattle. *Aust Vet J.* 1981;57(11):532–533.
110. Hogan JP, Petherick JC, Phillips CJ. The physiological and metabolic impacts on sheep and cattle of feed and water deprivation before and during transport. *Nutr Res Rev.* 2007;20(1):17–28.
111. Pringle JK, Berthiaume LM. Hyponatremia in calves. *J Vet Intern Med.* 1988;2(2):66–70.
112. Trueman KF, Clague DC. Sodium chloride poisoning in cattle. *Aust Vet J.* 1978;54(2):89–91.
113. Osweiler GD, Carr TF, Sanderson TP, Carson TL, Kinker JA. Water deprivation – sodium ion toxicosis in cattle. *J Vet Diagn Invest.* 1995;7(4):583–585.
114. Guitart R, Croubels S, Caloni F, et al. Animal poisoning in Europe. Part 1: Farm livestock and poultry. *Vet J.* 2010;183(3):249–254.
115. Giorgi M, Mengozzi G. Malicious animal intoxications: poisoned baits. *Vet Med (Praha).* 2011;56(4):173–179.
116. Pass MA, Stewart C. Administration of activated charcoal for the treatment of lantana poisoning of sheep and cattle. *J Appl Toxicol.* 1984;4(5):267–269.
117. Kobel W, Sumner DD, Campbell JB, Hudson DB, Johnson JL. Protective effect of activated charcoal in cattle poisoned with atrazine. *Vet Hum Toxicol.* 1985;27(3):185–188.
118. Joubert JP, Schultz RA. The treatment of *Moraea polystachya* (Thunb) KER-GAWL (cardiac glycoside) poisoning in sheep and cattle with activated charcoal and potassium chloride. *J S Afr Vet Assoc.* 1982;53(4):249–253.
119. Plumb DC. Charcoal, activated. In: *Plumb's Veterinary Drug Handbook*. Ames, IO: Wiley-Blackwell Publishing; 2005:216–217.
120. Pasricha PJ. Treatment of disorders of bowel motility and water flux; antiemetics; agents used in biliary and pancreatic disease. In: Brunton LL, Lazo JS, Parker KL, editors. *The Pharmacological Basis of Therapeutics*. 11th ed. New York, NY: McGraw-Hill Professional; 2005:989–995.

Veterinary Medicine: Research and Reports

Publish your work in this journal

Veterinary Medicine: Research and Reports is an international, peer-reviewed, open access journal publishing original research, case reports, editorials, reviews and commentaries on all areas of veterinary medicine. The manuscript management system is completely online and includes a very quick and fair peer-review system.

Submit your manuscript here: <http://www.dovepress.com/veterinary-medicine-research-and-reports-journal>

Dovepress

Visit <http://www.dovepress.com/testimonials.php> to read real quotes from published authors.