

Sensitivity and specificity of the iVue iWellnessExam™ in detecting retinal and optic nerve disorders

Catherine Awad¹
Samantha Slotnick^{2,3}
Sanjeev Nath⁴
Jerome Sherman²⁻⁴

¹Nova Southeastern College of Optometry, Fort Lauderdale-Davie, FL, ²SUNY State College of Optometry, ³SUNY Eye Institute, ⁴Eye Institute and Laser Center, New York, NY, USA

Background: The purpose of this study was to assess the specificity and sensitivity of the iWellnessExam™ screening protocol available on iVue® spectral domain optical coherence tomography (SD-OCT), in a cohort of confirmed normal subjects and subjects with confirmed disease.

Methods: In total, 126 of 132 confirmed normal subjects and 101 of 107 subjects with confirmed disease were included for analysis. Of the patients with confirmed disease, 67 had retinal disease, 50 had optic nerve disease, and 16 had both retinal and optic nerve pathology. All subjects were screened on the iWellnessExam protocol. Screen shots of the OD, OS, and OU comparison data were obtained and deidentified for reviewer analysis. Based on these data alone, each subject was sorted by a well trained eye care clinician into one of four categories (1, normal; 2, retinal disease; 3, optic nerve disease; 4, retinal and optic nerve disease).

Results: Of the confirmed normal subjects, 125 of 126 were correctly identified as normal (specificity 99%). Retinal and/or optic nerve disease was correctly detected in 97 of 101 patients with confirmed disease (category 2, 3, 4), retinal pathology was correctly detected in 64 of 67 patients with retinal disease (category 2, 4), and optic nerve pathology was properly detected in 45 of 50 patients with optic nerve disease (category 3, 4), with a sensitivity of 96%, 95.5%, and 90%, respectively.

Conclusion: The iWellnessExam offers the health care provider an excellent method for identifying eyes at risk using very reliable technology. High specificity and sensitivity was obtained when reviewed by a well trained eye care clinician. It would be valuable to repeat the study with a novice and/or student clinician reviewing the same data set to ascertain interobserver variability, as well as the impact of clinical experience on accurate referral, based on the screening data.

Keywords: epidemiology, ganglion cell complex, glaucoma, macula, nonglaucomatous optic neuropathy, screening, spectral domain optical coherence tomography

Introduction

The iVue® spectral domain optical coherence tomography (SD-OCT) device (Optovue Inc, Fremont, CA) contains a screening protocol, the iWellnessExam™, which obtains data on both retinal and optic nerve integrity with a single scan of the posterior pole. The patient can be situated and have both eyes screened in about one minute. The program obtains eight high-resolution cross-sectional images of the retina over a 7 mm × 7 mm area. It also segments the retina into inner and outer layers, providing a thickness assessment of the ganglion cell complex. The ganglion cell complex is comprised of ganglion cell bodies, their axons (ie, the retinal nerve fiber layer), and their dendrites (ie, the inner plexiform layer). This provides a measure of the integrity of the ganglion cells

Correspondence: Jerome Sherman
SUNY State College of Optometry,
33 W 42nd St, 11th Floor, New York,
NY 10036, USA
Tel +1 212 938 5862
Email j.sherman@sunyopt.edu

originating in the macula, with implications for glaucoma^{1–10} and other nonglaucomatous optic neuropathies, as well as retinal pathology affecting the inner retinal layer.

SD-OCT technology is already acknowledged to provide data at a finer level of detail than clinical ophthalmoscopy.^{11–15} Segmentation of the retina into inner and outer retinal components enables a quantitative assessment of the ganglion cells over the entire macula. This ganglion cell complex has been shown to provide an indication of optic nerve integrity.^{1–5,16,17} Early recognition of retinal abnormalities and/or optic nerve disease may lead to earlier diagnosis, treatment, and management of sight-threatening diseases.

The present study was designed to measure the specificity and sensitivity of the iWellnessExam screening protocol in a cohort of confirmed normal subjects and subjects with confirmed disease. Specificity data were obtained by evaluating patients within the primary care clinic at the University Eye Center, SUNY State College of Optometry, who were determined to be without retinal or optic nerve disease (confirmed normal subjects). Sensitivity data were obtained by evaluating patients within the Ocular Disease and Special Testing Service at the University Eye Center with known central retinal and/or optic nerve disorders (subjects with confirmed disease). All glaucoma suspects were excluded from evaluation.

Potential applications of the iWellnessExam screening software include detection of glaucomatous and nonglaucomatous optic neuropathies, and detection of retinal abnormalities such as diabetic retinopathy, hypertensive retinopathy, age-related macular degeneration, central serous chorioretinopathy, pigment epithelial detachment, retinal detachment, epiretinal membrane, macular hole, and retinoschisis extending into the posterior pole.

Materials and methods

Two groups of patients were examined, ie, a confirmed normal cohort for the specificity aspect of the study and a confirmed disease cohort for the sensitivity aspect. A total of 126 of the 132 confirmed normal subjects and 101 of the 107 subjects with confirmed disease were included for analysis. Of the patients with confirmed disease, 67 had retinal pathology and 50 had optic nerve pathology. Sixteen patients fell into both categories, with both retinal and optic nerve pathology.

For purposes of accurate sensitivity and specificity assessment, efforts were made to reduce ambiguity when confirming subjects in either the normal or disease categories. Subjects entering the specificity arm of the study were ineligible for recategorization into the sensitivity arm, in the event that

a disorder was detected on optical coherence tomography screening. Any subjects suspected of having glaucoma were excluded from evaluation, because their status as a normal or as a subject with optic nerve pathology could not be clearly established. Any presumed normal subjects who were referred as a result of the screening were also excluded.

Three different researchers, ie, CA, JS, and a trained technician obtained scans. Up to three scans were taken per eye. In most cases, it was possible to achieve a scan quality index of “good” in both eyes with a single scan. In some cases of severe retinal distortion or pathological myopia, it was not possible to improve upon scan quality. The OD, OS, and OU reports were printed from the best scan available.

Data were obtained utilizing the iVue SD-OCT, which scans at 26,000 A-scans per second with an axial resolution of 5 microns.¹⁸ All analyses were made utilizing the iWellnessExam, a one-step SD-OCT screening protocol, which images a 7 mm × 7 mm area of the posterior pole centered on the fovea. The iWellnessExam report provides eight high-resolution cross-sectional retinal images, along with its data analysis results, comprising a full retinal thickness map, a ganglion cell complex map, and a report on superior/inferior symmetry within the eye, and symmetry between eyes.

Those subjects who were classified as having a clinically normal healthy retina and optic nerve head who then demonstrated an abnormal iWellnessExam screening as part of the study were brought to the attention of the attending clinician for further evaluation.

Utilizing the RTvue ganglion cell complex analysis software, Tan et al found a ganglion cell complex mean thickness of $94.8 \pm 7.5 \mu\text{m}$ in a normal population (sample size of 65 individuals, 125 eyes included for study).¹⁹ These data were used for a normative comparison, taking two standard deviations as abnormal (average ganglion cell complex thickness $< 80 \mu\text{m}$). Intraocular and interocular symmetry were also evaluated. Tan et al report an intraocular superior/inferior ganglion cell complex thickness difference with a 95% confidence interval of -2.4 to $9.2 \mu\text{m}$.¹⁹ Budenz assessed interocular symmetry in 108 normal patients, concluding that the mean retinal nerve fiber layer thickness should not differ by $>9\text{--}12 \mu\text{m}$ (depending on the scanning algorithm used).²⁰ For the purposes of this study, any interocular or intraocular asymmetry $> 10 \mu\text{m}$ was considered optic nerve pathology. These data were used as guidelines (ie, ganglion cell complex thickness $< 80 \mu\text{m}$ and $>10 \mu\text{m}$ superior/inferior or OD/OS asymmetry), with room for clinical interpretation by the expert reviewer.

Images were acquired on two iVue systems, ie, confirmed normal subjects were screened in the primary care clinic and subjects with confirmed disease were screened by the Ocular Disease and Special Testing Service. Subjects were assigned randomized code numbers in order to assure non-consecutive image review (by code number rather than by subject number).

For each subject, OD, OS, and OU onscreen displays were captured and deidentified for review by a well trained clinician (JS). The OD and OS displays feature eight high-resolution retinal sections through the macula (seven horizontal, one vertical), the full retinal thickness map (7 mm × 7 mm), and the ganglion cell complex thickness map (6 mm × 6 mm). The OU displays feature four retinal sections (horizontal and vertical through the fovea of each eye), full retinal thickness and ganglion cell complex thickness maps, along with numerical data on ganglion cell complex thickness, highlighting interocular and intraocular asymmetry.

Once the data acquisition phase was complete, the images were reviewed by JS and classified into one of four categories (1, normal; 2, retinal disease; 3, optic nerve disease; 4, retinal and optic nerve disease). The image review was conducted in five separate sittings.

Representative deidentified data sets are displayed for each of the categories (category 1, normal, Figure 1; category 2, retinal disease only, Figures 2 and 3; category 3, optic nerve disease only, Figures 4 and 5; category 4, retinal and optic nerve disease, Figure 6). See the Discussion section for scan analysis.

Results

A total of 126 confirmed normal subjects and 101 subjects with confirmed disease were included for analysis (see Table 1 for demographics of subjects by gender, ethnicity, and age). A significant difference in the age of the two groups is apparent, but the examiner was blind to any

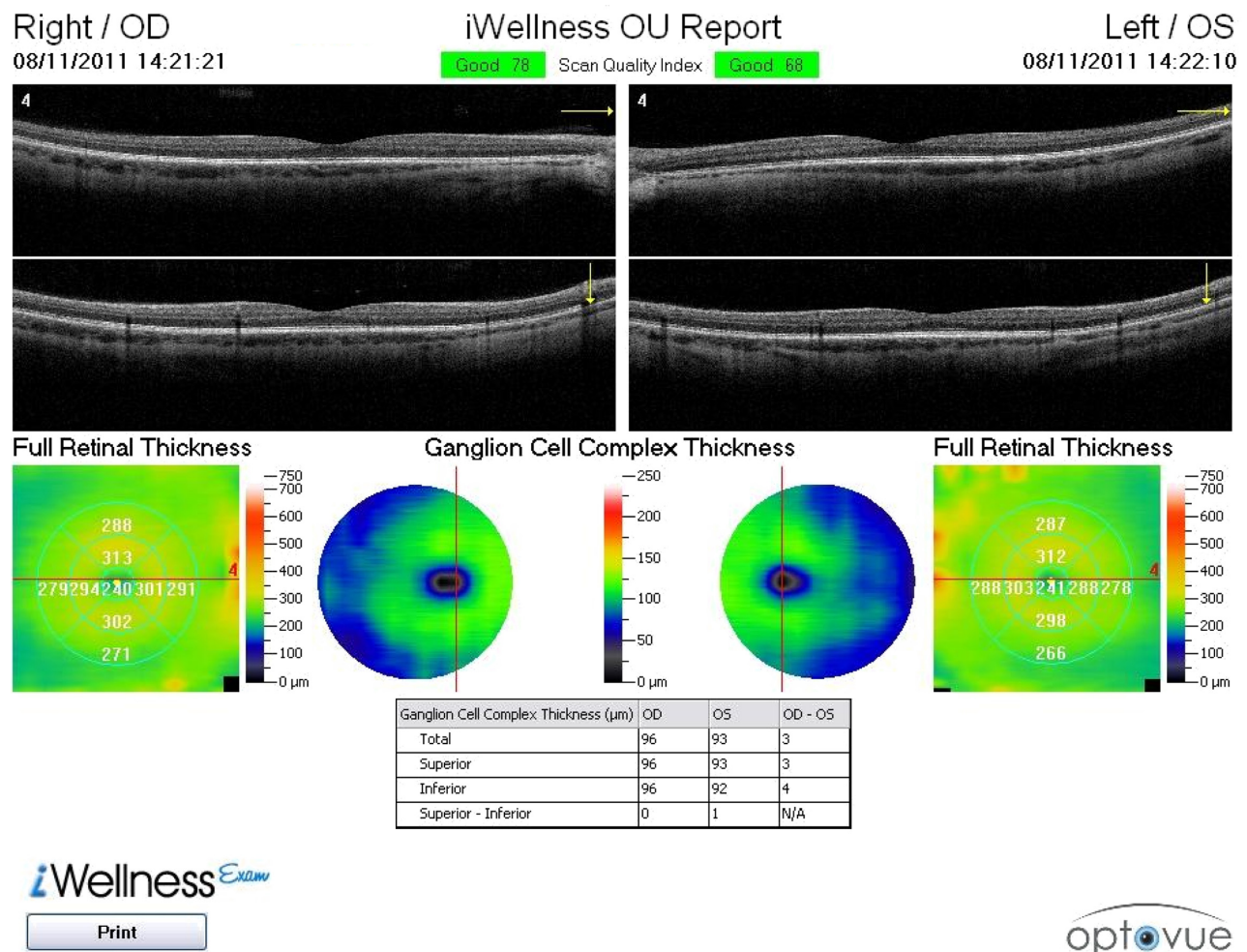


Figure 1 Category 1 iWellness™ OU report for subject J749, with a normal healthy retina and ganglion cell complex.

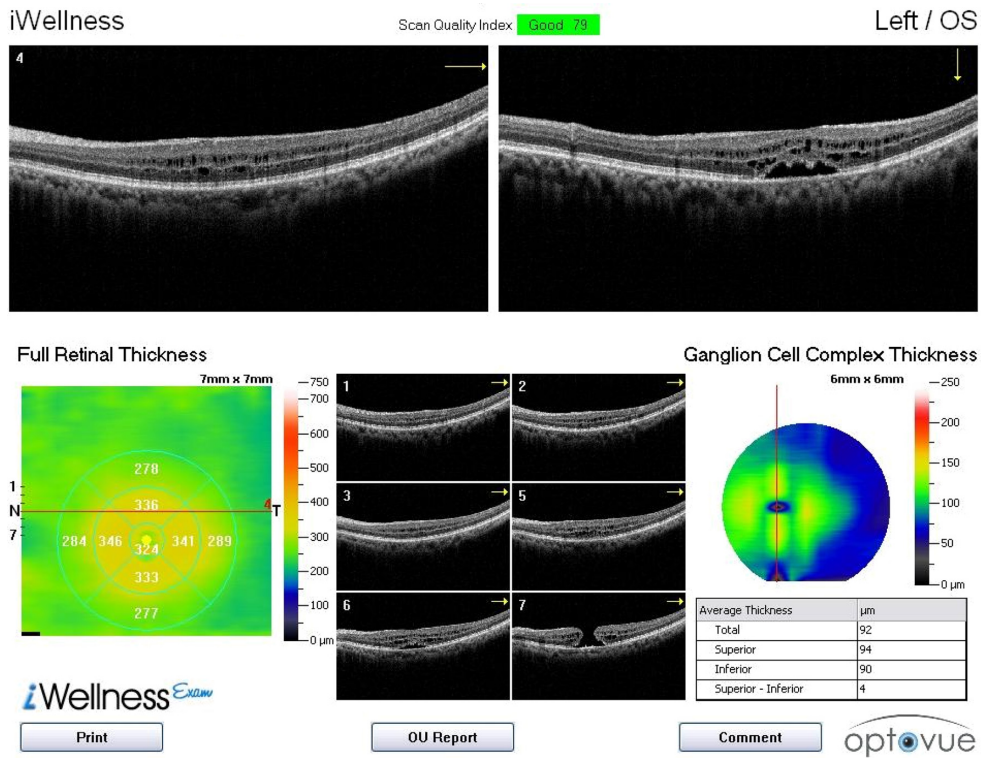


Figure 2 Category 2 iWellnessExam™ report OS for subject J893.

Notes: Monocular report provides multiple high-resolution sections through the macula, in which both retinoschisis and a macular hole (scan 7) OS are identifiable. Despite the thickened central volume on the full retinal thickness map, the ganglion cell complex maintains its integrity and appears intact in the optical coherence tomography scans, with normal thickness shown on the ganglion cell complex map. See OU report, Figure 3.

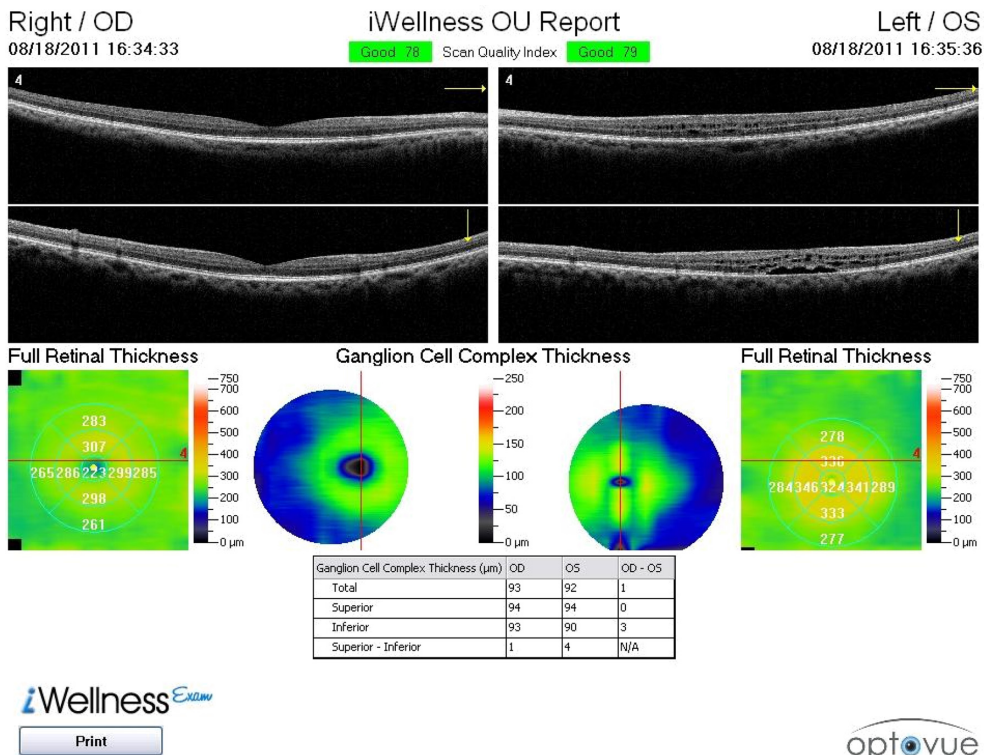


Figure 3 Category 2 iWellness™ OU report for subject J893.

Notes: Retained symmetry of ganglion cell complex OD/OS, despite central retinal elevation with retinoschisis OS. In this case, the OU report helps to rule out the likelihood of optic nerve disease while simultaneously documenting retinal disease.

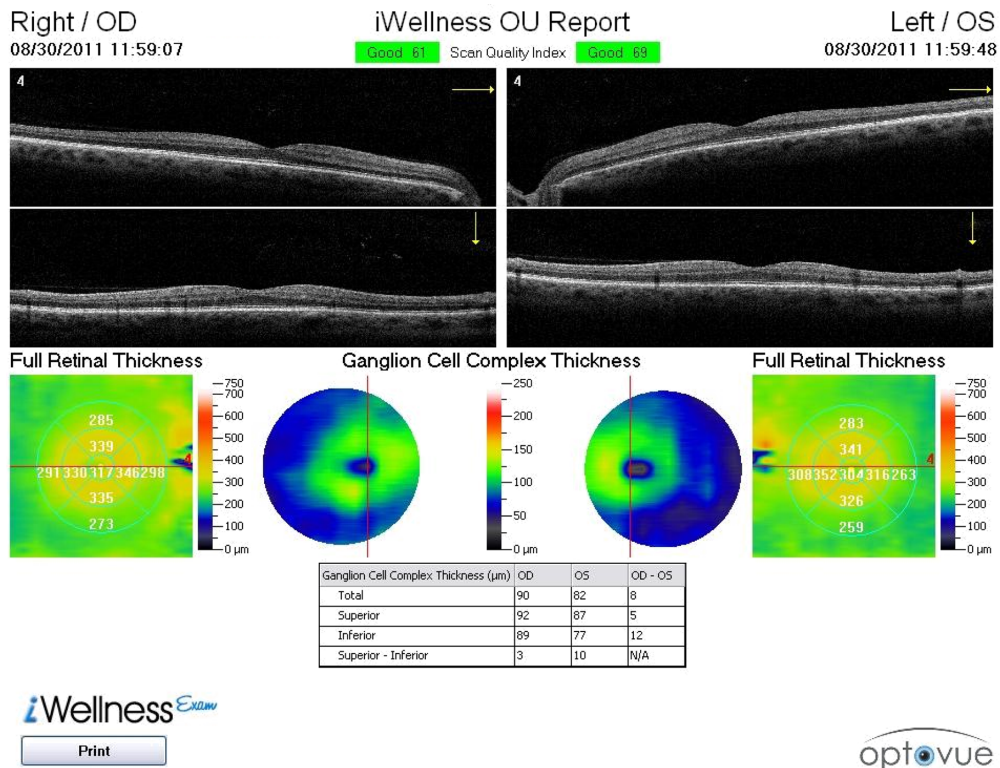


Figure 4 Category 3 iWellness™ OU report for subject J835.

Notes: 10 micron superior/inferior asymmetry OS, and 12 micron inferior asymmetry OD/OS. In this case, the OU report highlights the asymmetry both within the OS and between OD/OS. No retinal disease is apparent. See OS report, Figure 5.

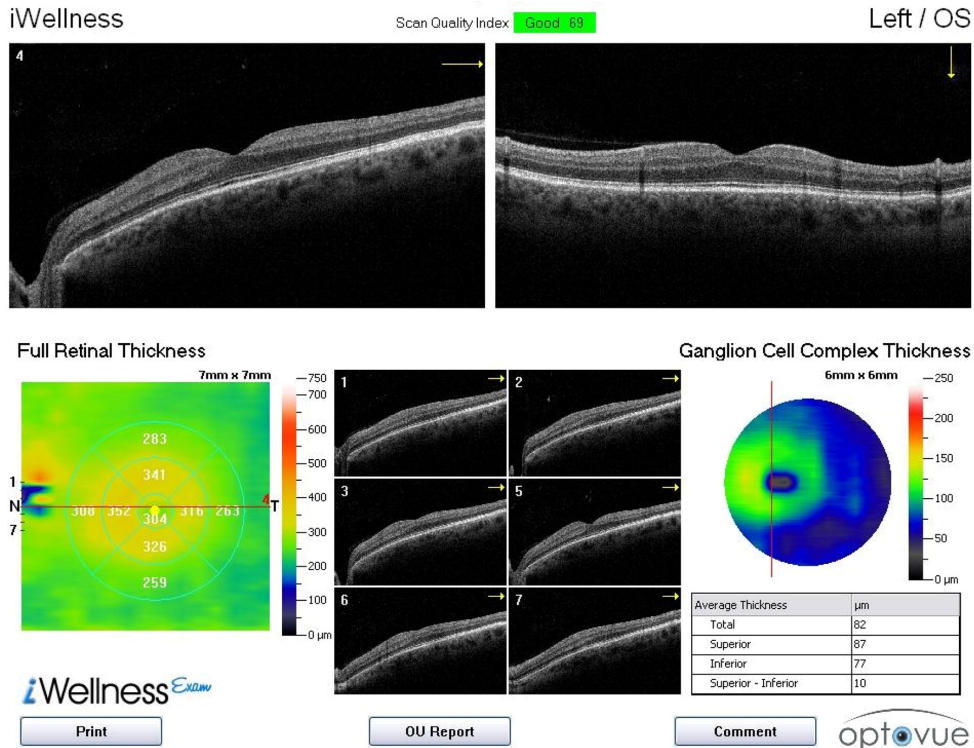


Figure 5 Category 3 iWellness™ report OS for subject J835.

Notes: The high-resolution scans through the macula support the reviewer's ability to assess the retina. In this case, the tilted scans depict a staphyloma, but the outer retina appears healthy, intact, and free of pathology. Hence, this subject "passed" the retinal screening but "failed" the optic nerve screening, with thinning of inferior ganglion cell complex OS (see OU report, Figure 4).

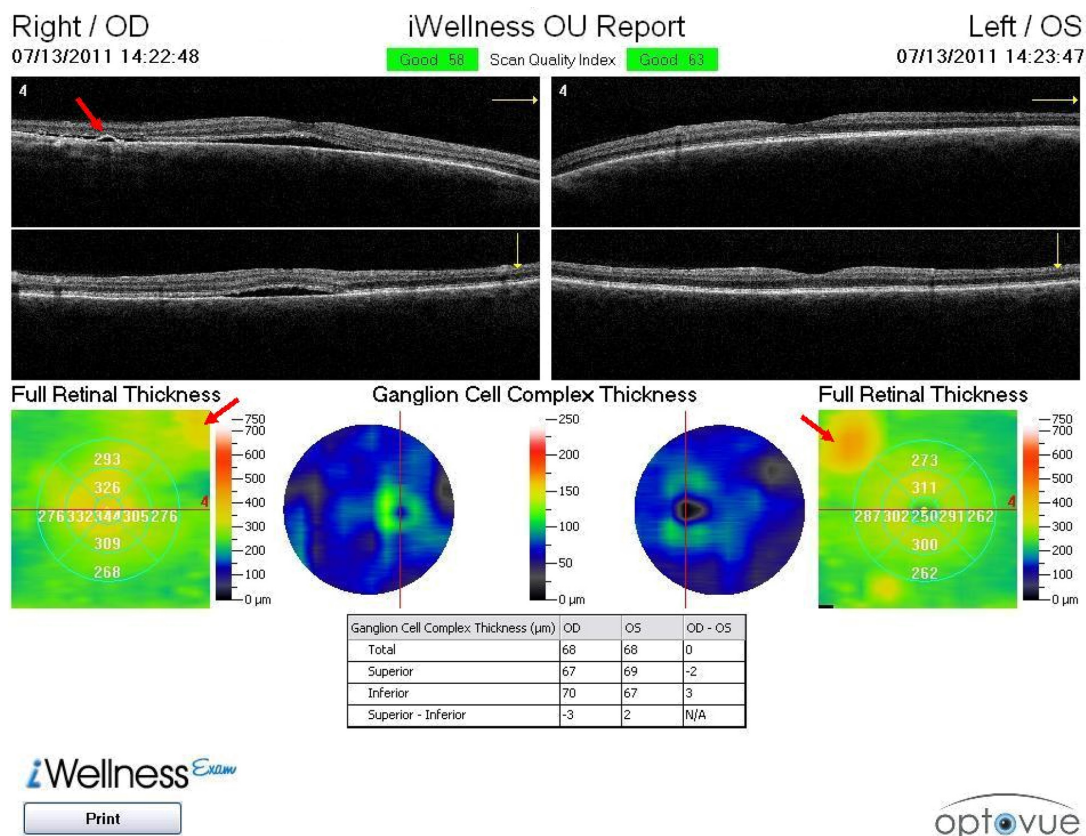


Figure 6 Category 4, iWellness™ OU report of subject J899.

Notes: OU report identifies an extremely thin ganglion cell complex OD and OS (more than 3 standard deviations below average), despite minimal intraocular or interocular asymmetry. Neurosensory retinal detachment OD is detected on both high-resolution scans displayed; pigment epithelial detachment is indicated in the horizontal scan OD, top-left, red arrow. Full retinal thickness maps show areas of retinal thickening superior nasal OD and OS (indicated by red arrows). These may also be serous detachments, which should be scanned in detail once identified on screening.

and all demographic data, including age, during image review.

Exclusions were made for nine glaucoma suspects (all six of the disease exclusions and three of the presumed normal exclusions). The iWellnessExam screening resulted in referral of three presumed normal subjects. Each of these subjects was excluded from the study. Two were referred for a retinal disease evaluation, and one as a glaucoma suspect, first identified on this screening. The reviewer correctly identified 125 of the 126 subjects as normal, and one was incorrectly identified as having optic nerve disease, yielding an iWellnessExam specificity of 99.2%.

Of the 101 subjects with confirmed disease, 51 exhibited only retinal disease (category 2), 34 subjects exhibited only optic nerve disease (category 3), and 16 subjects had both retinal and optic nerve disease. The expert reviewer correctly identified 97 of the 101 subjects with confirmed disease as having some form of ocular disease (category 2, 3, and 4, overall sensitivity 96.0%). Of the 67 subjects with retinal disease (category 2 and 4), 64 were properly

identified (retinal disease sensitivity 95.5%); of the 50 subjects with optic nerve disease (category 3 and 4), 45 were properly identified (optic nerve disease sensitivity 90.0%). Table 2 indicates the sensitivity of the iWellnessExam by disease category and the specificity of the iWellnessExam as identified by an expert reviewer without benefit of any additional clinical data. No subjects in category 2 were mis-sorted into category 3, and no subjects in category 3 were mis-sorted into category 2. Either of these would represent a “double-error”, ie, missing one disease entity and “over-referring” for the other disease entity.

Table 3 below indicates that on expert review the iWellnessExam has extremely high predictive value. There is a 98%–99% chance that patients identified as disease-positive actually have the disease in question; and there is a 96%–98% chance that patients identified as disease-negative are in fact free of the disease. The receiver operating characteristics (false positive rate, true positive rate, and accuracy) are provided in Table 3 and depicted graphically below.

Table 1 Subject demographics by gender, ethnicity, and age

Demographics	Normal	Disease	Total
Gender			
Female	94	53	147
Male	32	48	80
Ethnicity			
African American	25	54	79
Caucasian	58	16	74
Asian	29	6	35
Hispanic	12	23	35
Other	2	2	4
Age			
<35	78	5	83
36–50	22	12	34
51–65	22	39	61
66–80	3	33	36
≥81	1	12	13
Min	18	23	
Max	82	95	
Average	35.5	63.5	
SD	15.1	14.2	

An accounting of the pathologies encountered in the study sample is provided in Table 4. The screening is not sufficient for diagnosis in many cases, but provides sufficient data to indicate a problem, and to delineate whether the problem is related to the retina or optic nerve. Many of these subjects had multiple active disease conditions, and they are accounted for on each occurrence of pathology.

The cases in which the expert did not accurately classify the subject were reviewed. Misclassifications may have been due to either underdetection of or over-referral for suspicion of disease. The three retinal diseases that were not detected were one case each of cotton wool spots, dry age-related macular degeneration, and proliferative diabetic retinopathy. Two subjects with optic nerve disease were over-referred for retinal disease. Both cases were subjects in category 3 who were mis-sorted into category 4, and neither subject was normal (category 1).

Relative to the population size, there were several more errors of classification in optic nerve disease than retinal disease. As Table 5 indicates, in several of these cases, the

Table 2 iWellnessExam sensitivity and specificity, on expert review

	Sensitivity			Specificity
	Any disease	Retinal disease	Optic nerve disease	Normal
Test (+)	97	64	45	1
Test (–)	4	3	5	125
	96.0%	95.5%	90.0%	99.2%

Table 3 iVue iWellnessExam receiver operator characteristic on expert review

	Any disease	Retinal disease	Optic nerve disease
False positive rate	0.008	0.008	0.008
True positive rate	0.960	0.955	0.900
Accuracy	0.978	0.979	0.966
Positive predictive value	99.0%	98.5%	97.8%
Negative predictive value	96.9%	97.7%	96.2%

ganglion cell complex analysis was abnormal due to the presence of retinal disease. The five underdetected optic nerve diseases were optic nerve head drusen (n = 1) and glaucoma (1 misclassified as normal, three misclassified as retinal disease only, with ganglion cell complex interference). All four optic nerve disease over-referrals were sorted into category 4 rather than category 2. The presence of retinal

Table 4 Pathologies encountered

Retinal diseases identified (subjects in category 2 or 4)	
Diabetic retinopathy (DR)	14
Non-proliferative DR	11
Proliferative DR	3
Age-related macular degeneration (AMD)	16
Dry AMD	16
Wet AMD	0
Epiretinal membrane (ERM)	12
Macular hole	5
Clinically significant macular edema (CSME)	5
Clinically serous chorioretinopathy	3
Cystoid macular edema	2
Central retinal vein occlusion	4
Branch retinal vein occlusion	2
Hypertensive retinopathy	1
Myopic degeneration	8
Pigment epithelial detachment	2
Retinitis pigmentosa	2
Acute macular neuroretinopathy	1
Choroidal ectasia	1
Diffuse unilateral subacute neuroretinitis	1
Idiopathic vasculitis with hard exudates	1
Isolated, idiopathic cotton wool spot	1
Pericentral glial scar w/hemorrhage	1
Retinoschisis, macular	1
Toxoplasmosis	1
X-linked juvenile retinoschisis	1
	85
Optic nerve diseases identified (subjects in category 3 or 4)	
Glaucoma	45
Open angle glaucoma	42
Narrow angle glaucoma	2
Mixed mechanism glaucoma	1
Non-glaucomatous neuroretinopathy	3
Diffuse unilateral subacute neuroretinitis	1
Optic disc drusen	1
	50

Table 5 Accuracy in the identification of both disease conditions, on expert review

	Retinal disease	Optic nerve disease	GCC abnormal 2° to retinal disease*
Under-detected	3	5	3
Over-reported	2	4	4

Abbreviation: *GCC = Ganglion Cell Complex

disease interfered with the ability to interpret the ganglion cell complex findings accurately. It should be noted that the presence of retinal disease does not automatically confound detection of optic nerve disease.

Discussion

Scan analysis

The category 1 (normal) subject (see Figure 1) shows minimal OD/OS or superior/inferior asymmetry in the ganglion cell complex, no observable irregularity on the full retinal thickness map, and no subtle irregularities on the four cardinal SD-OCT scans (horizontal and vertical slice through each fovea). The supplementary high resolution horizontal scans, available on the OD and OS report, showed otherwise healthy retinal sections (similar to Figure 5, which also shows the monocular display on a healthy retina in a category 3 subject).

The category 2 (retinal disease only) subject (see Figure 2) has clearly identifiable retinoschisis with a full thickness macular hole OS (visible in scan 7). Displacement of the full thickness map (see Figure 2, left side, macular center is shifted downward) suggests eccentric fixation with a superior retinal locus as a result of the macular hole at the fovea. In sorting the subject into category 2, two decisions are made, ie, a “sensitivity” decision of retinal disease detection, and a “specificity” decision of the absence of optic nerve pathology. In this case, the monocular scan provides a more detailed retinal assessment for the purposes of identifying retinal disease, and the OU scan serves to rule out optic nerve disease, supported on interocular comparison (see Figure 3).

This category 3 (optic nerve disease only) subject was selected to highlight a case in which the ganglion cell complex map shows some subtle abnormalities, but the interocular and intraocular quantitative ganglion cell complex measures readily support identification of optic nerve pathology. Referring to the guidelines addressed in the Methods section, both ganglion cell complex thickness $< 80 \mu\text{m}$ and ganglion cell complex asymmetry $> 10 \mu\text{m}$ (whether OD/OS or superior/inferior) are indicative of optic nerve pathology. The ganglion cell complex maps in Figure 4 show only a subtle difference in

the shape and symmetry of the “green donut,” but clearly fails on all numerical guidelines: OS inferior thickness of $77 \mu\text{m}$, superior/inferior asymmetry OS of $10 \mu\text{m}$, and OD/OS asymmetry of $12 \mu\text{m}$ inferiorly. No retinal abnormalities are apparent in any of the eight high-resolution scans of either eye (OS shown, see Figure 5). As with category 2, sorting into category 3 requires two decisions, ie, a “sensitivity” decision about optic nerve pathology detection and a “specificity” decision about the absence of retinal disease.

The category 4 subject (with retinal and optic nerve disease) was selected to indicate the wide array of data which are made available in a single OU report (see Figure 6). The high resolution retinal sections shown OD indicate a detachment of the neurosensory retina with a small area of pigment epithelial detachment visible within the horizontal section OD (temporal, see red arrow). Additional indications of retinal disease are observable, with atypical color variations in the $7 \times 7 \text{ mm}$ full retinal thickness maps superior-nasal to the macula both OD (yellow region) and OS (yellow/orange region). The ganglion cell complex thickness maps are particularly thin (blue, with minimal “green donut” appearance OU). This is consistent with the quantitative measures of ganglion cell complex thickness $\leq 70 \mu\text{m}$ in all hemispheres. The patient shown here has central serous retinopathy OU, with a central and an eccentric zone of serous detachment OD, and with two eccentric zones of serous detachment OS. This patient also has longstanding primary open angle glaucoma OU, which has recently been complicated with the development of anterior uveitis OD and response to steroids.

Ganglion cell complex as an indicator for optic nerve disease

The macula contains more than 50% of all retinal ganglion cells.⁶ Correlations between optic nerve head retinal nerve fiber layer assessment and macular ganglion cell complex assessment indicate that the ganglion cell complex can be used to detect the early stages of glaucoma.^{21,22} Among high myopes, the ganglion cell complex demonstrated greater sensitivity for detecting early glaucoma than the retinal nerve fiber layer, particularly in the superior hemispheres.²³ In a large cohort of 315 subjects and 604 eyes, the ganglion cell complex demonstrated a greater area under the receiver operating characteristic curve than the retinal nerve fiber layer in subjects with early glaucoma, most noticeably in the inferior hemisphere.¹⁷ These findings not only indicate the utility of the ganglion cell complex, but also support the possibility that the ganglion cell complex may have a role complementary to retinal nerve fiber layer analysis regarding assessment of the

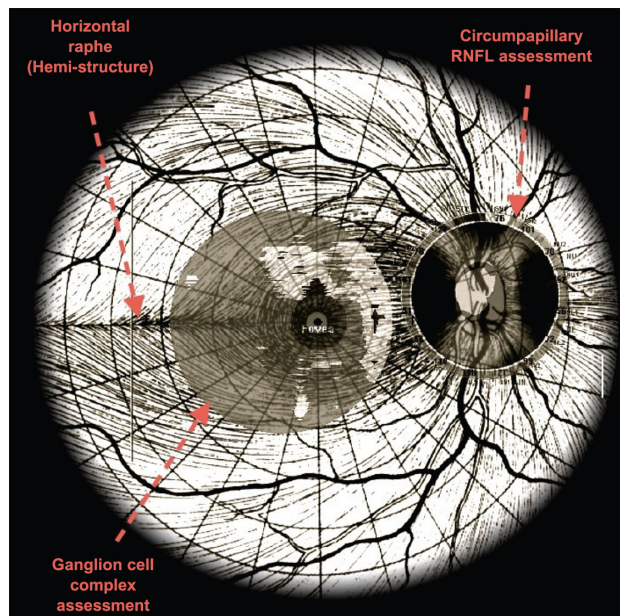


Figure 7 Ganglion cell complex measurement reflects a subset of cells different to those used for the peripapillary retinal nerve fiber layer (RNFL) assessment.

Notes: Axons at the 12 o'clock, 6 o'clock, and nasal aspects of the optic nerve head are not represented in the ganglion cell complex measurement. However, the ganglion cell complex offers a magnified assessment of cells traveling in the papillomacular bundle. This particular region often fails to reach statistical significance on retinal nerve fiber layer (RNFL) assessment, owing to the thinner caliber of axons in this region. © Reprinted with permission OptoVue.

optic nerve head, because the ganglion cell complex derives data from a different set of axons, with a greater emphasis on the papillomacular bundle (see Figure 7).²¹ Axons outside the papillomacular bundle (at the 12 o'clock, 6 o'clock, and nasal aspects of the optic nerve head) correspond to ganglion cells with cell bodies lying outside the macula;²⁴ these are not reflected in the ganglion cell complex measurement. Because the axons which travel in the papillomacular bundle are of particularly fine caliber,²⁵ the retinal nerve fiber layer has a very thin baseline thickness in the normal eye, and thus papillomacular bundle pathology often does not reach statistical significance in retinal nerve fiber layer analysis. However, when the axons of the papillomacular bundle are combined with the associated cell body measurements of the ganglion cell complex, a change in the thickness of this inner retinal segment is detectable.

Structure-function correlation is demonstrated between central visual fields (eg, 24-2 and 10-2) and the ganglion cell complex.^{4,10,16,17,22} Polar retinal nerve fiber layer projections have been demonstrated to correlate with 60-4 visual fields,²⁴ and such defects are not likely to correlate strongly with ganglion cell complex defects, because they assess a different cellular subset (Figure 7). Thus, the ganglion cell complex measurement, when evaluated in conjunction with a standard

optic nerve head-based retinal nerve fiber layer assessment, will likely increase the clinician's capacity for detection of glaucomatous and nonglaucomatous optic nerve damage.

Interpreting the ganglion cell complex in the presence of retinal pathology

Retinal disorders do have the potential to interfere with optic nerve assessment via the ganglion cell complex. When the retinal disease is limited to the outer retina, as in Figure 2, the ganglion cell complex often remains undisturbed. However, profound outer retinal distortions may disrupt the overlying inner retinal organization (see Figure 8). In such cases, inspection of the high-resolution line scans may provide a better appreciation of retinal nerve fiber layer thickness than the ganglion cell complex map or measurements. In the category 2 subject shown in Figure 8, retinal disease interferes with the retinal segmentation algorithms. The reviewing clinician observed symmetric superior/inferior retinal nerve fiber layer thickness in the vertical scan (top right), along with apparent integrity of the ganglion cell complex in horizontal slices, in order to assign this subject accurately to category 2. A well trained clinician may extrapolate from the high-resolution images on direct inspection in such cases where an irregular retina obscures proper ganglion cell complex segmentation.

Despite this, retinal disease interfered with the accuracy of ganglion cell complex assessment in seven cases, ie, three in which optic nerve disease was under-referred (category 4 subjects mis-sorted into category 2), and four in which it was over-referred (category 2 subjects mis-sorted into category 4, see Table 4).

Vitreoretinal adhesions do have the potential to interfere with optic nerve assessment via ganglion cell complex map and measurements as well. Figure 9 shows a category 2 example of an inner retinal disorder which distorts the surface of the retinal nerve fiber layer (epiretinal membrane). In this case, segmentation is fairly accurate, but traction between the vitreous and the inner retinal surface increases the thickness measurement in focal areas. Again, direct observation of the high resolution SD-OCT slices provides the well trained clinician with an opportunity to appreciate ganglion cell complex integrity despite surface irregularity. Superior/inferior symmetry is observed on the vertical scan (top right). In this OD scan, the horizontal (numbered) slices are expected to show a thicker ganglion cell complex on the nasal (right) side of the scans, because more axons project nasally than temporally towards the optic nerve head.

Distinguishing OCT abnormalities from clinically visible fundus pathology

SD-OCT may present challenges of over-referral for abnormalities which are not clinically detectable. There are a number of typical, subtle abnormalities on SD-OCT which cannot be clinically observed, either ophthalmoscopically or on retinal photographs. These include fine, solitary drusen (<20 μm transversely), subtle posterior hyaloid detachment, subtle epiretinal membrane (ie, without reflection or distortion on ophthalmoscopy), minor retinal pigment epithelial migration (ie, without macular mottling on ophthalmoscopy), and small exudates. The expert reviewer considers such findings on a continuum, with a high level of experience for the pairing of the appearance of such abnormalities on optical coherence tomography and their correlation with clinical/ophthalmoscopic presentation. It would be valuable to compare the specificity of expert evaluation with the specificity of less experienced clinicians and/or technicians.

Select retinal abnormalities due to early diabetic retinopathy are not readily observed on iVue optical coherence tomography which is insensitive to minor blood vessel abnormalities, focal arteriolar constriction, crossing changes, and small hemorrhages. Such changes are better appreciated on frontal view rather than a cross-sectional view. In addition, small hemorrhages are easier to identify by ophthalmoscopy than by optical coherence tomography. Similarly, arteriolar constrictions secondary to mild hypertensive retinopathy are better appreciated in frontal view. This clinical/technological disparity would be a known challenge for sensitivity to retinal disorders on the basis of optical coherence tomography alone. Screening via the iWellnessExam should be used to help identify those in need of further clinical evaluation, and in no way supplants clinical evaluation and judgment.

Disease specificity

The present study evaluated specificity with the traditional definition of detection of healthy status among healthy

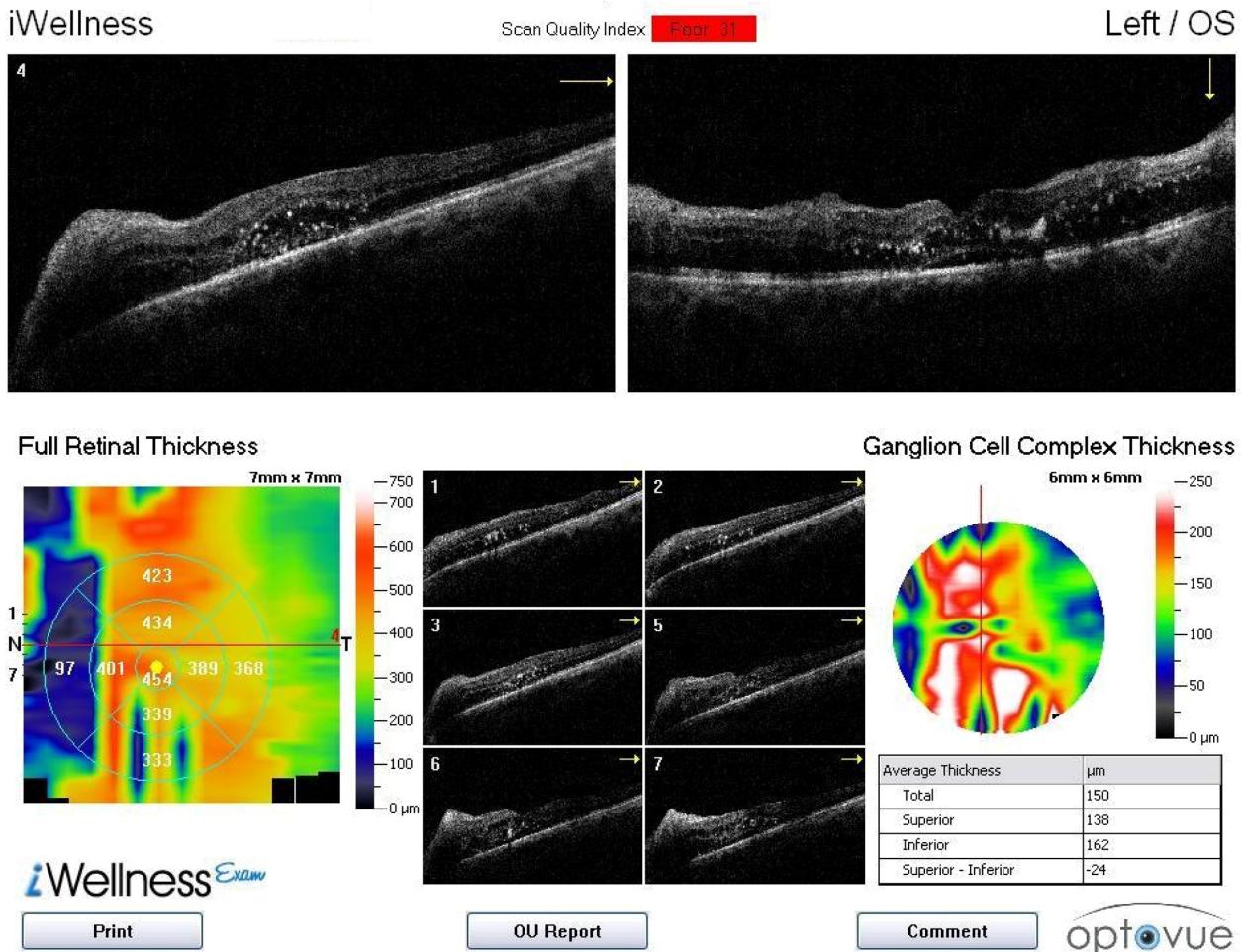


Figure 8 Category 2 subject (J728) with severe retinal distortion, interfering with retinal segmentation and ganglion cell complex thickness map and measurements.

Notes: Clinician inspects spectral domain optical coherence tomography scans directly in order to assess the retinal nerve fiber layer. Vertical slice (top-right) shows symmetric superior/inferior retinal nerve fiber layer thickness.

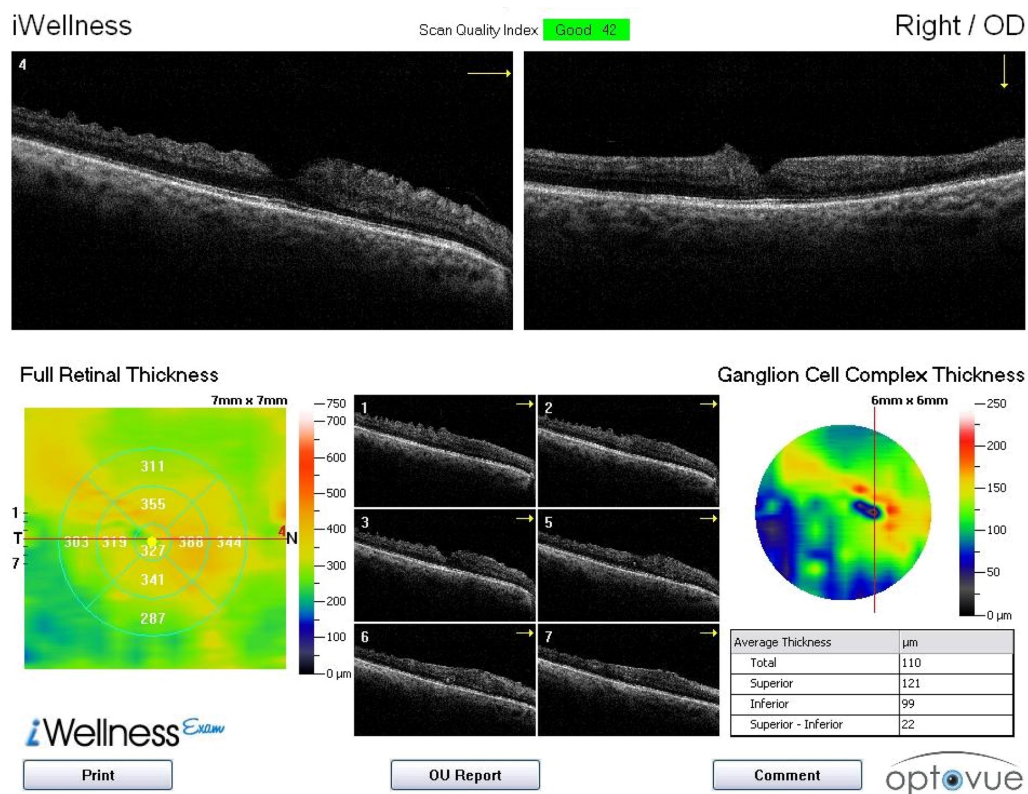


Figure 9 Category 2 subject (J911) with an epiretinal membrane and vitreomacular traction.

Notes: The traction creates an artificially thickened measurement of the ganglion cell complex, with distortions appreciated on the thickness map. Observation of the superior/inferior symmetry of the ganglion cell complex on the vertical scan (top right) and the integrity of the ganglion cell complex in the 7 (numbered) horizontal high resolution slices provides sufficient data to suggest a normal ganglion cell complex with overlying inner retinal distortion.

patients. However, the iWellnessExam offers an opportunity to detect two different disease categories simultaneously. The presence of retinal disease can and often does interfere with the ability to detect optic nerve disease accurately with this screening protocol.

Table 5 reports on the over-referral of patients for retinal disease (when they in fact had only optic nerve disease) and for optic nerve disease (when they in fact had only retinal disease). When over-referrals are considered in the disease population (as opposed to the healthy population), it mitigates the specificity of the iVue iWellnessExam screening protocol in the normal population. Another look at the data provides an opportunity to quantify over-referrals, ie, category 2 subjects who were sorted into category 4 and over-referred for optic nerve disease (four of 51, 7.8%). Category 3 subjects who were sorted into category 4 were over-referred for retinal disease (two of 34, 5.8%).

From a clinical perspective, the sensitivity of a screening protocol is more valuable than its specificity, because an effective screening process ought to lead to appropriate disease management. From a public health perspective, specificity is critical as well. Over-referrals should be avoided because they result in unnecessary

testing and may cause undue anxiety in patients returning for supplementary procedures. The iWellnessExam screening software can be used for the detection of two disease categories, each of which would be subject to different follow-up procedures once identified. Therefore, its specificity for disease detection should be evaluated as well for the appropriate management of patients with and without comorbidities.

Demographics

The populations in this study are reflective of the populations at the respective clinics (primary care and Ocular Disease and Special Testing Service), University Eye Center, SUNY State College of Optometry. Subjects were uniformly offered an opportunity to participate in the study on presentation for an examination. It would be of value to undertake a similar study in which the clinically normal and confirmed disease populations could be age-matched, with more stringent controls for gender and ethnicity matching as well.

Conclusion

The iVue iWellnessExam is an extremely sensitive screening program for the detection of both optic nerve disorders

and retinal disorders affecting the macula. When reviewed by a well trained eye care clinician, this screening protocol provides data for the efficient, effective, and accurate identification of both retinal and optic nerve pathology, and of normal healthy eyes. Subjects in need of additional and/or supplementary retinal or optic nerve evaluation were identified with a sensitivity of 96.0% and with a minimal rate of over-referral of healthy subjects (specificity > 99%). Retinal disease sensitivity was 95.5% and optic nerve disorder sensitivity was 90%. This screening protocol provides a finer and more detailed view of the retina than is clinically/ophthalmoscopically observable. Patients who require further monitoring and evaluation for either retinal or optic nerve conditions may thus be detected using this screening protocol but missed in a standard clinical evaluation. Indeed, three subjects who were presumed normal were referred on the basis of this screening for supplementary testing.

It would be valuable to repeat the study with a novice and/or student clinician reviewing the same data set to ascertain interobserver variability, as well as the impact of clinical experience on accurate referral, based on the screening data.

Acknowledgment

The authors would like to acknowledge Tamara St Preux for assistance in data acquisition.

Disclosure

JS lectures for Optovue Inc, but has no financial interest in the company. None of the other authors have any relevant disclosures. The two iVue systems used in the study were on loan to JS from Optovue Inc.

References

- Chen J, Sun X, Wang M. Fourier-domain optical coherence tomography measurement of macular ganglion cell complex and peripapillary nerve fiber layer thickness in normal and glaucomatous human eyes. *ARVO Meeting Abstracts*. 2009;50:3324.
- Schulze A, Pfeiffer N, Gunther S, Hoffmann EM. Measurement of retinal ganglion cell complex in glaucoma, ocular hypertension and healthy subjects with Fourier domain optical coherence tomographic (RTVue 100, Optovue). *ARVO Meeting Abstracts*. 2009;50:3323.
- Seong M, Sung K, Park S, Choi J, Kook M. Glaucoma discrimination capability of macular inner retinal layer thickness assessed by spectral domain optical coherence tomography. *ARVO Meeting Abstracts*. 2009;50:3326.
- Takagi ST, Nose A, Kita Y, Tomita G. Inner retinal layer measurements in macular region with Fourier domain optical coherence tomography in glaucomatous eyes with hemi-field defects. *Invest Ophthalmol Vis Sci*. 2008;Suppl 4648.
- Mori S, Hangai M, Nakanishi H, et al. Macular inner and total retinal volume measurement by spectral domain optical coherence tomography for glaucoma diagnosis. *Invest Ophthalmol Vis Sci*. 2008;Suppl 4651.
- Alexander L. Maximizing the use of peripapillary assessment of retinal nerve fiber layer (RNFL) and ganglion cell complex (GCC) for optic neuropathy by hemi-field comparison. Fremont, CA: Optovue Inc. Available at <http://www.optovue.com/pdf/PeripapillaryAssessment-White-Paper.pdf>. Accessed March 13, 2012.
- Tomidokoro A, Hangai M, Yoshimura N, Araie M; 3D OCT Study Group. Sensitivity and specificity of thickness measurements of macular ganglion cell layer and ganglion cell complex using spectral-domain OCT for diagnosis of preperimetric or early glaucoma. *ARVO Meeting Abstracts*. 2010;51:216.
- Michelessi M, Oddone F, Centofanti M, et al. Ganglion cell complex analysis with Fourier-domain OCT: reproducibility and diagnostic accuracy in glaucoma. *ARVO Meeting Abstracts*. 2010;51:238.
- Konno B Sr, Prata TS, Lima VC, et al. Macular ganglion cell complex versus peripapillary retinal nerve fiber layer analysis for assessment of early glaucoma. *ARVO Meeting Abstracts*. 2010;51:2742.
- Konno S, Tomidokoro A, Araie M. Correlation of visual field damage with structural changes in macular ganglion cell complex, parapapillary retinal nerve fiber layer and optic disc morphology in open-angle glaucoma eyes. *ARVO Meeting Abstracts*. 2010;51:4906.
- Huang D, Swanson EA, Lin CP, et al. Optical coherence tomography. *Science*. 1991;254:1178–1181.
- Hee MR, Izatt JA, Swanson EA, et al. Optical coherence tomography of the human retina. *Arch Ophthalmol*. 1995;113:325–332.
- Sakata LM, Deleon-Ortega J, Sakata V, Girkin CA. Optical coherence tomography of the retina and optic nerve – a review. *Clin Experiment Ophthalmol*. 2009;37:90–99.
- Chen TC, Cense B, Pierce MC, et al. Spectral domain optical coherence tomography: ultra-high speed, ultra-high resolution ophthalmic imaging. *Arch Ophthalmol*. 2005;123:1715–1720.
- Huang D, Tan O. Introduction to RTVue for glaucoma diagnosis. In: Weinreb RN, Varma R, editors, RTVue Primer Series: Vol. III Glaucoma: Fourier-Domain Optical Coherence Tomography. Available from: http://www.opto.com.br/imgs/downloads/1281618551_glaucomaprimerreva.pdf#page=19. Accessed March 16, 2012.
- Pekmezci M, Huang J-Y, Lin SC. Accuracy of the ganglion cell layer thickness analysis in predicting the visual field defects. *ARVO Meeting Abstracts*. 2009;50:3327.
- Kim NR, Lee ES, Seong GJ, Kim JH, An HG, Kim CY. Structure-function relationship and diagnostic value of macular ganglion cell complex measurement using Fourier-domain OCT in glaucoma. *Invest Ophthalmol Vis Sci*. 2010;51:4646–4651.
- Optovue Inc. Available from: <http://www.optovue.com/wp-content/uploads/iVue-Sales-Brochure.pdf>. Accessed March 16, 2012.
- Tan O, Chopra V, Lu AT, et al. Detection of macular ganglion cell loss in glaucoma by Fourier-domain optical coherence tomography. *Ophthalmology*. 2009;116:2305–2314.
- Budenz DL. Symmetry between the right and left eyes of the normal retinal nerve fiber layer measured with optical coherence tomography (an AOS thesis). *Trans Am Ophthalmol Soc*. 2008;106:252–275.
- Kita Y, Kita R, Nitta A, Nishimura C, Tomita G. Glaucomatous eye macular ganglion cell complex thickness and its relation to temporal circum-papillary retinal nerve fiber layer thickness. *Jpn J Ophthalmol*. 2011;55:228–234.
- Takagi ST, Kita Y, Yagi F, Tomita G. Macular retinal ganglion cell complex damage in the apparently normal visual field of glaucomatous eyes with hemifield defects. *J Glaucoma*. 2012;21:318–325.
- Kim NR, Lee ES, Seong GJ, et al. Comparing the ganglion cell complex and retinal nerve fibre layer measurements by Fourier domain OCT to detect glaucoma in high myopia. *Br J Ophthalmol*. 2011;95:1115–1121.
- Sherman J, Slotnick S, Boneta J. Discordance between structure and function in glaucoma: possible anatomical explanations. *Optometry*. 2009;80:487–501.
- Sadun AA, Win PH, Ross-Cisneros FN, Walker SO, Carelli V. Leber's hereditary optic neuropathy differentially affects smaller axons in the optic nerve. *Trans Am Ophthalmol Soc*. 2000;98:223–232.

Eye and Brain

Dovepress

Publish your work in this journal

Eye and Brain is an international, peer-reviewed, open access journal focusing on clinical and experimental research in the field of neuro-ophthalmology. All aspects of patient care are addressed within the journal as well as basic research. Papers covering original research, basic science, clinical and epidemiological studies, reviews and

evaluations, guidelines, expert opinion and commentary, case reports and extended reports are welcome. The manuscript management system is completely online and includes a very quick and fair peer-review system, which is all easy to use. Visit <http://www.dovepress.com/testimonials.php> to read real quotes from published authors.

Submit your manuscript here: <http://www.dovepress.com/eye-and-brain-journal>