

TranSI VEO system: a novel psoas-sparing device for transpsoas lumbar interbody fusion

Mitchell A Hardenbrook^{1,2}
Larry E Miller^{3,4}
Jon E Block⁴

¹Advanced Spine Institute of Greater Boston, North Billerica, MA,

²Department of Orthopedic Surgery, Tufts University School of Medicine, Boston, MA, ³Miller Scientific Consulting Inc, Arden, NC,

⁴The Jon Block Group, San Francisco, CA, USA

Abstract: Minimally invasive approaches for lumbar interbody fusion have been popularized in recent years. The retroperitoneal transpsoas approach to the lumbar spine is a technique that allows direct lateral access to the intervertebral disc space while mitigating the complications associated with traditional anterior or posterior approaches. However, a common complication of this procedure is iatrogenic injury to the psoas muscle and surrounding nerves, resulting in postsurgical motor and sensory deficits. The TranSI VEO system (TranSI Inc, Raleigh, NC, USA) utilizes a novel, minimally invasive transpsoas approach to the lumbar spine that allows direct visualization of the psoas and proximal nerves, potentially minimizing iatrogenic injury risk and resulting clinical morbidity. This paper describes the clinical uses, procedural details, and indications for use of the TranSI VEO system.

Keywords: fusion, lateral, lumbar, minimally invasive, transpsoas, VEO

Introduction

Minimally invasive approaches for lumbar interbody fusion have been popularized in recent years in an effort to reduce access-related patient morbidity while achieving outcomes comparable with open surgery.^{1,2} The retroperitoneal transpsoas approach to the lumbar spine allows direct lateral access to the intervertebral disc space from L1 to L5 while mitigating the complications associated with traditional anterior or posterior approaches. The minimally invasive, retroperitoneal transpsoas procedures utilize lateral entry directly through the psoas major muscle to access the lumbar spine, resulting in less blood loss, avoidance of critical blood vessels and paraspinal musculature, and more rapid postoperative mobilization.³ The approach provides excellent exposure to the disc space, allowing for thorough disc removal to provide an optimal environment for fusion. Furthermore, this approach allows the use of a larger implant, which increases biomechanical support, distributes the compressive loads over a larger surface area, and may lower subsidence risk.^{4,5} Several recent series have reported favorable outcomes using the transpsoas approach, with high fusion rates (range 91%–100%) and clinically significant improvements in pain (range 32%–80%) and back function (range 39%–82%) following surgery.⁶

However, the transpsoas approach is not without limitations, with transient leg weakness due to psoas and surrounding nerve complex injury as one of the most commonly reported complications.^{7,8} Despite the routine use of neuromonitoring to detect iatrogenic injury, the inability to visualize the psoas directly during the procedure increases the potential for iatrogenic injury to the psoas and the nerves of the lumbosacral plexus and genitofemoral nerve. Direct visualization of these critical

Correspondence: Jon E Block
The Jon Block Group, 2210 Jackson Street, Suite 401, San Francisco, CA 94115, USA
Tel +1 415 775 7947
Fax +1 415 928 0765
Email jonblock@jonblockgroup.com

structures is paramount to improving patient safety. A recent cadaveric study demonstrated significant variability in lumbar plexus anatomy, which does not allow for identification of a reliable safe working zone using fluoroscopic guidance only.⁹ Furthermore, safe entry to L4–L5 is hindered by longer nerve roots¹⁰ and significant narrowing of the safe working zone^{11–13} in this area compared with other lumbar levels, resulting in higher complication rates with L4–L5 fusion using a transposas approach.¹⁴

The use of fluoroscopy alone without direct visualization within the surgical field during psoas retraction has been shown to be associated with transient postoperative thigh pain, numbness, paresthesias, and weakness. Cummock et al⁷ performed a retrospective study focused in postoperative thigh symptoms and reported that almost two of three patients undergoing transposas lumbar fusion report these symptoms, despite the routine use of continuous electromyography. Although the majority of these thigh symptoms were transient, thigh numbness and thigh pain continued through one year post-treatment in 7% and 6% of patients, respectively. Youssef et al performed a review of extreme lateral interbody fusion studies and, similarly, reported the incidence of postoperative thigh symptoms to be as high as 75%.⁶

The TranS1 VEO system (TranS1 Inc, Raleigh, NC, USA) utilizes a novel minimally invasive transposas approach to the lumbar spine that is designed to minimize the potential for iatrogenic injury to the psoas and the surrounding nerves. The purpose of this paper is to describe the clinical uses, procedural details, and indications for use of the TranS1 VEO system.

Description

The TranS1 VEO system is a multicomponent system including instrumentation made of biocompatible materials such as stainless steel, aluminum, and Radel R (a high performance thermoplastic designed for use in reusable medical components) and implants made of polyetheretherketone (ASTM F2026) with tantalum (ASTM F560) markers. The system is characterized by a radiolucent tubular retractor designed to prevent soft tissue intrusion and a dual-blade, internal psoas retractor that allows a muscle-sparing approach while offering excellent visualization of the operative site. The radiolucent polyetheretherketone interbody fusion implant is cleared by the US Food and Drug Administration and comprised of various heights and footprints to accommodate individual patient anatomy and graft material sizes.

Procedural details

The patient is positioned in the lateral decubitus position on a radiolucent breaking table with the hips and knees slightly bent in order to relax the psoas muscle. The patient is secured to the table with tape just below the iliac crest, over the thoracic region, from the iliac crest to the knee to the table, and from the table over the knee and ankle to the table. Next, true anteroposterior and lateral fluoroscopic images are obtained to ensure proper patient positioning followed by standard skin preparation and draping methods.

A small (approximately 3 cm) anteroposterior incision is made over the center of the disc space as determined by fluoroscopic imaging. Dissection is continued deep to the fascia over the external oblique muscle. This fascia is incised in line with the muscle fibers using Bovie cautery. The three muscle layers of the abdominal wall are bluntly split in line with the muscle fibers, thereby reducing the trauma to the muscle and gaining access to the retroperitoneal space. Next, the surgical corridor is established using sequential blunt dilators through the retroperitoneal space onto the surface of the psoas muscle. Correct retractor position is confirmed with fluoroscopy (Figure 1A and B). A radiolucent tube is inserted (Figure 1C), the dilators are removed, and a lateral image is taken to confirm correct positioning over the disc space (Figure 1D). The psoas muscle and surrounding nerves are directly visualized and dissected in the anteroposterior direction down to the level of the disc. The nerve roots may be visible through the tube with the sensory root typically lying directly over the muscle and the L4 motor root to the posterior. Unlike other lateral systems, the VEO system enables direct visualization of these nerves, thereby minimizing the risk of iatrogenic injury. A secondary retractor is then inserted through the psoas with the inserter placed to the level of the disc. The retractor is opened and an annulotomy is performed.

Discectomy and endplate preparation is then undertaken using standard instruments. Autogenous bone graft material is packed inside the implant, which is inserted into the disc space. Final anteroposterior and lateral images are then taken, all instrumentation is removed, and the wound is closed in the standard fashion. The system is indicated for use with supplemental fixation devices, which may be selected at the surgeon's discretion.

Postoperative care

Patient monitoring following the transposas procedure varies according to overall patient health and the standard practice of the surgeon. Patient restrictions in the postoperative period

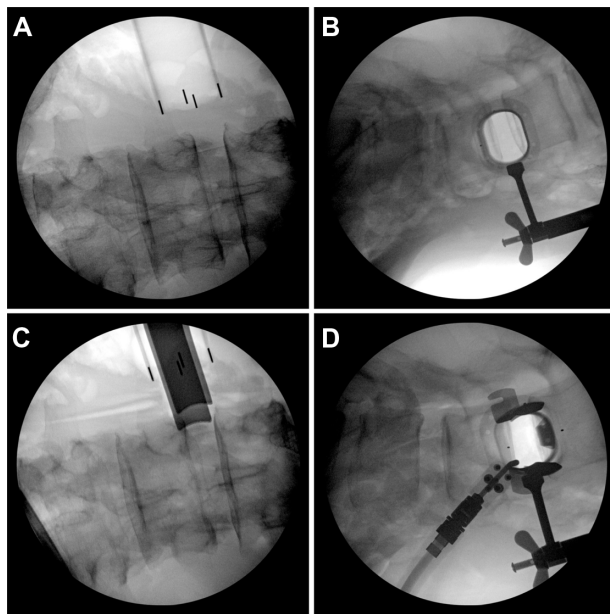


Figure 1 The TranS1 VEO system procedure demonstrating visualization of the correct retraction position using anteroposterior (A) and lateral (B) fluoroscopic images. Radiolucent tube insertion (C) and final confirmation of accurate positioning over the disc space to allow surgical access (D).

are similar to those of traditional lumbar fusion procedures including avoidance of bending and twisting at the waist, heavy lifting (>10 lb), and strenuous physical activity.

Indications for use

The TranS1 VEO system is indicated for spinal fusion procedures in skeletally mature patients with degenerative disc disease at one or two contiguous levels from L1 to L5 with or without grade I spondylolisthesis or retrolisthesis at the involved level(s). Eligible patients should have undergone six months of unsuccessful nonoperative treatment before consideration for surgery. The TranS1 VEO system is designed to be used with an autogenous graft.

Warnings and contraindications

Contraindications for the TranS1 lateral access and interbody fusion system are similar to those of other commercially available retroperitoneal transpsoas access systems and include, but are not limited to, active systemic infection, localized or spinal infection; morbid obesity; signs of local inflammation; fever or leukocytosis; demonstrated allergy or foreign body sensitivity to any implant materials; any medical or surgical condition which would preclude or impede the potential benefit of spinal implant and/or spinal fusion surgery, which could include, but not be exclusive to, elevated erythrocyte sedimentation rate, unexplained inflammatory/disease processes, elevation of white blood

cell count, marked left shift in the white blood cell count differential; distorted anatomy, due to congenital or remote post-traumatic/postinfectious abnormalities; conditions that may place excessive stresses on bone and implants, such as severe obesity or degenerative diseases, osteopenia, and/or osteoporosis (osteoporosis is a relative contraindication as this condition may limit the degree of obtainable correction and/or height restoration, the amount of mechanical fixation, and/or the quality of the bone graft); any case in which a bone graft and fusion technique or where fracture fixation is not performed or required; any operative case utilizing the mixing of dissimilar metals from different components; patients having inadequate soft tissue coverage over the operative site or where there is inadequate bone stock, bone quality, or anatomical definition; any case not described in the indications; patients whose activity, mental capacity, mental illness, alcoholism, drug abuse, smoking, occupation, or lifestyle may interfere with their ability to follow postoperative instructions and/or activity restriction guidelines and who may place undue stresses on the implant during bony healing and may be at a higher risk of implant failure.

Clinical outcomes with the TranS1 VEO system

Hardenbrook¹⁵ treated 87 lumbar levels in 65 subjects (mean age 57 years, 34 female) with the TranS1 VEO system without the use of neuromonitoring. Mean operative blood loss was 255 (range 40–1200) mL and patients were discharged from the hospital in 3.2 (range 1–10) days. Following treatment, back pain assessed with a visual analog scale improved 48% and back function assessed with the Oswestry Disability Index improved 34%. No nerve, vascular, or intra-abdominal injuries were noted. Two complications related to the procedure were noted, ie, nonunion at the treated level (1.1%, one of 87) and lower extremity weakness (1.5%, one of 65). The nonunion was surgically treated and the lower extremity weakness resolved without treatment.

Fleischer et al¹⁶ performed a retrospective analysis of 27 patients treated with the TranS1 VEO system. All cases were technically successful. Postoperative thigh symptoms were tabulated and compared with historical surgical controls. Patients treated with the TranS1 VEO system had a lower complication rate (14% versus 62%), including pain (7% versus 39%), paresthesias (11% versus 12%), motor weakness (4% versus 24%), and need for thigh anesthesia (0% versus 42%). Overall, the initial clinical experience with the TranS1 VEO system shows promising safety and effectiveness outcomes.

Discussion

The minimally invasive retroperitoneal transpsoas approach with the TranS1 VEO system represents a significant advancement in spinal surgery technology with the unique advantage of direct visualization of the psoas muscle and surrounding structures in this highly innervated region. Based on preliminary data, this technique offers comparable clinical and radiographic outcomes as standard lumbar fusion procedures and may reduce iatrogenic psoas injury and resulting thigh symptoms.

Numerous lateral transpsoas fusion systems are commercially available since the recent development of special instrumentation for this purpose. The clinical experience with these procedures has resulted in postoperative thigh symptom frequency ranging from 0% to 75%.^{6,7} However, it is commonly held that postoperative thigh symptoms are underreported since most papers do not focus specifically on transpsoas morbidity and, therefore, the true incidence may be near the higher end of this range. Although most thigh symptoms following transpsoas procedures are transient, some authors have reported that thigh symptoms linger for up to one year in almost one quarter of patients.⁴ These complications can be attributed to two main factors, ie, trauma to the psoas and associated nerve complex due to lack of direct visualization and the poor specificity of electromyography monitoring. It is well known that intraoperative monitoring of the upper lumbar roots during traditional transpsoas procedures is unreliable, with significant response variation caused by numerous factors including the depth and type of anesthesia used. In the study reported by Cummock et al,⁷ motor deficits following transpsoas fusion were reported in 24% of patients although no significant changes in electromyography monitoring were identified during the surgical approach. Complications are significantly more common at L4–L5 versus other levels given the proximity of the lumbar plexus to the lower lumbar area.¹⁴ These data underscore the limitations of transpsoas lumbar spine access.

The TranS1 VEO system has specific advantages compared with other lateral access systems. Only blunt instruments pass through the retroperitoneal space, minimizing the risk of iatrogenic injury to the intra-abdominal contents during the approach. Other lateral systems typically feature large-profile, sharp, radiodense instrumentation that may result in muscle creep and, when combined with the lack of direct visualization of structures of interest, may increase the risk for postoperative thigh symptoms and other access-related complications. Conversely, the TranS1 VEO system features blunt instrumentation utilizing a low-profile two-stage

radiolucent retractor that allows for direct psoas and nerve visualization and a smooth, controlled retraction process in the low trauma anterior-to-posterior direction. This approach may eliminate the need for intraoperative neuromonitoring and minimizes muscle and nervous trauma. Furthermore, the transpsoas corridor allows for a broad discectomy and placement of a large interbody graft or spacer without manipulation of the thecal sac or exiting nerve roots.

Despite the promising outcomes with the TranS1 VEO system, no published series with this device are available. As with any surgical procedure, spine surgeons must be intimately familiar with relevant anatomy and thorough training and experience with the transpsoas approach are paramount to achieving optimal clinical results.

Conclusion

The TranS1 VEO system, a novel psoas-sparing device for transpsoas lumbar interbody fusion, is a promising minimally invasive technique that offers the benefits of traditional lateral fusion procedures while offering direct visualization to the psoas and surrounding nerves, thereby potentially reducing iatrogenic injury and the risk of postoperative thigh symptoms.

Acknowledgments

We thank Gary Fleischer, Spine and Brain Center of New England, Nashua, NH, for contributing clinical data and Randy Asher for graphic assistance.

Disclosure

LEM and JEB received financial support from TranS1 Inc for assistance with manuscript development. MAH reports no conflict of interest in this work.

References

1. Mayer HM. A new microsurgical technique for minimally invasive anterior lumbar interbody fusion. *Spine (Phila Pa 1976)*. 1997;22(6):691–699.
2. Regan JJ, Yuan H, McAfee PC. Laparoscopic fusion of the lumbar spine: minimally invasive spine surgery. A prospective multicenter study evaluating open and laparoscopic lumbar fusion. *Spine (Phila Pa 1976)*. 1999;24(4):402–411.
3. Ozgur BM, Aryan HE, Pimenta L, Taylor WR. Extreme lateral interbody fusion (XLIF): a novel surgical technique for anterior lumbar interbody fusion. *Spine J*. 2006;6(4):435–443.
4. Kepler CK, Sharma AK, Huang RC. Lateral transpsoas interbody fusion (LTIF) with plate fixation and unilateral pedicle screws: a preliminary report. *J Spinal Disord Tech*. 2011;24(6):363–367.
5. Steffen T, Tsantrizos A, Aebi M. Effect of implant design and endplate preparation on the compressive strength of interbody fusion constructs. *Spine (Phila Pa 1976)*. 2000;25(9):1077–1084.
6. Youssef JA, McAfee PC, Patty CA, et al. Minimally invasive surgery: lateral approach interbody fusion: results and review. *Spine (Phila Pa 1976)*. 2010;35(Suppl 26):S302–S311.

7. Cummock MD, Vanni S, Levi AD, Yu Y, Wang MY. An analysis of postoperative thigh symptoms after minimally invasive transpsoas lumbar interbody fusion. *J Neurosurg Spine*. 2011;15(1):11–18.
8. Houten JK, Alexandre LC, Nasser R, Wollowick AL. Nerve injury during the transpsoas approach for lumbar fusion. *J Neurosurg Spine*. 2011;15(3):280–284.
9. Guerin P, Obeid I, Bourghli A, et al. The lumbosacral plexus: anatomic considerations for minimally invasive retroperitoneal transpsoas approach. *Surg Radiol Anat*. 2012;34(2):151–157.
10. Hasegawa T, Mikawa Y, Watanabe R, An HS. Morphometric analysis of the lumbosacral nerve roots and dorsal root ganglia by magnetic resonance imaging. *Spine (Phila Pa 1976)*. 1996;21(9):1005–1009.
11. Guerin P, Obeid I, Gille O, et al. Safe working zones using the minimally invasive lateral retroperitoneal transpsoas approach: a morphometric study. *Surg Radiol Anat*. 2011;33(8):665–671.
12. Kepler CK, Bogner EA, Herzog RJ, Huang RC. Anatomy of the psoas muscle and lumbar plexus with respect to the surgical approach for lateral transpsoas interbody fusion. *Eur Spine J*. 2011;20(4):550–556.
13. Regev GJ, Chen L, Dhawan M, Lee YP, Garfin SR, Kim CW. Morphometric analysis of the ventral nerve roots and retroperitoneal vessels with respect to the minimally invasive lateral approach in normal and deformed spines. *Spine (Phila Pa 1976)*. 2009;34(12):1330–1335.
14. Rodgers WB, Gerber EJ, Patterson J. Intraoperative and early postoperative complications in extreme lateral interbody fusion: an analysis of 600 cases. *Spine (Phila Pa 1976)*. 2011;36(1):26–32.
15. Hardenbrook MA. A new approach to lateral lumbar interbody fusion with one-year follow-up. Poster 218 presented at the 12th Annual Meeting of the International Society for the Advancement of Spinal Surgery, Barcelona, Spain, March 20–23, 2012.
16. Fleischer G, Kearns J, Bellisle M, Nguyen T. Direct visualization of the lumbar nerves during transpsoas approach to lateral interbody lumbar fusion significantly reduces nerve injury and postoperative thigh symptoms. Poster A-506-0000-00528 presented at the 13th Annual Meeting of the International Society for the Advancement of Spinal Surgery, Vancouver, Canada, April 3–5, 2013.

Medical Devices: Evidence and Research

Publish your work in this journal

Medical Devices: Evidence and Research is an international, peer-reviewed, open access journal that focuses on the evidence, technology, research, and expert opinion supporting the use and application of medical devices in the diagnosis, treatment and management of clinical conditions and physiological processes. The identification of novel

Submit your manuscript here: <http://www.dovepress.com/medical-devices-evidence-and-research-journal>

devices and optimal use of existing devices which will lead to improved clinical outcomes and more effective patient management and safety is a key feature. The manuscript management system is completely online and includes a quick and fair peer-review system. Visit <http://www.dovepress.com/testimonials.php> to read real quotes from authors.

Dovepress