

# Histologic and apoptotic changes induced by titanium dioxide nanoparticles in the livers of rats

Saud Alarifi<sup>1</sup>  
Daoud Ali<sup>1</sup>  
Amin A Al-Doaiss<sup>1,2</sup>  
Bahy A Ali<sup>1,3</sup>  
Mukhtar Ahmed<sup>1</sup>  
Abdulaziz A Al-Khedhairi<sup>1</sup>

<sup>1</sup>Department of Zoology, College of Science, King Saud University, Riyadh, Saudi Arabia; <sup>2</sup>Anatomy and Histology Department, Faculty of Medicine, Sana'a University, Sana'a, Republic of Yemen; <sup>3</sup>Genetic Engineering and Biotechnology Research Institute, City for Scientific Research and Technology Applications, Alexandria, Egypt

**Abstract:** Titanium dioxide (TiO<sub>2</sub>) nanoparticles are among the top five nanoparticles used in consumer products, paints, and pharmaceutical preparations. Given that exposure to such nanoparticles is mainly via the skin and inhalation, the present study was conducted in male Wistar albino rats (*Rattus norvegicus*). Our aim was to investigate the effect of TiO<sub>2</sub> nanoparticles on hepatic tissue in an attempt to understand their toxicity and the potential effect of their therapeutic and diagnostic use. To investigate the effects of TiO<sub>2</sub> nanoparticles on liver tissue, 30 healthy male Wistar albino rats were exposed to TiO<sub>2</sub> nanoparticles at doses of 63 mg, 126 mg, and 252 mg per animal for 24 and 48 hours. Serum glutamate oxaloacetate transaminase and alkaline phosphatase activity was altered. Changes in hepatocytes can be summarized as hydropic degeneration, cloudy swelling, fatty degeneration, portal and lobular infiltration by chronic inflammatory cells, and congested dilated central veins. The histologic alterations observed might be an indication of hepatocyte injury due to the toxicity of TiO<sub>2</sub> nanoparticles, resulting in an inability to deal with accumulated residues from the metabolic and structural disturbances caused by these nanoparticles. The appearance of cytoplasmic degeneration and destruction of nuclei in hepatocytes suggests that TiO<sub>2</sub> nanoparticles interact with proteins and enzymes in hepatic tissue, interfering with antioxidant defense mechanisms and leading to generation of reactive oxygen species which, in turn, may induce stress in hepatocytes, promoting atrophy, apoptosis, and necrosis. More immunohistochemical and ultrastructural investigations are needed in relation to TiO<sub>2</sub> nanoparticles and their potential effects when used as therapeutic and diagnostic tools.

**Keywords:** TiO<sub>2</sub> nanoparticles, rats, liver, histology, TUNEL assay, alkaline phosphatase, apoptosis

## Introduction

Nanotechnology is a promising new field with potential applications in the domestic, industrial, and biomedical fields.<sup>1</sup> Due to the growing number of applications, there is an increasing risk to animals from environmental exposure to nanomaterials. Their potential toxicologic impact is still under investigation and our actual knowledge about the effects of nanosized contaminants on biological systems remains incomplete.<sup>2,3</sup> These effects need to be assessed in order to provide a scientific basis for safe development of nanotechnologies. Use of nanotechnology has seen exponential growth in the areas of health care, consumer products, clothes, electronics, and sporting goods.<sup>2</sup> This is due to the unique chemical, mechanical, optical, magnetic, and biological properties of nanomaterials that make them desirable for commercial and medical applications.<sup>4</sup> According to a recent survey, the number of nanotechnology-based consumer products available on the world market now exceeds 1000.<sup>5</sup> TiO<sub>2</sub> nanoparticles have several

Correspondence: Daoud Ali  
Department of Zoology, College of Science, King Saud University, PO Box 2455, Riyadh 11451, Kingdom of Saudi Arabia  
Tel +966 5 5890 4621  
Fax + 966 11 467 8514  
Email aalidaoud@ksu.edu.sa

industrial applications, and as such, come in different sizes, shapes, chemical compositions, and crystalline structures.<sup>6</sup> TiO<sub>2</sub> occurs in four crystalline polymorphic forms, of which rutile and anatase are the most common.<sup>7</sup> Rutile is considered to be a more inert form whereas anatase is an active form of TiO<sub>2</sub>. Some studies indicate that anatase TiO<sub>2</sub> nanoparticles are more cytotoxic than rutile TiO<sub>2</sub> nanoparticles.<sup>8</sup> Yeo et al<sup>9</sup> have reported that different TiO<sub>2</sub> nanoparticles induce different toxicities during embryogenesis of the zebra fish due to their different sizes and crystalline phases. The increased use of nanoparticles is a matter of great concern to health professionals and environmental scientists because of the potential risks to humans and to the environment.<sup>10</sup> Of the possible exposure routes, inhalation and skin contact are considered to be the most important for nanoparticles. The toxic effects of nanoparticles can be attributed to their small size and hence large surface area, which increases their chemical reactivity and penetration into living cells.<sup>11</sup> TiO<sub>2</sub> nanoparticles also induce reactive oxygen species, leading to toxicity.<sup>12</sup>

The dimensions of TiO<sub>2</sub> nanoparticles are critical from the toxicity point of view, given that TiO<sub>2</sub> nanoparticles have more pronounced toxicity than conventional TiO<sub>2</sub> particles.<sup>13</sup> TiO<sub>2</sub> nanoparticles have been shown to impair the function of macrophages, to cause persistent inflammatory reactions, and to increase pulmonary retention compared with fine TiO<sub>2</sub> particles.<sup>14</sup> TiO<sub>2</sub> nanoparticles can be absorbed into the body by inhalation, ingestion, and dermal penetration, and are distributed to important organ systems, including lymph, brain, lung, liver, and kidney.<sup>15-17</sup> Of note, it has been observed in vivo that anatase TiO<sub>2</sub> nanoparticles increased inflammatory indicators, cell proliferation, and histopathology in bronchoalveolar lavage fluid.<sup>18</sup>

Characteristics of TiO<sub>2</sub> nanoparticles can be modified by several methods to improve their performance. Due to their small size, nanoparticles may cross biological barriers to reach a number of organs, and according to their size and surface properties, accumulation of metal nanoparticles has been observed previously in all organs in vivo.<sup>19</sup> Generation of free oxygen radicals and oxidative stress triggers a host of cellular events, including DNA damage and apoptosis.<sup>20</sup> Therefore, in the present study, an attempt was made to assess the toxicity and apoptotic potential of TiO<sub>2</sub> nanoparticles in the liver tissue of male rats.

## Materials and methods

### Chemicals and animals

Titanium (IV) oxide (TiO<sub>2</sub>) nanopowder (99.7% anatase, CAS 1317-70-0) was obtained from Sigma-Aldrich (St Louis,

MO, USA). A terminal transferase-mediated biotinylated 16-deoxy-uridine-triphosphate (dUTP) nick-end labeling (TUNEL) apoptosis detection kit (catalog number L00300) with anti-fluorescein antibody conjugated peroxidase (FITC-labeled POD) for paraffin-embedded tissue sections was purchased from GenScript Biology CRO (Piscataway, NJ, USA). All other chemicals were obtained locally in Saudi Arabia and were of analytical reagent grade. Forty healthy male Wistar albino rats (*Rattus norvegicus*) aged eight weeks with a mean weight of 126 g were obtained from the Animal Care Center, College of Pharmacy, King Saud University.

### Preparation and characterization of TiO<sub>2</sub> nanoparticles

TiO<sub>2</sub> NPs were suspended in Milli-Q water (Millipore Corporation, Billerica, MA, USA) at a concentration of 1 mg/mL. A stock suspension was probe-sonicated at 40 W for 15 minutes. Samples for analysis by transmission electron microscopy (TEM) were prepared by drop coating a TiO<sub>2</sub> nanoparticle solution on carbon-coated copper TEM grids. The films formed on the TEM grids were allowed to dry prior to measurement. TEM measurements were performed using a JEOL instrument (model 1101F, JEOL Ltd, Tokyo, Japan) operated at an accelerating voltage at 200 kV.

### Experimental design

The rats were housed in groups under standard lighting conditions with free access to water and food. Humidity and temperature (22°C ± 1°C) were controlled in ventilated cages on a 12-hour day/night cycle. Five animals from each group were anesthetized and euthanized by cervical dislocation after 24 and 48 hours of exposure to TiO<sub>2</sub> nanoparticles. All experiments were conducted in accordance with the guidelines approved by the local animal care and use committee at King Saud University.

TiO<sub>2</sub> nanoparticle doses were calculated based on average body weight.<sup>21,22</sup> The study was conducted to compare the toxicity of the nanoparticles at three different doses. The animals were divided into four groups of ten rats each, which were injected intraperitoneally as follows for two days:

- group 1, normal animals, injected with Milli-Q water
- group 2, injected with 63 mg of TiO<sub>2</sub> nanoparticles per animal
- group 3, injected with 126 mg of TiO<sub>2</sub> nanoparticles per animal
- group 4, injected with 252 mg of TiO<sub>2</sub> nanoparticles per animal.

## Histopathology

The animals were exposed to different doses of TiO<sub>2</sub> nanoparticles intraperitoneally for 24 and 48 hours. After euthanizing the animals, fresh portions of the lateral lobes of the liver from each rat were cut rapidly, fixed in neutral buffered formalin (10%), then dehydrated using grades of ethanol (70%, 80%, 90%, 95%, and 100%). Dehydration was followed by clearing the samples in two changes of xylene. The samples were then impregnated with two changes of molten paraffin wax, embedded, and blocked out. The tissue sections (4–5 μm) were stained according to the method described by Bancroft and Stevens<sup>23</sup> using conventional histologic stains. Stained sections from the control and treated rats were observed and photographs were taken using an optical microscope (Olympus, Tokyo, Japan) for alterations in architecture, hepatocytes, and sinusoids, and for the presence of degeneration, necrosis, fatty changes, and portal fibrosis.

## Estimation of GOT and ALP

After exposure for 48 hours, blood samples were taken from five rats per group, and the serum was separated out for estimation of alkaline phosphatase (ALP) and glutamate oxaloacetate transaminase (GOT) activity using already reported methods.<sup>24,25</sup>

## TUNEL assay

Formalin-fixed, paraffin-embedded tissue sections were dewaxed in xylene, rehydrated through graded ethanol, and pretreated with proteinase-K 20 μg/mL in phosphate-buffered saline for 15 minutes at 37°C in a humidified chamber. After washing twice in distilled water and rinsing in Tris-buffered saline (pH 7.6), the sections were incubated for 60 minutes at 37°C with a reaction mixture containing 0.3 U/μL terminal deoxynucleotidyl transferase (GenScript),

terminal transferase buffer (GenScript) 100 mM cacodylate buffer (pH 6.8), 1 mM cobalt chloride, and 0.5 mM DL-dithiothreitol with biotinylated 16-dUTP added (GenScript). The reaction was terminated by rinsing twice in Tris-buffered saline. Next, the sections were covered with 2% bovine serum albumin in Tris-buffered saline for 15 minutes and then incubated with avidin-biotin-conjugated ALP (GenScript) at 1:100 for 30 minutes. Staining was done using 5-bromo-chloro-indoxyl phosphate/nitro blue tetrazolium (GenScript) with 1 mM levamisole added to inhibit endogenous ALP activity. The result imparted an orange/brown color to the nuclei of apoptotic cells.

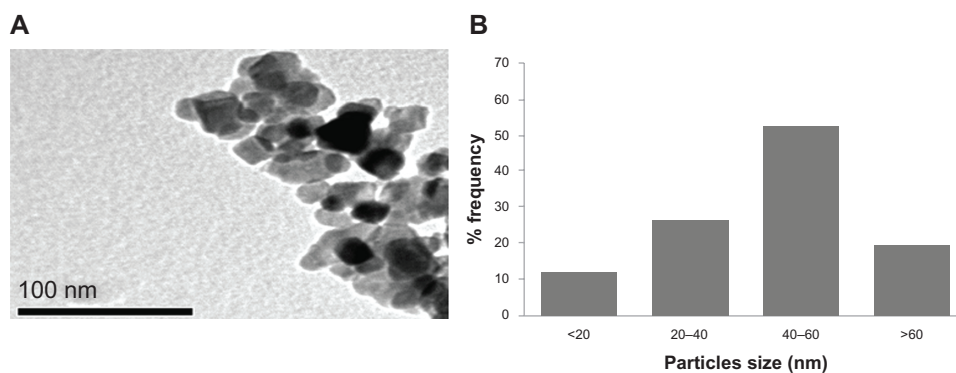
Positive control slides were created by staining sections of rat liver tissue with 50 μL of DNase I solution (GenScript). For the negative control, terminal deoxynucleotidyl transferase was omitted from the reaction buffer. The slides for the control and treated rat hepatocytes were observed and the images captured using an optical Olympus microscope.

## Statistical analysis

One independent experiment was carried out for evaluation. Data were expressed as the mean ± standard error and tested by one-way analysis of variance. A *P*-value less than 0.01 was considered to be statistically significant.

## Results and discussion

The TiO<sub>2</sub> nanoparticles were characterized first for size and found to be in the nanoscale range, but formed small agglomerates in aqueous solution. TEM imaging revealed the morphology of the nanoparticles (Figure 1A). The average size measured by TEM was 50.40 ± 5.60 nm (Figure 1B). The typical TEM image shown in Figure 1A suggests that most of the TiO<sub>2</sub> nanoparticles had a polyhedral morphology. Like other materials, when normal-scale TiO<sub>2</sub> is converted



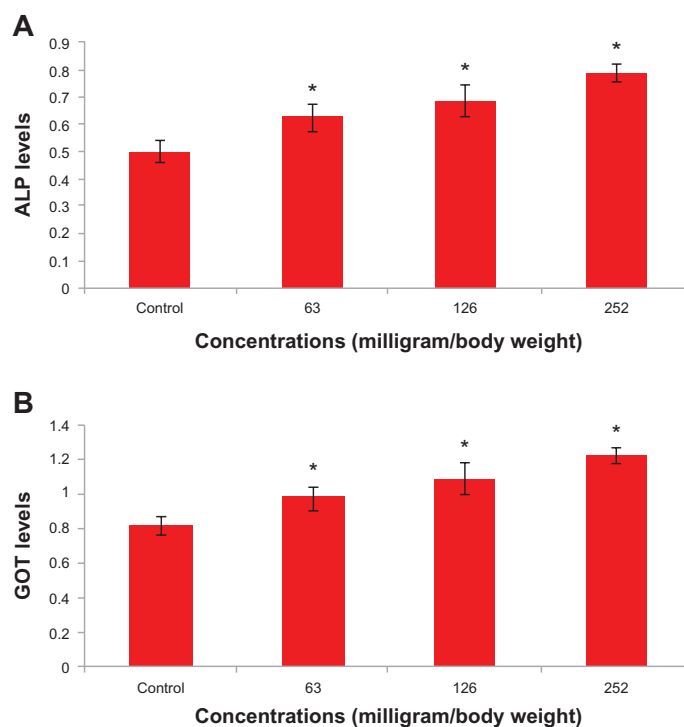
**Figure 1** Characterization of titanium oxide nanoparticles. (A) Transmission electron microscopic image and (B) size distribution histogram generated using transmission electron microscopy.

into nanoscale TiO<sub>2</sub>, the physicochemical properties change. The special physicochemical properties of nanoparticles come from their high surface-to-volume ratio. They also have a considerable higher percentage of atoms on their surface compared with bulk particles, which makes them more reactive.

We measured blood chemistry parameters, including enzymes, to evaluate organ function in our experimental animals. There was a significant ( $P < 0.05$ ) increase in GOT and ALP levels (Figure 2). GOT and ALP levels are indicative of the functional efficiency of the liver, and are very sensitive to any disease process of the liver.<sup>26</sup> The histologic changes observed in the liver and the accompanying increase in ALP and GOT levels indicate compromised liver function. In comparison with the control group, histologic changes were detected in the liver tissue of rats treated with TiO<sub>2</sub> nanoparticles (Figure 3). Apoptosis was also seen in the hepatocytes of rats treated with these nanoparticles. The appearance of inflammatory cells in hepatic tissue suggests that the TiO<sub>2</sub> nanoparticles can interact with proteins and enzymes in the interstitial tissue of the liver, interfering with the antioxidant defense mechanism and leading to generation of reactive oxygen species, which in turn may imitate an inflammatory response.<sup>27</sup> Distortion and swelling of hepatocytes together with dilatation of the central vein

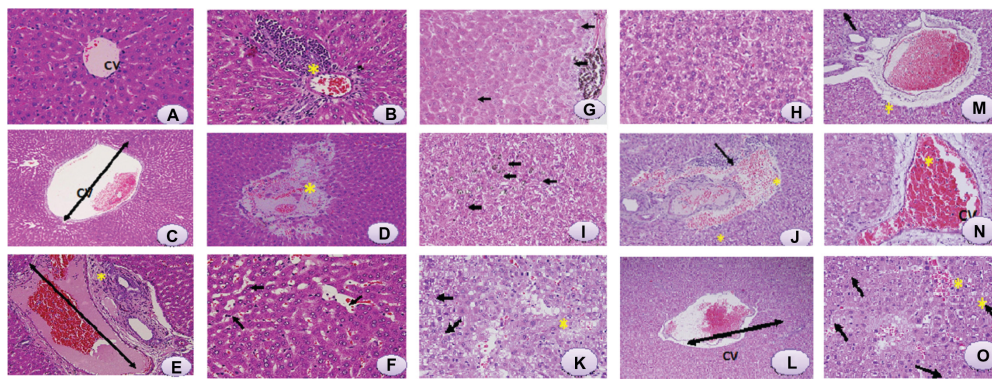
and blood sinusoids indicate that these nanoparticles may affect permeability of the cell membrane in hepatocytes and the endothelial lining of blood vessels. Swelling of hepatocytes on exposure to nanoparticles as seen in the present study might lead to adaptation of cell transporters.<sup>28</sup> Binucleation is a consequence of cell injury and a type of chromosomal hyperplasia usually seen in regenerating cells.<sup>29</sup> Cloudy swelling might be seen as a result of disturbed membrane function, leading to a massive influx of water and sodium due to the effects of nanoparticles. Cell swelling might be accompanied by leakage of lysosomal hydrolytic enzymes, leading to degeneration of the cytoplasm and macromolecular crowding.<sup>30</sup> Hydropic degeneration is a result of ion and fluid homeostasis, and leads to an increase in intracellular water.<sup>31</sup> The vacuolated swelling seen in the cytoplasm of hepatocytes from rats exposed to TiO<sub>2</sub> nanoparticles indicates acute liver injury.

We also observed that apoptosis in hepatocytes exposed to TiO<sub>2</sub> nanoparticles increased in a dose-dependent and time-dependent manner (Figure 4). Sporadic, spotty, and well defined necrosis was also noted in some hepatocytes from rats exposed to TiO<sub>2</sub> nanoparticles, which might have been because of oxidative stress triggered by depletion of glutathione in these cells. Park et al<sup>32</sup> reported that TiO<sub>2</sub>



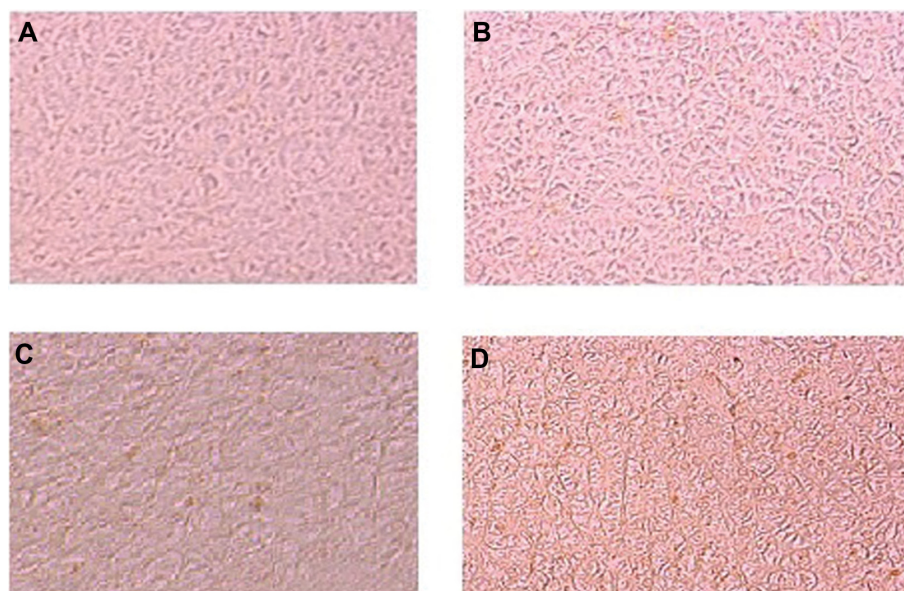
**Figure 2** Levels of (A) alkaline phosphatase and (B) glutamate oxaloacetate transaminase after exposure of titanium oxide nanoparticles in the different experimental groups at 48 hours. Each value represents the mean  $\pm$  standard error of three experiments. \* $P < 0.05$  versus control.





**Figure 3** Light microphotographs of liver tissue.

**Notes:** (A) Male rats injected with Milli-Q water for 48 hours demonstrating normal histologic architecture. Hematoxylin and eosin, 400 $\times$ . (B) Male rats 24 hours post-exposure to titanium oxide nanoparticles (252 mg per animal) by intraperitoneal administration demonstrating lymphocytic infiltration (\*) in the hepatic portal space. Hematoxylin and eosin, 400 $\times$ . (C) Male rats 24 hours post-exposure to titanium oxide nanoparticles (252 mg per animal) by a single oral administration demonstrating marked dilatation of central vein. Hematoxylin and eosin, 400 $\times$ . (D) Male rats 24 hours post-exposure to titanium oxide nanoparticles (252 mg per animal) by intraperitoneal administration demonstrating marked necrosis (\*) and scattered hemorrhages. Hematoxylin and eosin, 400 $\times$ . (E) Male rats 24 hours post-exposure to titanium oxide nanoparticles (252 mg per animal) by intraperitoneal administration demonstrating dilatation of congested portal vein with edema (\*) around the blood vessel in the portal triad. Hematoxylin and eosin, 400 $\times$ . (F) Male rats 24 hours post-exposure to titanium oxide nanoparticles (252 mg per animal) by intraperitoneal administration demonstrating dilatation and congestion of blood sinusoids (arrows) and binucleation of hepatocytes (circles). Hematoxylin and eosin, 400 $\times$ . (G) Male rats 48 hours post-exposure to titanium oxide nanoparticles (252 mg per animal) by intraperitoneal administration demonstrating swelling of hepatocytes (arrows) and presence of nanoparticle beneath the capsule (\*). Hematoxylin and eosin, 400 $\times$ . (H) Male rats 48 hours post-exposure to titanium oxide nanoparticles (252 mg per animal) by intraperitoneal administration demonstrating vacuolization of hepatocytes. Hematoxylin and eosin, 400 $\times$ . (I) Male rats 48 hours post-exposure to titanium oxide nanoparticles (252 mg per animal) by intraperitoneal administration, hydropic degeneration (ballooning) of hepatocytes and presence of nanoparticle in blood sinusoids (arrows). Hematoxylin and eosin, 400 $\times$ . (J) Male rats 24 hours post-exposure to titanium oxide nanoparticles (126 mg per animal) by intraperitoneal administration demonstrating dilatation of congested portal vein with hemorrhage and edema (\*) around the blood vessel and lymphocytic infiltration (arrow) in the portal triad. Hematoxylin and eosin, 400 $\times$ . (K) Male rats 24 hours post-exposure to titanium oxide nanoparticles (126 mg per animal) by intraperitoneal administration demonstrating focal necrosis (\*) and hydropic degeneration of hepatocytes (arrows). Hematoxylin and eosin, 400 $\times$ . (L) Male rats 48 hours post-exposure to titanium oxide nanoparticles (126 mg per animal) by intraperitoneal administration demonstrating marked dilatation of congested central vein. Hematoxylin and eosin, 400 $\times$ . (M) Male rats 48 hours post-exposure to titanium oxide nanoparticles (126 mg per animal) by intraperitoneal administration demonstrating dilatation of congested portal vein with edema (\*) around the blood vessel in the portal triad. Hematoxylin and eosin, 400 $\times$ . (N) Male rats 24 hours post-exposure to titanium oxide nanoparticles (63 mg per animal) by intraperitoneal administration demonstrating marked dilatation of congested central vein. Hematoxylin and eosin, 400 $\times$ . (O) Male rats 48 hours post-exposure to titanium oxide nanoparticles (63 mg per animal) by intraperitoneal administration demonstrating focal necrosis (\*) and hydropic degeneration of hepatocytes (arrows). Hematoxylin and eosin, 400 $\times$ .



**Figure 4** Photomicrograph of apoptosis in liver tissue after exposure of titanium oxide nanoparticles. (A) Control, (B) 63 mg per animal, (C) 126 mg per animal, and (D) 252 mg per animal.

nanoparticles induced oxidative stress and apoptosis in cultured BEAS-2B cells. In the present study, after intraperitoneal administration of high-dose TiO<sub>2</sub> nanoparticles, the difficulty encountered in clearance of these nanoparticles in vivo may have resulted in deposition of particles in the liver and a hepatic lesion.<sup>33</sup> The International Programme on Chemical Safety<sup>34</sup> shows that most ingested titanium is excreted via the urine and is not absorbed by the organism. The liver, being the main detoxification organ in the body, is activated to eliminate the side effects induced by the ingested mass of TiO<sub>2</sub> nanoparticles, and a proportion of these nanoparticles should be excreted by the kidneys. Because of their small size and difficult clearance, TiO<sub>2</sub> nanoparticles were retained in vivo, and liver damage occurred after intraperitoneal exposure to a high dose.

## Conclusion

In conclusion, our results indicate that TiO<sub>2</sub> nanoparticles induce histologic changes in hepatocytes, which may be mediated by generation of reactive oxygen species and stress to induce atrophy and apoptosis. Long-term biological safety is another issue that will need clarification in future investigations.

## Acknowledgment

The authors extend their appreciation to the Deanship of Scientific Research at King Saud University for funding this work through research group project RGP-VPP-180.

## Disclosure

The authors report no conflicts of interests in this work.

## References

1. Peralta-Videa JR, Zhao L, Lopez-Moreno ML, de la Rosa G, Hong J, Gardea-Torresdey JL. Nanomaterials and the environment: a review for the biennium 2008–2010. *J Hazard Mater*. 2011;186:1–15.
2. Singh N, Manshian B, Jenkins GJS, et al. NanoGenotoxicology: the DNA damaging potential of engineered nanomaterials. *Biomaterials*. 2009;30:3891–3914.
3. Skocaj M, Filipic M, Petkovic J, Novak S. Titanium dioxide in our everyday life: is it safe? *Radiol Oncol*. 2011;45:227–247.
4. Nel A, Xia T, Madler L, Li N. Toxic potential of materials at the nanolevel. *Science*. 2006;311:622–627.
5. Project of the Emerging Nanotechnologies 2009. Available from: <http://www.nanotechproject.org>. Accessed June 14, 2013.
6. Li JJ, Muralikrishnan S, Ng CT, Yung LY, Bay BH. Nanoparticle-induced pulmonary toxicity. *Exp Biol Med (Maywood)*. 2012;235:1025–1033.
7. Madl AK, Pinkerton KE. Health effects of inhaled engineered and incidental nanoparticles. *Crit Rev Toxicol*. 2009;39:629–658.
8. Hirakawa K, Mori M, Yoshida M, Oikawa S, Kawanishi S. Photo-irradiated titanium dioxide catalyzes site specific DNA damage via generation of hydrogen peroxide. *Free Radic Res*. 2004;38:439–447.
9. Yeo MK, Kang M. The biological toxicities of two crystalline phases and differential sizes of TiO<sub>2</sub> nanoparticles during zebra fish embryogenesis development. *Mol Cell Toxicol*. 2012;8:317–326.
10. Oberdorster G, Oberdorster E, Oberdorster J. Nanotoxicology: an emerging discipline evolving from studies of ultrafine particles. *Environ Health Perspect*. 2005;113:823–839.
11. Pan Z, Lee W, Slutsky L, Clark RA, Pernodet N, Rafailovich MH. Adverse effects of titanium dioxide nanoparticles on human dermal fibroblasts and how to protect cells. *Small*. 2009;5:511–520.
12. Barnard AS. One-to-one comparison of sun screen efficacy, aesthetics and potential nanotoxicity. *Nat Nanotechnol*. 2012;5:271–274.
13. Driscoll KE, Maurer JK. Cytokine and growth factor release by alveolar macrophages: potential biomarkers of pulmonary toxicity. *Toxicol Pathol*. 1991;19:398–405.
14. Baggs RB, Fern J, Oberdorster G. Regression of pulmonary lesions produced by inhaled titanium dioxide in rats. *Vet Pathol*. 1997;34: 592–597.
15. Bermudez E, Mangum JB, Wong BA, et al. Pulmonary responses of mice, rats, and hamsters to subchronic inhalation of ultrafine titanium dioxide particles. *Toxicol Sci*. 2004;77:347–357.
16. Thomas T, Thomas K, Sadrieh N, Savage N, Adair P, Bronaugh R. Research strategies for safety evaluation of nanomaterials, part VII: evaluating consumer exposure to nanoscale materials. *Toxicol Sci*. 2006;91:14–19.
17. Wang J, Zhou G, Chen C, et al. Acute toxicity and bio distribution of different sized titanium dioxide particles in mice after oral administration. *Toxicol Lett*. 2007;168:176–185.
18. Warheit DB, Webb TR, Reed KL, Frerichs S, Sayes CM. Pulmonary toxicity study in rats with three forms of ultrafine TiO<sub>2</sub> particles: differential responses related to surface properties. *Toxicology*. 2007;230: 90–104.
19. Li YF, Chen C. Fate and toxicity of metallic and metal-containing nanoparticles for biomedical applications. *Small*. 2011;7:2965–2980.
20. Ostrovsky S, Kazimirsky G, Gedanken A, Brodie C. Selective cytotoxic effect of ZnO nanoparticles on glioma cells. *Nano Res*. 2009;2: 882–890.
21. Park EJ, Yoon J, Choi K, Yi J, Park K. Induction of chronic inflammation in mice treated with titanium dioxide nanoparticles by intratracheal instillation. *Toxicology*. 2009;260(1–3):37–46.
22. Zhang XD, Wu HY, Wu D, et al. Toxicologic effects of gold nanoparticles in vivo by different administration routes. *Int J Nanomedicine*. 2010;5:771–781.
23. Bancroft JD, Stevens A. *Theory and Practice of Histological Techniques*, 4th ed. London, UK: Churchill-Livingstone; 1999.
24. King EJ, Armstrong AR. In vitro determination of alkaline phosphatase. *Can Med Assoc J*. 1934;31:376–379.
25. Giray B, Gurbay A, Hineal F. Cypermethrin induced oxidative stress in rat brain and liver is prevented by vit-E or allopurinol. *Toxicol Lett*. 2011;118:139–146.
26. Tietz NW. *Fundamentals of Clinical Chemistry*, 4th ed. Philadelphia, PA: WB Saunders Company; 1996.
27. Johar D, Roth JC, Bay GH, Walker JN, Krocak TJ, Los M. Inflammatory response, reactive oxygen species, programmed (necrotic-like and apoptotic) cell death and cancer. *Rocz Akad Med Bialymst*. 2004;49:31–39.
28. Johnson CE. Effects of fluid imbalances. In: Conn PM, editor. *Neurosciences in Medicine*. New York, NY: JB Lippincott Company; 1995.
29. Gerlyng P, Åbyholm A, Grotmol T, et al. Binucleation and polyploidization patterns in developmental and regenerative rat liver growth. *Cell Prolif*. 2008;26:557–565.
30. Del Monte U. Swelling of hepatocytes injured by oxidative stress suggests pathological changes related to macromolecular crowding. *Med Hypotheses*. 2005;64:818–825.
31. Schrand AM, Rahman MF, Hussain SM. Metal-based nanoparticles and their toxicity assessment. *Nanomed Nanobiotechnol*. 2010;2: 544–568.
32. Park EJ, Yi J, Chung KH, Ryu DY, Choi J, Park K. Oxidative stress and apoptosis induced by titanium dioxide nanoparticles in cultured BEAS-2B cells. *Toxicol Lett*. 2008;180:222–229.

33. Johnston HJ, Hutchison GR, Christensen FM, Peters S, Hankin S, Stone V. Identification of the mechanisms that drive the toxicity of TiO<sub>2</sub> particulates: the contribution of physicochemical characteristics. *Part Fibre Toxicol.* 2009;6:33.
34. World Health Organization. International Programme on Chemical Safety. Environmental Health Criteria 24-Titanium. Geneva, Switzerland: World Health Organization; 1982. Available from: <http://www.inchem.org/documents/ehc/ehc/ehc24.htm>. Accessed June 13, 2013.

### International Journal of Nanomedicine

Dovepress

### Publish your work in this journal

The International Journal of Nanomedicine is an international, peer-reviewed journal focusing on the application of nanotechnology in diagnostics, therapeutics, and drug delivery systems throughout the biomedical field. This journal is indexed on PubMed Central, MedLine, CAS, SciSearch®, Current Contents®/Clinical Medicine,

Journal Citation Reports/Science Edition, EMBase, Scopus and the Elsevier Bibliographic databases. The manuscript management system is completely online and includes a very quick and fair peer-review system, which is all easy to use. Visit <http://www.dovepress.com/testimonials.php> to read real quotes from published authors.

Submit your manuscript here: <http://www.dovepress.com/international-journal-of-nanomedicine-journal>