

A case of bacteremia caused by *Campylobacter fetus*: an unusual presentation in an infant

Amani M Alnimr

Department of Microbiology, King Fahad University Hospital, College of Medicine, University of Dammam, Saudi Arabia

Abstract: Bacteremia due to *Campylobacter* spp. is rarely reported, and *Campylobacter fetus* is the species most commonly exhibiting vascular tropism, as occurred in this case report describing the diagnosis of *C. fetus* bacteremia in an infant presenting with respiratory tract infection. A 5-month-old baby, with undiagnosed failure to thrive, presented to the acute care service with a high fever and respiratory symptoms of 2 days duration. The initial clinical and laboratory diagnosis suggested bacteremia, but there was difficulty with recovery and identification of the organism from blood. Subsequent laboratory testing confirmed *C. fetus* as the etiological agent. *Campylobacter* isolated from blood culture bottles may give atypical laboratory features, rendering its identification challenging. Thus, such an infrequent species might be underestimated in frequency, and it should be considered in diagnostic laboratories, when a gram-negative organism with atypical findings is encountered in respiratory samples or blood culture bottles.

Keywords: microbiology, vascular tropism, blood stream infection

Introduction

The genus *Campylobacter* contains fifteen species, of which *Campylobacter jejuni* is the most commonly clinically isolated, in association with invasive diarrheal colitis. The less commonly encountered *Campylobacter fetus* subsp. *fetus* (*C. fetus*) is an opportunistic organism that causes nonintestinal infections with vascular tropism. It has been implicated in various systemic infections, including endocarditis, mycotic aneurysms, septic thrombophlebitis, pneumonia, and neonatal sepsis.^{1,2} Lower respiratory infection caused by *C. fetus* has been described as febrile lobar pneumonia, occurring in the absence of gastrointestinal disease, that tends to occur in splenectomized patients.³ Patients with underlying chronic debilitating illness, eg, diabetes, thalassemias, malignancy, cardiac conditions, or cirrhosis, are at increased risk for *C. fetus* bloodstream infections.^{3,4} The virulence of *C. fetus* is thought to be mainly related to its production of a high-molecular-weight surface protein, which acts as a microcapsule with high affinity to the vascular endothelium;² Blaser et al reported that *C. fetus* strains were serum resistant, which explains the high affinity of the organism to endothelial tissues.² We present a case of pneumonia accompanied by bacteremia caused by *C. fetus*, in an infant who was suspected to have another undiagnosed comorbidity.

Case presentation

A 5-month-old baby was admitted to the hospital with a 2-day history of a high fever, influenza-like symptoms, and a dry cough but no gastrointestinal or

Correspondence: Amani M Alnimr
Department of Microbiology, King Fahad University Hospital, College of Medicine, University of Dammam, PO Box 1982, Postcode 31441, Saudi Arabia
Tel +966 1 3333 5130
Email amalnimr@ud.edu.sa

neurological symptoms. The vital signs were: temperature 39.1°C, respiratory rate 40 per minute, blood pressure 80/50, and oxygen saturation 98%. Bronchopneumonia was clinically diagnosed based on radiological findings, and intravenous cefuroxime was empirically initiated. The fever did not resolve, while respiratory specimens and stool did not grow any significant isolate on the corresponding bacteriological media. The patient was previously noted as a case of “undiagnosed failure to thrive” and scheduled for cardiology assessment since the family history suggested the possibility of a congenital heart disease. The microbiology laboratory noted a positive blood culture bottle, which initially did not yield an organism in gram staining. There was also no growth found on the routine subculture media in the first day. However, after 48 hours, scanty growth was detected, which was oxidase negative and had a microscopic appearance of gram-negative coccobacilli. Routine processing could not identify the organism. Then, further clinical data obtained from the attending physician suggested a possible chronic morbidity that could predispose the patient to an opportunistic pathogen; the colonies were subcultured on multiple laboratory media, including Skirrow’s media, which were incubated microaerophilically at 25°C, 27°C, and 42°C for 48 hours. Heavy growth was detected on Skirrow’s media at both 25°C and 37°C but not at 42°C, with the typical colonial morphology of *Campylobacter* (Figure 1). Further testing showed strong oxidase-positive and typical reactions for *C. fetus*. The VITEK® 2 system (bioMérieux Inc., Craponne, France) gave 99% identification accuracy of the colonies obtained from the Skirrow’s media but failed to identify the organism grown on routine blood culture plates. Sensitivity testing was done using

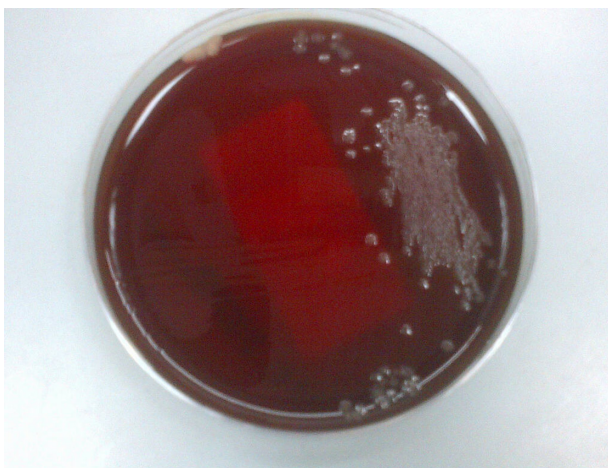


Figure 1 The translucent droplet colonies of *Campylobacter fetus*, as seen on Skirrow’s media.

the VITEK 2, which showed susceptibility to ampicillin, cefuroxime, chloramphenicol, gentamicin, and imipenem. Imipenem was recommended, and the patient remained afebrile from the second day of imipenem treatment, then was discharged in asymptomatic condition 18 days post-identification of the organism, after completion of 22 days of antimicrobial therapy. There was no relapse found at 6, 12, and 18 months following discharge, but the child was diagnosed to have a ventricular septal defect at a subsequent cardiology clinic visit and investigations.

Discussion

A remarkable clinical feature of *C. fetus* is the potential to cause bacteremic illness, which may or may not have a focus of infection.⁵ This can be explained by the lack of *C. fetus*-specific opsonizing antibodies and effective phagocytosis in susceptible patient groups.² Bacteremia due to *C. fetus* has been rarely reported, reflecting an underestimated frequency and difficulties in laboratory identification, where it is grown in nonfavorable metabolic conditions. These inherent difficulties as well as the sporadic nature of the infection have contributed to lack of understanding of the disease. Experimental utilization of the recently developed pathogenesis model for *C. fetus* would enable elaboration of some of its clinical aspects in systemic infections.⁶

The source of *C. fetus* infection in patients often remains unknown. As in this case, gastrointestinal manifestations might be absent, and the organism is very rarely isolated in stool.⁷ In this particular case, the stool was consistently negative for *Campylobacter*. A history of contact with domestic animals and poultry is also not common. Despite the lack of epidemiological association, the typing methods suggest that the organism is transmitted through contaminated food to the gastrointestinal tract then to the circulation before being subsequently deposited in tissue foci.⁷ The reservoir of *C. fetus* can be zoonotic or environmental since the organism may survive for 24 hours in liquids and up to 3 weeks in the soil. This infant, who was exclusively breastfed, initially presented with a respiratory illness that might be attributed to the same organism since *C. fetus* has been reported to cause pneumonia,^{8,9} but the respiratory isolation media may not have favored its growth; subsequent respiratory samples aiming at isolating *C. fetus* on selective media at microaerophilic conditions failed to grow the organism. Thus, it can be interpreted either that such samples were collected following antimicrobial therapy or that the child might have had a viral respiratory infection along with *C. fetus* primary bacteremia. Nosocomial spread of *C. fetus* has

been described, necessitating strict enteric infection control measures in the admitting unit.³

The optimal antimicrobial treatment of this microorganism has not been determined in prospective comparative studies, and evidence is solely based on cohorts and case series. Although the in vitro testing generally reveals extreme susceptibility to multiple antimicrobials, it is recommended to treat *C. fetus* bacteremia with parenteral carbapenem, which maintains powerful anti-*Campylobacter* activity and prevents relapse.¹ Therapeutic failure or relapses were described following the use of other agents, despite in vitro sensitivity.^{10,11} The minimal inhibitory concentration of imipenem is 0.06 µg/mL compared with 4.0 µg/mL for penicillins.¹⁰ The use of cephalosporins is not advised, even in the case of susceptibility, since their bactericidal activity is weaker than that of other agents.^{11,12} Ciprofloxacin-resistance was also encountered in *C. fetus*.¹³ Gentamicin has been found to show very low minimum inhibitory concentrations for *C. fetus*, and a recent report from Quebec did not identify gentamicin-resistance among a large cohort of *C. fetus* strains.¹⁴ On the basis of anecdotal clinical experience and microbiological data, gentamicin can be used in a combination regimen to eradicate severe *C. fetus* endovascular infections.

The duration of treatment for *C. fetus*-related bacteremia is not well defined, but a minimum of 3 weeks of treatment has been suggested to avoid relapse.¹¹ Patients need to be followed for the potential of recurrence with fatal septic shock, even in immune-competent hosts.⁵ Although this patient was cured and did not show relapse at 6, 12, and 18 months follow-up, the relapsing nature of the illness and the mortality following relapse due to *C. fetus* bacteremia is reported to be as high as 30% – this can be reduced significantly when the infection is timely diagnosed, illustrating the importance of communication between clinician and the laboratory in early detection.^{1,8,13} The difficulty of identifying an organism from a sample type for which it is not routinely analyzed calls for a more collaborative multiteam approach, when treating a patient with undiagnosed illness. *Campylobacter* spp. are easily identified organisms in routine processing of stool, but they are difficult to spot in blood cultures, where the incubation conditions are not microaerophilic. Table 1 summarizes the general tropism features of various *Campylobacter* spp., which are proposed in secondary investigation of relevant clinical samples, when the routine specimen protocols fail to identify a common etiological pathogen. Mortality is associated with cancer, splenectomy, use of fluoroquinolones, and the lack of secondary clinical manifestations of bacteremia,¹⁴ none of which were present in the described case.

Table 1 General tropism of various *Campylobacter* species which are proposed in the secondary investigation of relevant clinical samples, when the routine specimen protocols fail to identify a common etiological pathogen

Tissue tropism	<i>Campylobacter</i> spp.
Intestinal	<i>C. jejuni</i> , <i>C. coli</i> , <i>C. lari</i> , <i>C. helveticus</i> , <i>C. upsaliensis</i>
Extraintestinal	<i>C. fetus</i> , <i>C. hyointestinalis</i> , <i>C. sputorum</i> , <i>C. jejuni</i> , <i>C. coli</i>
Dental	<i>C. concisus</i> , <i>C. curvus</i> , <i>C. rectus</i> , <i>C. showae</i>

Conclusion

A case of *C. fetus* bacteremia in an infant was presented. The condition was diagnosed by microbiological examination of a blood culture following correlation with clinical data. This report illustrates the difficulties in identifying an organism infrequently implicated in bloodstream infections of high-risk groups and the importance of laboratory readiness to provide an alternative identification algorithm based upon clinical needs. This review also calls for a greater liaison between the treating physician and clinical microbiologist, to optimize the management of a potentially life-threatening condition. For optimal health care, such cases need to be addressed in a patient-centered, multidisciplinary clinical environment.

Acknowledgments

The author thanks the technical team in the Microbiology laboratory of the King Fahad University Hospital, College of Medicine, University of Dammam, Saudi Arabia, for supporting the diagnosis of this case. A written informed consent was obtained from the patient's guardian for publication of this case report.

Disclosure

The author reports no conflict of interest in this work.

References

- Fujihara N, Takakura S, Saito T, Inuma Y, Ichiyama S. A case of perinatal sepsis by *Campylobacter fetus* subsp. *fetus* infection successfully treated with carbapenem – case report and literature review. *J Infect*. 2006;53(5):e199–e202.
- Blaser MJ, Newell DG, Thompson SA, Zechner EL. Pathogenesis of *Campylobacter fetus*. In: Nachmakin S, Blaser, editors. *Campylobacter*. 3rd ed. Washington, DC: ASM Press; 2008:401–428.
- Guerrant RL, Lahita RG, Winn WC Jr, Roberts RB. *Campylobacteriosis* in man: pathogenic mechanisms and review of 91 bloodstream infections. *Am J Med*. 1978;65(4):584–592.
- Anstead G, Jorgensen J, Craig F, Blaser M, Patterson T. Thermophilic multidrug-resistant *Campylobacter fetus* infection with hypersplenism and histiocytic phagocytosis in a patient with acquired immunodeficiency syndrome. *Clin Infect Dis*. 2001;32(2):295–296.
- Neuzil KM, Wang E, Haas DW, Blaser MJ. Persistence of *Campylobacter fetus* bacteremia associated with absence of opsonizing antibodies. *J Clin Microbiol*. 1994;32(7):1718–1720.

6. Grogono-Thomas R, Dworkin J, Blaser MJ, Newell DG. Roles of the surface layer proteins of *Campylobacter fetus* subsp. *fetus* in ovine abortion. *Infect Immun*. 2000;68(3):1687–1691.
7. Wassenaar TM, Newell DG. The genus *Campylobacter*. In: Dworkin M, Falkow S, Rosenberg E, Schleifer KH, Stackebrandt E, editors. *Prokaryotes*. 3rd ed. New York, NY: Springer; 2006;7:119–138.
8. Sakran W, Raz R, Levi Y, Colodner R, Koren A. *Campylobacter* bacteremia and pneumonia in two splenectomized patients. *Eur J Clin Microbiol Infect Dis*. 1999;18(7):496–498.
9. Targan SR, Chow AW, Guze LB. *Campylobacter fetus* associated with pulmonary abscess and empyema. *Chest*. 1977;71(1):105–108.
10. Francioli P, Herzstein J, Grob JP, Vallotton JJ, Mombelli G, Glauser MP. *Campylobacter fetus* subspecies *fetus* bacteremia. *Arch Intern Med*. 1985;145(2):289–292.
11. Gazonne L, Legrand P, Renaud B, et al. *Campylobacter fetus* bloodstream infection: risk factors and clinical features. *Eur J Clin Microbiol Infect Dis*. 2008;27(3):185–189.
12. Morooka T, Oda T, Shigeoka H. In vitro evaluation of antibiotics for treatment of meningitis caused by *Campylobacter fetus* subspecies *fetus*. *Pediatr Infect Dis J*. 1989;8(9):653–654.
13. Meier PA, Dooley DP, Jorgensen JH, Sanders CC, Huang WM, Patterson JE. Development of quinolone-resistant *Campylobacter fetus* bacteremia in human immunodeficiency virus-infected patients. *J Infect Dis*. 1998;177(4):951–954.
14. Tremblay C, Gaudreau C, Lorange M. Epidemiology and antimicrobial susceptibilities of 111 *Campylobacter fetus* subsp. *fetus* strains isolated in Québec, Canada, from 1983 to 2000. *J Clin Microbiol*. 2003;41(1):463–466.

Infection and Drug Resistance

Dovepress

Publish your work in this journal

Infection and Drug Resistance is an international, peer-reviewed open-access journal that focuses on the optimal treatment of infection (bacterial, fungal and viral) and the development and institution of preventive strategies to minimize the development and spread of resistance. The journal is specifically concerned with the epidemiology of antibiotic

resistance and the mechanisms of resistance development and diffusion in both hospitals and the community. The manuscript management system is completely online and includes a very quick and fair peer-review system, which is all easy to use. Visit <http://www.dovepress.com/testimonials.php> to read real quotes from published authors.

Submit your manuscript here: <http://www.dovepress.com/infection-and-drug-resistance-journal>