

Acute orbital apex syndrome and rhino-orbito-cerebral mucormycosis

Ursula M Anders¹

Elise J Taylor¹

Joseph R Martel¹⁻³

James B Martel¹⁻³

¹Research Center, Martel Eye Medical Group, Rancho Cordova, ²Graduate Medical Education, California Northstate University College of Medicine, Elk Grove, ³Department of Ophthalmology, Dignity Health, Carmichael, CA, USA

Purpose: To demonstrate the successful clinical identification and management of rhino-orbital mucormycosis, a fungal infection with a high mortality rate.

Patients and methods: A diabetic male patient with a headache and orbital apex syndrome in the right eye was examined using computed tomography (CT) and magnetic resonance imaging (MRI) for a possible fungal infection. Endoscopic surgical resection was performed and a pathology sample was taken. Specimens were prepared with Gömöri methenamine silver and hematoxylin and eosin staining. The patient was treated with liposomal amphotericin B 400 mg daily, followed by posaconazole 400 mg twice daily.

Results: CT and MRI revealed a mass of the right sphenoid spreading into the orbit, indicative of a fungal infection. The biopsy confirmed the diagnosis of mucormycosis. Complete recovery of eyelid and oculomotor function was achieved after 10 months of treatment, although the patient continues to suffer from irreversible blindness in the right eye due to optic nerve atrophy. He has been without signs or symptoms of recurrence.

Conclusion: Patients with rhino-orbito-cerebral mucormycosis need extensive surgical and medical treatment to maximize outcomes. Success requires multidisciplinary management.

Keywords: ophthalmoplegia, sixth nerve palsy, diabetes mellitus, nephrotoxicity, amphotericin B, posaconazole

Introduction

Orbital apex syndrome (OAS) is an uncommon clinical presentation consisting of complete ophthalmoplegia with vision loss, involving cranial nerves II, III, IV, V₁, and VI.¹ OAS may result from trauma, malignancy, infection, inflammation, or vascular origins. Some of these conditions, particularly among the infectious causes, can be life-threatening with delayed diagnosis and treatment. Rhino-orbito-cerebral mucormycosis (ROCM) is an invasive and often fatal fungal infection. The incidence of mucormycosis is increasing,^{2,3} with a current estimate of 1.7/1,000,000 cases in the US annually.⁴ In the emergent setting, any patient with OAS who is either immune compromised or diabetic should be evaluated for the presence of mucormycosis. We present a case of a successfully treated diabetic patient with OAS resulting from rhino-orbital mucormycosis who presented to the emergency department for treatment of headache symptoms.

Case report

A 68-year-old Hispanic male presented to the Emergency Department for severe headache, dizziness, and nausea. He had a past history of prostate cancer with 48 days

Correspondence: James B Martel
Graduate Medical Education,
California Northstate University
College of Medicine, 9700 West Taron
Drive, Elk Grove, CA 95757, USA
Tel +1 916 686 7300
Fax +1 916 686 7310
Email james.martel@cnsu.edu

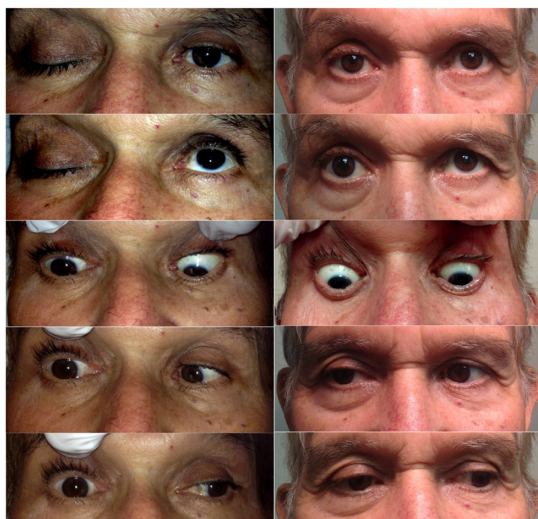

Figure 1 External examination of extraocular eye movements.

Notes: Images demonstrating complete ophthalmoplegia of the right eye with ptosis prior to surgery or amphotericin B treatment (left), followed by images obtained after 10 months showing full levator function with restoration of right extraocular eye movement in each position of gaze (right).

of ongoing radiotherapy, and an acoustic neuroma that was treated with gamma knife surgery 3 years prior to this presentation. Current medical history revealed poorly diet-controlled type 2 diabetes. He was noted to have significantly decreased ocular motility and loss of vision in his right eye. Ophthalmologic examination revealed no light perception and ophthalmoplegia in the right eye (Figure 1) with impairment of cranial nerves II, III, IV, V₁, and VI, culminating in a diagnosis of OAS. Fundusoscopic examination showed no significant abnormalities.

A computed tomography (CT) scan of the brain showed bilateral opacification of the ethmoids, near complete opacification of the right sphenoid, and mild mucosal thickening in the left sphenoid and maxillary sinuses (Figure 2). Hyperintense T2 signals of the right sphenoid sinus shown on MRI suggested the presence of fungal involvement. ENT evaluated the patient and concurred with the possible diagnosis of mucormycosis.

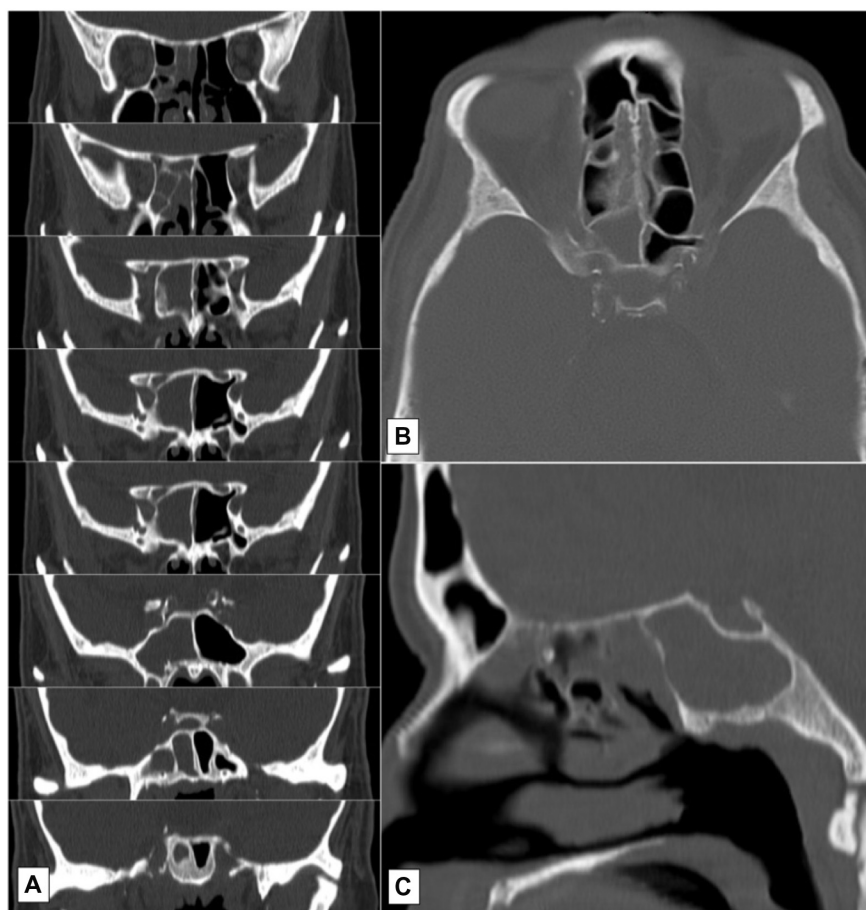

Figure 2 CT scan of the brain, without contrast.

Notes: CT scan displaying bilateral opacification of the ethmoids, near complete opacification of the right sphenoid, and mild mucosal thickening in the left sphenoid and maxillary sinuses with extension into the orbit. The coronal sectional image illustrates the proximity of the lesion next to the foramen rotundum and optic nerve foramen (A). The axial cross section discloses the opacification being significantly more affected on the right side of the sphenoid and ethmoid sinus, with some thickening on the left sphenoid sinus region. There is also involvement of the right middle and posterior orbital cavity adjacent to the optic foramen (B). The sagittal section illustrates the opacity reaching back toward the nasopharynx. The inferior, middle, and superior turbinates are also affected, with some suggestion of involvement of the cribriform plate (C).

Abbreviation: CT, computed tomography.

Endoscopic surgical resection was performed by ENT, and a pathology sample was taken. Histopathology of tissue stains showed positivity for mucormycosis (Figure 3). The patient subsequently underwent aggressive endoscopic removal of the involved tissue. The patient was treated with liposomal amphotericin B 400 mg, IV, postsurgery. After 3 weeks, he experienced some minor nephrotoxicity as a side effect of the liposomal amphotericin B, and was switched to posaconazole 400 mg twice daily for 2 months. After 10 months, there was complete resolution of ophthalmoplegia, although there was evidence of presynaptic atrophy of the right optic nerve (Figure 4).

Written informed consent was obtained from the patient to allow the publication of photographs for educational purposes. This study adhered to the tenets of the Declaration of Helsinki and was Health Insurance Portability and Accountability Act (HIPAA) compliant. Dignity Health Institutional Review Committee ruled that approval was not required for this study.

Discussion

OAS is a common presentation of ROCM, but unfortunately blindness is permanent and the risk of mortality is increased at this stage of progression. Mucormycosis is the third most frequent fungal disease after candidiasis and aspergillosis,³ and is more likely to cause OAS.⁵ Prime susceptibility factors for ROCM include diabetes mellitus, ketoacidosis, immunosuppression, and elevated levels of serum iron.^{5,6} Elevated blood glucose levels and change in acidity levels nourish fungal colonies, and increased availability of unbound serum iron in acidotic conditions aids in the growth of fungus and development of vascular invasion.⁷ Angioinvasion with thrombus and further tissue necrosis is the most likely mechanism of the sinus disease spreading into the orbit and brain.

Mucormycosis can be difficult to identify if indicators such as thrombosis and necrotic tissue are absent or are late in presentation. Thurtell et al⁵ reported 14 patients with biopsy proven ROCM and OAS, with only one patient being correctly diagnosed at presentation. In diabetics, OAS secondary

to ROCM may initially present as a sixth nerve palsy or partial ophthalmoplegia and is felt to represent microvascular disease, particularly when there is minimal disease sinus findings by CT.⁸ When any sinus disease with OAS is observed in a diabetic or immunocompromised patient by CT or MRI, a fungal etiology should be suspected. MRI is an effective technique in diagnosing OAS, with biopsy being the most reliable.

Mucormycosis is a highly aggressive infection known to have a high mortality rate when not treated. Survival rates depend on the interval period from appearance of symptoms to onset of treatment or surgery, extent and location of the infection, type of treatment, and amount of immunosuppression. Roden et al² published a review of infectious patterns and outcomes of 929 patients with zygomycosis between 1885 and 2005. The most common sites of infection were sinus (39%), pulmonary (24%), and cutaneous (19%). Of the sinus infections, 21% of patients had rhinocerebral involvement, 8% had sino-orbital involvement, and 8% had sinusitis. Of these, the mortality rates were 62%, 24%, and 16%, respectively. Orbital involvement is unilateral,⁹ and the survival rate decreases dramatically with bilateral sinus involvement.⁶

Amphotericin B has been the antifungal of choice since the first successful treatment of this disease by Gass in 1961.^{6,10} Liposomal amphotericin B has similar or better survival rates than amphotericin B with less nephrotoxicity.^{4,6,9} However, in this case the patient still developed mild nephrotoxicity and was switched to posaconazole. Posaconazole is useful as a secondary treatment when kidney function is affected, and is more effective against Mucorales in vitro than other triazoles.^{4,9} Optimal therapy requires a multidisciplinary approach between internists and ENT, ophthalmology, and infectious disease specialists.

Disclosure

The authors report no conflicts of interest in this work.

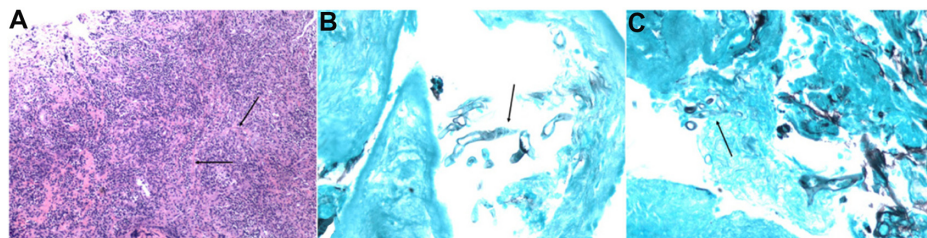


Figure 3 Histopathology slides.

Notes: Hematoxylin and eosin stain (200×) obtained from mucosal tissue of the ethmoid sinus showing necrotic and edematous tissue with neutrophilic infiltrate. There are also hyphae noted in this section, indicated by the arrows (A). Two Gömöri methenamine silver stains (400×) from the same biopsy showing broad, aseptate hyphae with right angle branching, also indicated by the arrows (B and C).

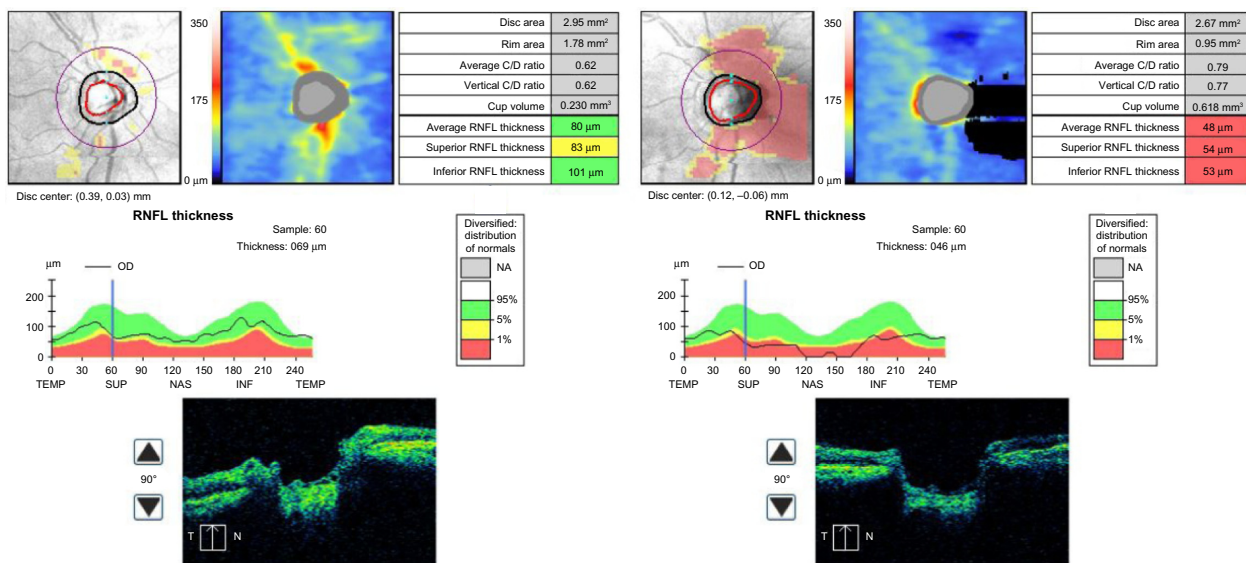


Figure 4 Optical coherence tomography.

Notes: Cirrus-HD optical coherence tomography (Carl Zeiss Meditec, Inc., Oberkochen, Germany) of the right optic nerve at initial presentation (left), followed by an additional scan obtained 10 months later demonstrating enlargement of the physiologic cup and generalized loss of retinal nerve fiber displaying gradual presynaptic atrophy of the right optic nerve (right).

Abbreviations: RNFL, retinal nerve fiber layer; C/D, cup to disc; T/TEMP, temporal; SUP, superior; N/NAS, nasal; INF, inferior; HD, high definition; OD, right eye; NA, not available.

References

- Anders UM, Taylor EJ, Martel JR, Martel JB. Pseudo-orbital apex syndrome in the acute trauma setting due to ipsilateral dissection of internal carotid artery. *Ophthalm Plast Reconstr Surg*. Epub September 11, 2014.
- Roden MM, Zaoutis TE, Buchanan WL, et al. Epidemiology and outcome of zygomycosis: a review of 929 reported cases. *Clin Infect Dis*. 2005; 41(5):634–653.
- Di Carlo P, Pirrello R, Guadagnino G, et al. Multimodal surgical and medical treatment for extensive rhinocerebral mucormycosis in an elderly diabetic patient: a case report and literature review. *Case Rep Med*. 2014;2014:527062.
- Gamaletsou MN, Sipsas NV, Roilides E, Walsh TJ. Rhino-orbital-cerebral mucormycosis. *Curr Infect Dis Rep*. 2012;14(4):423–434.
- Thurtell MJ, Chiu AL, Goold LA, et al. Neuro-ophthalmology of invasive fungal sinusitis: 14 consecutive patients and a review of the literature. *Clin Exp Ophthalmol*. 2013;41(6):567–576.
- Yohai RA, Bullock JD, Aziz AA, Markert RJ. Survival factors in rhino-orbital-cerebral mucormycosis. *Surv Ophthalmol*. 1994;39(1): 3–22.
- Sravani T, Uppin SG, Uppin MS, Sundaram C. Rhinocerebral mucormycosis: pathology revisited with emphasis on perineural spread. *Neurol India*. 2014;62(4):383–386.
- Balch K, Philips HP, Newman NJ. Painless orbital apex syndrome from mucormycosis. *J Neuroophthalmol*. 1997;17(3):178–182.
- Toumi A, Larbi Ammari F, Loussaief C, et al. Rhino-orbital-cerebral mucormycosis: five cases. *Med Mal Infect*. 2012;42(12):591–598.
- Sponsler TA, Sassani JW, Johnson LN, Towfighi J. Ocular invasion in mucormycosis. *Surv Ophthalmol*. 1992;36(5):345–350.

International Medical Case Reports Journal

Publish your work in this journal

The International Medical Case Reports Journal is an international, peer-reviewed open-access journal publishing original case reports from all medical specialties. Previously unpublished medical posters are also accepted relating to any area of clinical or preclinical science. Submissions should not normally exceed 2,000 words or

Submit your manuscript here: <http://www.dovepress.com/international-medical-case-reports-journal-journal>

4 published pages including figures, diagrams and references. The manuscript management system is completely online and includes a very quick and fair peer-review system, which is all easy to use. Visit <http://www.dovepress.com/testimonials.php> to read real quotes from published authors.

Dovepress