

The p53 breast cancer tissue biomarker in Indian women

Vinayak W Patil¹
 Mukund B Tayade²
 Sangeeta A Pingale¹
 Shubhangi M Dalvi¹
 Rajesh B Rajekar¹
 Hemkant M Deshmukh¹
 Shital D Patil¹
 Rajeev Singhai¹

¹Department of Biochemistry,
²Department of General Surgery,
 Grant Medical College and Sir JJ
 Group of Hospitals, Mumbai, India

Background: Combination chemotherapy is highly effective in locally advanced breast cancer. A negative expression of biomarker p53 indicates a higher chance of responding to this regimen. Patients' p53 status may be used as a biological cancer marker to identify those who would benefit from more aggressive treatments.

Aims: The role of p53 in modulating apoptosis was suggested that it may affect the efficacy of anticancer agents. p53 alterations in 80 patients with locally advanced breast cancer IIIB undergoing neoadjuvant chemotherapy were prospectively evaluated.

Materials and methods: Patients received three cycles of paclitaxel (175 mg/m²) and doxorubicin (60 mg/m²) every 21 days. Tumor sections were analyzed before treatment for altered patterns of p53 expression, using immunohistochemistry and DNA sequencing.

Results: An overall response rate of 83.5% was obtained, including 15.1% complete pathological responses. The regimen was well tolerated with 17.7% grade 2/3 nausea and 12.8% grade 3/4 leukopenia. There was a statistically significant correlation between response and expression of p53. Of 20 patients who obtained a complete clinical response, only two were classified as p53-positive ($P = 0.004$, χ^2). Of 11 patients who obtained a complete pathological remission, one was positive ($P = 0.099$, χ^2).

Conclusion: Immunohistochemical (IHC) analysis has been shown to be a prognostic factor for patients with breast cancer in India. Paclitaxel is one of the most promising anticancer agents for the therapy of breast cancer, where it has also shown activity in tumors resistant to doxorubicin.

Keywords: breast cancer, doxorubicin, p53, paclitaxel, cancer tissue biomarkers, neoadjuvant chemotherapy, immunohistochemistry, infiltrating duct cancer

Introduction

Doxorubicin and paclitaxel have been tested in a variety of schedules and sequences to exploit the high therapeutic potential of the two drugs in metastatic breast cancer.¹ An initial study indicated that the tolerability of the combination was sequence dependent if paclitaxel was infused over at least 24 hours, independently of the schedule for doxorubicin administration.² Taking advantage of the safety and feasibility of a short infusion of paclitaxel, the study showed that tolerability did not depend on sequence and that the combination was highly effective in metastatic breast cancer.³

Although the interactions of paclitaxel with the cytoskeleton are well characterized, the molecular mechanisms by which such an interaction leads to cell-cycle arrest and cytotoxicity are not well understood. Recent evidence suggests that

Correspondence: Rajeev Singhai
 Department of Biochemistry, Grant
 Medical College and Sir JJ Group of
 Hospitals, Mumbai 400008, India
 Tel +91 969 998 56615
 Email dr.rajeevj@gmail.com

paclitaxel alters certain intracellular signal-transduction events, such as activation of mitogen-activated protein kinase and transcriptional activation of genes encoding a number of cytokines.^{4,5} In breast cancer, mutations in the p53 gene have been demonstrated by our group and others to be the most frequently observed single gene alteration.⁶ Deoxyribonucleic acid (DNA) damage caused by various chemotherapeutic agents leads to an increase in the level of tumor-suppressor gene p53, followed by a G1 cell-cycle arrest, and, subsequently, apoptosis. The p53 protein is a multifunctional transcriptional regulator involved in the cellular response to DNA damage, and has been implicated as a putative determinant of tumor cell sensitivity to cytotoxic agents.^{7,8}

The tumor suppressor function of wild-type p53 is lost following activating mutation of the p53 gene. Interestingly, the mutated gene product appears to play an active role in tumor progression via a dominant negative effect. It has been proposed that the dominant effect of p53 mutants may reflect interaction of the mutant protein with wild-type p53, thereby inactivating the suppressor function of the latter. This suggestion gains credence from a report of mutant p53 binding to wild-type p53 in cells containing high-expression vectors for the mutant protein.¹⁴

The efficacy and feasibility of a combination of paclitaxel and doxorubicin as preoperative treatment for locally advanced breast cancer and the impact of the expression of the tumor suppressor gene p53 on response rate and overall survival was investigated for the present study.

Materials and methods

Patients who were diagnosed with breast cancer and underwent curative surgery from May 2007 to December 2010 at Grant Medical College and Sir JJ Group of Hospitals, Mumbai, India, were included in the study. Tissue samples were taken from 80 breast cancer patients. Expression of p53 was analyzed in specimens of invasive duct breast cancer tissue during modified radical mastectomy. This study protocol was approved by the Institutional Ethics Committee of Grant Medical College and Sir JJ Group of Hospitals, Mumbai, India (No IEC/Pharm /36/07).

The p53 immunohistochemical breast cancer tissue biomarkers were analyzed in specimens of invasive duct breast cancer tissue of Indian women after radical mastectomy and lumpectomy. Eighty women who had primary locally advanced breast cancer in stage IIIB, T4b, N1–2, and M0, according to the tumor, node, and metastasis staging system,

were enrolled in the treatment. Patients' median tumor size was 8.4 cm, ascertained by physical examination and mammography. Patients were required to have histopathological proof of invasive duct cancer, to be at least 18 years of age, have a performance status of 90% on the Karnofsky scale, have a serum bilirubin level <0.5 mg/dL, serum creatinine level <1.5 mg/dL, absolute granulocyte count $\geq 1500/\text{mm}^3$, platelet count $\geq 100,000/\text{mm}^3$, and normal cardiac function. All patients performed an ejection fraction test multigated acquisition scan before the first cycle and 3 weeks after the third cycle of chemotherapy. Mammographies, computed tomography scans of the chest and abdomen, and bone scans were performed before entering the trial to ensure the absence of metastatic disease.

Immunohistochemistry

Tissue samples were fixed in 10% neutral-buffered formalin for 12–24 hours. Tissue samples were processed in an auto-processor, embedded in paraffin wax, and cut, using a microtome, into 4 μm thick sections that were dried overnight at 37°C. Prior to antibody staining, the slides were pretreated with microwave irradiation to unmask binding epitopes, after blocking of endogenous peroxidase activity with a 3% solution of hydrogen peroxide in methanol for 30 minutes. Slides were then immersed in 200 mL of 10 mM citric acid (pH 6.0) for 5 minutes at a power level of 100 W, then subjected to four cycles of 5 minutes each at 50 W power. After the buffer was topped up with distilled water, this step was repeated. The slides were then left to stand for 10 minutes in buffer at room temperature before being washed thoroughly in tap water.

After three washes in Tris-buffered saline (TBS), (T6664; Sigma-Aldrich Co, St Louis, MO) the slides were incubated with a 1:25 dilution of mouse anti-p53 monoclonal primary antibody (clone: DO-7; M7001; DakoCytomation, Copenhagen, Denmark) in TBS for 1 hour at room temperature. After three more washes in TBS, the secondary antibody (K0355; DakoCytomation) biotinylated goat antibody linked to mouse/rabbit immunoglobulin diluted 1:100 in TBS was applied for 1 hour at room temperature. After an additional three washes, streptavidin-biotin/horseradish peroxidase (HRP) complex (K0355; DakoCytomation) dilute antibody (1:50) in TBS was applied for 1 hour at room temperature. After an additional three washes, the staining was visualized by adding diaminobenzidine kit (K3467; DakoCytomation) for 5 minutes at room temperature. The slides were washed well in tap water and counterstained with

Harris's hematoxylin (HHS128; Sigma-Aldrich) for 10 seconds to 1 minute and then dehydrated, cleared, and mounted in distyrene plasticizer xylene (DPX) (44581-DPX mountant; Sigma-Aldrich). Positive and negative controls were performed with each batch of slides. Surgical specimens from the same patient were stained on the same run.²⁵

Each entire stained slide was scanned for immunostaining evaluation by light microscope. The image collection and microphotographs were taken using an Axio Imager M1 Microscope with AxioVision software (v 4.7 SFM; Carl Zeiss Microscopy, Jena, Germany). Slides were checked under a 10× objective to confirm that the cells were still attached to the slides, then examined under 400× objective magnification. All images were taken under 400× objective magnification without oil immersion. All images were processed with AxioVision software (Carl Zeiss Microscopy).

Analysis of scoring methods

Tumors with an immunohistochemical (IHC) score of ≥ 2 for p53 were considered positive for p53 protein accumulation. Scoring was as follows.

- <10% tumor cell nuclei staining for p53 = 0 (negative score)
- 10%–30% tumor cell nuclei staining for p53 = 1+
- 31%–50% tumor cell nuclei staining for p53 = 2+
- 50% tumor cell nuclei staining for p53 = 3+.

Scoring criteria for p53 represented as the proportion of nuclear staining are thus:

- none = 0
- <1/10 = score of 1
- 1/10–1/2 = score of 2
- 1/2 = score of 3.

True p53 positivity is given by nuclear staining only. The p53 protein expression represents an adverse prognostic cancer biomarker in inflammatory breast cancer. It is a rare but aggressive variant and may provide a valuable tool for selecting treatment.

Statistical analysis

Immunohistochemical results estimation was performed using the log-rank test and using SPSS-16 procedure (SPSS-16 Analytical Software Inc, Chicago, IL). For statistical analysis, differences in proportions were evaluated by the χ^2 test or Fisher's exact test. Survival was estimated using the Kaplan–Meier method, and differences among groups were tested by the log-rank test. For all statistical tests, differences were considered significant at $P < 0.05$.

Protocol of chemotherapy

Following standard premedication with glucocorticoids and histamine type H1/H2 receptor blockers, doxorubicin (60 mg/m²) was administered as a bolus infusion followed by paclitaxel (175 mg/m²) infused over 3 hours. Chemotherapy was given every 3 weeks for three cycles. On the completion of chemotherapy, all patients were given a modified radical mastectomy with axillary dissection. After recovery from surgery, all patients received systemic chemotherapy and adjuvant tamoxifen for 5 years when the estrogen receptor was positive. All patients underwent external beam irradiation using a 6 MeV linear accelerator (Siemens Model 6740; Siemens AG, Munich, Germany).

Size of primary breast tumors was determined immediately before administration of each cycle of chemotherapy and before surgery. Before the first cycle and in the week before surgery, mammography was performed. At each assessment, the product of the two greatest perpendicular diameters was used to quantify the tumor. In the absence of clinical evidence of tumor in the breast, response to therapy was categorized as a complete clinical response (CCR). When the diameters decreased by 50% or more, the response was judged to be a partial response. Patients with reductions of between 25% and 50% were categorized as having stable disease (ESD). Progression of disease was categorized as an increase of at least 25%. Surgical specimens were evaluated for their histopathological tumor status and were further classified as complete pathological responders with no histopathological evidence of invasive tumor cells, or with histopathological evidence of invasive cells.

Staining results were interpreted independently. In each case, the entire section was systemically examined under high-power fields (400×) for p53 immunoreactivity. Among all immunoreactive nuclei, only those clearly and strongly immunostained were recorded as being p53 positive. Level of immunoreactivity was expressed as the percentage of p53-positive cancer cell nuclei. Staining was considered positive if at least 10% of tumor cell nuclei stained positively compared with corresponding controls. Samples classified as positive were also analyzed at the molecular level by DNA sequencing. Genomic DNA was extracted from paraffin blocks and sequences corresponding to the functional domains L2, L3, and the loop-sheet-helix of the p53 protein was amplified by polymerase chain reaction. DNA sequencing was performed using the ABI Prism™ 377 DNA Sequencer (Applied Biosystems, Foster City, CA) and the DNA sequencing kit BigDye Terminator Cycle Sequencing

(Applied Biosystems) as described elsewhere.⁸ Patients were cross classified by p53 expression and by clinical responses to chemotherapy.

Results

Each entire stained slide was scanned for immunostaining evaluation by light microscopy. The image collection and microphotographs were taken using an Axio Imager. M1 microscope with AxioVision software (Carl Zeiss Microscopy). Slides were checked under a 10× objective to confirm that the cells were still attached to the slides, then examined under 400× objective magnification. All images were taken under 400× objective magnification without oil immersion and were processed with AxioVision software (Carl Zeiss Microscopy).

Immunohistochemical staining was conducted on 80 samples of infiltrating duct cancer of the breast. Each entire slide was scanned for immunostaining evaluation by light microscopy. Tissue sections exhibiting distinct nuclear immunoreactivity for p53 in tumor cells were identified as positive, as shown in Figure 1A; negative staining of tumor cells is shown in Figure 1B. All patients completed the planned three cycles of therapy and were therefore assessable for overall clinical locoregional tumor response. CCR, as previously defined, was documented in 25 patients (34.2%). Thirty patients (49.3%) achieved a CPR and 12 patients (16.4%) were classified as CSD, resulting in an overall response rate to the regimen of 83.5%. No cases of progressive disease during treatment were observed. Histopathologic examination of breast tissue from all 80 patients showed no evidence of residual cancer in 11 specimens (15.1%) and only noninvasive tumors (ductal carcinoma in situ) in three (4.11%). Seven cases were not reported because tissue were insufficient for processing.

Chemotherapy was generally well tolerated. In 219 delivered cycles, grade 2/3 nausea and vomiting was present in 16.8% of patients; grade 3/4 leukopenia occurred in 13.2% (n = 8) patients, who required hospitalization and intravenous antibiotics due to febrile neutropenia. Alopecia was universal in all patients. There were no toxicity-related deaths. The median ejection fraction before chemotherapy was 66% (range 54–84). After the three cycles of chemotherapy the median ejection fraction was 62% (range 44–76). Seven patients (9.6%) had a cardiac ejection fraction test below 50% after the three cycles of treatment. One patient developed cardiac failure, requiring clinical intervention 10 months after completion of treatment. This relatively good

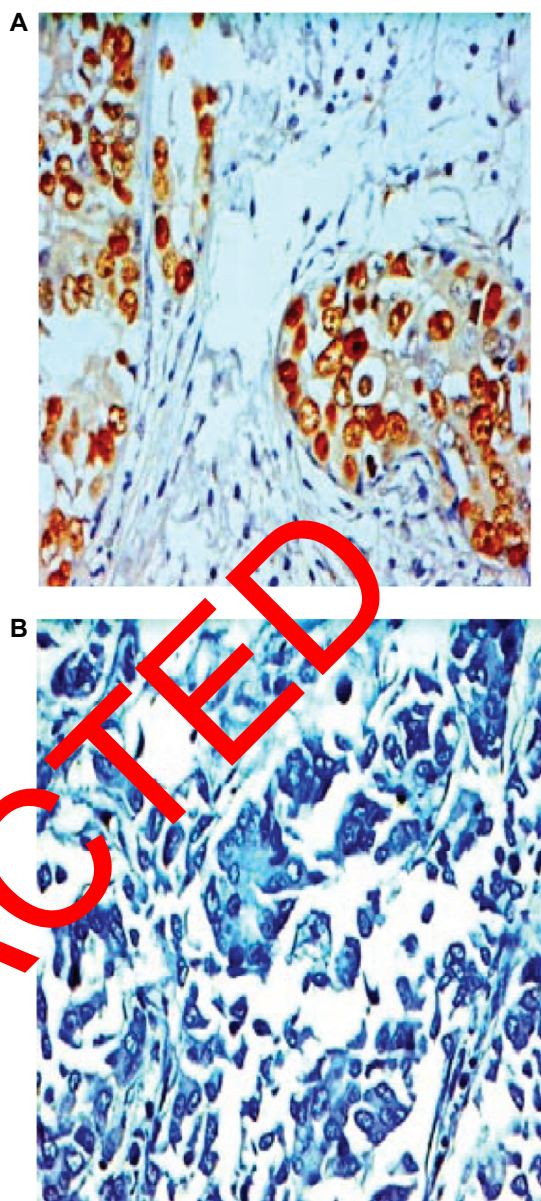


Figure 1 Immunostaining of infiltrating duct breast cancer, 400× objective magnification; **(A)** dark brown positive nuclear staining for p53 and **(B)** negative nuclear staining for p53.

toleration of the drug regimen was reflected in the high relative dose intensity that could be achieved during the three cycles of primary chemotherapy, with 90.4% of the cycles being delivered on the scheduled date.

A high level of p53 immunoreactivity was seen in 30.1% of patients. Direct sequencing of these tumors identified two mutations on codon 259, causing an amino acid change from asparagine (GAC) to tyrosine (TAC). Response to chemotherapy was correlated with p53 expression as shown in Table 1 and Figure 2, where 23 patients with p53-negative tumors obtained a complete clinical remission compared

Table 1 p53 expression and response to preoperative chemotherapy

	Clinical outcome			Total
	Stable disease	Partial response	Complete response	
p53-positive	3	17	2	22
p53-negative	9	19	23 ^a	51
Total	12	36	25	73

Notes: Seven cases were not reported because tissues were insufficient for processing; ^a $P = 0.004$; χ^2 -test.

with two patients with p53-positive tumors ($P = 0.004$, χ^2). There was also a trend towards statistical significance when p53 expression was correlated with the achievement of a complete pathological response. Eleven patients achieved a complete pathological response, 10 of whom were classified as p53-negative ($P = 0.099$, χ^2). Overall survival was also influenced by p53 expression, showing a statistical advantage for those patients with p53-negative tumors ($P = 0.0023$, log-rank), as shown in Figure 3.

Seven cases were not reported because tissues were insufficient for processing. Overall survival is also changed among those patients who achieved a complete pathological response as shown in Figure 4 ($P = 0.017$, log-rank).

Discussion

Detection of p53 mutations in plasma DNA may be used as a prognostic factor and an early marker to indicate recurrence or distant metastasis.

Breast cancer continues to frustrate oncologists worldwide. In India, it is the second most common neoplasia among women and is increasing in incidence. Several molecular cancer biomarkers have been associated with a poor prognosis in patients with breast cancer and the presence of these

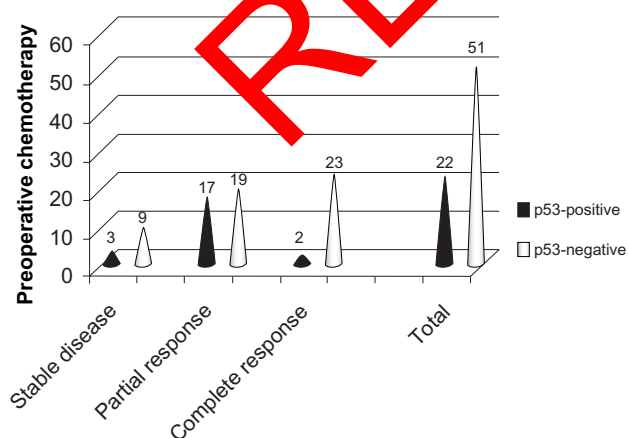


Figure 2 p53 expression and response to preoperative chemotherapy.

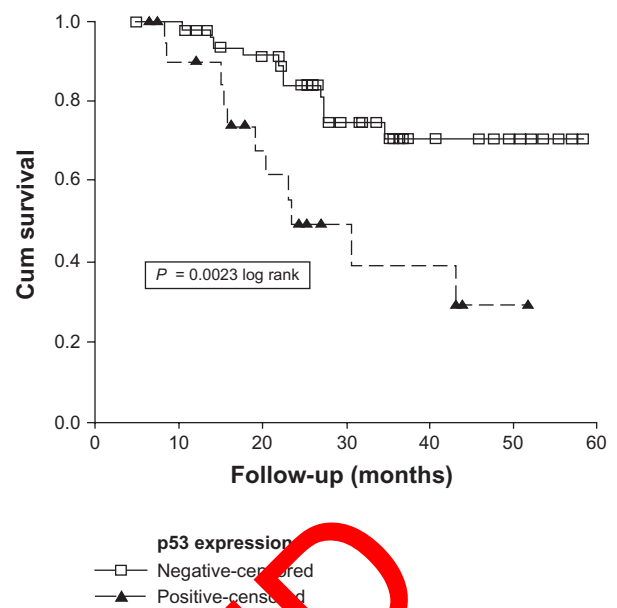


Figure 3 Overall survival for all patients and p53 expression by immunohistochemistry in breast cancer in a group of Indian women.

markers is often thought to provide information on the biological behavior of the malignant breast tumor. Much attention has recently been focused on the tumor suppressor gene p53. Mutation or alteration in this gene leads to the loss of negative growth regulation and hence to rapid cell proliferation.

Several randomized prospective studies on breast cancer patients have proved the safety of neoadjuvant chemotherapy.^{23,24} The tumor down-staging does improve

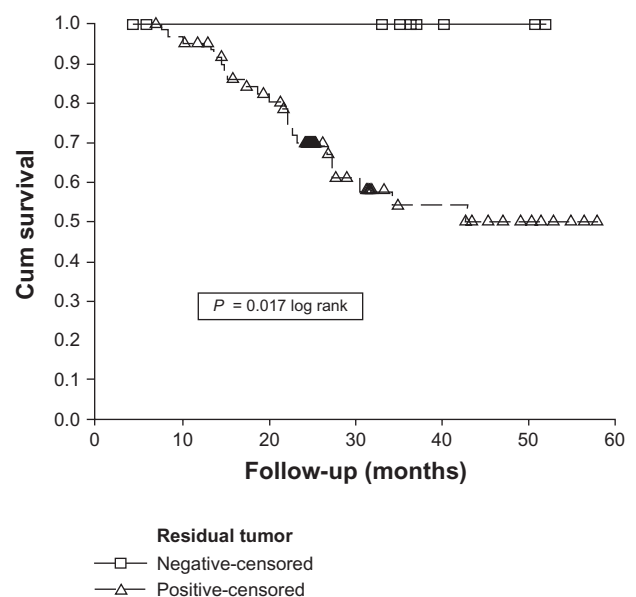


Figure 4 Overall survival for all patients with respect to the presence of residual tumor.

eligibility for breast-conservative surgery without increasing local recurrence rates, with possibly an improved survival. Identification of predictive markers associated with pathologic complete response could help to distinguish patients with high or low probability of a response to treatment so that an individualized treatment plan could be implemented. It could also streamline the development of new alternative regimens for those who are unlikely to benefit from existing drugs. It is expected that a combination of several cancer biomarkers will be more informative than a single one. So far, several factors have been studied as predictors for response to cytotoxic treatment, including tumor size, hormone receptor status, tumor type, and differentiation.^{23,24}

Paclitaxel is one of the most promising anticancer agents for the treatment of breast cancer, where it has also shown activity in tumors resistant to doxorubicin.⁹ Combination of both drugs resulted in high response rates in metastatic disease, with no impact, however, on overall survival or on disease-free survival.¹⁰⁻¹² This combination has been previously used in the neoadjuvant setting by Moliterni et al, who reported an overall response rate of 88%.¹³ Notable in this trial is that only 41% of the women were clinically staged as having locally advanced disease, favoring the high response rate in more initial stages. In the present study, an overall response rate of 83.5%, including 15.1% CPR, was achieved, confirming the high efficacy of this regimen. Therefore, it is important to understand if there are cellular factors that can play a role in determining the response of breast tumors to the combination of paclitaxel and doxorubicin. The p53 protein plays a central role in the response to anticancer treatment. It has been shown that in different cell types, the presence of a wild-type p53 induces sensitization to DNA-damaging agents, although more recent evidence of a wild-type p53-induced chemoresistance has been described.¹⁴ The role of p53 in the intrinsic sensitivity of human cancer cells to paclitaxel remains controversial. While paclitaxel resistance is primarily conferred by tubulin mutations, the loss of functional p53 observed in some cell lines suggests that this loss may facilitate the development of resistance potentially by providing a clonal advantage that promotes the isolation of paclitaxel resistant cells.¹⁴ In a study published by the European Organization for Research and Treatment of Cancer, 114 women with metastatic breast cancer were treated with paclitaxel or doxorubicin and all specimens were assessed by immunohistochemistry using monoclonal antibodies against HER-2/neu, p53 and bcl-2.¹⁵ The results

of this study were correlated with clinical response to therapy and the authors found no correlation between the expression of any of the cancer tissue biomarkers and the clinical response to either agent. Paclitaxel, which does not interact directly with DNA, was found to be able to activate p53 in some cell types, and this increase has been associated mainly with its ability to activate the Raf-1 cascade.¹⁶ In cell cultures, including one human ovarian cancer cell line, p53 expression was not increased after paclitaxel treatment, and the presence of a wild-type p53 did not result in a change in sensitivity to paclitaxel with respect to cells expressing mutated p53.¹⁷ The presence of wild-type p53 has been reported to decrease the cytotoxicity of paclitaxel compared with the same cell lines not expressing wild-type p53. This was explained on the basis of a p53-dependent block in G1 after treatment that would prevent the cell from progressing to G2-M, where paclitaxel is known to exert its activity.^{17,18} Another report, however, showed that in a human ovarian cancer cell line, disruption of wild-type p53 did reduce the cytotoxicity induced by paclitaxel.¹⁹ Several studies have shown overexpression of p53 to be a strong prognostic indicator in infiltrating duct cancer, although a recent consensus statement by the College of American Pathologists categorizes p53 protein overexpression as a category two parameter for this reason.^{20,23} This category means that the clinical relevance should be tested in well-designed studies with validation of the methodology in individual laboratories. The p53 immunohistochemistry assays detect overexpression of the gene, which is often related to conformational alterations and a prolonged half-life of the encoded protein. The p53 mutations that generate truncated proteins, like nonsense and splicing mutations, do not correlate with p53 overexpression,²¹ but this kind of mutation is observed only in a minority of cases.²² Routine sequencing of the p53 gene in all breast cancers would be highly costly and time consuming in daily practice. So, the validation of immunohistochemistry is the most critical step in using it as a prognostic factor.²³ In the authors' laboratory, the p53 immunohistochemical procedure is very well standardized and only cases with distinct and strong nuclear staining of more than 10% of nuclei were considered positive.

In this study, the response to chemotherapy was correlated with p53 expression, with a significant statistical advantage among those patients with p53-negative tumors. The same advantage was observed when p53 expression was correlated with the odds of a complete pathological response. Since overall survival is changed among those patients who

achieved a complete histopathological response, determination of the p53 status may be used as a biological marker to identify those patients who would benefit from more aggressive treatments.

Adjuvant systemic chemotherapy has been shown to prolong survival in all subsets of patients with breast cancer. In addition, among patients with locally advanced breast cancer, neoadjuvant or preoperative chemotherapy has improved the ability to perform breast-conserving therapy.^{24–26}

Conclusion

IHC analysis has been shown to be a prognostic factor for patients with breast cancer in India. Paclitaxel is one of the most promising anticancer agents for the therapy of breast cancer, where it has also shown activity in tumors resistant to doxorubicin. Adjuvant systemic chemotherapy has been shown to prolong survival in all subsets of patients with breast cancer. In addition, among patients with locally advanced breast cancer, neoadjuvant or preoperative chemotherapy has improved the ability to perform breast-conserving therapy. The p53 expression was correlated with the odds of a complete histopathological response. Since overall survival is changed among those patients who achieved a complete histopathological response, determination of the p53 status may be used as a biological cancer marker to identify those patients who would benefit from more aggressive treatments.

Acknowledgment

Thanks to all members of the histopathology sections of Grant Medical College and Sir JJ Group of Hospitals, Mumbai, India, for providing surgical specimen tissue samples.

Disclosure

The authors report no conflicts of interest in this work.

References

- Holmes FA, Valero V, Walters RS, et al. Paclitaxel by 24-hour infusion with doxorubicin by 48-hour infusion as initial therapy for metastatic breast cancer: phase I results. *Ann Oncol.* 1999;10(4):403–411.
- Holmes FA, Madden T, Newman RA, et al. Sequence dependent alteration of doxorubicin pharmacokinetics by paclitaxel in a phase I study of paclitaxel and doxorubicin in patients with metastatic breast cancer. *J Clin Oncol.* 1996;14(10):2713–2721.
- Gianni L, Munzone E, Capri G, et al. Paclitaxel by 3-hour infusion in combination with bolus doxorubicin in women with untreated metastatic breast cancer: high antitumor efficacy and cardiac effects in a dose-finding and sequence-finding study. *J Clin Oncol.* 2000;13(11):2688–2699.
- Horwitz SB. Taxol (paclitaxel): mechanisms of action. *Ann Oncol.* 1994;5(Suppl 6):S3–S6.
- Motwani M, Delohery TM, Schwartz GK. Sequential dependent enhancement of caspase activation and apoptosis by flavopiridol on paclitaxel-treated human gastric and breast cancer cells. *Clin Cancer Res.* 1999;5(7):1876–1883.
- Anelli A, Anelli TF, Youngson B, Rosen PP, Borgen PI. Mutations of the p53 gene in male breast cancer. *Cancer.* 1995;75(9):2233–2238.
- Bonetti A, Zaninelli M, Leone R, et al. Bcl-2 but not p53 expression is associated with resistance to chemotherapy in advanced breast cancer. *Clin Cancer Res.* 1998;4(10):2331–2336.
- Miller CW, Aslo A, Tsay C, et al. Frequency and structure of p53 rearrangements in human osteosarcomas. *Cancer Res.* 1990;50(24):7950–7954.
- Gianni L, Capri G, Munzone E, Straneo M. Paclitaxel (Taxol) efficacy in patients with advanced breast cancer resistant to anthracyclines. *Semin Oncol.* 1994;21(5 Suppl 8):29–33.
- Hortobagyi GN, Holmes FA, Theriault RL, Rahman Z, Buzdar AU. Combination chemotherapy with paclitaxel and doxorubicin for metastatic breast cancer. *Semin Oncol.* 1997;24(4 Suppl 1):S11–S19.
- Hortobagyi GN, Holmes FA. Optimal dosing of paclitaxel and doxorubicin in metastatic breast cancer. *Semin Oncol.* 1997;24(1 Suppl 3):S4–S7.
- Sledge GW, Robertson J, Sparano JA, et al. Eastern Cooperative Oncology Group studies of paclitaxel and doxorubicin in advanced breast cancer. *Semin Oncol.* 1995;22(3 Suppl 6):105–108.
- Moliterni A, Lorenzi E, Capri G, et al. Pilot study of primary chemotherapy with doxorubicin plus paclitaxel in women with locally advanced operable breast cancer. *Semin Oncol.* 1997;24(5 Suppl 17):10–14.
- Giannakakou P, Poy G, Zhan Z, Knutsen T, Blagosklonny MV, Fojo T. Paclitaxel selects for mutant or pseudo-null p53 in drug resistance associated with tubulin mutations in human cancer. *Oncogene.* 2000;20(27):3078–3085.
- Hamilton A, Larsimont D, Paridaens R, et al. A study of the value of p53, HER-2/neu, and Bcl-2 in the prediction of response to doxorubicin and paclitaxel as single agents in metastatic breast cancer: a companion study to EORTC 10923. *Clin Breast Cancer.* 2000;1(3):233–240.
- Blagosklonny MV, Schulte TW, Nguyen P, Mimnaugh EG, Trepel J, Neckers L. Taxol induction of p21 WAF1 and p53 requires c-raf-1. *Cancer Res.* 1995;55(20):4623–4626.
- Debernardis D, Sire EG, De Feudis P, et al. p53 status does not affect sensitivity of human ovarian cancer cell lines to paclitaxel. *Cancer Res.* 1997;57(5):870–874.
- Wahl AF, Donaldson KL, Fairchild C, et al. Loss of normal p53 function confers sensitization to Taxol by increasing G2/M arrest and apoptosis. *Nature Med.* 1996;2(1):72–79.
- Wu GS, El Diery WS. p53 and chemo sensitivity. *Nature Med.* 1996;2(3):255–256.
- Fitzgibbons PL, Page DL, Weaver D, et al. Prognostic factors in breast cancer. College of American Pathologists Consensus Statement 1999. *Arch Pathol Lab Med.* 2000;124(7):966–978.
- Eicheler W, Zips D, Dorfler A, Grenman R, Baumann M. splicing mutations in TP53 in human squamous cell lines influences immunohistochemical detection. *J Histochem Cytochem.* 2002;50(2):197–204.
- Logullo AF, de Moura RP, Nonogaki S, Kowalski LP, Nagai MA, Simpson AJ. A proposal for the integration of immunohistochemical staining and DNA-based techniques for the determination of TP53 mutations in human carcinomas. *Diagn Mol Pathol.* 2000;9(1):35–40.
- Allred DC, Harvey JM, Berardo M, Clark GM. Prognostic and predictive factors in breast cancer by immunohistochemistry analysis. *Mod Pathol.* 1998;11(2):155–168.

24. Green M, Hortobagyi GN. Neoadjuvant chemotherapy for operable breast cancer. *Oncology*. 2002;16(7):871–884.
25. Lara PC, Llorc M, Clavo B, et al. Severe hypoxia induces chemoresistance in clinical cervical tumors through MVP over-expression. *Radiat Oncol*. 2009;4:29.
26. Henriquez-Hernandez LA, Murias-Rosales A, Gonzales-Hernandez A, et al. Distribution of TYMS, MTHFR, p53 and MDR1 gene polymorphisms in patients with breast cancer treated with neoadjuvant chemotherapy. *Cancer Epidemiol*. 2010;34(5):634–638.

RETRACTED

Breast Cancer: Targets and Therapy

Dovepress

Publish your work in this journal

Breast Cancer: Targets and Therapy is an international, peer-reviewed open access journal focusing on breast cancer research, identification of therapeutic targets and the optimal use of preventative and integrated treatment interventions to achieve improved outcomes, enhanced survival and quality of life for the cancer patient.

Submit your manuscript here: <http://www.dovepress.com/breast-cancer---targets-and-therapy-journal>

View the full aims and scopes of this journal here. The manuscript management system is completely online and includes a very quick and fair peer-review system, which is all easy to use. Visit <http://www.dovepress.com/testimonials.php> to read real quotes from published authors.