

# The incidence of cervical spondylosis decreases with aging in the elderly, and increases with aging in the young and adult population: a hospital-based clinical analysis

Chuanling Wang<sup>1,\*</sup>  
Fuming Tian<sup>1,\*</sup>  
Yingjun Zhou<sup>2</sup>  
Wenbo He<sup>1</sup>  
Zhiyou Cai<sup>1</sup>

<sup>1</sup>Department of Neurology, <sup>2</sup>Physical Examination Center, Renmin Hospital, Hubei University of Medicine, Shiyen Renmin Hospital, Shiyen, Hubei Province, People's Republic of China

\*These authors contributed equally to this work

**Background and purpose:** Cervical spondylosis is well accepted as a common degenerative change in the cervical spine. Compelling evidence has shown that the incidence of cervical spondylosis increases with age. However, the relationship between age and the incidence of cervical spondylosis remains obscure. It is essential to note the relationship between age and the incidence of cervical spondylosis through more and more clinical data.

**Methods:** In the case-controlled study reported here, retrospective clinical analysis of 1,276 cases of cervical spondylosis has been conducted. We analyzed the general clinical data, the relationship between age and the incidence of cervical spondylosis, and the relationship between age-related risk factors and the incidence of cervical spondylosis. A chi-square test was used to analyze the associations between different variables. Statistical significance was defined as a *P*-value of less than 0.05.

**Results:** The imaging examination demonstrated the most prominent characteristic features of cervical spondylosis: bulge or herniation at C3-C4, C4-C5, and C5-C6. The incidence of cervical spondylosis increased with aging before age 50 years and decreased with aging after age 50 years, especially in the elderly after 60 years old. The occurrence rate of bulge or herniation at C3-C4, C4-C5, C5-C6, and C6-C7 increased with aging before age 50 years and decreased with aging after age 50 years, especially after 60 years. Moreover, the incidence of hyperosteoegeny and spinal stenosis increased with aging before age 60 years and decreased with aging after age 60 years, although there was no obvious change in calcification. The age-related risk factors, such as hypertension, hyperlipidemia, diabetes, cerebral infarct, cardiovascular diseases, smoking, and drinking, have no relationship with the incidence of cervical spondylosis.

**Conclusion:** A decreasing proportion of cervical spondylosis with aging occurs in the elderly, while the proportion of cervical spondylosis increases with aging in the young and the adults. This investigation implicates that aging is not only a contributor to the clinical performance of cervical spondylosis in the elderly, although the incidence of cervical spondylosis is proportional to the progress of age.

**Keywords:** cervical spondylosis, incidence, aging, risk factor

Correspondence: Zhiyou Cai  
Department of Neurology, Renmin Hospital, Hubei University of Medicine, Shiyen Renmin Hospital, No 39 Chaoyang Middle Road, Shiyen 442000, Hubei Province, People's Republic of China  
Tel +86 719 863 7909  
Fax +86 719 863 7909  
Email c0909@hotmail.com

## Introduction

Cervical spondylosis is a chronic degenerative process of the cervical spine that affects the vertebral bodies and intervertebral disks of the neck, and may progress into disk herniation, bone spur formation, compression of the spinal cord, or cervical spondylotic myelopathy.<sup>1</sup> Cervical spondylosis often develops at multiple interspaces and worsens with age.<sup>2,3</sup> Cervical spondylosis can be identified in the

majority of people older than 50 years. There also appears to be a genetic predisposition to develop diseases of the skeletal elements of the spine because some families will have more of these changes.<sup>4-6</sup> It can also be shown that the degenerative changes in the cervical spines of twins follow a very similar pattern.<sup>6,7</sup> Chronic cervical degeneration is the most common cause of progressive spinal cord and nerve root compression. Spondylotic changes are frequently found in many asymptomatic adults, resulting in stenosis of the spinal canal, lateral recess, and foramina.<sup>8,9</sup> Radiculopathy is a result of intervertebral foramina narrowing. Spinal canal stenosis can lead to spinal cord compression, ultimately resulting in cervical spondylosis myelopathy.<sup>8</sup> Cervical disk herniation occurs when the nucleus in the center of the disc pushes out of its normal space.<sup>10</sup> The nucleus presses against the annulus, causing the disc to bulge outward. Gradually, the nucleus herniates completely through the annulus and crushes the disc, compressing the spinal canal or nerve roots. Additionally, the nucleus releases chemicals that can irritate the surrounding nerves causing inflammation and pain.<sup>11,12</sup> Symptoms of cervical spondylosis include one, or a combination, of the following: numbness, weakness and tingling in the neck and/or arms, pain in the neck and/or arms, neck stiffness, headaches, symptomatic compression of the spinal cord (myelopathy) or<sup>13</sup> nerve roots (radiculopathy)<sup>14</sup> or a combination of the two (myeloradiculopathy), or problems with bladder function from cervical myelopathy.<sup>15,16</sup>

Cervical spondylosis is a disorder of age-related wear affecting the disks and vertebrae of cervical spine.<sup>17</sup> Increasing clinical imaging data evidence that age is a risk factor and a contributor to the incidence of cervical spondylosis that increases with aging.<sup>18,19</sup> However, our clinical investigation has recently demonstrated that the trend of the incidence of cervical spondylosis decreases with aging in the elderly and increases with aging in the young and the adults.

## Clinical data and methods

The study was conducted at Renmin Hospital, Hubei University of Medicine in the Central China. It is a general hospital with over 2,500 outpatient visits daily and 2,800 inpatient beds. Subjects (n=1,276) with cervical spondylosis were included. In this study, all data from January 2013 to December 2014 were collected from the all departments of Renmin Hospital, Hubei University of Medicine. This study was approved by the Research Ethics Board of Hubei University of Medicine. Diagnoses were

determined according to 2012 ICD-9-CM Diagnosis Code 721 (721.0 Cervical spondylosis without myelopathy, 721.1 Cervical spondylosis with myelopathy). The comprehensive diagnostic process included medical history, physical examination, and diagnostic tests. All patients with cervical injury, tumor, or infection were excluded from the study. Computed tomography scans and/or magnetic resonance imaging were performed to confirm the diagnosis of cervical spondylosis. The clinical data of all cases were collected, including variables on sociodemographic characteristics, age-related risk factors (hypertension, hyperlipidemia, diabetes, cerebral infarct, cardiovascular diseases, smoking, and drinking), and physical examination findings such as body weight, height, hip and waist circumferences, and blood pressure.

Retrospective clinical analysis of 1,276 cases of cervical spondylosis has been conducted. The data were edited and entered into a computer to be analyzed using SPSS, Windows version 13.0 (IBM Corporation, Armonk, NY, USA). A chi-square test was used to analyze the associations between different variables. Statistical significance was defined as a *P*-value of less than 0.05.

## Results

### The general clinical data analysis

The general clinical data demonstrated that the main symptoms and signs of cervical spondylosis involved pain in the back, neck and/or arms, weakness and tingling in the neck and/or arms, dizziness, headache, vertigo and instability while walking, nausea and vomiting, and neck stiffness. The most prevalent symptom was pain in the back, neck, and/or arms (Table 1). The imaging examination with computed tomography and/or magnetic resonance imaging presented the most prominent characteristic features of cervical spondylosis: bulge or herniation at C3-C4, C4-C5, and C5-C6, besides spinal stenosis, vertebral hyperostosis, calcification, and the disappearance of the spine's physiological curvature (Table 2).

**Table 1** Clinical symptoms and signs

Symptoms or signs	Cases	Percentage
Headache	355	27.8
Dizziness	696	54.5
Neck stiffness	139	12.3
Nausea and vomiting	181	14.2
Weakness and tingling in the neck and/or arms	655	51.3
Pain in the back, neck, and/or arms	1,106	86.7
Vertigo and instability of walking	188	14.7

**Table 2** Imaging features

Imaging features	Cases	Percentage
Bulge or herniation at C2-C3	24	1.9
Bulge or herniation at C3-C4	746	58.5
Bulge or herniation at C4-C5	798	62.5
Bulge or herniation at C5-C6	741	58.1
Bulge or herniation at C6-C7	310	24.3
Bulge or herniation at C7-T1	22	1.7
Hyperosteoegeny	189	14.8
Spinal stenosis	77	6.0
Calcification	8	0.6

## The analysis of relationship between age and the incidence of cervical spondylosis

In general, clinical data showed that the proportion of patients with cervical spondylosis increased with aging before age 50 years and decreased with aging after age 50 years, especially in the elderly after 60 years. The same results were found in both the male and the female subjects. There is an obvious decrease in the incidence of the disease in elderly female patients (Figure 1 and Table 3).

The imaging findings (Figure 2 and Table 4) are consistent with the previous results that the proportion of cervical spondylosis increased with aging before age 50 years and decreased with aging after age 50 years. The occurrence rate of bulge or herniation at C3-C4, C4-C5, and C5-C6, the most prominent characteristic imaging features, increased with aging before age 50 years and decreased with aging after age 50 years, especially after 60 years. The same finding was observed in the bulge or herniation at C6-C7. In addition, the proportion of hyperosteoegeny and spinal stenosis increased with aging before age 60 years and decreased with aging

after age 60 years, although there was no obvious change in calcification.

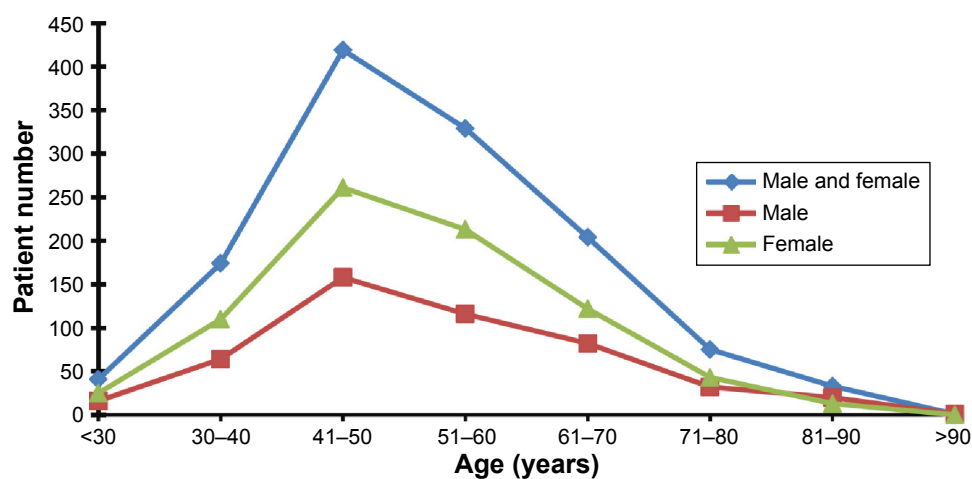
## The relationship between risk factors and the incidence of cervical spondylosis

The association between the clinical risk factors and cervical spondylosis is listed in Table 5. It seems that the most related element with cervical spondylosis was hypertension. However, Table 6 showed that the age-related risk factors (hypertension, hyperlipidemia, diabetes, cerebral infarct, cardiovascular diseases, smoking, and drinking) have no relationship with the incidence of cervical spondylosis.

## Discussion

The one hospital-based clinical investigation showed that the most prevalence symptom of cervical spondylosis is pain in the back, neck, and/or arms, and the most prominent characteristic feature is the bulge or herniation at C3-C4, C4-C5, and C5-C6. The most age-related risk element with cervical spondylosis was hypertension, and to a lesser extent, hyperlipidemia, diabetes, cerebral infarct, cardiovascular diseases, smoking, and drinking. Different from past reports that the incidence of cervical spondylosis increases with aging, the distinctive characteristics of this study have indicated that the incidence of cervical spondylosis increases with aging before age 50 years, and decreases with aging after age 50 years, especially in the elderly after 60 years.

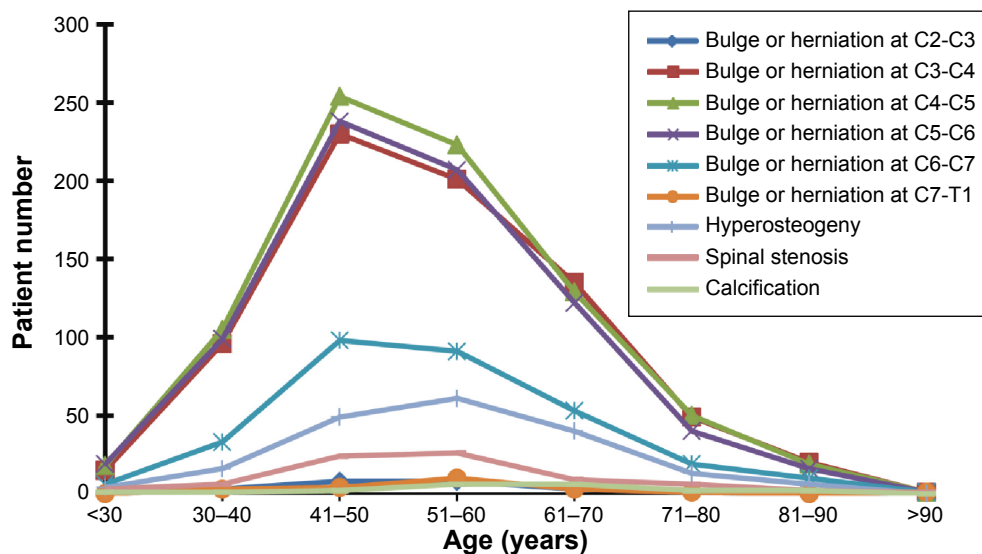
Increasing evidence shows that intervertebral disks lose hydration and elasticity with age, gradually resulting in cracks and fissures and causing a loss of their elastic properties for the surrounding ligaments and developing the onset of spurs.<sup>20-23</sup> The disk subsequently collapses



**Figure 1** Age distribution of patients with cervical spondylosis.

**Table 3** Age distribution of patients with cervical spondylosis

Sex	Age distribution (years)								N
	<30	30-40	41-50	51-60	61-70	71-80	81-90	>90	
Male and female	41	174	419	329	204	75	33	1	1,276
Male	16	64	158	116	82	32	20	1	489
Female	25	110	261	213	122	43	13	0	787



**Figure 2** Age distribution of patients with imaging features of cervical spondylosis.

**Table 4** Age distribution of patients with imaging features of cervical spondylosis

Imaging features	Age distribution (years)								N
	<30	30-40	41-50	51-60	61-70	71-80	81-90	>90	
Bulge or herniation at C2-C3	0	3	8	8	3	1	0	1	24
Bulge or herniation at C3-C4	15	96	230	201	135	49	20	1	746
Bulge or herniation at C4-C5	18	105	254	223	129	50	19	1	798
Bulge or herniation at C5-C6	19	99	238	207	122	40	16	19	741
Bulge or herniation at C6-C7	6	33	98	91	53	19	10	1	310
Bulge or herniation at C7-T1	0	3	4	10	3	1	0	1	22
Hyperosteoegeny	4	16	49	61	40	13	6	0	189
Spinal stenosis	3	6	24	26	6	2	9	1	77
Calcification	1	1	0	2	2	1	1	0	8

**Table 5** Clinical risk factors

Risk factors	Cases	Percentage
Hypertension	209	16.4
Diabetes	81	6.3
Cardiovascular diseases	124	9.7
Cerebral infarct	93	7.3
Smoking	107	8.4
Drinking	91	7.1
Hyperlipidemia	32	2.5

**Table 6** The relationship between risk factors and the incidence of cervical spondylosis

Risk factors	Age distribution (years)								P-value
	<30	30–40	41–50	51–60	61–70	71–80	81–90	>90	
Hypertension	41 9 (22.0%)	174 28 (16.1%)	419 64 (15.3%)	329 50 (15.2%)	204 34 (16.7%)	75 12 (16.0%)	33 11 (33.3%)	1 1 (100%)	0.106
Diabetes	6 (14.6%)	18 (10.3%)	23 (5.5%)	14 (4.3%)	11 (5.4%)	3 (4.0%)	6 (18.2%)	0 (0)	0.093
Cardiovascular diseases	7 (17.1%)	22 (12.6%)	31 (7.4%)	25 (7.6%)	29 (14.2%)	6 (8.0%)	4 (12.1%)	0 (0)	0.081
Cerebral infarct	6 (14.6%)	18 (10.3%)	15 (3.6%)	19 (5.8%)	22 (10.8%)	10 (13.3%)	2 (6.1%)	1 (100%)	0.126
Smoking	4 (9.8%)	15 (8.6%)	39 (9.3%)	33 (10.0%)	11 (5.4%)	3 (4.0%)	2 (6.1%)	0 (0)	0.327
Drinking	5 (12.2%)	20 (11.5%)	34 (8.1%)	16 (4.9%)	10 (4.9%)	4 (5.3%)	2 (6.1%)	0 (0)	0.107
Hyperlipidemia	3 (7.3%)	6 (3.4%)	6 (1.4%)	10 (3.0%)	4 (2.0%)	1 (1.3%)	2 (6.1%)	0 (0)	0.095

as a result of biomechanical disability, leading to serious consequences (the annulus to bulge outward). Annulus fissures and herniation can occur directly after the annulus bulges.<sup>18,24</sup> Disk herniation may be a very poor source of chronic spondylotic changes on the basis of annulus fissures and herniation.<sup>25,26</sup> An increasing clinical and pathological literature supports that cervical spondylotic changes are also a common occurrence with age.<sup>19</sup> With the progress of cervical spondylotic changes, symptoms often develop slowly over time, such as headache, neck stiffness, pain in the back, neck and/or arms, weakness and tingling in the neck and/or arms, dizziness, and so on.<sup>27–30</sup> Patients with cervical spondylosis usually present with neck pain with or without radiculopathy or myelopathy.<sup>26,31</sup> It is well known that the major risk factor is aging. By the age of 60, most persons show signs of cervical spondylosis (according to imaging examination).<sup>2,3,19</sup> With the process of aging, discs gradually dry out, lose their strength and resiliency, and easily induce the occurrence of herniation.<sup>32,33</sup> Accordingly, the clinical presentation will become more pronounced. However, our clinical investigation has implicated that the incidence of cervical spondylosis decreases with aging in the elderly population, especially after 60 years, although it increases with aging before age 50 years. Further assays subsequently proved that there is no relationship between the incidence of cervical spondylosis in the elderly and the age-related risk factors. Thus, we addressed the pathogenesis of cervical spondylosis and showed that the volume and inflammation of the nucleus gets lesser since chronic degeneration contributes to atrophy of the nucleus with the aging process.<sup>34–36</sup> The pressure from the nucleus will become gradually less, resulting in the lower incidence of annulus injury and occurrence of cervical spondylosis, and less clinical manifestations, especially after 60 years of age. Considering that the inflammatory effect of the nucleus is stronger than degeneration in the young and the adults before 50 years, the highest incidence of cervical

spondylosis corresponds with this age stage – approximately 50 years. With the process of aging, the inflammatory effect of the nucleus is weaker than the degeneration of the nucleus after 60 years of age, the incidence of cervical spondylosis will decrease with aging.

Cervical spondylosis is a common condition that is estimated to account for the degenerative changes in the cervical spine, with approximately 90% of cases occurring in those older than 50 years.<sup>37,38</sup> Age may play a dual role in the pathogenesis of cervical spondylosis. In different age stages, cervical spondylosis will have a different clinical feature. In consideration of the previous finding that the incidence of cervical spondylosis increases with aging before age 50 years and decreases with aging after age 50 years, our clinical data indicated that surgery is not the treatment of first choice in elderly patients with cervical spondylosis. If it is not an acute case of nerve and spinal cord compression, nonoperative therapeutic interventions should be designed for the elderly cervical spondylosis patients, such as physical therapy and pain medications. Older cervical spondylosis patients usually have more lesions of cervical disc levels, and then surgery will not benefit to improve functional outcome.<sup>39,40</sup> As age progresses, the volume of the nucleus becomes smaller, and the pressure from the nucleus is less. Hence, the mainstay of the treatment for the old adult patients with cervical spondylosis is in a rehabilitation center if they present with degenerative changes and have no acute symptoms and signs. Moreover, this study also provides new consideration for the future treatment of cervical spondylosis, especially in the elderly population.

## Acknowledgments

This work was supported by grants from the Natural Science Foundation of Hubei Province (2015CFB260), the Hubei Province Health and Family Planning Scientific Research Project (WJ2015MB219), the Shiyan Natural Science Foundation (15K70), and the Natural Science Foundation

of Renmin Hospital, Hubei University of Medicine to Dr Zhiyou Cai.

## Disclosure

The authors report no conflicts of interest in this work.

## References

- Xiong W, Li F, Guan H. Tetraplegia after thyroidectomy in a patient with cervical spondylosis: a case report and literature review. *Medicine (Baltimore)*. 2015;94(6):e524.
- Mamata H, Jolesz FA, Maier SE. Apparent diffusion coefficient and fractional anisotropy in spinal cord: age and cervical spondylosis-related changes. *J Magn Reson Imaging*. 2005;22(1):38–43.
- Zalewski P, Konopka W, Pietkiewicz P. Analysis of vascular vertigo due to cervical spondylosis and vertebro-basilar insufficiency based on sex and age in clinical materials. *Otolaryngol Pol*. 2004;58(1):97–100. Polish.
- Yoo K, Origitano TC. Familial cervical spondylosis. Case report. *J Neurosurg*. 1998;89(1):139–141.
- Wilson JR, Patel AA, Brodt ED, Dettori JR, Brodke DS, Fehlings MG. Genetics and heritability of cervical spondylotic myelopathy and ossification of the posterior longitudinal ligament: results of a systematic review. *Spine (Phila Pa 1976)*. 2013;38(22 Suppl 1):S123–S146.
- Mukerji N, Sinar EJ. Identical twins with cervical myelopathy: a case for hereditary cervical spondylosis? Report of two cases and review of the literature. *J Neurosurg Spine*. 2007;6(4):344–349.
- Palmer PE, Stadalnick R, Arnon S. The genetic factor in cervical spondylosis. *Skeletal Radiol*. 1984;11(3):178–182.
- Kelly JC, Groarke PJ, Butler JS, Poynton AR, O'Byrne JM. The natural history and clinical syndromes of degenerative cervical spondylosis. *Adv Orthop*. 2012;2012:393642.
- Inoue S, Moriyama T, Tachibana T, et al. Risk factors for intraoperative lateral mass fracture of lateral mass screw fixation in the subaxial cervical spine. *J Neurosurg Spine*. 2014;20(1):11–17.
- Peterson CK, Schmid C, Leemann S, Anklin B, Humphreys BK. Outcomes from magnetic resonance imaging-confirmed symptomatic cervical disk herniation patients treated with high-velocity, low-amplitude spinal manipulative therapy: a prospective cohort study with 3-month follow-up. *J Manipulative Physiol Ther*. 2013;36(8):461–467.
- Podichetty VK. The aging spine: the role of inflammatory mediators in intervertebral disc degeneration. *Cell Mol Biol (Noisy-le-grand)*. 2007;53(5):4–18.
- Nackley AG, Makriyannis A, Hohmann AG. Selective activation of cannabinoid CB(2) receptors suppresses spinal fos protein expression and pain behavior in a rat model of inflammation. *Neuroscience*. 2003;119(3):747–757.
- Kato Y, Nishida N, Taguchi T. Paraplegia caused by posture during MRI in a patient with cervical disk herniation. *Orthopedics*. 2010;33(6):448.
- Tzeng YS, Chen SG, Chen TM. Herniation of the cervical disk in plastic surgeons. *Ann Plast Surg*. 2012;69(6):672–674.
- Aurich M, Hofmann GO, Gras FM. Cervical myelopathy after low grade distortion of the cervical spine: possible association with pre-existing spondylosis of the cervical spine. *Unfallchirurg*. 2015;118(4):372–375. German.
- Johansson B. Degeneration of the cervical vertebral disk is seldom the only cause of disk herniation. Cause of disk herniation is a common dispute in insurance cases after whiplash injuries. *Lakartidningen*. 1999;96(34):3540–3541. Swedish.
- Iwanami A, Toyama Y. Cervical spondylosis. *Nihon Rinsho*. 2014;72(10):1755–1760. Japanese.
- Nagashima H, Dokai T, Hashiguchi H, et al. Clinical features and surgical outcomes of cervical spondylotic myelopathy in patients aged 80 years or older: a multi-center retrospective study. *Eur Spine J*. 2011;20(2):240–246.
- Hayashi H, Okada K, Hamada M, Tada K, Ueno R. Etiologic factors of myelopathy. A radiographic evaluation of the aging changes in the cervical spine. *Clin Orthop Relat Res*. 1987;214:200–209.
- Cuellar VG, Cuellar JM, Vaccaro AR, Carragee EJ, Scuderi GJ. Accelerated degeneration after failed cervical and lumbar nucleoplasty. *J Spinal Disord Tech*. 2010;23(8):521–524.
- Pavlova MN, Pogozeva TI. Structural and functional characteristics of the intervertebral disks of infants in the 1st year of life. *Arkh Anat Gistol Embriol*. 1980;79(11):91–98. Russian.
- Stokes IA, Laible JP, Gardner-Morse MG, Costi JJ, Iatridis JC. Refinement of elastic, poroelastic, and osmotic tissue properties of intervertebral disks to analyze behavior in compression. *Ann Biomed Eng*. 2011;39(1):122–131.
- Tyndyk MA, McGarry JP, Barron V, et al. Effects of intervertebral disk degeneration on the flexibility of the human thoracolumbar spine. *J Long Term Eff Med Implants*. 2008;18(4):269–288.
- Del Grande F, Maus TP, Carrino JA. Imaging the intervertebral disk: age-related changes, herniations, and radicular pain. *Radiol Clin North Am*. 2012;50(4):629–649.
- Misterska E, Jankowski R, Glowacki M. Chronic pain coping styles in patients with herniated lumbar discs and coexisting spondylotic changes treated surgically: considering clinical pain characteristics, degenerative changes, disability, mood disturbances, and beliefs about pain control. *Med Sci Monit*. 2013;19:1211–1220.
- Fernandez de Rota JJ, Meschian S, Fernandez de Rota A, Urbano V, Baron M. Cervical spondylotic myelopathy due to chronic compression: the role of signal intensity changes in magnetic resonance images. *J Neurosurg Spine*. 2007;6(1):17–22.
- Misterska E, Jankowski R, Glowacki M. Psychometric properties of the Polish language version of the chronic pain coping inventory-42 for patients treated surgically due to herniated lumbar discs and spondylotic changes. *Med Sci Monit*. 2014;20:789–801.
- Rao R. Neck pain, cervical radiculopathy, and cervical myelopathy: pathophysiology, natural history, and clinical evaluation. *Instr Course Lect*. 2003;52:479–488.
- Sasaki H. Programs for continuing medical education: a session; 4. Clinical manifestation of cervical spondylosis. *Nihon Naika Gakkai Zasshi*. 2012;101(3):675–679. Japanese.
- Takagi I, Eliyas JK, Stadlan N. Cervical spondylosis: an update on pathophysiology, clinical manifestation, and management strategies. *Dis Mon*. 2011;57(10):583–591.
- Gerard CS, O'Toole JE. Current techniques in the management of cervical myelopathy and radiculopathy. *Neurosurg Clin N Am*. 2014;25(2):261–270.
- Morishita Y, Naito M, Hymanson H, Miyazaki M, Wu G, Wang JC. The relationship between the cervical spinal canal diameter and the pathological changes in the cervical spine. *Eur Spine J*. 2009;18(6):877–883.
- Kokubo Y, Uchida K, Kobayashi S, et al. Herniated and spondylotic intervertebral discs of the human cervical spine: histological and immunohistological findings in 500 en bloc surgical samples. Laboratory investigation. *J Neurosurg Spine*. 2008;9(3):285–295.
- Takano M, Kawabata S, Komaki Y, et al. Inflammatory cascades mediate synapse elimination in spinal cord compression. *J Neuroinflammation*. 2014;11:40.
- Beattie MS, Manley GT. Tight squeeze, slow burn: inflammation and the aetiology of cervical myelopathy. *Brain*. 2011;134(Pt 5):1259–1261.
- Nagashima H, Morio Y, Yamane K, Nanjo Y, Teshima R. Tumor necrosis factor-alpha, interleukin-1beta, and interleukin-6 in the cerebrospinal fluid of patients with cervical myelopathy and lumbar radiculopathy. *Eur Spine J*. 2009;18(12):1946–1950.
- Birnie D, Healey JS, Krahn AD, et al. Prevalence and risk factors for cervical and lumbar spondylosis in interventional electrophysiologists. *J Cardiovasc Electrophysiol*. 2011;22(9):957–960.
- Okada E, Matsumoto M, Ichihara D, et al. Aging of the cervical spine in healthy volunteers: a 10-year longitudinal magnetic resonance imaging study. *Spine (Phila Pa 1976)*. 2009;34(7):706–712.

39. Tauchi R, Imagama S, Inoh H, et al. Risk factors for a poor outcome following surgical treatment of cervical spondylotic amyotrophy: a multicenter study. *Eur Spine J*. 2013;22(1):156–161.
40. Inui Y, Miyamoto H, Sumi M, Uno K. Clinical outcomes and predictive factors relating to prognosis of conservative and surgical treatments for cervical spondylotic amyotrophy. *Spine (Phila Pa 1976)*. 2011;36(10):794–799.

### Clinical Interventions in Aging

#### Publish your work in this journal

Clinical Interventions in Aging is an international, peer-reviewed journal focusing on evidence-based reports on the value or lack thereof of treatments intended to prevent or delay the onset of maladaptive correlates of aging in human beings. This journal is indexed on PubMed Central, MedLine,

CAS, Scopus and the Elsevier Bibliographic databases. The manuscript management system is completely online and includes a very quick and fair peer-review system, which is all easy to use. Visit <http://www.dovepress.com/testimonials.php> to read real quotes from published authors.

Submit your manuscript here: <http://www.dovepress.com/clinical-interventions-in-aging-journal>

Dovepress