

# Stereoacuity after small aperture corneal inlay implantation

Steven H Linn<sup>1</sup>  
David F Skanchy<sup>2</sup>  
Tyler S Quist<sup>3</sup>  
Jordan D Desautels<sup>4</sup>  
Majid Moshirfar<sup>1,5</sup>

<sup>1</sup>Department of Clinical Research, HDR Research Center, Hoopes Vision, Draper, UT, <sup>2</sup>McGovern Medical School, The University of Texas Health Science Center at Houston, TX, <sup>3</sup>University of Utah School of Medicine, Salt Lake City, UT, <sup>4</sup>Tufts University School of Medicine, Boston, MA, <sup>5</sup>John A Moran Eye Center, Department of Ophthalmology and Visual Sciences, University of Utah School of Medicine, Salt Lake City, UT, USA

**Purpose:** The aim of this study was to compare stereoacuity before and after KAMRA corneal inlay implantation for the correction of presbyopia.

**Patients and methods:** This is a prospective study of 60 patients who underwent KAMRA inlay implantation. Patients were examined before and 6 months after surgery for stereoacuity, uncorrected distance visual acuity (UDVA), and uncorrected near visual acuity (UNVA).

**Results:** The mean stereoacuity before surgery was  $29.5 \pm 28.1$  arcsec (range: 20–200) and at 6 months was  $29.8 \pm 26.4$  arcsec (range: 20–200). The decline in stereoacuity was not statistically significant. At 6 months follow-up, UDVA was 20/25 or better in all 60 patients and UNVA was J2 (20/25) or better in 51 (85%) patients.

**Conclusion:** There is no significant change in stereoacuity following KAMRA inlay implantation. The KAMRA inlay is a good treatment option for improving near vision in presbyopic patients while preserving stereoacuity and distance vision.

**Keywords:** KAMRA, corneal inlay, AcuFocus, stereoacuity, presbyopia

## Introduction

Stereopsis, or the perception of depth, is a higher level of visual function produced by the brain as it receives visual stimuli from both eyes. Stereoacuity is the smallest measurable difference in depth detected with binocular vision and is reported in arc seconds (1/3,600 of a degree). Smaller numerical values correlate with better stereoacuity and greater depth perception. Impaired stereoacuity may significantly impact daily visuomotor tasks, even in the setting of excellent visual acuity. Recently, the KAMRA corneal inlay (AcuFocus, Inc.) has become a popular surgical option for the treatment of presbyopia. The KAMRA inlay is a small disk that is placed within the corneal stroma of the non-dominant eye. Utilizing the principle of pinhole optics, it increases the depth of focus and improves near vision. Multiple studies have shown the KAMRA inlay to be a safe and effective device.<sup>1–3</sup> Change in stereoacuity has previously been investigated for treatments of presbyopia, such as monovision laser in situ keratomileusis (LASIK) and monovision contact lenses.<sup>4,5</sup> However, in this work, we compare the stereoacuity of patients before and after KAMRA inlay implantation.

## Patients and methods

This is a prospective study of 60 patients who underwent KAMRA inlay implantation for the correction of presbyopia at our institution between October 2009 and June 2010. Analyses performed for this study were part of routine postoperative data collection, and written informed consent was provided by all patients to have their data used for research purposes. An institutional review board approval was not

Correspondence: Majid Moshirfar  
HDR Research Center, Hoopes Vision,  
11820 S State Street Suite #200,  
Draper, UT 84020, USA  
Tel +1 801 568 0200  
Fax +1 801 563 0200  
Email cornea2020@me.com

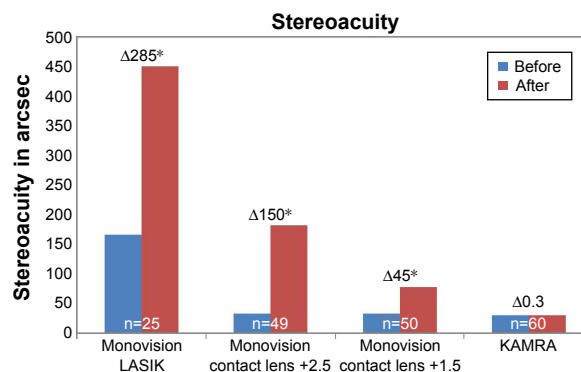
obtained for this study according to the Office for Human Research Protection/Recommended Guidance on Minimal Risk Research and Informed Consent (45 CFR 46.102.i). The mean age was 53 (range: 45–60). Inclusion criteria included a spherical equivalent between +0.50 and –0.75, a monocular uncorrected near visual acuity (UNVA) worse than 20/40 and better than 20/100, and a monocular corrected distance visual acuity (CDVA) of 20/20 or better. Stereoacuity was measured using the Optec 5000 Visual Screener (Stereo Optical Co., Inc., Chicago, IL, USA). The surgical technique and third-generation KAMRA inlay used in this study have previously been described.<sup>1,2</sup> Patients were examined before and 6 months after KAMRA inlay implantation for stereoacuity, uncorrected distance visual acuity (UDVA), and UNVA. Statistical analysis and figure production were accomplished using Microsoft Excel 2016 (Microsoft Corporation, Redmond, WA, USA). Statistical significance was determined using a Wilcoxon signed-rank test for paired samples, with a *P*-value of  $\leq 0.05$ .

## Results

In this study, the mean stereoacuity preoperatively and 6 months postoperatively was  $29.5 \pm 28.1$  arcsec (range: 20–200) and  $29.8 \pm 26.4$  arcsec (range: 20–200), respectively. There was a mean difference between preoperative and postoperative groups of  $-0.3 \pm 19.0$  arcsec (range: –50 to 80), which was not statistically significant ( $P=0.60$ ). Thirty-six (60%) patients had no change in stereoacuity, 9 (15%) patients had improved stereoacuity (range: 10–80), and 15 (25%) patients had worsened stereoacuity (range: –5 to –50). For unknown reasons, one patient had a stereoacuity of 200 arcsec before implantation. However, this patient had no change in stereoacuity after surgery. Preoperatively, this cohort had a mean UDVA of 20/20 (logMAR  $-0.04 \pm 0.09$ ) and UNVA of J7 (20/60, logMAR  $0.47 \pm 0.06$ ). At 6 months follow-up, the mean UDVA was 20/20 (logMAR  $-0.04 \pm 0.07$ ), and UNVA was J2 (20/25, logMAR  $0.06 \pm 0.07$ ).

## Discussion

Stereopsis is an important visual function to determine both position and distance. Following monovision treatment for presbyopia, some patients complain of poor visual outcomes despite great binocular visual acuity. Diminished stereoacuity may be a contributing factor to their discontent. In this study, we report a negligible change in stereoacuity following implantation of the KAMRA corneal inlay in the non-dominant eye. On the contrary, it has been reported that both monovision LASIK and monovision contact lenses for



**Figure 1** Change in stereoacuity before and after treatment with monovision LASIK,<sup>4</sup> monovision contact lenses,<sup>5</sup> and KAMRA inlay implantation.

**Notes:** Δ, Change in stereoacuity; \*statistically significant ( $P < 0.001$ ).

**Abbreviation:** LASIK, laser in situ keratomileusis.

the correction of presbyopia result in a significant decline in stereoacuity (Figure 1).<sup>4,5</sup> Levinger et al measured stereoacuity before and after monovision LASIK with the Optec 6500 vision testing system using far stereo depth perception slides for 20–400 arcsec. The author reported a statistically significant difference between the preoperative and postoperative stereoacuity of 52 and 142 arcsec, respectively. For the study group, the mean postoperative uncorrected binocular visual acuity at distance was 20/25. Durrie evaluated the effect of different monovision contact lens powers on stereoacuity using the Optec 3500 (Stereo Optical, Co. Inc.) device in 50 emmetropic presbyopic patients.<sup>5</sup>

## Conclusions

Overall, the author showed worsening stereoacuity with increasing lens power. Initially, the mean distance stereoacuity was  $32 \pm 23$  arcsec. Following treatment, the mean stereoacuity worsened to  $44 \pm 38$  arcsec for the +0.75 D lens power,  $77 \pm 76$  arcsec for the +1.50 D lens power, and  $182 \pm 142$  arcsec for the +2.50 D lens power. The KAMRA corneal inlay results in improved UNVA while maintaining preoperative UDVA in the treated eye.<sup>1,3</sup> While all three methods significantly improved visual acuity, preoperative stereoacuity was only preserved with the KAMRA corneal inlay.

## Disclosure

The publication fee for this article was paid by Acufocus Inc. The authors report no other conflicts of interest in this work.

## References

- Seyeddain O, Riha W, Hohensinn M, Nix G, Dexl AK, Grabner G. Refractive surgical correction of presbyopia with the Acufocus small aperture corneal inlay: two-year follow-up. *J Refract Surg*. 2010;26(10):707–715.

2. Dexl AK, Seyeddain O, Riha W, et al. One-year visual outcomes and patient satisfaction after surgical correction of presbyopia with an intracorneal inlay of a new design. *J Cataract Refract Surg.* 2012; 38(2):262–269.
3. Dexl AK, Jell G, Strohmaier C, et al. Long-term outcomes after monocular corneal inlay implantation for the surgical compensation of presbyopia. *J Cataract Refract Surg.* 2015;41(3):566–575.
4. Levinger E, Trivizki O, Pokroy R, Levartosky S, Sholov G, Levinger S. Monovision surgery in myopic presbyopes: visual function and satisfaction. *Optom Vis Sci.* 2013;90(10):1092–1097.
5. Durrie DS. The effect of different monovision contact lens powers on the visual function of emmetropic presbyopic patients (an American Ophthalmological Society thesis). *Trans Am Ophthalmol Soc.* 2006; 104:366–401.

### Clinical Ophthalmology

## Publish your work in this journal

Clinical Ophthalmology is an international, peer-reviewed journal covering all subspecialties within ophthalmology. Key topics include: Optometry; Visual science; Pharmacology and drug therapy in eye diseases; Basic Sciences; Primary and Secondary eye care; Patient Safety and Quality of Care Improvements. This journal is indexed on

Submit your manuscript here: <http://www.dovepress.com/clinical-ophthalmology-journal>

PubMed Central and CAS, and is the official journal of The Society of Clinical Ophthalmology (SCO). The manuscript management system is completely online and includes a very quick and fair peer-review system, which is all easy to use. Visit <http://www.dovepress.com/testimonials.php> to read real quotes from published authors.

Dovepress