

# Sudden unilateral visual loss after autologous fat injection into the nasolabial fold

Sang Hyouk Park  
Hae Jung Sun  
Kyung Seek Choi

Department of ophthalmology,  
Soonchunhyang University College  
of Medicine, Seoul, Korea

**Abstract:** A 27-year-old female presented with sudden visual loss of her right eye after receiving an autologous fat injection into the right nasolabial fold. Fundus examination of the right eye showed multiple whitish patchy lesions with macular edema. Fluorescein angiogram showed deterioration of choroidal circulation with patchy choroidal filling and arm-to-retina circulation time and retinal arteriovenous passage time were delayed to 30 seconds and 20 seconds, respectively. There was no response in flash visual evoked potential (VEP). High dose steroid therapy (methylprednisolone 1 g/day/i.v.) was done and about 2 weeks later, the disc edema subsided and retinal arteriovenous passage time of fluorescein angiogram was normalized but there was no improvement in visual acuity. Absence of a cherry red spot, deterioration of choroidal circulation with patchy choroidal fillings seen in fluorescein angiogram, and no response in flash VEP suggests multiple choroidal infarction due to perfusion defect of the short posterior ciliary artery. The autologous fat injected is thought to have entered the dorsal nasal artery and the retrograde migration of the emboli to the ophthalmic artery might have caused the multiple occlusions of the short posterior ciliary artery.

**Keywords:** autologous fat injection, ciliary artery occlusion, ischemic optic neuropathy

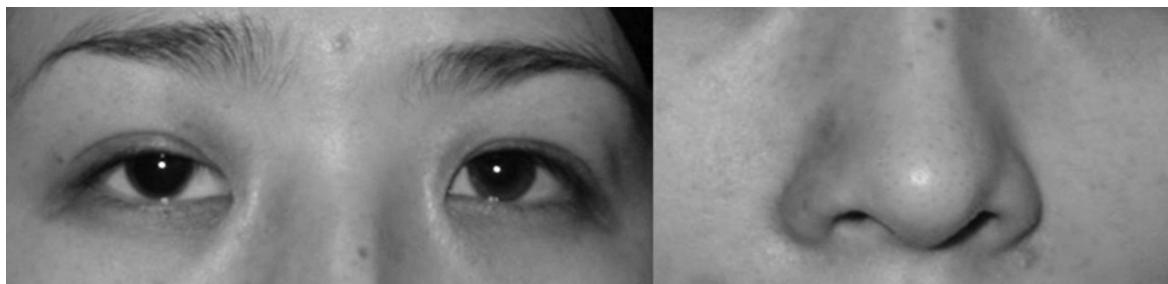
## Introduction

Occlusion of posterior ciliary artery is caused by hypertension, diabetes mellitus, connective tissue diseases, and embolisms which lead to a sudden visual loss by ischemic optic neuropathy. Blindness resulting from retinal vascular occlusions is very rare but can be seen in cases such as subcutaneous injections of drugs on the periocular area. Local injections of steroids on the facial lesions including the periocular area are frequently done for therapeutic reasons and with increasing interests in cosmetic surgery, visual losses have been reported after rhinoplasty as well as with autologous fat injection on glabella and paraffin injection on forehead (Lee et al 1969; Ellis 1978; Whiteman et al 1980; Thomas and Laborde 1986; Cheney and Blair 1987; Dreizen and Framm 1989; Garland et al 1989). We report a case of sudden monocular visual loss after autologous fat injection into the nasolabial fold.

## Case report

A 27-year-old female came into our clinic through the emergency department with a sudden visual loss of her right eye after receiving an autologous fat injection into the right nasolabial fold on the same day. She had received the cosmetic surgery at a local plastic surgery clinic and about ten minutes after the injection, she complained of a sudden blackout of her right eye. There was nothing particular with her past history, family history, and other physical examinations. Slight ptosis of her right eyelid was noticeable and petechia around the right nasolabial fold was seen due to the fat injection (Figure 1). Corrected visual acuity of her right and left eye was hand motion and 1.0 and the intraocular pressure was measured 8 mmHg and 16 mmHg

Correspondence: Kyung Seek Choi  
657 Hannam-dong Yongsan-gu, Seoul  
140-743, Korea  
Tel +82 2 709 9354  
Fax +82 2 798 7797  
Email ckseek@hosp.sch.ac.kr



**Figure 1** Initial photograph of the patient shows mild ptosis of her right eye (right), petechia of autologous fat injection site along the right nasolabial fold (left).

with noncontact tonometer. On slit lamp examinations, the cornea was clear and the anterior chamber was deep with no cells visible. The right pupil was fixed and mid-dilated. Fundus examination of the right eye showed multiple whitish patchy lesions with macular edema (Figure 2). Fluorescein angiogram showed deterioration of choroidal circulation with patchy choroidal filling. Arm-to-retina circulation time and retinal arteriovenous passage time were delayed to 30 seconds and 20 seconds, respectively (Figure 3). No specific findings were seen in echocardiography, carotid Doppler ultrasonography, brain computed tomography, and serological examinations.

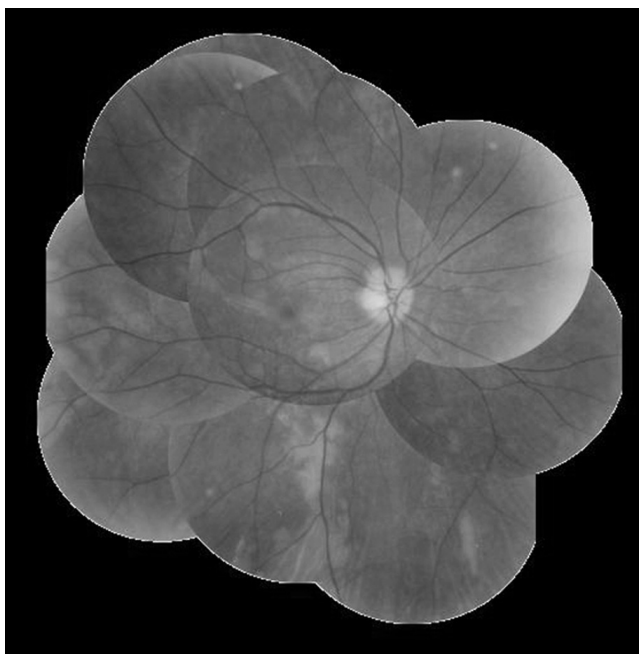
Five days later, there was marked increase in optic disc edema and no response was seen on flash visual evoked potential (VEP) (Figure 4). High dose steroid therapy (methylprednisolone 1 g/day/i.v.) was done for 3 days and dose tapering was done with oral methylprednisolone.

Sixteen days later, no improvement in visual acuity was seen after the steroid therapy and relative afferent papillary defect was present in the right eye. The disc edema subsided and retinal arteriovenous passage time of fluorescein angiogram was normalized to 9 seconds.

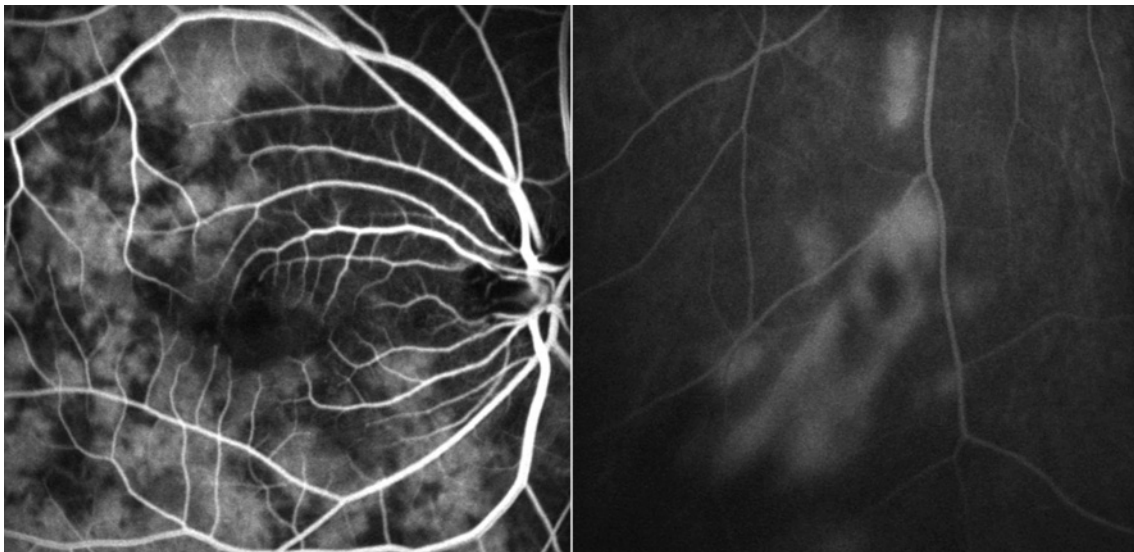
The patient was revisited after 6 months but there was no interval change in vision and relative afferent papillary defect was still present.

## Discussion

Retinal artery occlusion is mainly due to an embolus. It is especially common in atherosclerotic carotid artery diseases and it is also associated with other systemic vasculitides. Plaques in the retinal arterioles are mostly composed of cholesterol, platelet-fibrin coagulate, and calcium precipitate emboli. Unlike the white platelet-fibrin coagulate emboli, bright yellow or orange colored emboli are cholesterol



**Figure 2** Initial fundus photograph of the patient's right eye shows multiple whitish patchy lesions and macular edema.



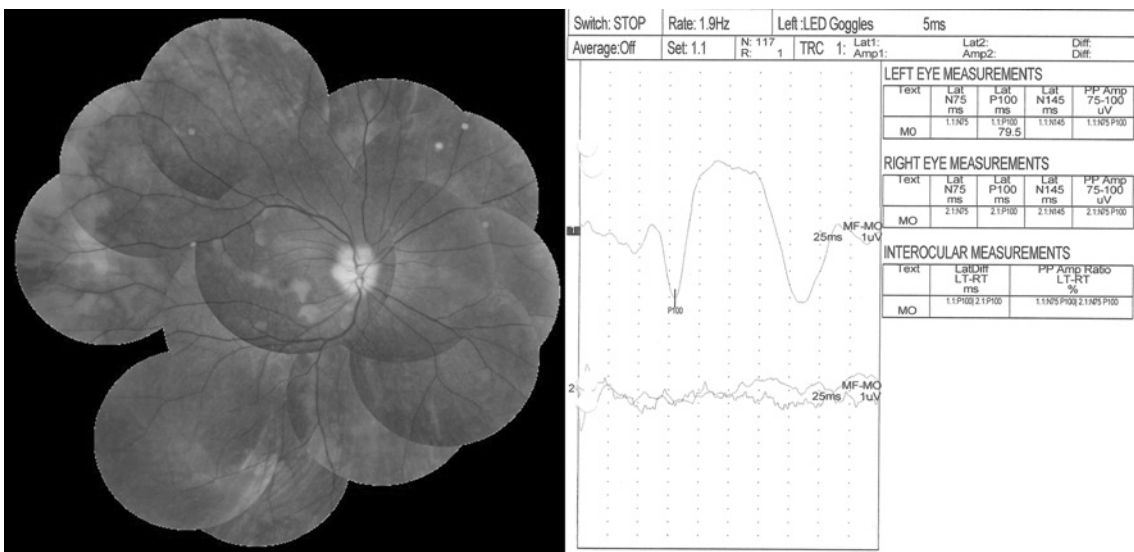
**Figure 3** Initial fluorescein angiogram of the patient shows delayed choroidal filling (right) at early phase and multiple patchy choroidal filling (left) at late phase.

crystals which are broken off from an atheromatous plaque located in the aorta or the carotid artery. These make up the most of the emboli responsible for the retinal artery occlusion (Hollenhorst 1961).

Recently, retinal artery occlusions are being induced iatrogenically. Jee and Lee (2002) reported a case of a 44-year-old female with left ophthalmic artery occlusion and right carotid cavernous fistula after illegal augmentation rhinoplasty of subcutaneous liquid silicone injection. Whiteman and colleagues (1980) and Wilkinson and colleagues (1989) reported concurrent retinal and choroidal microvascular embolism after intranasal corticosteroid injection. Danesh-Meyer and

colleagues (2001) reported a case of ocular and cerebral ischemia following facial injection of autologous fat into the left nasolabial fold which induced occlusions of ipsilateral middle cerebral artery, central retinal artery, and posterior ciliary artery. Egido and colleagues (1993) reported a case of middle cerebral artery embolism and unilateral visual loss after autologous fat injection into the glabellar area.

The ophthalmic artery, which is the first branch of the internal carotid artery, branches out to the retinal artery and the posterior ciliary artery. The posterior ciliary artery then bifurcates to supply blood flow to the sclera and the inner and outer parts of the choroids (Hayreh 1975). The choroidal



**Figure 4** 5 days after the accident, disc edema has increased with more apparent multiple whitish patchy lesions (left), the flash visual evoked potential (VEP) of the right eye shows no response (right).

circulation is in charge of the perfusion of the posterior pole and the optic disc area so if any ischemic changes might occur, the optic nerve might get damaged. Considering the fact that choroidal arteries are end arteries, the damage can get even worse.

In many cases of ciliary artery occlusions, concurrent occlusions of choroidal arteries and retinal arteries are accompanied, contributing to the poor visual prognosis due to the ischemic damage and severe visual loss. Besides, an embolism due to autologous fat which does not respond to thrombolytic agents, as in our case, has a very poor prognosis (Caplan 1993). Dreizen and Framm (1989) reported a case of a patient with unilateral visual loss to no light perception after autologous fat injection into the glabellar area and Danesh-Meyer and colleagues (2001) reported a case whose visual acuity also became no light perception following injection of autologous fat into the nasolabial fold. In our case, the visual acuity of the patient's right eye was hand motion.

Autologous fat is harvested from the buttocks, medial side of the thigh, and around the umbilical area. The donor site should be chosen where there is least vasculature and the recipient site should have plenty of vascular distributions. Harvested autologous fat is slowly injected to prevent damage to the adipose cells usually into the muscle, not into the subcutaneous tissue. Autologous fat particles can enter the vascular network when there is too much vasculature, tissue damage due to trauma, and when fat is injected with high pressure (Stephen et al 2006).

In our case, we can analogize how this autologous fat particle reached to the ophthalmic artery with two different standpoints: a systemic and a localized point of view. In a systemic point of view, the injected fat particle could have entered the facial vein and passed through the systemic circulation to reach the ophthalmic artery to cause the embolism. In a localized point of view, the fat particle might have entered one of the facial branches of the ophthalmic artery, then due to the injection pressure, it could have run counter to the blood flow to reach the ophthalmic artery. Since the patient had no other complications such as dyspnea and other respiratory or systemic symptoms of fat embolism other than unilateral visual loss, and based on the fact that most of the emboli that enter the venous system are filtered while passing through the pulmonary circulation, it is difficult to see the cause of the emboli to be systemic. Feinendegen and colleagues (1998) reported that under a condition with no pulmonary damage, only the injected autologous fat sized less than 7  $\mu\text{m}$  can pass through the systemic circulation to

induce a cerebral infarction. Also, when the injection site and the affected eye are ipsilateral, the visual loss just after the injection gives more support to the localized viewpoint.

The mild ptosis seen in this case might have been caused by the functional occlusion of a branch of the ophthalmic artery which supplies the extraocular muscles giving rise to ischemic changes in the extraocular muscles. The optic disc edema which began five days after the accident is thought to be due to the obstruction of an artery supplying the optic nerve by an embolus. Absence of a cherry red spot, deterioration of choroidal circulation with patchy choroidal fillings seen in fluorescein angiogram, and no response in flash VEP suggests multiple choroidal infarction due to perfusion defect of the short posterior ciliary artery. In conclusion, based on the swelling and petechia of the patient's right nasolabial fold, the autologous fat injected into this area is thought to have entered the dorsal nasal artery and the retrograde migration of the emboli to the ophthalmic artery might have caused the multiple occlusions of the short posterior ciliary artery.

## Conclusion

With the current tendency of increasing cosmetic surgeries, facial autologous fat injections should be carried out with caution and thorough information should be given to the patients that complications of permanent visual loss can occur due to the fat embolism of ciliary or central retinal arteries. To prevent this disastrous event, fat injections should be performed slowly with the lowest possible pressure and injecting fillers with a blunt needle could be another possible method.

## Disclosure

No grants or sponsoring organizations have been involved in the work for this submission. The authors have no proprietary or commercial interests related to the manuscript.

## References

- Caplan LR. 1993. Brain embolism, revisited. *Neurology*, 43:1281–7.
- Cheney ML, Blair PA. 1987. Blindness as a complication of rhinoplasty. *Arch Otolaryngol Head Neck Surg*, 113:768–9.
- Danesh-Meyer HV, Savino PJ, Sergott RC. 2001. Case reports and small case series: ocular and cerebral ischemia following facial injection of autologous fat. *Arch Ophthalmol*, 119:777–8.
- Dreizen NG, Framm L. 1989. Sudden unilateral visual loss after autologous fat injection into the glabellar area. *Am J Ophthalmol*, 107:85–7.
- Egido JA, Arroyo R, Marcos A, et al. 1993. Middle cerebral artery embolism and unilateral visual loss after autologous fat injection into the glabellar area. *Stroke*, 24:615–16.
- Ellis PP. 1978. Occlusion of the central retinal artery after retrobulbar corticosteroid injection. *Am J Ophthalmol*, 85:352–6.
- Feinendegen DL, Baumgartner RW, Vuadens P, et al. 1998. Autologous fat injection for soft tissue augmentation in the face: a safe procedure? *Aesthetic Plast Surg*, 22:163–7.

- Garland PE, Crandall AS, Creel DJ, et al. 1989. Visual disturbance resulting from intranasal steroid injection. Case report. *Arch Ophthalmol*, 107:22–3.
- Hayreh SS. 1975. Segmental nature of the choroidal vasculature. *Br J Ophthalmol*, 59:631–48.
- Hollenhorst RW. 1961. Significance of bright plaques in the retinal arterioles. *JAMA*, 178:23–9.
- Jee DH, Lee KI. 2002. A case of left ophthalmic artery occlusion and right carotid cavernous fistula after illegal rhinoplasty. *J Korean Ophthalmol Soc*, 43:898–904.
- Lee JH, Lee KH, Moon HJ. 1969. A case of unilateral blindness after paraffin injection on the forehead. *J Korean Ophthalmol Soc*, 10:49–51.
- Stephen JM, Vincent RH. 2006. Plastic surgery. 2nd ed. Vol. 1, General Principles. Philadelphia: Elsevier, pp. 579–84.
- Thomas EL, Laborde RP. 1986. Retinal and choroidal vascular occlusion following intralesional corticosteroid injection of a chalazion. *Ophthalmology*, 93:405–7.
- Whiteman DW, Rosen DA, Pinkerton RM. 1980. Retinal and choroidal microvascular embolism after intranasal corticosteroid injection. *Am J Ophthalmol*, 89:851–3.
- Wilkinson WS, Morgan CM, Baruh E, et al. 1989. Retinal and choroidal vascular occlusion secondary to corticosteroid embolization. *Br J Ophthalmol*, 73:32–4.

